

Motile and non-motile cilia in human pathology: from function to phenotypes

Hannah M Mitchison^{1,†,*} and Enza Maria Valente^{2,3,†,*}

¹ Genetics and Genomic Medicine Programme, University College London, UCL Great Ormond Street Institute of Child Health, 30 Guilford Street, London, WC1N 1EH, UK

² Department of Medicine and Surgery, University of Salerno, Salerno, Italy

³ Neurogenetics Unit, IRCCS Santa Lucia Foundation, Via del Fosso di Fiorano, 00143, Rome, Italy

*Correspondence to: Hannah M Mitchison, BSc, PhD, UCL Great Ormond Street Institute of Child Health, 30 Guilford Street, London, WC1N 1EH, UK. E-mail: h.mitchison@ucl.ac.uk; Enza Maria Valente, MD, PhD, Neurogenetics Unit, IRCCS Santa Lucia Foundation, Via del Fosso di Fiorano, 00143 Rome, Italy. E-mail: em.valente@hsantalucia.it

†Equal first/co-senior/co-corresponding authors.

Abstract

Ciliopathies are inherited human disorders caused by both motile and non-motile cilia dysfunction that form an important and rapidly expanding disease category. Ciliopathies are complex conditions to diagnose, being multisystem disorders characterized by extensive genetic heterogeneity and clinical variability with high levels of lethality. There is marked phenotypic overlap among distinct ciliopathy syndromes that presents a major challenge for their recognition, diagnosis, and clinical management, in addition to posing an on-going task to develop the most appropriate family counselling. The impact of next-generation sequencing and high-throughput technologies in the last decade has significantly improved our understanding of the biological basis of ciliopathy disorders, enhancing our ability to determine the possible reasons for the extensive overlap in their symptoms and genetic aetiologies. Here, we review the diverse functions of cilia in human health and disease and discuss a growing shift away from the classical clinical definitions of ciliopathy syndromes to a more functional categorization. This approach arises from our improved understanding of this unique organelle, revealed through new genetic and cell biological insights into the discrete functioning of subcompartments of the cilium (basal body, transition zone, intraflagellar transport, motility). Mutations affecting these distinct ciliary protein modules can confer different genetic diseases and new clinical classifications are possible to define, according to the nature and extent of organ involvement.

Copyright © 2016 Pathological Society of Great Britain and Ireland. Published by John Wiley & Sons, Ltd.

Keywords: cilia; ciliopathies; signalling; ciliogenesis; kidney cystic diseases; Joubert syndrome; skeletal dysplasia; Meckel syndrome; Bardet–Biedl syndrome; oral-facial-digital syndrome

Received 21 October 2016; Revised 3 November 2016; Accepted 4 November 2016

No conflicts of interest were declared.

Introduction

Cilia are highly conserved organelles projecting from the surface of virtually every cell type in the vertebrate body that are found ubiquitously across species from nematodes to ancient protozoa. These complex and dynamic structures are broadly divided into motile and non-motile subtypes that share a 25 µm micrometre diameter cytoskeletal scaffold, the axoneme, composed of hundreds of proteins [1,2]. The axoneme contains nine peripheral microtubule doublets, consisting of A and B tubules, either surrounding a central pair of microtubules (9 + 2 pattern) or lacking the central pair (9 + 0 pattern). Motile 9 + 2 cilia exist as multiple cilia (multicilia), whilst 9 + 0 motile and non-motile cilia exist as single monocilia on the cell surface. Almost all human

cells possess a single non-motile (primary or sensory) cilium, whereas multicilia are generated by specialized cells, and sperm tail (flagella) motility also employs a highly conserved axonemal structure.

During cilia formation (ciliogenesis), the axoneme nucleates from a centriole-derived basal body that docks at the plasma membrane, extending out a microtubule bundle contained within a specialized extension of the plasma membrane that harbours selected signalling molecules and ion channels [3]. Lacking machinery for protein synthesis, proteins of the ciliary compartment synthesized in the Golgi apparatus are imported through a ciliary ‘gate’ located towards the cilia base. This consists of the basal body with transition fibres and a transition zone area above, which directs entry of cargos for their subsequent transport along the length of the cilia [4]. Intraflagellar transport of cargos, IFT, occurs

in a bidirectional manner with the anterograde and retrograde direction of traffic mediated, respectively, by kinesin-2 and cytoplasmic dynein-2 motors attached to multisubunit protein complexes called IFT particles (Figure 1) [5,6]. The functional importance of cilia has emerged in recent years with the recognition of their central role in normal human development and also in disease. 'Ciliopathies' are complex multisystem human disorders of cilia with involvement of all the major organs including the kidney, brain, eye, airways, and limbs; they contribute subtypes to many common diseases such as retinal dystrophy and kidney disease [7–10]. This expanding disease category includes many syndromes such as primary ciliary dyskinesia (PCD), autosomal-dominant and -recessive polycystic kidney diseases (ADPKD, ARPKD), nephronophthisis (NPHP), Leber congenital amaurosis (LCA), and Bardet–Biedl (BBS), Senior–Løken (SLS), Joubert (JBTS), Jeune (or asphyxiating thoracic dystrophy, JATD), short rib polydactyly (SRPS), Meckel–Gruber (MKS) and oral-facial-digital (OFD) syndromes. These inherited disorders are individually rare, but collectively may affect up to 1 in 2000 people [11]. Ciliopathies share common clinical features and there is considerable genetic and phenotypic overlap as well as genetic heterogeneity [12].

Many reviews are available on the structure and functioning of cilia. Here, we present a global overview of the eclectic functions of cilia in different organs and tissues, referring to specialized reviews for further details; moreover, we summarize the spectrum of cilia-related phenotypes in relation to their genetic determinants, and discuss the increasing need to change the way of looking at cilia-related diseases, shifting from the classical definition of ciliopathy syndromes (and related acronyms) to a more descriptive approach based on the type and extent of organ involvement.

Motile ciliopathies

Motile ciliopathies are characterized by dysfunction of tissues, organs, and gametes that bear the specialized ciliary and flagella machinery for generating fluid flow or movement within fluids. Failure of these mechanisms compromises mucus clearance, causing chronic airway diseases which are associated with defects of laterality, fertility, and brain development. The hallmark disease of motile cilia is PCD [13]. About half of affected individuals have laterality defects, most commonly *situs inversus totalis* (mirror image reversal of the internal organs, Kartagener syndrome). A proportion of cases have more complex laterality defects dominated by left isomerism with congenital heart disease [14,15]. Oligocilia or reduced generation of multiple motile cilia (RGMC) is a subtype of PCD presenting the same disease spectrum but with a distinct aetiology: PCD and Kartagener syndrome result from structural and assembly defects of ciliary components, whilst RGMC arises

from defects in the multiciliogenesis programme and is not associated with laterality defects [16,17].

Structure and function of motile cilia

Motile cilia line the epithelial surfaces of the upper and lower respiratory tracts and middle ear, the ventricles of the central nervous system, and the Fallopian tubes. They show variable length (e.g. brain ependymal cilia are longer and beat faster than lung cilia [18]), and axonemal arrangement (9 + 2 in respiratory and Fallopian tube cilia and sperm flagella; 9 + 0 in nodal cilia) [19–21]. Many microtubule-associated multisubunit structures attach with regular periodicity along the axoneme, creating a stable membrane-bound rod that supports and regulates dynein motor-based motility and waveform (Figure 2). Notably, only motile cilia and sperm flagella contain dynein motor proteins that power axonemal beating through ATP hydrolysis [22]. The outer and inner dynein motors are at 96 nm periodicity along the peripheral A tubule, projecting between the peripheral doublets, and two 'molecular ruler' proteins are required to maintain this periodicity [23]. Nexin–dynein regulatory complexes (N-DRCs) link between adjacent peripheral doublets to regulate dynein activity and facilitate inner dynein arm attachment, thereby governing axonemal waveform [24,25]. Radial spoke complexes in close proximity to the inner dynein arms project inwards to the central microtubule apparatus, providing a radial scaffold between the central apparatus and the peripheral microtubules for mechanochemical signal transduction that governs the ciliary beat and waveform [26]. Axoneme structure can vary; for example, the dynein arms differ in composition at the cilia base and tip [27].

The motor and signalling functions of this complex superstructure maintain a uniquely coordinated self-propagating beat [28]. Motile 9 + 0 monocilia of the embryonic left–right organiser beat unidirectionally [21], whilst motile 9 + 2 multicilia form a lawn of 200–300 cilia per cell, creating a coordinated metachronal wave moving at 1000 beats per minute to move fluids. Sperm flagella, though broadly similar in their 9 + 2 arrangement [29], differ in their detailed structure, such as the distribution of dynein arms along the axoneme [27,30]. The sigmoidal, symmetric three-dimensional movement of sperm flagella is also completely distinct from the cilia's planar asymmetric effective and recovery strokes [28,30].

Motile and non-motile cilia in left–right axis determination

Both motile and non-motile primary cilia are essential for establishing correct left–right patterning and the asymmetric positioning of internal organs, a physiological condition termed '*situs solitus*'. Both motile

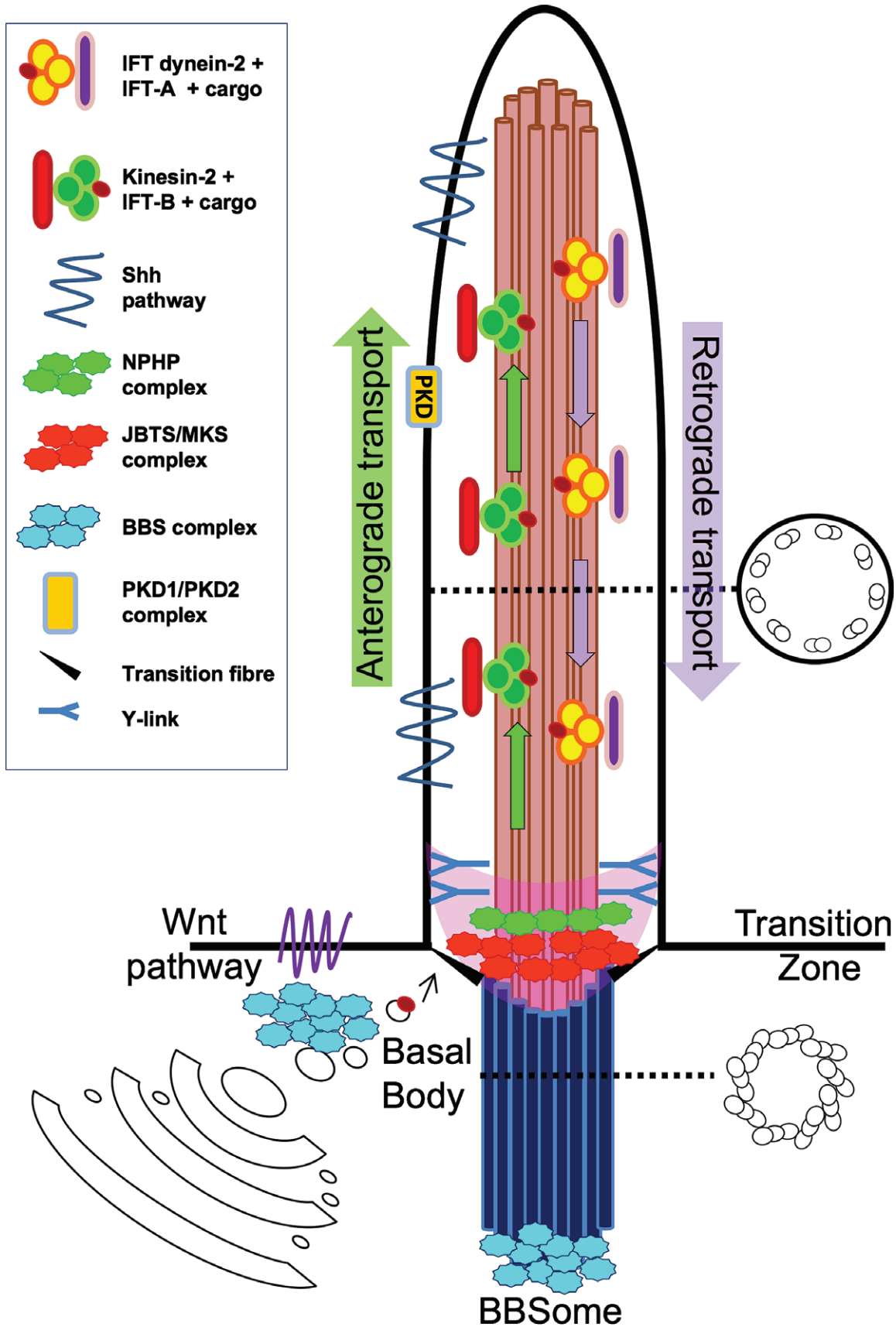


Figure 1. Schematic structure of the primary cilium depicting the main subcilary compartments: the transition zone (pink), containing proteins of the JBTS/MKS complex and the NPH complex; IFT subcomplexes IFT-A and IFT-B (mediating retrograde and anterograde transport, respectively); the BBSome; and the PKD1/PKD2 membrane complex. The relationship of the main developmental pathways Shh and Wnt with the primary cilium is also indicated. Figure adapted from ref 142.

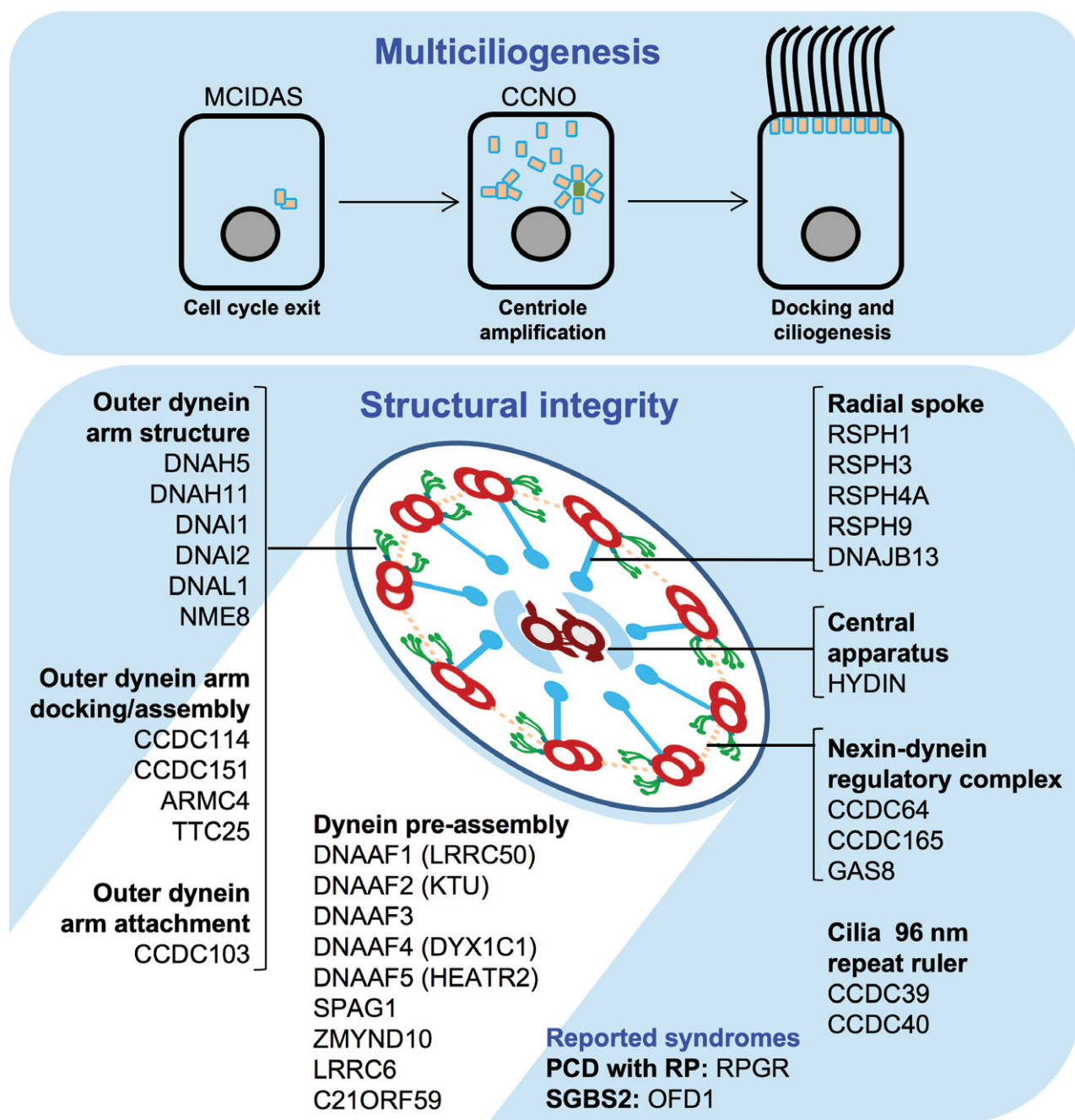


Figure 2. Structure of motile cilia and role of mutant proteins. Motile ciliopathies are caused by mutations in (top panel) components of the ciliogenesis pathway or (bottom panel) structural and attachment proteins of the axoneme dynein 'arm' motors (green), the dynein arm docking complex, the nexin–dynein regulatory complex (dotted lines), the central apparatus (brown), the radial spokes (blue), as well as molecular ruler proteins and cytoplasmic dynein arm assembly factors. Reported syndromes are: PCD associated with retinitis pigmentosa (RP) and Simpson–Golabi–Behmel syndrome, type 2 (SGBS2).

and non-motile ciliopathies can manifest with left–right axis patterning defects. The left–right organiser, part of the embryonic node, appearing early during embryonic development, possesses two types of 9+0 cilia: centrally placed singleton motile cilia and peripherally placed primary immotile cilia. Fluid flow across the embryonic node is a crucial first step in early embryogenesis, marking the earliest point of breaking of bilateral embryo symmetry [21]. Motile node cilia have dynein motors but their lack of a central pair creates a clockwise motion and they rotate at an average 600 rpm to generate a leftward fluid flow in the extracellular

space. The peripheral immotile cilia sense the flow and respond, transmitting signals to the lateral plate mesoderm, which activates an asymmetric gene expression cascade; the most important downstream effector gene is *Nodal*, a member of the TGFβ growth factor family, which induces the asymmetric transcription of downstream genes, activating a self-propagating signalling cascade that establishes LR laterality and the vertebrate body plan [21,31,32]. Left–right patterning is also governed by FGF signalling, which controls the Shh pathway and ciliary length during embryonic development [33,34].

Pathogenesis of motile ciliopathies

Motile cilia in the airways have a prominent role in host defence against infection from inhaled microorganisms and other particles. Airway mucociliary clearance forms an important 'self-cleaning' mechanism by the mucociliary escalator, whereby collaborating mucus-producing epithelial goblet cells and multiciliated cells move mucus containing trapped pathogens and pollutants either up or down to the throat, to be ingested or expelled [35,36]. In the brain, 'ependymal flow' of cerebrospinal fluid (CSF) is generated by multicilia lining the ventricles, which moves signalling molecules through the central nervous system and maintains structure [37,38]. In females, the multiciliated Fallopian tube epithelia assist in the transport of eggs to the uterus, whilst the male gametes are propelled towards the uterus by sperm flagella motility.

In motile cilia diseases, failure of mucociliary clearance is often evident from birth with neonatal respiratory distress. Throughout life, there is progressive accumulation of mucus and pathogens causing obstruction and infections in the sinuses, ears, and lungs [13]. Ultimately the recurring lung infections associated with damage to the lungs can lead to irreversible bronchiectasis and permanent loss of lung function. In cases where laterality is affected, there may be cardiac disease associated with *situs ambiguous* that can be associated with severe congenital heart defects requiring surgery and transplant, and other features of isomerism such as polysplenia and asplenia [14,15]. There is also subfertility in affected males and females, due to reduced and immotile sperm and poor movement along the Fallopian tubes of eggs towards the uterus, with ectopic pregnancy reported.

The central nervous system can also be affected, as brain malformations and hydrocephalus can arise from dysmotility of ependymal cilia. Whilst common in PCD mouse models, hydrocephalus is rare in human PCD, likely due to species differences in the size and structure of the ventricular system. In *DNAH5*-mutant PCD mice, loss of ciliary ependymal CSF flow through the narrow cerebral aqueduct connecting the third and fourth ventricles is thought to contribute to aqueduct closure and consequent triventricular hydrocephalus in the early postnatal brain development period, while the larger aqueducts of the human brain may not be so susceptible to ventricle obstruction [37]. Notably, hydrocephalus is significantly more frequent in human PCD caused by multiciliogenesis defects, where cilia numbers are reduced (RGMC), than in PCD, where the multicilia, even if static, are still present [16,17,39]. The reasons for this are not known, but could be connected to better aqueduct structure maintenance if there are still cilia present, or because the cilia are not always fully static in PCD depending on the underlying mutations. In addition to blocked CSF circulation, hydrocephalus may in fact be initiated by ciliated epithelial cells of the choroid plexus (CPECs), the secretory cell region within each ventricle that produces CSF [40]. CPEC cilia are poorly characterized but

are reported as transiently motile during the perinatal period; however, rather than or additional to motility functions, it may be that defective sensory functions of non-motile cilia also present on CPECs contribute to hydrocephalus through defective ion transport, which is proposed to govern CSF production [40,41].

Motile cilia diseases are genetically heterogeneous, caused by mutations in more than 30 genes affecting dynein motors and other structural components or dynein arm assembly of the multicilia in PCD [13,42–44], whilst multiciliogenesis gene mutations cause RGMC [16,17] (Figure 2). A biological stratification of the motile ciliopathies is starting to emerge since certain features of PCD do not manifest with selected gene mutations. For example, loss of central microtubular pair function caused by mutations in genes such as the *HYDIN* and *RSPH* genes is associated with a lack of laterality defects, since nodal monocilia do not require the central apparatus for motility [13,45]. Interestingly, mutations affecting the radial spokes and nexin–dynein regulatory complexes (N-DRCs) do not cause laterality defects, even though radial spoke and N-DRC genes are expressed at the embryonic node [46,47]. The multiciliogenesis gene defects associated with RGMC affect respiratory and brain cilia motility but apparently not sperm or nodal cilia. Since their mutation does not cause male infertility or laterality defects, though severe cases of hydrocephalus are seen [16,17,39]. It is also apparent that the function of a growing number of ciliary proteins present in the lungs may be provided by other proteins in the sperm, thus causing PCD without male infertility [48].

Non-motile ciliopathies

Non-motile or sensory ciliary disorders represent an expanding group of highly heterogeneous inherited disorders caused by defects in assembly or functioning of the 9 + 0 primary cilium. A wide phenotypic variability is notable amongst primary ciliopathies compared with motile ciliopathies, and extensive genetic and clinical overlaps among distinct conditions reflect their underlying molecular complexity. Indeed, non-motile cilia are much more ubiquitous in the body, functioning as key sensors of extracellular molecules that regulate numerous intracellular signal transduction cascades. Through signalling, primary cilia activate a wide range of responses including modulation of key developmental pathways, control of cell polarity in epithelial tissues, transduction of sensory stimuli, and regulation of stem cell proliferation and maintenance. Bioactive extracellular vesicles (EVs) have also been identified at cilia tips [49,50] and exosomes bearing ciliary membrane proteins have been isolated from the liver and urine [51,52], so cilia have the potential to release vesicles considered to have signalling roles in addition to their capacity to receive sensory signals [52]. Here, we present an overview of the diverse functions of primary cilia as they

relate to different organs of the body and distinct ciliopathy phenotypes. A schematic diagram of the primary cilium with the different subcompartments referred to below is shown in Figure 1.

Functions of primary cilia in embryonic and adult life

Kidneys

Primary cilia protrude from the apical surface of epithelial cells lining the nephron tubule and collecting ducts, in contact with urine flow. In the adult kidney, cilia act as sensory antennae that respond to modifications of urine flow, composition, and osmolality by modulating important intracellular signalling pathways [10,53,54]. For instance, polycystin-1 and -2, the two proteins mutated in ADPKD, were found to regulate a urine-flow dependent, calcium-mediated intracellular response able to influence several signalling pathways, such as G-protein signalling, mTOR, Wnt, and even Sonic Hedgehog (Shh) [55]. Similarly, mutations in ciliary proteins such as inversin or nephrocystin-3, which cause infantile and juvenile nephronophthisis (NPH), alter the balance between canonical and non-canonical Wnt pathways that is essential to control the correct polarity of epithelial tubular cells, thus explaining the pathogenesis of cyst formation [56].

Cilia defects in the kidneys typically lead to the development of cystic kidney diseases. Cysts may form at any age from prenatal to adult life; can vary widely in number, size, and distribution; and in some cases, are associated with progressive interstitial fibrosis, defining a wide spectrum of renal ciliopathies. While the pathomechanisms of cyst formation have largely been elucidated [57,58], how ciliary dysfunction leads to excessive interstitial fibrosis still remains a matter of debate. Recently, several proteins mutated in NPH were found to be implicated in a highly conserved pathway, the so-called DNA damage response (DDR) that senses and signals the presence of DNA damage due to replication stress and can arrest the cell cycle to promote DNA repair. An abnormal DDR could lead to increased apoptosis and epithelial-to-mesenchymal transition of duct cells at the kidney corticomedullary junction and a pro-fibrotic response of surrounding fibroblasts, explaining at least in part the massive fibrosis that usually is more evident than cysts in patients with NPH [59,60].

Brain

Primary cilia were first identified on neuronal cells during electron microscope examinations of brain tissue sections [61,62], but only decades later could the relevance of this observation be fully appreciated. The functional characterization of ciliary genes in cellular and animal models and the dissection of the interplay between the primary cilium and pathways essential for brain development have greatly expanded our

knowledge of the role of this organelle in regulating neuronal cell fate, migration, differentiation, and signalling.

In mammals, primary cilia are essential mediators of the Shh pathway of which many components are variably localized within the cilia at different steps of pathway activation [63]. Dysregulation of Shh signalling due to mutations in genes encoding proteins of the pathway results in neural tube closure defects, hydrocephalus, and other midline defects such as occipital encephalocele, corpus callosum defects, and holoprosencephaly [64] which are also part of the ciliopathy spectrum. Moreover, cilia-mediated Shh signalling represents the main proliferative driver for cerebellar granule neuron precursors [65,66], and mutations or conditional removal of distinct genes implicated in this pathway results in cerebellar dysgenesis and hypoplasia, a condition that is often observed in ciliopathies [67–73].

Another key developmental pathway implicated in cerebellar development is the Wnt canonical pathway, which was found to be enhanced by Joubertin, a ciliary protein encoded by the *AH11* gene. Joubertin knock-out mice display defective cerebellar vermian midline fusion [74,75], and similarly, *AH11* mutations in human patients lead to a notable constellation of mid-hindbrain malformations with cerebellar vermis hypodysplasia, the so-called ‘molar tooth sign’ (MTS) [76]. On the other hand, other evidence suggests a negative ciliary regulation of the Wnt pathway [77], or even no Wnt signalling defects [78], indicating that the interplay between primary cilia and Wnt may be more complex than currently appreciated such that the influence on Wnt could vary according to distinct settings. Besides these, other signalling pathways linked to ciliary function include PDGFR α , involved in promoting directional cell migration [79], and Notch, which was found to enhance the ciliary-mediated activation of the Shh pathway [80].

Neuronal cilia of cortical progenitor cells have also been directly implicated in the modulation of proliferation, directional migration, and differentiation of both excitatory and inhibitory neurons in the developing cerebral cortex [81]. This is thought to be mediated partly by Shh signalling itself and partly by receptors of guidance cues such as PDGFR and GPCR, localized on the ciliary membrane of interneurons [82,83]. A key ciliary component implicated in control of neuronal migration is the cilia membrane-associated small GTPase *ARL13B*, whose ablation results in impaired ciliary localization of specific guidance cue receptors and defective placement of postmitotic interneurons that is also associated with mislocalized ciliary signalling machinery [84,85]. Interestingly, mutations of *ARL13B* typically cause JBTS, a ciliopathy characterized by the MTS and neurological features [86]. *ARL13B* is also implicated in regulation of membrane biogenesis and cilia length control, a function disrupted in the context of JBTS causal mutations [87]. Overt malformations of cortical development such as polymicrogyria have been reported in a minority of JBTS patients [88,89], but it is possible that more subtle defects of cortical development due to

ciliary dysfunction may contribute to the cognitive defects that are nearly invariably seen in JBTS patients. The lack of decussation of the superior cerebellar peduncles and pyramidal tracts reported in neuropathological as well as diffusion tensor imaging tractography studies of patients with JBTS [90,91] has suggested that defective primary cilia could also impair the process of axonal guidance. However, it is also possible that these crossing defects may be secondary to altered cell fate or survival, and a specific role for cilia in axon guidance still remains to be demonstrated to date [92].

Primary cilia are also thought to play a role in the formation of adult neural stem cells, a pool of neural progenitors within the hippocampal dentate gyrus able to generate neurons during postnatal life [93]. Embryonic ablation of either ciliary genes or components of the Shh pathway, such as *Smo*, resulted in failed development of radial astrocytes in the dentate gyrus, with subsequent failure of postnatal neurogenesis [94].

Finally, primary cilia have been reported in both the orexigenic and the anorexigenic neurons in the arcuate nucleus of the hypothalamus, implicated in the metabolic regulation of food intake and responses to the adipocyte hormone leptin and the pancreatic hormone insulin. Indeed, the systematic ablation of some ciliary genes from adult mice resulted in hyperphagia and obesity, with increased levels of insulin, leptin, and glucose [95]. On the other hand, the obesity phenotype observed in some ciliopathies could also relate to defective leptin signalling or leptin resistance, and to abnormal modulation of Shh and Wnt signalling, both of which play a role in the regulation of adipogenesis [96].

Retina

In the vertebrate neural retina, cone and rod photoreceptors rely on the outer segment, a highly specialized ciliary organelle capable of detecting light through a complex structure of regularly stacked, photopigment-filled membranous disks oriented along the axis of the incoming light, which are either fully internalized or in continuity with the plasma membrane. The outer segment is connected to the cell body (also termed inner segment) through a thin connecting 9 + 0 cilium anchored to a triplet microtubule basal body derived from the mother centriole between the outer and inner segment [97]. The photoreceptor-connecting cilium corresponds to the ciliary transition zone of primary cilia, and is essential for regulating the flux of specific proteins in and out of the outer segment. This involves mainly disk proteins such as rhodopsin, which are continuously trafficked along the connecting cilium, as well as other proteins that shuttle between the two compartments following changes in ambient lighting [98]. As in other non-specialized primary cilia, anterograde and retrograde protein trafficking is mediated by IFT complexes which are associated with motor proteins that move up and down the ciliary axoneme. Indeed, selective knockdown of various IFT proteins in mice photoreceptors results in the accumulation of

ectopic rhodopsin, impaired formation of the outer segment, and increased cellular death [99–101].

Given the complexity of the retinal modified cilium, it is not surprising that mutations of multiple photoreceptor proteins can impact at different levels on its development, maintenance, and functioning, resulting in the phenotype of retinal dystrophy that is a common feature in ciliopathies. Photoreceptor proteins associated with ciliopathies include *ALMS1*, mutated in LCA and Alström syndrome (a renal ciliopathy often presenting with retinopathy), which has been implicated in the transport of rhodopsin and other proteins along the photoreceptor axoneme [102]; *CC2D2A*, mutated in retinitis pigmentosa, JBTS, and MKS, which regulates the extension of the connecting cilium and the outer segment [103]; and *TMEM67*, also causative of a spectrum of ciliopathies with multi-organ involvement, which is involved in membrane disk assembly [104]. However, it is interesting to note that isolated forms of retinal dystrophy or LCA are not invariably ciliopathies and only a subset of the many causative genes of this phenotype are implicated in ciliary assembly or function [105]. In parallel, cilia genes can be associated with both isolated or syndromic (ciliopathy) forms of retinal dystrophy, for example *C21ORF2* and *IFT140* [8,9].

Liver

Primary cilia protrude from cholangiocytes, the epithelial cells lining the biliary ducts of the liver. These form early during development starting from a transient structure, the ductal plate, which appears around the sixth to seventh week of gestation in the region between the branches of the portal vein. Here, hepatoblasts start to differentiate into primitive cholangiocytes and form bile ducts, which are separated by surrounding liver parenchyma by intense mesenchymal proliferation paralleled by enhanced apoptotic processes [106]. Similarly to renal cilia, primary cilia on cholangiocytes function as mechano-, chemo-, and osmo-receptors, which sense biliary lumen flow, composition, and osmolality, and transduce these signals through modulation of intracellular calcium and cAMP [107]. The impaired functioning of primary cilia due to mutations in a ciliary protein results in aberrant remodelling of the ductal plate (so-called 'ductal plate malformation of the liver'), with the formation of abnormal bile ducts that are surrounded by excessive extracellular matrix and often present cystic dilatation [108]. This congenital hepatic fibrosis can remain paucisymptomatic or manifest with severe complications, mainly portal hypertension, cholangitis or cholestasis [109]. Many primary ciliopathies display liver fibrosis including PKD, NPHP, BBS, JBTS, and MKS [45,110].

Pancreas

Primary cilia are also involved in the development and functioning of the pancreas, an organ with exocrine and endocrine functions that comprises distinct cell types,

of which about 15% are ciliated. In particular, primary cilia have been detected on ductal cells as well as α -, β -, and δ -cells in the islets of Langerhans [111,112]. Pancreas development is a complex process that involves several key pathways (Shh, Wnt, TGF- β , Notch, and FGF), all of which are modulated by the functioning of primary cilia. Moreover, primary cilia in adult pancreatic ductal cells have been proposed to sense and transduce signals related to luminal flow, similarly to their counterpart in the kidneys and liver [113]. Correlating with this, ciliary impairment has been associated with pancreatic defects that, as in the liver, are mainly characterized by fibrosis, dysplasia, and the formation of ductal cysts. However, pancreatic involvement in ciliopathies is less frequently documented, possibly because the exocrine and endocrine functions are often preserved despite the underlying structural damage. An exception is in Alström syndrome, in which dysfunction of the β -cells and diabetes mellitus are consistent and typical features [114].

Skeletal system

Cilia-related skeletal phenotypes mainly arise from IFT defects that cause deficiency of the Hedgehog pathways, affecting the growth of the cartilage and bones [115]. Indian hedgehog (Ihh) is a key signalling molecule in the endochondral bone formation responsible for most skeletal components including the ribs and long bones, regulating chondrocyte maturation during this ossification process; mice with disrupted Ihh signalling have shortened long bones and a short and narrow thorax [116,117]. Defective Shh in *Ift88* mouse mutants is thought to underlie their polydactyly and aberrant skull formation through incorrect expression of the downstream GLI effectors that specify digit patterning [118,119].

The IFT system has been well characterized by numerous methods including protein crystallography [5,6]. Ciliopathy associated mutations are found in selected subunits of the IFT retrograde dynein motor and components of the IFT complexes A and B [120,121], or proteins of the basal body and centrosomes likely connected to IFT but with less defined functions [9,120,122,123]. Components of IFT implicated in these diseases transport the transmembrane smoothed (SMO) receptor, a key signal transducer in Hedgehog signalling, along the cilia. In their absence, SMO accumulation to cilia is not sufficient to activate the pathway [124,125]. Disturbed ciliary targeting of SMO is at least partially responsible for the premature differentiation and reduced proliferation of chondrocytes in long bone growth plates that underlie SRPS phenotypes [126].

Links between motile and non-motile cilia functions

The links between motile and non-motile ciliopathies are unclear but increasing knowledge about

sensory receptors in motile cilia and the influence of mechanosensory signals on motile cilia in the embryonic node and elsewhere has led to the question of whether sensory functions (chemo- and mechano-sensitivity) can be attributed to motile as well as primary cilia. Clinical ciliopathy studies have reported overlapping features of motile and primary ciliopathy disorders in relation to laterality defects, infertility, and hydrocephalus.

With the unique features of nodal cilia that can move despite sharing the typical 9 + 0 arrangement of non-motile cilia, and the mix of motile and non-motile cilia at the left–right organiser, it is perhaps not surprising that laterality defects, in the form of partial or complete *situs inversus*, are part of the phenotypic spectrum of both motile and non-motile ciliopathies such as JBTS, NPH, and skeletal ciliopathies [127–131]. Interestingly, homozygous mutations in the *NPHP2* gene, which usually cause infantile NPH with *situs inversus*, were found in a fetus displaying these features as well as signs of motile cilia dyskinesia, expanding the phenotypic spectrum of this gene to include motile and non-motile ciliopathies [132].

Lung and airway defects have been reported in BBS, MKS, NPH, and retinal dystrophy patients, but whether these are organ development rather than cilia motility-related problems and whether there is any common aetiology has yet to be proven [133]. Indeed, respiratory motile cilia dysfunction has been excluded in BBS [134]. Syndromic forms of motile cilia disease have been associated with mutations in *RPGR* and *OFD1* (Simpson–Golabi–Behmel syndrome, type 2) but the underlying basis for impaired cilia motility is less clear in these rarer cases where the syndromic features reflect more common phenotypes [135,136].

Phenotypic spectrum of non-motile ciliopathies: more a continuum rather than distinct syndromes

Since the first descriptions of human ciliopathies nearly two decades ago [137,138], the number of disorders falling under the umbrella of primary ciliopathies has significantly increased. Currently, this term includes several syndromes that are clinically diagnosed based on the major organ(s) involved, spanning a spectrum of severity from relatively mild to lethal (Figure 3).

The first group of disorders identified as primary ciliopathies were the cystic kidney disorders, including the two main groups of PKD and NPH. Both ADPKD and ARPKD are characterized by enlarged multicystic kidneys, but they differ by the age at onset (in adult and prenatal life, respectively) and the extent of multi-organ involvement. In fact, ADPKD features multiple cysts in the liver, pancreas, seminal vesicles, and arachnoid membrane, frequently associated with cardiovascular defects (e.g. arterial dilatations/aneurysms and cardiac valve abnormalities), while ARPKD typically presents congenital liver fibrosis [55,139]. While PKDs are extremely rare conditions, juvenile NPH

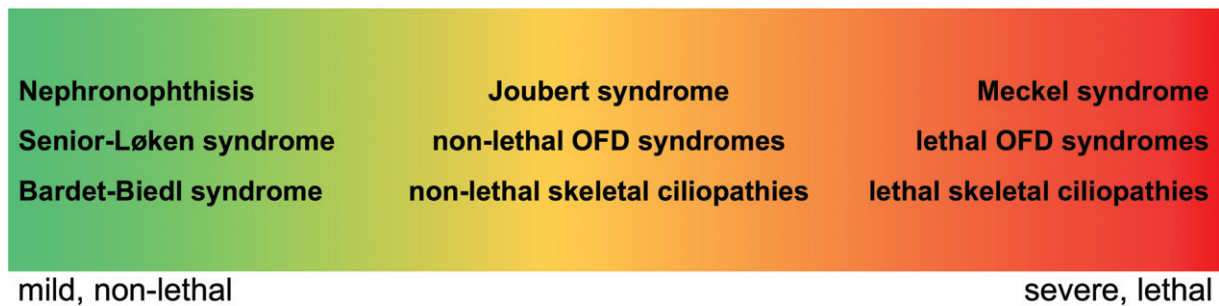


Figure 3. Spectrum of the severity of primary ciliopathies. Distribution of known ciliopathy syndromes across a spectrum of severity.

represents the commonest genetic cause of end-stage renal failure (ESRF) in children. Distinct from PKD, it is characterized by tubular atrophy, irregular tubular membranes, progressive tubulointerstitial fibrosis, and inflammation, leading to the formation of small, hyper-echogenic kidneys and occasional cysts restricted to the corticomedullary border, which appears poorly differentiated. Infantile NPHP, with onset of ESRF in early childhood, is much rarer, and combines the tubular atrophy and fibrosis typical of NPH with widespread cysts and kidney enlargement as seen in PKD. SLS is defined by the association of NPH with retinal dystrophy, often in the severe form of LCA [140].

Among the non-lethal ciliopathies, two relevant conditions are BBS and JBTS. BBS is among the mildest ciliopathies, diagnosed by the primary features of cone-rod retinal dystrophy, post-axial polydactyly, obesity (with hypogonadism in males), genital and renal malformations, and intellectual impairment [141]. JBTS is uniquely characterized by the MTS, a pathognomonic constellation of mid-hindbrain defects clearly appreciable on brain imaging. The MTS derives from the association of cerebellar vermis hypodysplasia, thickened and horizontalized superior cerebellar peduncles, and deepened interpeduncular fossa, giving the appearance of a 'tooth' on MRI axial sections at the pontomesencephalic level. This typical pattern can variably associate with defects in other organs, including the kidneys, retina, liver, and skeleton, giving rise to an extremely large spectrum of phenotypes, from relatively mild to severe [142]. At the end of this spectrum is MKS, a lethal ciliopathy characterized by enlarged cystic kidneys, polydactyly, occipital encephalocele, and frequently congenital liver fibrosis [143].

Two other groups of ciliopathies displaying a wide range of severity are skeletal ciliopathies and OFD syndromes. Skeletal ciliopathies comprise at least 16 different subtypes including the lethal SRPS type I–V and syndromes more compatible with life, Jeune syndrome or asphyxiating thoracic dystrophy (ATD), Mainzer–Saldino syndrome (MZSDS), and Ellis–van Creveld syndrome (EVC or chondroectodermal dysplasia). These recessive disorders of skeletal bone growth manifest with short ribs giving rise to a constricted thorax, shortened long bones, and a characteristic trident aspect to the acetabular roof, with or without polydactyly. Cleft lip/palate and defects of the eye,

heart, kidneys, liver, pancreas, intestines, and genitalia can also be variably present. Cranioectodermal dysplasia (CED; Sensenbrenner syndrome) is an overlapping ciliopathy with similar genetic origins and skeletal abnormalities that feature craniosynostosis, narrow rib cage, short limbs, and brachydactyly [144]. EVC and CED in addition manifest with variable ectodermal defects affecting the teeth, hair, nails, and skin. Finally, OFD syndromes are a heterogeneous group of ciliopathies (more than 15 forms have been described to date) that share the association of oral, facial, and digital defects, and are clinically differentiated by the occurrence of additional involvement of other organs such as the brain and kidneys [145].

While this classification of ciliopathy diseases into distinct subtypes is widely adopted in clinical practice, it is important to bear in mind that the overlap of clinical features among ciliopathies is striking (see Table 2 in ref 144), often making it difficult to assign a specific diagnosis to a patient. For instance, the MTS may occur in association with short ribs and other skeletal defects, fulfilling the diagnosis of both JBTS and JATD [146–148], or in association with typical features of OFD, defining the so-called OFD VI syndrome, which is classified within both the JBTS and the OFD subgroups [145,149]. Adding further complexity, some patients present anomalies that are typical of multiple ciliopathies: one such example is OFD IV, a condition sharing features of SRPS (shortened long bones, trident appearance of the acetabulum), OFD (lobulated tongue, polydactyly), and MKS (occipital encephalocele, enlarged cystic kidneys, and ductal plate proliferation of the liver) [150].

Genetic basis of non-motile ciliopathies

The clinical heterogeneity of non-motile ciliopathies is mirrored by their genetic heterogeneity, and the recent advent of whole-exome and whole-genome sequencing strategies has impressively accelerated the identification of novel ciliopathy genes even in families underpowered for linkage studies [151]. To date, we know of over 50 genes causative of non-motile ciliopathies, and functional studies have disclosed interesting correlates between the function and the ciliary

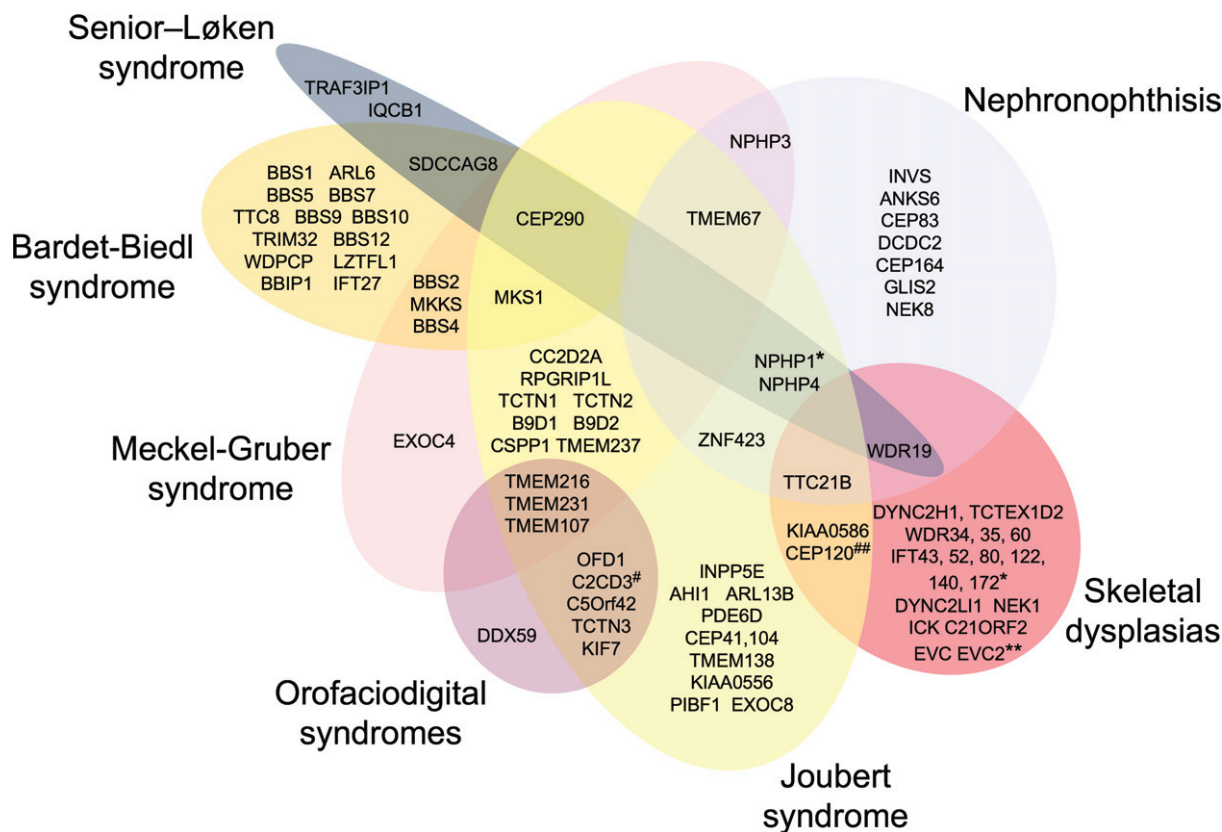


Figure 4. Clinical and genetic variability of primary ciliopathies. Venn diagram summarizing the genetic overlap among distinct ciliopathies. *Also found mutated in a single family with BBS [189,190]. **Also proposed as a novel candidate gene for MKS [180]. #Also found mutated in a single family with skeletal dysplasia [191]. ##Also found mutated in a fetus resembling MKS [192]. Figure extended from ref [193].

domain of the mutated protein and the underlying clinical phenotype. Many proteins were found to cluster in discrete complexes ('modules') bearing specific functions within the cilium. Indeed, most skeletal ciliopathies are caused by mutations in IFT components [152], while the majority of BBS-related proteins form the BBSome that modulates the correct assembly of IFT complexes at the ciliary base and regulates the turnaround from anterograde to retrograde transport at the ciliary tip [153]. Conversely, most proteins mutated in JBTS, MKS, and NPH reside in the transition zone, where they form distinct functional modules (such as JBTS/MKS and NPH complexes), which essentially regulate cilia-related signalling cascades and protein trafficking in and out of the cilium [154] (Figure 1). Protein redundancy and functional interaction between complexes have been demonstrated in distinct *in vivo* models, possibly explaining why mutations in so many genes can result in similar multi-organ pathologies [155,156]. Interestingly, CEP290 was found to regulate the activity of distinct complexes, which could justify the pleiotropic phenotypes associated with its mutations (see below) [157].

Besides gene discovery, next-generation sequencing technologies have also revolutionized genetic diagnosis, allowing us to simultaneously, rapidly, and cost-effectively sequence hundreds of ciliary genes in large cohorts of patients [158]. This has resulted in a more accurate estimate of the mutation frequency, as

well as in an unexpected expansion of the phenotypic spectrum of ciliary genes (Figure 4). Interestingly, some genes appear to be very organ-specific; for instance, mutations in *ARL13B* have been identified only in JBTS patients with purely neurological manifestations [86], while to date *IFT80* and *DYNC2H1* are found mutated only in isolated SRP phenotypes [84,85]. Other genes are not so selective but still show a preferential involvement of specific organs and tissues. Some examples are *TMEM67*, nearly invariably associated with congenital liver fibrosis [159–161]; *C50rf42*, whose mutations cause OFD as well as JBTS with a high prevalence of polydactyly [162,163]; and *IFT40*, mutated in SRPS with a high prevalence of severe kidney diseases [7]. On the other hand, genes such as *CEP290* are extremely pleiotropic, being mutated in a wide spectrum of ciliopathies with defects in the retina, kidneys, liver, and CNS [164]. Similarly, *KIAA0586* mutations are known to cause a relatively mild form of pure JBTS as well as more complex ciliopathy phenotypes, with features of JBTS, OFD, and SRPS [123,147,165–167].

Some genotype–phenotype correlates have been established, as the occurrence of at least one hypomorphic mutation is usually associated with milder phenotypes, while biallelic loss-of-function mutations frequently lead to severe and often lethal disorders [128,160,168,169]. However, such correlates are only in part able to explain this variability, as they are challenged by several pieces of evidence. For instance,

the homozygous deletion of the *NPHP1* gene is a recurrent mutation that is known to cause distinct phenotypes, from isolated NPH to oculo-renal and cerebello-oculo-renal ciliopathies [170–172]. Moreover, significant clinical variability has been reported among siblings carrying the same genetic mutations [173], suggesting the existence of genetic, epigenetic or even environmental modifiers able to modulate their phenotypic manifestation. Some BBS families were found to show ‘oligogenic inheritance’, as autosomal recessive mutations in a BBS gene had to be associated with a third heterozygous mutation in a distinct gene in order to become penetrant [174,175]. While true oligogenic inheritance has not been confirmed in other ciliopathies, the existence of genetic phenotypic modifiers has been suggested by some sporadic observations, showing a positive correlation between the presence of certain heterozygous variants (e.g. *AH11* p.R830W or *RPGRIP1L* p.A229T) and the occurrence of neurological, retinal or renal manifestations [76,176,177]. However, these findings required additional confirmation in larger, independent cohorts.

Despite the progresses in gene discovery made in the past decade, a proportion of patients remain without a genetic diagnosis, indicating that a subset of genes still has to be identified. Of note, this proportion varies among different ciliopathies and, most intriguingly, when considering the organs involved. From recent NGS-based screenings and our own personal experience, we consider that BBS appears to be the most solved condition, a genetic diagnosis being reached in about 70–80% of cases [178,179]. Skeletal ciliopathies and MKS have a success rate above 70% [180–182], while this is up to 60% for JBTS [89]. Yet this proportion lowers to about 40% when considering the subgroup of JBTS with kidney involvement, in line with distinct studies reporting a mutation rate only up to 20% in NPH-related ciliopathies [183,184]. From these observations, it seems that genes with major kidney expression have been less characterized than genes involved, for instance, in skeletal or brain development.

Conclusions and future perspectives

The mutation spectrum for motile ciliopathies (PCD, RGMC) has been greatly expanded, allowing an extensive biology-defined stratification of patients into distinct gene and mutation categories. Moreover, new insights into the regulation of multiciliogenesis have arisen and clinically meaningful correlations are emerging to connect the underlying genotype of affected individuals with clinical outcomes across the lifespan of these chronic diseases [48,185,186]. This assists diagnosis that is complicated by clinical heterogeneity, with motile ciliopathies acknowledged to be greatly underdiagnosed [13]. The hope is to move this field more rapidly towards clinical translation, using novel pharmacogenomic approaches to target therapy in a biologically appropriate manner.

For the primary ciliopathies, the impressive clinical and genetic heterogeneity and marked overlap among distinct syndromes present a major challenge for the physicians dealing with these disorders, and it is not unusual that a patient receives different diagnoses from clinicians with expertise in different pathologies. The complex scenario of ciliopathies recalls the ancient anecdote of ‘the elephant and the blind men’ [187]: six blind men encountered an elephant for the first time and each touched a different part of its body, reaching different conclusions about its nature (a pillar, a rope, a tree branch, a fan, a wall, a pipe) according to the part they had touched (the leg, the tail, the trunk, the ear, the belly, the tusk). Of course, despite each having made an accurate analysis, all had reached false conclusions as they missed the ‘big picture’. Similarly, when approaching a patient with a ciliopathy, a common mistake is that of sticking to a specific syndromic diagnosis based on the presence of certain features. This is not a trivial issue, as it bears consequences in terms of management and counselling of patients and their families. While in some cases a syndromic diagnosis is straightforward, clinicians should be aware that, for other patients, the attempt to classify the phenotype within one or other ciliopathy syndromes may be inaccurate, and it would be better to provide a more descriptive diagnosis based on the extent of multi-organ involvement. The increasing availability of large-scale genetic testing including unbiased approaches such as whole-exome or whole-genome sequencing also provides a useful diagnostic tool, as it allows a reclassification of complex ciliopathy phenotypes based primarily upon their genetic defect, and can suggest a potential spectrum of organ involvement according to the gene that is found mutated.

Current ‘omic’ technologies are also leading ciliary research into novel, intriguing avenues. For instance, an unbiased approach combining affinity proteomics, genetics, and cell biology allowed definition of the ‘ciliary landscape’, highlighting interactions and protein complexes that could not be revealed otherwise, and which can possibly expand the spectrum of ciliopathies to include other, apparently unrelated disorders [188]. Similarly, unbiased siRNA-based functional genomic screens matched with whole-exome sequencing data led to the identification of novel ciliopathy genes and regulators of ciliogenesis [9,166]. Yet despite the major progress made in recent years, the pathobiological mechanisms underlying the striking variable expressivity of ciliary gene mutations remain largely unknown, greatly hampering the appropriate counselling of families, especially those needing to make reproductive choices. In our opinion, a deeper understanding of these mechanisms represents the greatest challenge ahead in the field of ciliopathy research.

Acknowledgements

HMM is a Great Ormond Street Hospital Children’s Charity Reader in Molecular and Medical Genetics and

a member of the EU BMBS COST Action BM1407 'BEAT-PCD' supported by Great Ormond Street Hospital Children's Charity, the National Institute for Health Research Biomedical Research Centre at Great Ormond Street Hospital for Children NHS Foundation Trust, and University College London, Action Medical Research (GN2101), and Newlife Foundation for Disabled Children UK (10-11/15). EMV is supported by grants from the European Research Council (Starting Grant 260888 – CBCD), Telethon Foundation Italy (GGP13146), and the Italian Ministry of Health (NET-2013-02356160). We are grateful to Dr Sara Nuovo for her support in Figure 4 development.

Author contribution statement

HMM and EMV wrote the manuscript, prepared the figures, edited and revised the manuscript, and approved the final version.

References

- Arnaiz O, Cohen J, Tassin AM, *et al.* Remodeling Cildb, a popular database for cilia and links for ciliopathies. *Cilia* 2014; **3**: 9.
- Pazour GJ, Agrin N, Leszyk J, *et al.* Proteomic analysis of a eukaryotic cilium. *J Cell Biol* 2005; **170**: 103–113.
- Goetz SC, Anderson KV. The primary cilium: a signalling centre during vertebrate development. *Nature Rev Genet* 2010; **11**: 331–344.
- Reiter JF, Blacque OE, Leroux MR. The base of the cilium: roles for transition fibres and the transition zone in ciliary formation, maintenance and compartmentalization. *EMBO Rep* 2012; **13**: 608–618.
- Pedersen LB, Rosenbaum JL. Intraflagellar transport (IFT) role in ciliary assembly, resorption and signalling. *Curr Top Dev Biol* 2008; **85**: 23–61.
- Taschner M, Lorentzen E. The intraflagellar transport machinery. *Cold Spring Harb Perspect Biol* 2016; **8**: a028092.
- Schmidts M, Frank V, Eisenberger T, *et al.* Combined NGS approaches identify mutations in the intraflagellar transport gene *IFT140* in skeletal ciliopathies with early progressive kidney disease. *Hum Mutat* 2013; **34**: 714–724.
- Bifari IN, Elkhamary SM, Bolz HJ, *et al.* The ophthalmic phenotype of IFT140-related ciliopathy ranges from isolated to syndromic congenital retinal dystrophy. *Br J Ophthalmol* 2016; **100**: 829–833.
- Wheway G, Schmidts M, Mans DA, *et al.* An siRNA-based functional genomics screen for the identification of regulators of ciliogenesis and ciliopathy genes. *Nature Cell Biol* 2015; **17**: 1074–1087.
- Goggolidou P. Wnt and planar cell polarity signaling in cystic renal disease. *Organogenesis* 2014; **10**: 86–95.
- Quinlan RJ, Tobin JL, Beales PL. Modeling ciliopathies: primary cilia in development and disease. *Curr Top Dev Biol* 2008; **84**: 249–310.
- Arts HH, Knoers NV. Current insights into renal ciliopathies: what can genetics teach us? *Pediatr Nephrol* 2013; **28**: 863–874.
- Lucas JS, Burgess A, Mitchison HM, *et al.* Diagnosis and management of primary ciliary dyskinesia. *Arch Dis Child* 2014; **99**: 850–856.
- Kennedy MP, Omran H, Leigh MW, *et al.* Congenital heart disease and other heterotaxic defects in a large cohort of patients with primary ciliary dyskinesia. *Circulation* 2007; **115**: 2814–2821.
- Harrison MJ, Shapiro AJ, Kennedy MP. Congenital heart disease and primary ciliary dyskinesia. *Paediatr Respir Rev* 2016; **18**: 25–32.
- Boon M, Wallmeier J, Ma L, *et al.* *MCIDAS* mutations result in a mucociliary clearance disorder with reduced generation of multiple motile cilia. *Nature Commun* 2014; **5**: 4418.
- Wallmeier J, Al-Mutairi DA, Chen CT, *et al.* Mutations in *CCNO* result in congenital mucociliary clearance disorder with reduced generation of multiple motile cilia. *Nature Genet* 2014; **46**: 646–651.
- O'Callaghan C, Sikand K, Rutman A. Respiratory and brain ependymal ciliary function. *Pediatr Res* 1999; **46**: 704–707.
- Raidt J, Werner C, Menchen T, *et al.* Ciliary function and motor protein composition of human fallopian tubes. *Hum Reprod* 2015; **30**: 2871–2880.
- Lechtreck KF, Delmote P, Robinson ML, *et al.* Mutations in *Hydin* impair ciliary motility in mice. *J Cell Biol* 2008; **180**: 633–643.
- Pennekamp P, Menchen T, Dworniczak B, *et al.* *Situs inversus* and ciliary abnormalities: 20 years later, what is the connection? *Cilia* 2015; **4**: 1.
- King SM. Axonemal dynein arms. *Cold Spring Harb Perspect Biol* 2016; **8**: a028100.
- Oda T, Yanagisawa H, Kamiya R, *et al.* A molecular ruler determines the repeat length in eukaryotic cilia and flagella. *Science* 2014; **346**: 857–860.
- Heuser T, Raytchev M, Krell J, *et al.* The dynein regulatory complex is the nexin link and a major regulatory node in cilia and flagella. *J Cell Biol* 2009; **187**: 921–933.
- Awata J, Song K, Lin J, *et al.* *DRC3* connects the N-DRC to dynein g to regulate flagellar waveform. *Mol Biol Cell* 2015; **26**: 2788–2800.
- Pigino G, Bui KH, Maheshwari A, *et al.* Cryoelectron tomography of radial spokes in cilia and flagella. *J Cell Biol* 2011; **195**: 673–687.
- Fliegeauf M, Olbrich H, Horvath J, *et al.* Mislocalization of *DNAH5* and *DNAH9* in respiratory cells from patients with primary ciliary dyskinesia. *Am J Respir Crit Care Med* 2005; **171**: 1343–1349.
- Mitchison TJ, Mitchison HM. Cell biology: how cilia beat. *Nature* 2010; **463**: 308–309.
- Afzelius B. Electron microscopy of the sperm tail; results obtained with a new fixative. *J Biophys Biochem Cytol* 1959; **5**: 269–278.
- Linck RW, Chemes H, Albertini DF. The axoneme: the propulsive engine of spermatozoa and cilia and associated ciliopathies leading to infertility. *J Assist Reprod Genet* 2016; **33**: 141–156.
- Blum M, Feistel K, Thumberger T, *et al.* The evolution and conservation of left–right patterning mechanisms. *Development* 2014; **141**: 1603–1613.
- Yoshida S, Hamada H. Roles of cilia, fluid flow, and Ca^{2+} signaling in breaking of left–right symmetry. *Trends Genet* 2014; **30**: 10–17.
- Tanaka Y, Okada Y, Hirokawa N. FGF-induced vesicular release of Sonic hedgehog and retinoic acid in leftward nodal flow is critical for left–right determination. *Nature* 2005; **435**: 172–177.
- Neugebauer JM, Amack JD, Peterson AG, *et al.* FGF signalling during embryo development regulates cilia length in diverse epithelia. *Nature* 2009; **458**: 651–654.
- Mall MA. Role of cilia, mucus, and airway surface liquid in mucociliary dysfunction: lessons from mouse models. *J Aerosol Med Pulm Drug Deliv* 2008; **21**: 13–24.
- Wanner A, Salathe M, O'Riordan TG. Mucociliary clearance in the airways. *Am J Respir Crit Care Med* 1996; **154**: 1868–1902.
- Ibanez-Tallon I, Pagenstecher A, Fliegeauf M, *et al.* Dysfunction of axonemal dynein heavy chain *Mdnah5* inhibits ependymal flow and reveals a novel mechanism for hydrocephalus formation. *Hum Mol Genet* 2004; **13**: 2133–2141.
- Faubel R, Westendorf C, Bodenschatz E, *et al.* Cilia-based flow network in the brain ventricles. *Science* 2016; **353**: 176–178.

39. Amirav I, Wallmeier J, Loges NT, *et al.* Systematic analysis of CCNO variants in a defined population: implications for clinical phenotype and differential diagnosis. *Hum Mutat* 2016; **37**: 396–405.
40. Banizs B, Pike MM, Millican CL, *et al.* Dysfunctional cilia lead to altered ependyma and choroid plexus function, and result in the formation of hydrocephalus. *Development* 2005; **132**: 5329–5339.
41. Narita K, Kozuka-Hata H, Nonami Y, *et al.* Proteomic analysis of multiple primary cilia reveals a novel mode of ciliary development in mammals. *Biol Open* 2012; **1**: 815–825.
42. Olbrich H, Cremers C, Loges NT, *et al.* Loss-of-function *GAS8* mutations cause primary ciliary dyskinesia and disrupt the nexin–dynein regulatory complex. *Am J Hum Genet* 2015; **97**: 546–554.
43. El Khouri E, Thomas L, Jeanson L, *et al.* Mutations in *DNAJB13*, encoding an HSP40 family member, cause primary ciliary dyskinesia and male infertility. *Am J Hum Genet* 2016; **99**: 489–500.
44. Wallmeier J, Shiratori H, Dougherty GW, *et al.* TTC25 deficiency results in defects of the outer dynein arm docking machinery and primary ciliary dyskinesia with left–right body asymmetry randomization. *Am J Hum Genet* 2016; **99**: 460–469.
45. Hildebrandt F, Benzing T, Katsanis N. Ciliopathies. *N Engl J Med* 2011; **364**: 1533–1543.
46. Wirschell M, Olbrich H, Werner C, *et al.* The nexin–dynein regulatory complex subunit DRC1 is essential for motile cilia function in algae and humans. *Nature Genet* 2013; **45**: 262–268.
47. Castleman VH, Romio L, Chodhari R, *et al.* Mutations in radial spoke head protein genes *RSPH9* and *RSPH4A* cause primary ciliary dyskinesia with central-microtubular-pair abnormalities. *Am J Hum Genet* 2009; **84**: 197–209.
48. Onoufriadis A, Paff T, Antony D, *et al.* Splice-site mutations in the axonemal outer dynein arm docking complex gene *CCDC114* cause primary ciliary dyskinesia. *Am J Hum Genet* 2013; **92**: 88–98.
49. Wood CR, Huang K, Diener DR, *et al.* The cilium secretes bioactive ectosomes. *Curr Biol* 2013; **23**: 906–911.
50. Wang J, Silva M, Haas LA, *et al.* *C. elegans* ciliated sensory neurons release extracellular vesicles that function in animal communication. *Curr Biol* 2014; **24**: 519–525.
51. Hogan MC, Manganelli L, Woollard JR, *et al.* Characterization of PKD protein-positive exosome-like vesicles. *J Am Soc Nephrol* 2009; **20**: 278–288.
52. Wang J, Barr MM. Ciliary extracellular vesicles: txt msg organelles. *Cell Mol Neurobiol* 2016; **36**: 449–457.
53. Habbig S, Bartram MP, Muller RU, *et al.* NPHP4, a cilia-associated protein, negatively regulates the Hippo pathway. *J Cell Biol* 2011; **193**: 633–642.
54. Frank V, Habbig S, Bartram MP, *et al.* Mutations in *NEK8* link multiple organ dysplasia with altered Hippo signalling and increased c-MYC expression. *Hum Mol Genet* 2013; **22**: 2177–2185.
55. Saigusa T, Bell PD. Molecular pathways and therapies in autosomal-dominant polycystic kidney disease. *Physiology (Bethesda)* 2015; **30**: 195–207.
56. Lienkamp S, Ganner A, Walz G. Inversin, Wnt signaling and primary cilia. *Differentiation* 2012; **83**: S49–S55.
57. Tran PV, Sharma M, Li X, *et al.* Developmental signaling: does it bridge the gap between cilia dysfunction and renal cystogenesis? *Birth Defects Res C Embryo Today* 2014; **102**: 159–173.
58. Mangolini A, de Stephanis L, Aguiari G. Role of calcium in polycystic kidney disease: from signaling to pathology. *World J Nephrol* 2016; **5**: 76–83.
59. Slaats GG, Giles RH. Are renal ciliopathies (replication) stressed out? *Trends Cell Biol* 2015; **25**: 317–319.
60. Slaats GG, Saldívar JC, Bacal J, *et al.* DNA replication stress underlies renal phenotypes in CEP290-associated Joubert syndrome. *J Clin Invest* 2015; **125**: 3657–3666.
61. Palay SL. The fine structure of secretory neurons in the preoptic nucleus of the goldfish (*Carassius auratus*). *Anat Rec* 1960; **138**: 417–443.
62. Dahl HA. Fine structure of cilia in rat cerebral cortex. *Z Zellforsch Mikrosk Anat* 1963; **60**: 369–386.
63. Ruat M, Roudaut H, Ferret J, *et al.* Hedgehog trafficking, cilia and brain functions. *Differentiation* 2012; **83**: S97–S104.
64. Murdoch JN, Copp AJ. The relationship between Sonic Hedgehog signaling, cilia, and neural tube defects. *Birth Defects Res A Clin Mol Teratol* 2010; **88**: 633–652.
65. De Luca A, Cerrato V, Fuca E, *et al.* Sonic hedgehog patterning during cerebellar development. *Cell Mol Life Sci* 2016; **73**: 291–303.
66. Spassky N, Han YG, Aguilar A, *et al.* Primary cilia are required for cerebellar development and Shh-dependent expansion of progenitor pool. *Dev Biol* 2008; **317**: 246–259.
67. Putoux A, Thomas S, Coene KL, *et al.* *KIF7* mutations cause fetal hydrolethals and acrocallosal syndromes. *Nature Genet* 2011; **43**: 601–606.
68. Dafinger C, Liebau MC, Elsayed SM, *et al.* Mutations in *KIF7* link Joubert syndrome with Sonic Hedgehog signaling and microtubule dynamics. *J Clin Invest* 2011; **121**: 2662–2667.
69. Vortkamp A, Gessler M, Grzeschik KH. *GLI3* zinc-finger gene interrupted by translocations in Greig syndrome families. *Nature* 1991; **352**: 539–540.
70. Kang S, Graham JM Jr, Olney AH, *et al.* *GLI3* frameshift mutations cause autosomal dominant Pallister–Hall syndrome. *Nature Genet* 1997; **15**: 266–268.
71. Elson E, Perveen R, Donnai D, *et al.* *De novo GLI3* mutation in acrocallosal syndrome: broadening the phenotypic spectrum of *GLI3* defects and overlap with murine models. *J Med Genet* 2002; **39**: 804–806.
72. Patterson VL, Damrau C, Paudyal A, *et al.* Mouse hitchhiker mutants have spina bifida, dorso-ventral patterning defects and polydactyly: identification of Tulp3 as a novel negative regulator of the Sonic hedgehog pathway. *Hum Mol Genet* 2009; **18**: 1719–1739.
73. Kim JJ, Gill PS, Rotin L, *et al.* Suppressor of fused controls mid-hindbrain patterning and cerebellar morphogenesis via *GLI3* repressor. *J Neurosci* 2011; **31**: 1825–1836.
74. Lancaster MA, Gopal DJ, Kim J, *et al.* Defective Wnt-dependent cerebellar midline fusion in a mouse model of Joubert syndrome. *Nature Med* 2011; **17**: 726–731.
75. Lancaster MA, Schroth J, Gleeson JG. Subcellular spatial regulation of canonical Wnt signalling at the primary cilium. *Nature Cell Biol* 2011; **13**: 700–707.
76. Louie CM, Caridi G, Lopes VS, *et al.* *AHI1* is required for photoreceptor outer segment development and is a modifier for retinal degeneration in nephronophthisis. *Nature Genet* 2010; **42**: 175–180.
77. Corbit KC, Shyer AE, Dowdle WE, *et al.* *Kif3a* constrains beta-catenin-dependent Wnt signalling through dual ciliary and non-ciliary mechanisms. *Nature Cell Biol* 2008; **10**: 70–76.
78. Ocbina PJ, Tuson M, Anderson KV. Primary cilia are not required for normal canonical Wnt signaling in the mouse embryo. *PLoS One* 2009; **4**: e6839.
79. Carter CS, Vogel TW, Zhang Q, *et al.* Abnormal development of *NG2*⁺*PDGFR-α*⁺ neural progenitor cells leads to neonatal hydrocephalus in a ciliopathy mouse model. *Nature Med* 2012; **18**: 1797–1804.
80. Stasiulewicz M, Gray SD, Mastromina I, *et al.* A conserved role for Notch signaling in priming the cellular response to Shh through ciliary localisation of the key Shh transducer Smo. *Development* 2015; **142**: 2291–2303.
81. Sarkisian MR, Guadiana SM. Influences of primary cilia on cortical morphogenesis and neuronal subtype maturation. *Neuroscientist* 2015; **21**: 136–151.

82. Mukhopadhyay S, Rohatgi R. G-protein-coupled receptors, Hedgehog signaling and primary cilia. *Semin Cell Dev Biol* 2014; **33**: 63–72.
83. Hilgendorf KI, Johnson CT, Jackson PK. The primary cilium as a cellular receiver: organizing ciliary GPCR signaling. *Curr Opin Cell Biol* 2016; **39**: 84–92.
84. Higginbotham H, Eom TY, Mariani LE, *et al.* Arl13b in primary cilia regulates the migration and placement of interneurons in the developing cerebral cortex. *Dev Cell* 2012; **23**: 925–938.
85. Higginbotham H, Guo J, Yokota Y, *et al.* Arl13b-regulated cilia activities are essential for polarized radial glial scaffold formation. *Nature Neurosci* 2013; **16**: 1000–1007.
86. Cantagrel V, Silhavy JL, Bielas SL, *et al.* Mutations in the cilia gene *ARL13B* lead to the classical form of Joubert syndrome. *Am J Hum Genet* 2008; **83**: 170–179.
87. Lu H, Toh MT, Narasimhan V, *et al.* A function for the Joubert syndrome protein Arl13b in ciliary membrane extension and ciliary length regulation. *Dev Biol* 2015; **397**: 225–236.
88. Dixon-Salazar T, Silhavy JL, Marsh SE, *et al.* Mutations in the *AH11* gene, encoding joubertin, cause Joubert syndrome with cortical polymicrogyria. *Am J Hum Genet* 2004; **75**: 979–987.
89. Bachmann-Gagescu R, Dempsey JC, Phelps IG, *et al.* Joubert syndrome: a model for untangling recessive disorders with extreme genetic heterogeneity. *J Med Genet* 2015; **52**: 514–522.
90. Friede RL, Boltshauser E. Uncommon syndromes of cerebellar vermis aplasia. I: Joubert syndrome. *Dev Med Child Neurol* 1978; **20**: 758–763.
91. Poretti A, Boltshauser E, Loenneker T, *et al.* Diffusion tensor imaging in Joubert syndrome. *AJNR Am J Neuroradiol* 2007; **28**: 1929–1933.
92. Engle EC. Human genetic disorders of axon guidance. *Cold Spring Harbor Persp Biol* 2010; **2**: a001784.
93. Gage FH, Temple S. Neural stem cells: generating and regenerating the brain. *Neuron* 2013; **80**: 588–601.
94. Han YG, Spassky N, Romaguera-Ros M, *et al.* Hedgehog signaling and primary cilia are required for the formation of adult neural stem cells. *Nature Neurosci* 2008; **11**: 277–284.
95. Davenport JR, Watts AJ, Roper VC, *et al.* Disruption of intraflagellar transport in adult mice leads to obesity and slow-onset cystic kidney disease. *Curr Biol* 2007; **17**: 1586–1594.
96. Oh EC, Vasanth S, Katsanis N. Metabolic regulation and energy homeostasis through the primary cilium. *Cell Metab* 2015; **21**: 21–31.
97. Goldberg AF, Moritz OL, Williams DS. Molecular basis for photoreceptor outer segment architecture. *Prog Retin Eye Res* 2016; **55**: 52–81.
98. Pearring JN, Salinas RY, Baker SA, *et al.* Protein sorting, targeting and trafficking in photoreceptor cells. *Prog Retin Eye Res* 2013; **36**: 24–51.
99. Lopes VS, Jimeno D, Khanobdee K, *et al.* Dysfunction of heterotrimeric kinesin-2 in rod photoreceptor cells and the role of opsin mislocalization in rapid cell death. *Mol Biol Cell* 2010; **21**: 4076–4088.
100. Jimeno D, Lillo C, Roberts EA, *et al.* Kinesin-2 and photoreceptor cell death: requirement of motor subunits. *Exp Eye Res* 2006; **82**: 351–353.
101. Pazour GJ, Baker SA, Deane JA, *et al.* The intraflagellar transport protein, IFT88, is essential for vertebrate photoreceptor assembly and maintenance. *J Cell Biol* 2002; **157**: 103–113.
102. Collin GB, Cyr E, Bronson R, *et al.* Alms1-disrupted mice recapitulate human Alström syndrome. *Hum Mol Genet* 2005; **14**: 2323–2333.
103. Bachmann-Gagescu R, Phelps IG, Stearns G, *et al.* The ciliopathy gene *cc2d2a* controls zebrafish photoreceptor outer segment development through a role in Rab8-dependent vesicle trafficking. *Hum Mol Genet* 2011; **20**: 4041–4055.
104. Collin GB, Won J, Hicks WL, *et al.* Meckelin is necessary for photoreceptor intraciliary transport and outer segment morphogenesis. *Invest Ophthalmol Vis Sci* 2012; **53**: 967–974.
105. Nash BM, Wright DC, Grigg JR, *et al.* Retinal dystrophies, genomic applications in diagnosis and prospects for therapy. *Transl Pediatr* 2015; **4**: 139–163.
106. Roskams T, Desmet V. Embryology of extra- and intrahepatic bile ducts, the ductal plate. *Anat Rec (Hoboken)* 2008; **291**: 628–635.
107. Masyuk AI, Masyuk TV, LaRusso NF. Cholangiocyte primary cilia in liver health and disease. *Dev Dyn* 2008; **237**: 2007–2012.
108. Desmet VJ. Congenital diseases of intrahepatic bile ducts: variations on the theme ‘ductal plate malformation’. *Hepatology* 1992; **16**: 1069–1083.
109. Rock N, McLin V. Liver involvement in children with ciliopathies. *Clin Res Hepatol Gastroenterol* 2014; **38**: 407–414.
110. Gunay-Aygun M. Liver and kidney disease in ciliopathies. *Am J Med Genet C Semin Med Genet* 2009; **151C**: 296–306.
111. Aughtsteen AA. The ultrastructure of primary cilia in the endocrine and excretory duct cells of the pancreas of mice and rats. *Eur J Morphol* 2001; **39**: 277–283.
112. Yamamoto M, Kataoka K. Electron microscopic observation of the primary cilium in the pancreatic islets. *Arch Histol Jpn* 1986; **49**: 449–457.
113. Lodh S, O’Hare EA, Zaghoul NA. Primary cilia in pancreatic development and disease. *Birth Defects Res C Embryo Today* 2014; **102**: 139–158.
114. Marshall JD, Maffei P, Collin GB, *et al.* Alström syndrome: genetics and clinical overview. *Curr Genomics* 2011; **12**: 225–235.
115. Ruiz-Perez VL, Blair HJ, Rodriguez-Andres ME, *et al.* Evc is a positive mediator of Ihh-regulated bone growth that localises at the base of chondrocyte cilia. *Development* 2007; **134**: 2903–2912.
116. St-Jacques B, Hammerschmidt M, McMahon AP. Indian hedgehog signaling regulates proliferation and differentiation of chondrocytes and is essential for bone formation. *Genes Dev* 1999; **13**: 2072–2086.
117. Karp SJ, Schipani E, St-Jacques B, *et al.* Indian hedgehog coordinates endochondral bone growth and morphogenesis via parathyroid hormone related-protein-dependent and -independent pathways. *Development* 2000; **127**: 543–548.
118. Haycraft CJ, Zhang Q, Song B, *et al.* Intraflagellar transport is essential for endochondral bone formation. *Development* 2007; **134**: 307–316.
119. Wen X, Lai CK, Evangelista M, *et al.* Kinetics of hedgehog-dependent full-length Gli3 accumulation in primary cilia and subsequent degradation. *Mol Cell Biol* 2010; **30**: 1910–1922.
120. Huber C, Cormier-Daire V. Ciliary disorder of the skeleton. *Am J Med Genet C Semin Med Genet* 2012; **160C**: 165–174.
121. Schmidts M, Hou Y, Cortes CR, *et al.* *TCTEX1D2* mutations underlie Jeune asphyxiating thoracic dystrophy with impaired retrograde intraflagellar transport. *Nature Commun* 2015; **6**: 7074.
122. Shaheen R, Schmidts M, Faqeih E, *et al.* A founder *CEP120* mutation in Jeune asphyxiating thoracic dystrophy expands the role of centriolar proteins in skeletal ciliopathies. *Hum Mol Genet* 2015; **24**: 1410–1419.
123. Alby C, Piquand K, Huber C, *et al.* Mutations in *KIAA0586* cause lethal ciliopathies ranging from a hydrolethalus phenotype to short-rib polydactyly syndrome. *Am J Hum Genet* 2015; **97**: 311–318.
124. May SR, Ashique AM, Karlen M, *et al.* Loss of the retrograde motor for IFT disrupts localization of Smo to cilia and prevents the expression of both activator and repressor functions of Gli. *Dev Biol* 2005; **287**: 378–389.

125. Ocbina PJ, Anderson KV. Intraflagellar transport, cilia, and mammalian Hedgehog signaling: analysis in mouse embryonic fibroblasts. *Dev Dyn* 2008; **237**: 2030–2038.
126. Rix S, Calmont A, Scambler PJ, *et al.* An Ift80 mouse model of short rib polydactyly syndromes shows defects in hedgehog signalling without loss or malformation of cilia. *Hum Mol Genet* 2011; **20**: 1306–1314.
127. Brancati F, Barrano G, Silhavy JL, *et al.* CEP290 mutations are frequently identified in the oculo-renal form of Joubert syndrome-related disorders. *Am J Med Genet* 2007; **81**: 104–113.
128. Bergmann C, Fliegauf M, Bruchle NO, *et al.* Loss of nephrocystin-3 function can cause embryonic lethality, Meckel–Gruber-like syndrome, situs inversus, and renal-hepatic-pancreatic dysplasia. *Am J Hum Genet* 2008; **82**: 959–970.
129. Otto EA, Schermer B, Obara T, *et al.* Mutations in *INVS* encoding inversin cause nephronophthisis type 2, linking renal cystic disease to the function of primary cilia and left–right axis determination. *Nature Genet* 2003; **34**: 413–420.
130. Chen CP, Chang TY, Tzen CY, *et al.* Sonographic detection of situs inversus, ventricular septal defect, and short-rib polydactyly syndrome type III (Verma–Naumoff) in a second-trimester fetus not known to be at risk. *Ultrasound Obstet Gynecol* 2002; **19**: 629–631.
131. Majewski E, Ozturk B, Gillessen-Kaesbach G. Jeune syndrome with tongue lobulation and preaxial polydactyly, and Jeune syndrome with situs inversus and asplenia: compound heterozygosity Jeune–Mohr and Jeune–Ivemark? *Am J Med Genet* 1996; **63**: 74–79.
132. Moalem S, Keating S, Shannon P, *et al.* Broadening the ciliopathy spectrum: motile cilia dyskinesia, and nephronophthisis associated with a previously unreported homozygous mutation in the *INVS/NPHP2* gene. *Am J Med Genet A* 2013; **161A**: 1792–1796.
133. Lee JE, Gleeson JG. A systems-biology approach to understanding the ciliopathy disorders. *Genome Med* 2011; **3**: 59.
134. Shoemark A, Dixon M, Beales PL, *et al.* Bardet Biedl syndrome: motile ciliary phenotype. *Chest* 2015; **147**: 764–770.
135. Moore A, Escudier E, Roger G, *et al.* RPGR is mutated in patients with a complex X linked phenotype combining primary ciliary dyskinesia and retinitis pigmentosa. *J Med Genet* 2006; **43**: 326–333.
136. Budny B, Chen W, Omran H, *et al.* A novel X-linked recessive mental retardation syndrome comprising macrocephaly and ciliary dysfunction is allelic to oral-facial-digital type I syndrome. *Hum Genet* 2006; **120**: 171–178.
137. Barr MM, Sternberg PW. A polycystic kidney-disease gene homologue required for male mating behaviour in *C. elegans*. *Nature* 1999; **401**: 386–389.
138. Pazour GJ, Dickert BL, Vucica Y, *et al.* *Chlamydomonas IFT88* and its mouse homologue, polycystic kidney disease gene *Tg737*, are required for assembly of cilia and flagella. *J Cell Biol* 2000; **151**: 709–718.
139. Bergmann C. ARPKD and early manifestations of ADPKD: the original polycystic kidney disease and phenocopies. *Pediatr Nephrol* 2015; **30**: 15–30.
140. Wolf MT, Hildebrandt F. Nephronophthisis. *Pediatr Nephrol* 2011; **26**: 181–194.
141. Khan SA, Muhammad N, Khan MA, *et al.* Genetics of human Bardet–Biedl syndrome, an update. *Clin Genet* 2016; **90**: 3–15.
142. Romani M, Micalizzi A, Valente EM. Joubert syndrome: congenital cerebellar ataxia with the molar tooth. *Lancet Neurol* 2013; **12**: 894–905.
143. Barker AR, Thomas R, Dawe HR. Meckel–Gruber syndrome and the role of primary cilia in kidney, skeleton, and central nervous system development. *Organogenesis* 2014; **10**: 96–107.
144. Arts HH, Knoers NV. Current insights into renal ciliopathies: what can genetics teach us? *Pediatr Nephrol* 2012; **28**: 863–874.
145. Franco B, Thauvin-Robinet C. Update on oral-facial-digital syndromes (OFDS). *Cilia* 2016; **5**: 12.
146. Lehman AM, Eydoux P, Doherty D, *et al.* Co-occurrence of Joubert syndrome and Jeune asphyxiating thoracic dystrophy. *Am J Med Genet A* 2010; **152A**: 1411–1419.
147. Malicdan MC, Vilboux T, Stephen J, *et al.* Mutations in human homologue of chicken *talpid3* gene (*KIAA0586*) cause a hybrid ciliopathy with overlapping features of Jeune and Joubert syndromes. *J Med Genet* 2015; **52**: 830–839.
148. Tuz K, Bachmann-Gagescu R, O'Day DR, *et al.* Mutations in *CSPP1* cause primary cilia abnormalities and Joubert syndrome with or without Jeune asphyxiating thoracic dystrophy. *Am J Hum Genet* 2014; **94**: 62–72.
149. Poretti A, Vitiello G, Hennekam RC, *et al.* Delineation and diagnostic criteria of oral-facial-digital syndrome type VI. *Orphanet J Rare Dis* 2012; **7**: 4.
150. Thomas S, Legendre M, Saunier S, *et al.* *TCTN3* mutations cause Mohr–Majewski syndrome. *Am J Hum Genet* 2012; **91**: 372–378.
151. Alazami AM, Alshammari MJ, Salih MA, *et al.* Molecular characterization of Joubert syndrome in Saudi Arabia. *Hum Mutat* 2012; **33**: 1423–1428.
152. Yuan X, Serra RA, Yang S. Function and regulation of primary cilia and intraflagellar transport proteins in the skeleton. *Ann N Y Acad Sci* 2015; **1335**: 78–99.
153. Wei Q, Zhang Y, Li Y, *et al.* The BBSome controls IFT assembly and turnaround in cilia. *Nature Cell Biol* 2012; **14**: 950–957.
154. Czarnecki PG, Shah JV. The ciliary transition zone: from morphology and molecules to medicine. *Trends Cell Biol* 2012; **22**: 201–210.
155. Lee J, Chung YD. Ciliary subcompartments: how are they established and what are their functions? *BMB Rep* 2015; **48**: 380–387.
156. Szymanska K, Johnson CA. The transition zone: an essential functional compartment of cilia. *Cilia* 2012; **1**: 10.
157. Li C, Jensen VL, Park K, *et al.* MKS5 and CEP290 dependent assembly pathway of the ciliary transition zone. *PLoS Biol* 2016; **14**: e1002416.
158. Knopp C, Rudnik-Schoneborn S, Eggermann T, *et al.* Syndromic ciliopathies: from single gene to multi-gene analysis by SNP arrays and next generation sequencing. *Mol Cell Probes* 2015; **29**: 299–307.
159. Brancati F, Iannicelli M, Travaglini L, *et al.* *MKS3/TMEM67* mutations are a major cause of COACH syndrome, a Joubert syndrome related disorder with liver involvement. *Hum Mutat* 2009; **30**: E432–442.
160. Otto EA, Tory K, Attanasio M, *et al.* Hypomorphic mutations in meckelin (*MKS3/TMEM67*) cause nephronophthisis with liver fibrosis (NPHP11). *J Med Genet* 2009; **46**: 663–670.
161. Doherty D, Parisi MA, Finn LS, *et al.* Mutations in 3 genes (*MKS3*, *CC2D2A* and *RPGRIP1L*) cause COACH syndrome (Joubert syndrome with congenital hepatic fibrosis). *J Med Genet* 2010; **47**: 8–21.
162. Romani M, Mancini F, Micalizzi A, *et al.* Oral-facial-digital syndrome type VI: is *C5orf42* really the major gene? *Hum Genet* 2015; **134**: 123–126.
163. Lopez E, Thauvin-Robinet C, Reversade B, *et al.* *C5orf42* is the major gene responsible for OFD syndrome type VI. *Hum Genet* 2014; **133**: 367–377.
164. Coppieters F, Lefever S, Leroy BP, *et al.* CEP290, a gene with many faces: mutation overview and presentation of CEP290base. *Hum Mutat* 2010; **31**: 1097–1108.
165. Bachmann-Gagescu R, Phelps IG, Dempsey JC, *et al.* *KIAA0586* is mutated in Joubert syndrome. *Hum Mutat* 2015; **36**: 831–835.
166. Roosing S, Hofree M, Kim S, *et al.* Functional genome-wide siRNA screen identifies *KIAA0586* as mutated in Joubert syndrome. *Elife* 2015; **4**: e06602.

167. Stephen LA, Tawamie H, Davis GM, *et al.* TALPID3 controls centrosome and cell polarity and the human ortholog *KIAA0586* is mutated in Joubert syndrome (*JBTS23*). *Elife* 2015; **4**: e08077.
168. Iannicelli M, Brancati F, Mougou-Zerelli S, *et al.* Novel *TMEM67* mutations and genotype–phenotype correlates in meckelin-related ciliopathies. *Hum Mutat* 2010; **31**: E1319–E1331.
169. Leitch CC, Zaghoul NA, Davis EE, *et al.* Hypomorphic mutations in syndromic encephalocele genes are associated with Bardet–Biedl syndrome. *Nature Genet* 2008; **40**: 443–448.
170. Castori M, Valente EM, Donati MA, *et al.* *NPHP1* gene deletion is a rare cause of Joubert syndrome related disorders. *J Med Genet* 2005; **42**: e9.
171. Parisi MA, Bennett CL, Eckert ML, *et al.* The *NPHP1* gene deletion associated with juvenile nephronophthisis is present in a subset of individuals with Joubert syndrome. *Am J Hum Genet* 2004; **75**: 82–91.
172. Soliman NA, Hildebrandt F, Otto EA, *et al.* Clinical characterization and *NPHP1* mutations in nephronophthisis and associated ciliopathies: a single center experience. *Saudi J Kidney Dis Transpl* 2012; **23**: 1090–1098.
173. Zaki MS, Sattar S, Massoudi RA, *et al.* Co-occurrence of distinct ciliopathy diseases in single families suggests genetic modifiers. *Am J Med Genet A* 2011; **155A**: 3042–3049.
174. Badano JL, Leitch CC, Ansley SJ, *et al.* Dissection of epistasis in oligogenic Bardet–Biedl syndrome. *Nature* 2006; **439**: 326–330.
175. Lindstrand A, Frangakis S, Carvalho CM, *et al.* Copy-number variation contributes to the mutational load of Bardet–Biedl syndrome. *Am J Hum Genet* 2016; **99**: 318–336.
176. Tory K, Lacoste T, Burglen L, *et al.* High *NPHP1* and *NPHP6* mutation rate in patients with Joubert syndrome and nephronophthisis: potential epistatic effect of *NPHP6* and *AH11* mutations in patients with *NPHP1* mutations. *J Am Soc Nephrol* 2007; **18**: 1566–1575.
177. Khanna H, Davis EE, Murga-Zamalloa CA, *et al.* A common allele in *RPGRIP1L* is a modifier of retinal degeneration in ciliopathies. *Nature Genet* 2009; **41**: 739–745.
178. Ece Solmaz A, Onay H, Atik T, *et al.* Targeted multi-gene panel testing for the diagnosis of Bardet Biedl syndrome: identification of nine novel mutations across *BBS1*, *BBS2*, *BBS4*, *BBS7*, *BBS9*, *BBS10* genes. *Eur J Med Genet* 2015; **58**: 689–694.
179. Redin C, Le Gras S, Mhamdi O, *et al.* Targeted high-throughput sequencing for diagnosis of genetically heterogeneous diseases: efficient mutation detection in Bardet–Biedl and Alström syndromes. *J Med Genet* 2012; **49**: 502–512.
180. Shaheen R, Faqeih E, Alshammari MJ, *et al.* Genomic analysis of Meckel–Gruber syndrome in Arabs reveals marked genetic heterogeneity and novel candidate genes. *Eur J Hum Genet* 2013; **21**: 762–768.
181. Szymanska K, Berry I, Logan CV, *et al.* Founder mutations and genotype–phenotype correlations in Meckel–Gruber syndrome and associated ciliopathies. *Cilia* 2012; **1**: 18.
182. Schmidts M. Clinical genetics and pathobiology of ciliary chondrodysplasias. *J Pediatr Genet* 2014; **3**: 46–94.
183. Schueler M, Halbritter J, Phelps IG, *et al.* Large-scale targeted sequencing comparison highlights extreme genetic heterogeneity in nephronophthisis-related ciliopathies. *J Med Genet* 2016; **53**: 208–214.
184. Halbritter J, Porath JD, Diaz KA, *et al.* Identification of 99 novel mutations in a worldwide cohort of 1,056 patients with a nephronophthisis-related ciliopathy. *Hum Genet* 2013; **132**: 865–884.
185. Davis SD, Ferkol TW, Rosenfeld M, *et al.* Clinical features of childhood primary ciliary dyskinesia by genotype and ultrastructural phenotype. *Am J Respir Crit Care Med* 2015; **191**: 316–324.
186. Knowles MR, Ostrowski LE, Leigh MW, *et al.* Mutations in *RSPH1* cause primary ciliary dyskinesia with a unique clinical and ciliary phenotype. *Am J Respir Crit Care Med* 2014; **189**: 707–717.
187. Elephant and the blind men. [Accessed 16 September 2016]. Available from: <http://www.jainworld.com/literature/story25.htm>
188. Boldt K, van Reeuwijk J, Lu Q, *et al.* An organelle-specific protein landscape identifies novel diseases and molecular mechanisms. *Nature Commun* 2016; **7**: 11491.
189. Bujakowska KM, Zhang Q, Siemiatkowska AM, *et al.* Mutations in *IFT172* cause isolated retinal degeneration and Bardet–Biedl syndrome. *Hum Mol Genet* 2015; **24**: 230–242.
190. Lindstrand A, Davis EE, Carvalho CM, *et al.* Recurrent CNVs and SNVs at the *NPHP1* locus contribute pathogenic alleles to Bardet–Biedl syndrome. *Am J Hum Genet* 2014; **94**: 745–754.
191. Cortes CR, McInerney-Leo AM, Vogel I, *et al.* Mutations in human *C2CD3* cause skeletal dysplasia and provide new insights into phenotypic and cellular consequences of altered *C2CD3* function. *Sci Rep* 2016; **6**: 24083.
192. Roosing S, Romani M, Isrie M, *et al.* Mutations in *CEP120* cause Joubert syndrome as well as complex ciliopathy phenotypes. *J Med Genet* 2016; **53**: 608–615.
193. Zaghoul NA, Katsanis N. Functional modules, mutational load and human genetic disease. *Trends Genet* 2010; **26**: 168–176.