

# Sudden, unexpected death of a 15-year-old boy due to pancarditis

## A case report and possible etiopathogenesis

Antonio Osculati, MD<sup>a</sup>, Silvia Damiana Visonà, MD<sup>a,\*</sup>, Francesco Ventura, MD<sup>b</sup>, Francesca Castelli, MD<sup>c</sup>, Luisa Andreello, MD, PhD<sup>c</sup>

### Abstract

**Background:** Generally, rheumatic heart disease is, today, sporadic in developed countries, even though it continues to be a major health hazard in the developing ones. It is also a very rare cause of sudden unexpected death. We report a case of a 15-year-old boy who suddenly died at home. Since 3 days he had presented fever and chest pain. The family physician had diagnosed bronchitis and treated the boy with amoxicillin.

**Methods:** Seven hours after death, a forensic autopsy were performed. Before the autopsy, anamnesis and some circumstantial data were collected from the boy's parents. During the autopsy, samples for histological, toxicological and molecular examinations were collected. The samples for the histology (brain, hypophysis, heart and pericardium, lungs, spleen, liver, kidney, adrenal glands) were formalin fixed and paraffin embedded. Each section was stained with Hematoxylin-Eosin. Immunostaining was also performed, with anti-CD 68, anti-CD3, anti-CD 20, anti-myeloperoxidase. Microbiological cultures were performed on cardiac blood, myocardium, pericardial effusion and cerebrospinal fluid samples collected during autopsy. Blood specimens were also processed through PCR, in order to reveal the presence of Enteroviruses, Chickenpox virus, Epstein Barr virus. Also chemical-toxicological examinations for the detection of the main medications and drugs were performed on blood samples.

**Results:** The anamnesis, collected before the autopsy, revealed an acute pharyngitis few weeks before. The autopsy, and the following histological and immunochemical examinations suggested an immunological etiology. The immunohistochemistry, showing a strong positivity of antiCD68 antibodies, integrated with clinical-anamnestic information, leads to hypothesize a rheumatic carditis.

**Conclusion:** In light of this case, at least 3 main messages of great importance for the clinician can be deduced. First, an accurate anamnesis collected by the family physician could have led to the correct interpretation of the objective signs and the administration of an appropriate therapy. Second, a pharyngeal swab should be performed for cases involving sore throat in young children and adolescents, especially in cases involving repeated pharyngitis. Finally, apparently unremarkable findings revealed from objective examinations can be signs of a serious disease. Moreover, in some cases, these diseases can be lethal if they are not properly treated.

**Abbreviations:** CD20 = CD20 antigens: unglycosylated phosphoproteins expressed only on B-cells, CD3 = CD3 antigens, complex of at least 5 membrane-bound polypeptides in mature T-lymphocytes that are noncovalently associated with one another and with the T-cell receptor, CD68 = CD68 antigen, human; macrophage-myeloid associated antigen, PCR = polymerase chain reaction.

**Keywords:** pancarditis, rheumatic carditis, sudden death

Editor: Carlo Torti.

Ethical approval was not necessary in this case because the examinations performed and the samples collected had to be done for forensic purposes, regardless of the study. Therefore, nothing different from the necessary examinations was performed.

The authors have no conflicts of interest to disclose.

<sup>a</sup> Department of Public Health, Experimental and Forensic Medicine, Section of Legal Medicine and Forensic Sciences "Antonio Fornari," University of Pavia, Pavia, <sup>b</sup> Department of Legal and Forensic Medicine, University of Genoa, Genoa, Italy, <sup>c</sup> Medico Legal Service of Canton Ticino, Bellinzona, Switzerland.

\* Correspondence: Silvia Damiana Visonà, Department of Public Health, Experimental and Forensic Medicine, via Forlanini 12, 27100 Pavia, Italy (e-mail: silviadamiana.visona01@universitadipavia.it; visona.silvia@gmail.com).

Copyright © 2016 the Author(s). Published by Wolters Kluwer Health, Inc. All rights reserved.

This is an open access article distributed under the terms of the Creative Commons Attribution-Non Commercial-No Derivatives License 4.0 (CCBY-NC-ND), where it is permissible to download and share the work provided it is properly cited. The work cannot be changed in any way or used commercially.

Medicine (2016) 95:35(e4586)

Received: 2 March 2016 / Received in final form: 22 July 2016 / Accepted: 22 July 2016

<http://dx.doi.org/10.1097/MD.0000000000004586>

## 1. Introduction

Myocarditis is a rare cause of death in infancy and childhood and it is identified histopathologically as inflammation of the heart muscle. Myocarditis can be classified as scant, mild, or marked, depending on the number of inflammatory foci per slide. Myocarditis is also frequently accompanied by myocellular necrosis.<sup>[1]</sup> The etiology of this condition varies and can involve both infectious and noninfectious causes. The infectious causes can include viruses, helminths, or bacteria. Hypersensitivity myocarditis may develop following the administration of drugs, exposure to chemicals such as hydrocarbons, or exposure to physical agents such as radiation.

There have been only a few published reports of carditis-related sudden deaths. One case involved autoimmune carditis<sup>[2]</sup> and another case involved giant cell pancarditis.<sup>[3]</sup> Here, we present an autopsy report for a case involving the sudden and unexpected cardiac death of a 15-year-old boy that was caused by severe pancarditis.

## 2. Case report

A previously healthy 15-year-old boy presented to his family physician with a high fever (up to 39 °C) and chest pain. An

objective examination showed normal blood pressure (120/78 mm Hg) and a mild elevation of heart rate (96 beats/min). Chest auscultation was negative for any pathologic findings. Laboratory investigations showed: C-reactive protein, 36 mg/dL; leukocytes, 14,310/mm<sup>3</sup>; hemoglobin, 16.5 g/dL; and platelets, 257,000/mm<sup>3</sup>. The physician diagnosed acute bronchitis and prescribed antibiotic therapy (amoxicillin/clavulanate 40 mg/kg/day, 3 times a day). The boy was allowed to return home.

After maintaining a persistent fever (~38 °C) at home for 3 days, the boy experienced a generalized tonic-clonic seizure that lasted about 30 to 40 seconds. A few minutes later, the boy collapsed and was lifeless. A forensic autopsy was performed 7 hours later.

The anamnesis that was collected from the boy's parents revealed acute pharyngitis had affected the boy several weeks before, and this condition was not treated nor was it investigated further. In addition, 15 days before his death, the boy had received a vaccination for diphtheria and tetanus toxoids. The family history was negative.

An external examination of the corpse (length 187 cm, weight 98 kg) revealed no obvious abnormalities. An autopsy revealed approximately 350 mL of turbid pericardial effusion and multiple hemorrhagic foci at the internal surface of the pericardium with fibrinous pericarditis. The heart (650 g) exhibited visible alterations that included the presence of many petechiae and several whitish streaks at the epicardium. A generally pale and locally reddish, mottled myocardium was also observed, along with an increase in wall thickness that extended over most of the heart. In particular, the thickness of the anterior wall of the left ventricle was 1.4 cm. The right and left lungs weighed 1075 g and 988 g, respectively. Both lungs exhibited marked congestion and clear ascites were observed (450 cc).

Microscopically, the myocardium contained a florid lymphocytic infiltrate, along with a few scattered multinucleated giant cells and focal areas of necrosis involving the epicardium, myocardium, and endocardium. In the myocardium, epithelioid cells were occasionally observed. The infiltration of inflammatory cells was associated with diffuse cardiomyocyte edema, necrosis, and hemorrhagic foci in all of the specimens examined (e.g., left ventricular wall, right ventricular wall, and septum). Furthermore, the inflammatory infiltrate that was aggregated in foci was

so abundant that it completely subverted the myocardial structure (Fig. 1). Focal thickening of the left and right ventricular endocardium was also associated with the presence of inflammatory cells. The pericardium and epicardium showed similar changes, including edema, necrosis, and hemorrhagic foci.

To characterize the molecular features of the inflammation observed, immunostaining assays were performed to detect monocyte-macrophages, T-lymphocytes, B-lymphocytes, and granulocytes with the following antibodies: monoclonal mouse antihuman CD68 (clone PG-M1) (3), Dako M0876, 1:100 dilution), polyclonal rabbit antihuman CD3 (Dako A0452, 1:70 dilution), monoclonal mouse antihuman CD20 (clone L26, Dako M0755, 1:700 dilution), and polyclonal rabbit antihuman myeloperoxidase (Dako A0398, 1:7000 dilution), respectively.

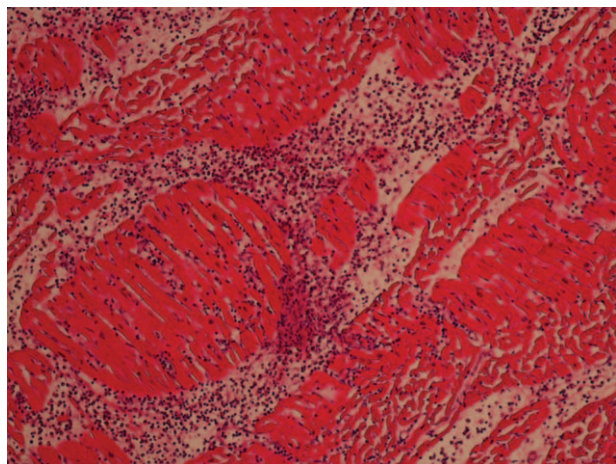
All of the specimens stained were strongly positive for CD68, the main hematopoietic differentiation marker of the monocyte-macrophage lineage. These results suggest a massive macrophage infiltration had occurred. CD68 immunostaining also showed that the positive cells aggregated in foci which resembled very early granulomas (Fig. 2).

Microbiological examinations of cardiac blood, myocardium, pericardial fluid, and cerebrospinal fluid samples that were collected in a sterile fashion during the autopsy were performed. Oral cavity saprophytes were present in all of the cultures. The blood specimens were further examined by PCR (polymerase chain reaction) and all were negative for enteroviruses, varicella zoster virus, and Epstein Barr virus. A chemical-toxicological examination of the blood samples also excluded the presence of any toxic substances.

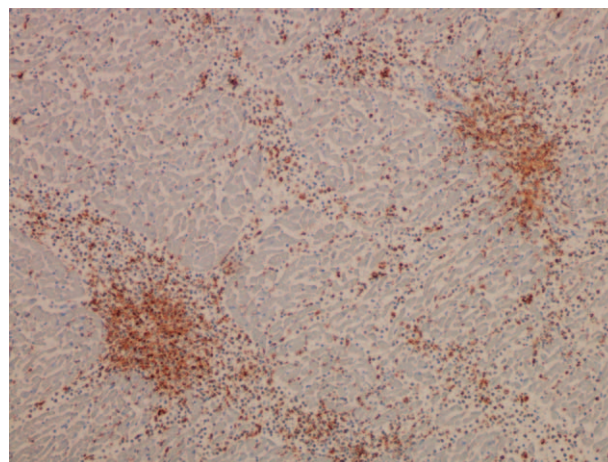
### 3. Discussion

In the present case, the cause of death was identified as massive pancarditis that caused acute heart failure with cardiogenic shock. An arrhythmia induced by a massive infusion of an inflammatory infiltrate into the myocardium may have also contributed to the cause of death.

There was insufficient information to hypothesize about the etiology of the seizure. However, it is hypothesized that a febrile seizure occurred. The anamnesis collected from the parents prior to the autopsy was negative for epilepsy. In addition, the patient was an adolescent, and with this stage being between early



**Figure 1.** Hematoxylin and eosin staining of the myocardium containing an inflammatory infiltrate that subverted the histological structure. Magnification,  $\times 20$ .



**Figure 2.** Anti-CD68 staining of the myocardium containing an inflammatory infiltrate that subverted the histological structure. Magnification,  $\times 20$ .

childhood and adulthood, a diagnosis was more difficult. There were also no signs of encephalitis upon autopsy or in the histological examinations performed on the brain.

With the cause of death established, we further investigated the etiology of the pancarditis. There are several bacterial infections that can cause myocarditis,<sup>[4]</sup> although bacteria-induced myocarditis is much less common than virus-induced myocarditis. In the present case, an integration of the anamnestic-circumstantial data, as well as histopathological and microbiologic culture data, demonstrated that a bacterial etiology could be excluded. It is also well known that cultures of bacterial pancarditis typically reveal a single bacterial species. In the present case, the identification of multiple species of saprophytic bacteria, without any one bacteria being prevalent, suggests that the etiology of the pancarditis was not bacterial. It is possible that the positive cultures arose due to postmortem contamination, probably from postmortal migration of bacteria from the oral cavity.

To address the potential for viral-induced myocarditis, PCR was performed. These data established that the most common viral causes of myocarditis in Western Europe and North America could be excluded (1). Thus, based on the anamnesis, the clinical presentation, and the histological findings, postvaccination myopericarditis and rheumatic carditis were considered. Most cases of postvaccination myopericarditis are self-limited. However, it has been observed that massive myocardial damage as a result of a hypersensitivity reaction to vaccination can occur. Typically, the histological pattern of hypersensitivity myocarditis includes a predominant role for eosinophils.<sup>[5]</sup> In the present case, a massive presence of macrophages and very few eosinophils were observed.

After considering both the clinical and histological data, we decided that the most likely etiology for the present case was rheumatic. In particular, the anamnestic data were crucial: a few weeks prior to death the subject suffered from a sore throat that was not pharmacologically treated. In addition, and significantly, a throat culture was not performed by the family physician. Therefore, the presence of a possible *Streptococcus* infection was not confirmed by a positive throat culture or detection of elevated levels of antistreptococcal antibodies. Furthermore, to our knowledge, it is not feasible to perform these assays postmortem. The histopathologic pattern of the present case, albeit not typical, also suggests rheumatic etiology. Namely, cardiac enlargement, fibrinous pericarditis, and an interstitial inflammatory infiltrate with a predominant presence of macrophages were observed. Aschoff nodules were not detected, although the presence of macrophages that aggregated in foci resembled very early granulomas. A gross examination did not reveal valvular damage, and a histological examination of the valves was not performed prior to suspecting rheumatic disease. Considering all the available data, we hypothesize that the young boy had an untreated streptococcal infection that presented as a sore throat,

and then a few weeks later, he developed acute pancarditis. The typical pattern of rheumatic carditis was not observed because of the exceptional course of carditis that resulted in a massive and rapid inflammation that quickly resulted in death. This presentation, which does not completely fulfill the criteria for a diagnosis of rheumatic fever,<sup>[6,7]</sup> is very unusual both clinically and histopathologically, and therefore, in our opinion, is of particular interest. Furthermore, the findings of the present case also support the observation that the histological pattern of fatal cases of rheumatic carditis, especially those that involve sudden death, differs from the histological pattern of cases involving patients who survive rheumatic carditis and then several years later develop rheumatic heart disease, typically involving the heart valves. The latter group of patients are often the subjects of studies of rheumatic carditis based on the histology of their biopsies or surgically excised valves.

In conclusion, a striking observation of the present case is that a proper anamnesis at the first objective examination by the family physician could have provided vital information that would have substantially changed the course and outcome of the present case. This situation highlights that nonspecific and apparently unremarkable findings from objective examinations can represent signs of serious diseases that can be lethal if not properly treated. Second, we recommend that a pharyngeal swab should be performed for cases involving coughs in young children and adolescents, especially in cases involving repeated pharyngitis. If a *Streptococcus pyogenes* infection is properly diagnosed and treated, it is easily cured and potentially serious consequences can be avoided. As demonstrated in the present case, carditis is a life-threatening manifestation of a streptococcus infection that often begins with very nonspecific and mild clinical signs and symptoms.

## References

- [1] Blauwet LA, Cooper LT. Myocarditis. *Prog Cardiovasc Dis* 2010;52:274–88.
- [2] Duan Y, Liu L, Liu Y, et al. Sudden death due to lupus-induced pancarditis diagnosed after necropsy: a case report. *Forensic Sci Int* 2013;232:e9–11.
- [3] Desai HM, Gayathri AP. Giant cell myocarditis with epicardial and endocardial involvement: an autopsy case report with review of literature. *Indian J Pathol Microbiol* 2013;56:67–8.
- [4] Sagar S, Liu PP, Cooper LT Jr. Myocarditis. *Lancet* 2012;379:738–47.
- [5] Park Y, Ahn SG, Ko A, et al. Hypersensitivity myocarditis confirmed by cardiac magnetic resonance imaging and endomyocardial biopsy. *Korean J Intern Med* 2014;29:236–40.
- [6] Burke RJ, Chang C. Diagnostic criteria of acute rheumatic fever. *Autoimmun Rev* 2014;13:503–7.
- [7] Gewitz MH, Baltimore RS, Tani LY, et al. Revision of the Jones Criteria for the diagnosis of acute rheumatic fever in the era of Doppler echocardiography: a scientific statement from the American Heart Association. *Circulation* 2015;131:1806–18.