



Dynamic Edematous Response of the Human Heart to Myocardial Infarction

Implications for Assessing Myocardial Area at Risk and Salvage

Editorial, see p 1301

BACKGROUND: Clinical protocols aimed to characterize the post-myocardial infarction (MI) heart by cardiac magnetic resonance (CMR) need to be standardized to take account of dynamic biological phenomena evolving early after the index ischemic event. Here, we evaluated the time course of edema reaction in patients with ST-segment-elevation MI by CMR and assessed its implications for myocardium-at-risk (MaR) quantification both in patients and in a large-animal model.

METHODS: A total of 16 patients with anterior ST-segment-elevation MI successfully treated by primary angioplasty and 16 matched controls were prospectively recruited. In total, 94 clinical CMR examinations were performed: patients with ST-segment-elevation MI were serially scanned (within the first 3 hours after reperfusion and at 1, 4, 7, and 40 days), and controls were scanned only once. T2 relaxation time in the myocardium (T2 mapping) and the extent of edema on T2-weighted short-tau triple inversion-recovery (ie, CMR-MaR) were evaluated at all time points. In the experimental study, 20 pigs underwent 40-minute ischemia/reperfusion followed by serial CMR examinations at 120 minutes and 1, 4, and 7 days after reperfusion. Reference MaR was assessed by contrast-multidetector computed tomography during the index coronary occlusion. Generalized linear mixed models were used to take account of repeated measurements.

RESULTS: In humans, T2 relaxation time in the ischemic myocardium declines significantly from early after reperfusion to 24 hours, and then increases up to day 4, reaching a plateau from which it decreases from day 7. Consequently, edema extent measured by T2-weighted short-tau triple inversion-recovery (CMR-MaR) varied with the timing of the CMR examination. These findings were confirmed in the experimental model by showing that only CMR-MaR values for day 4 and day 7 postreperfusion, coinciding with the deferred edema wave, were similar to values measured by reference contrast-multidetector computed tomography.

CONCLUSIONS: Post-MI edema in patients follows a bimodal pattern that affects CMR estimates of MaR. Dynamic changes in post-ST-segment-elevation MI edema highlight the need for standardization of CMR timing to retrospectively delineate MaR and quantify myocardial salvage. According to the present clinical and experimental data, a time window between days 4 and 7 post-MI seems a good compromise solution for standardization. Further studies are needed to study the effect of other factors on these variables.

Rodrigo Fernández-Jiménez, MD*

Manuel Barreiro-Pérez, MD, PhD*

Ana Martín-García, MD, PhD*

Javier Sánchez-González, PhD

Jaume Agüero, MD, PhD

Carlos Galán-Arriola, DVM

Jaime García-Prieto, BSc

Elena Díaz-Pelaez, MD

Pedro Vara, DCS

Irene Martínez, DCS

Ivan Zamorro, DCS

Beatriz Garde, BPharm

Javier Sanz, MD

Valentin Fuster, MD PhD

Pedro L. Sánchez, MD, PhD

Borja Ibanez, MD, PhD

*Drs Fernández-Jiménez, Barreiro-Pérez, and Martín-García contributed equally.

Correspondence to: Borja Ibanez, MD, PhD, Translational Laboratory for Cardiovascular Imaging and Therapy, Centro Nacional de Investigaciones Cardiovasculares Carlos III (CNIC) & Cardiology Department, IIS-Fundación Jiménez Díaz. Melchor Fernández Almagro, 3. 28029, Madrid, Spain, or Pedro L. Sánchez, MD, PhD, Cardiology Department, Hospital Universitario Salamanca-IBSAL, Paseo de San Vicente 58-182, 37007, Salamanca, Spain. E-mail bibanez@cnic.es or pedrosanchez@secardiologia.es

Sources of Funding, see page 1298

Key Words: edema ■ magnetic resonance imaging ■ myocardial infarction ■ translational medical research

© 2017 The Authors. *Circulation* is published on behalf of the American Heart Association, Inc., by Wolters Kluwer Health, Inc. This is an open access article under the terms of the [Creative Commons Attribution Non-Commercial-NoDerivs License](https://creativecommons.org/licenses/by-nc-nd/4.0/), which permits use, distribution, and reproduction in any medium, provided that the original work is properly cited, the use is noncommercial, and no modifications or adaptations are made.

Clinical Perspective

What Is New?

- This work shows for the first time that myocardial edema in the week after ST-segment–elevation myocardial infarction in humans is a bimodal phenomenon.
- An initial wave of edema appears abruptly at reperfusion, but it is significantly attenuated by 24 hours.
- The initial wave of edema is followed by a second (deferred) healing-related wave of edema several days after reperfusion reaching a plateau ≈ 4 to 7 days after myocardial infarction.
- This bimodal edematous response has a major impact on retrospective myocardial area at risk and salvage quantification by cardiac magnetic resonance given that measures of edema are greatly influenced by the timing of imaging.

What Are the Clinical Implications?

- Both cardiac magnetic resonance imaging techniques and timing of postinfarction imaging for assessing myocardial area at risk and myocardial salvage should be standardized to take account of the pathophysiology of the bimodal edematous phenomenon.
- The time frame between day 4 and 7 postinfarction seems a good compromise solution according to clinical and experimental data here presented.
- Our results have important implications for the design and interpretation of clinical trials using edema-sensitive cardiac magnetic resonance protocols to quantify myocardium at risk and myocardial salvage as an end point.

Noninvasive tissue characterization by cardiac magnetic resonance (CMR) after myocardial infarction (MI) offers the possibility to evaluate the impact of interventions designed to preserve cardiac function and predict long-term remodeling.¹ It has been postulated that an intense edematous reaction confined to the posts ischemic region appears early after MI and persists in stable form for at least 1 week.^{2,3} On the basis of this assumption, the use of edema-sensitive T2-CMR sequences to delineate the spatial extent of post-MI edema was rapidly incorporated as an index of the original occluded coronary artery perfusion territory (myocardium at risk, MaR).^{4,5} Quantification of late gadolinium enhancement (LGE) and edema extent (assumed to delineate MaR) in the same imaging session has been extensively used to quantify the amount of salvaged myocardium, a theoretical surrogate of the effect of cardioprotective therapies,^{6,7} thus reducing the required sample size in trials.⁸ Consequently, CMR-based myocardial salvage has been and continues to be used as an end point in multiple clinical and experimental studies.⁹

On the basis of the assumed stable unimodal edematous reaction during the first week after MI, the timing of the end point imaging session in these studies varies considerably. However, recent work in the pig model showed that the post-MI edematous reaction is not stable, and instead follows a bimodal pattern.¹⁰ An initial reperfusion-related wave of edema appears abruptly on reperfusion and dissipates at 24 hours. This is followed by a healing-related deferred wave of edema appearing several days after MI, peaking around postreperfusion day 7.¹¹ This coordinated bimodal edema pattern suggests that CMR-quantified MaR may vary according to the day of imaging, but to date this has not been tested in a controlled manner. Some recent studies evaluated MaR extent in patients according to the timing of post-MI imaging, but these were either retrospective analyses¹² or did not systematically scan patients at the same time points.¹³ Consequently, whether this phenomenon occurs in MI patients is unclear.

This study was designed to address these specific 2 questions: (1) is post-MI edematous reaction bimodal in humans, and (2) does the bimodal edematous reaction affect the CMR-based quantification of MaR and myocardial salvage? We designed a longitudinal clinical study in which patients with ST-segment–elevation MI (STEMI) successfully treated by primary angioplasty were prospectively recruited and CMR performed within the first 3 hours postreperfusion and at 24 hours, 4 days, 7 days, and 40 days. The impact of the dynamic edematous response on post-MI CMR measures of MaR, infarct size (IS), and salvaged myocardium was evaluated in the pig model of reperfused MI by performing reference measures of MaR and a comprehensive serial CMR imaging study.

METHODS

Clinical Study

Design

Hemodynamically stable consecutive patients with a first anterior STEMI and undergoing primary percutaneous coronary intervention were prospectively recruited between February 2015 and November 2015 ad hoc for this study. Patients eligible for enrollment were aged ≥ 18 years, and showed symptoms consistent with STEMI for >90 minutes and ST-segment elevation ≥ 2 mm in ≥ 2 contiguous leads in V_1 through V_5 , with an anticipated time from symptom onset to reperfusion of ≤ 8 hours. Additional mandatory inclusion criteria were evidence of complete occlusion in the proximal or mid portion of the left anterior descending coronary artery (TIMI 0–1 initial flow) and successful primary angioplasty evidenced by appropriate reestablishment of coronary flow in the culprit artery (TIMI-3 flow after angioplasty). Exclusion criteria were Killip class III to IV, persistent systolic blood pressure <100 mm Hg, persistent heart rate <50 bpm or >110 bpm, presence of bifascicular or trifascicular block, evidence of second- or third-degree atrioventricular block, atrial fibrillation, known history of previous MI, pregnancy, active breastfeeding, and the presence

of metallic objects or devices incompatible with MRI. Patients were managed according to current clinical guidelines.^{14,15}

CMR examinations were performed within 3 hours of reperfusion (hyperacute reperfusion) and at 24 hours, 4 days, 7 days, and 40 days after reperfusion (Figure 1A). Normal T2 relaxation times (baseline) were obtained in 16 healthy age- and sex-matched volunteers. The study was approved by the hospital Ethics Committee, and all patients and volunteers gave written informed consent.

CMR Protocol

CMR examinations were conducted with a Philips 1.5-Tesla Achieva whole-body scanner (Philips Healthcare) equipped with a 16-element phased-array cardiac coil. At all time points, the imaging protocol included a standard segmented cine steady-state free-precession sequence to provide high-quality anatomic references; a T2-weighted short-tau triple inversion-recovery (T2W-STIR) sequence to assess the extent of edema and intramyocardial hemorrhage (IMH); and a T2-gradient-spin-echo mapping sequence to provide precise myocardial T2 relaxation time properties.¹⁶ On day 7 and day 40 CMR, LGE imaging was performed to assess infarct size and microvascular obstruction (MVO), using a T1-weighted inversion recovery turbo field echo sequence acquired 10 to 15 minutes after intravenous administration of 0.20 mmol gadobutrol contrast agent per kg body weight.

CMR Analysis

CMR images were analyzed using dedicated software (MR Extended Work Space 2.6, Philips Healthcare; and

QMassMR 7.6, Medis) by 2 observers experienced in CMR analysis and blinded to time-point allocation and patient identification. T2 maps were analyzed by placing the region of interest at the transmural ischemic, infarcted (with or without including areas suggestive of IMH), salvage, and transmural remote areas in a midapical ventricular short-axis slice corresponding to the same anatomic level in all acquisitions to track T2 relaxation time changes over time.^{16,17} The extent of edema, expressed as a percentage of left ventricular (LV) mass (CMR-MaR), was initially identified by using the full width at half-maximum with subsequent manual correction and visual border delineation after tracing the endocardial and epicardial contours of T2W-STIR short-axis images.¹⁸ Hypointense areas within the edematous zone, corresponding to IMH, were included within the edematous region.^{19,20} In addition, IMH area was calculated by manual delineation of the hypointense areas on T2W images¹⁹ and expressed as a percentage of LV mass.

IS, expressed as a percentage of LV mass, was defined according to the extent of LGE after manually tracing the endocardial and epicardial contours on T1-weighted inversion recovery turbo field echo short-axis images. Abnormal areas were defined using the full width at half-maximum, with manual correction if needed. Hypointense black areas within the necrotic zone, corresponding to MVO, were included within the necrotic area.^{19,20} In addition, the size of the MVO area was calculated by manual delineation of

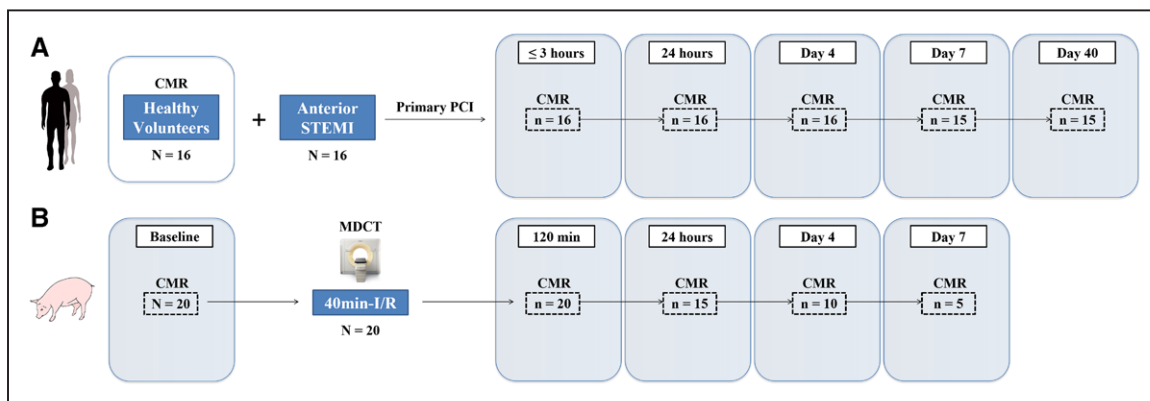


Figure 1. Study design.

A, Clinical study design. Twenty-two consecutive anterior patients with STEMI fulfilling the inclusion criteria were assessed for eligibility: 3 patients refused to participate; 1 patient experienced anxiety and a claustrophobic reaction requiring premature termination of the first CMR; 1 patient felt sick with vomiting before the first CMR, which could not be performed; and 1 patient had a failed CMR study because of frequent episodes of premature ventricular contraction and nonsustained ventricular tachycardia during the scan. The clinical study population thus included 16 consecutive hemodynamically stable patients with anterior STEMI reperfused by primary percutaneous coronary intervention. CMR examinations including T2-weighted short-tau triple inversion-recovery and T2-gradient-spin-echo mapping sequences were per protocol scheduled at the following times after reperfusion: within the first 3 hours and at 24 hours, 4 days, 7 days, and 40 days. To take account of baseline values, myocardial T2 relaxation time was measured in 16 healthy age- and sex-matched volunteers. **B**, Experimental study design. The study population comprised 20 pigs weighing 30 to 40 kg that underwent closed-chest 40 minutes reperfused acute anterior myocardial infarction. These pigs were euthanized at 120 minutes (n=5), 24 hours (n=5), 4 days (n=5), and 7 days (n=5) after myocardial infarction. Arterial enhanced multidetector computed tomography was performed during coronary occlusion in all pigs as a reference standard for measuring the myocardial area at risk. CMR scans, including T2-weighted short-tau triple inversion-recovery, T2 mapping, and late gadolinium enhancement imaging, were performed at every follow-up stage until euthanization. CMR indicates cardiac magnetic resonance; I/R, ischemia/reperfusion; MDCT, multidetector computed tomography; PCI, percutaneous coronary intervention; and STEMI, ST-segment–elevation myocardial infarction.

the hypointense areas on LGE images¹⁹ and expressed as a percentage of LV mass.

Detailed information about CMR imaging protocol and parameters, and imaging analysis is presented in the [online-only Data Supplement Methods](#).

Experimental Study

Design and MI Procedure

The study was approved by Institutional and Regional Animal Research Committees.

To study the impact of the dynamic edematous response on post-MI CMR time profile measures of MaR, IS, and salvaged myocardium, a group of 20 pigs underwent closed-chest reperfused MI by the percutaneous catheter-based technique, with 40-minute angioplasty-balloon occlusion of the mid left anterior descending coronary artery, followed by balloon deflation and reestablishment of blood flow¹⁰ (Figure 1B). These pigs were euthanized at 120 minutes (n=5), 24 hours (n=5), 4 days (n=5), or 7 days (n=5) after ischemia/reperfusion (I/R). In all pigs, arterial enhanced multidetector computed tomography (MDCT) was performed during the index coronary occlusion, between minute 10 and minute 20 of ischemia, to delineate the reference MaR (hypoperfused region during coronary occlusion).²¹ Comprehensive CMR scans were performed at every follow-up stage until euthanization (ie, animals euthanized on day 7 underwent baseline, 120 minutes, 24 hours, day4, and day7 CMR examinations).

Full methods can be found in the [online-only Data Supplement Appendix](#).

Arterial Enhanced MDCT Protocol and Analysis

All MDCT studies were performed on a 64-slice CT scanner (Brilliance CT 64, Philips Healthcare) after intravenous administration of 60 mL of 400 mg/mL iomeprol (Iomeron 400, Bracco Imaging).²¹ MDCT images were analyzed using dedicated software (MR Extended Work Space 2.6, Philips Healthcare). MaR and remote areas were visually identified based on contrast enhancement differences, manually delineated, and expressed as a percentage of LV area.

CMR Protocol and Analysis

CMR examinations were conducted with a Philips 3-Tesla Achieva Tx whole body scanner (Philips Healthcare) equipped with a 32-element phased-array cardiac coil. The imaging protocol included an steady-state free-precession sequence to provide high-quality anatomic references, and assessment of LV mass and wall thickness; a T2W-STIR sequence to assess the extent of edema and IMH; a T2-gradient-spin-echo mapping sequence^{10,16}; and a T1-weighted inversion recovery turbo field echo sequence to assess IS and MVO. CMR images were similarly analyzed using dedicated software (MR Extended Work Space 2.6, Philips Healthcare; and QMassMR 7.6, Medis) by 2 observers experienced in CMR analysis and blinded to group allocation.

Detailed information about MDCT and CMR imaging protocol and parameters, and imaging analysis, can be found in the [online-only Data Supplement Methods](#).

Statistical Analysis

In the clinical study, the sample size calculation to detect a difference in T2 relaxation time in the ischemic

myocardium between examination time points after STEMI was prespecified by using the user-written command *nsize* (Stata 12.0). A sample size of 16 patients was determined on the basis of our previous experimental results,¹⁰ a 95% confidence level, a statistical power of 80%, a conservative significant mean difference to detect of 15 ms in T2, a SD of 12, and multiple pairwise comparisons between time points.

Normal distribution of each data subset was checked by using graphical methods and a Shapiro-Wilk test. The Leven test was performed to check the homogeneity of variances. For quantitative variables, data are expressed as mean±SD. For categorical variables, data are expressed as frequencies and percentages. To take account of repeated measures, generalized linear mixed models were conducted to analyze the time course of T2 relaxation time, CMR-MaR, IMH, MVO, IS, and salvaged myocardium. Models evaluating the time course of T2 or CMR-MaR were further adjusted by extent of hemorrhage, including the amount of IMH expressed as a percentage of the LV as a covariate, given that this parameter is known to affect T2. Given the hypothesis-driven nature of the study, comparisons among different time points were planned in advance. Nonetheless, *P* value was adjusted for multiple comparisons by using the Hochberg method.

All statistical analyses were performed with Stata v12.0 (StataCorp).

RESULTS

Clinical Study

General Characteristics of the Population

Clinical characteristics of the study population are summarized in Table 1. Serial CMR was performed with informed consent in 16 consecutive patients with anterior STEMI fulfilling the inclusion criteria (mean age 58.8±14.5 years, 14 [87.5%] male) and successfully treated by primary percutaneous coronary intervention. A total of 94 CMR examinations were performed: the 16 healthy volunteers were scanned once, and the 16 patients with STEMI were scanned at 2.2±0.5 hours, 24.8±1.8 hours, 3.8±0.4 days, 6.8±0.6 days, and 41.7±4.3 days after reperfusion. In all patients, the first CMR scan was performed within the first 3 hours (90–180 minutes) after primary percutaneous coronary intervention. The timing for the initial CMR scan (around the peak of reperfusion-related wave of edema) was identified before in a dedicated separate group of 5 pigs undergoing serial CMR scans every 20 minutes during the 6 hours following reperfusion (see [online-only Data Supplement Methods and Results](#), and [online-only Data Supplement Figures I and II](#)). Evaluable T2-mapping and T2W-STIR data were available in 100% of CMR scans performed. Information on vital status was available for all participants.

Table 1. Baseline Patient Characteristics

Characteristic	All Patients (n=16)
Age, y	58.8±14.5
Male sex	14 (87.5)
Body mass index, kg/m ²	27.1±2.9
Hypertension	9 (56.3)
Smoking	
Current smoker	9 (56.3)
Ex-smoker (0–10 y before)	4 (25.0)
Dyslipidemia	10 (62.5)
Diabetes mellitus	3 (18.8)
Ischemia duration, min*	185±115
Killip class at recruitment	
I	11 (68.7)
II	5 (31.3)
Infarct artery lesion location	
Proximal left anterior descending coronary artery	16 (100.0)
Mid left anterior descending coronary artery	0 (0.0)
Treatment at the time of primary percutaneous intervention	
Heparin	16 (100.0)
Oral antiplatelet	
Aspirin	14 (87.5)
Clopidogrel	8 (50.0)
Prasugrel	5 (31.3)
Ticagrelor	4 (25.0)
Thrombus aspiration	9 (56.3)
Glycoprotein IIb/IIIa during primary percutaneous intervention	9 (56.3)

Data are presented as mean±SD or n (%).

*Mean time from symptom onset to reperfusion.

Edema Time Course in Patients With STEMI

T2 Relaxation Time

Mean myocardial T2 relaxation times in the 16 healthy volunteers (mean age 59.3±17.7 years, 12 [75%] male) were 53.1±4.1 ms and 51.1±4.5 ms for the midapical anteroseptal and posterolateral LV walls, respectively. In comparison with these values, hyperacute reperfusion in patients with STEMI (≤3 hours) was associated with significantly longer T2 relaxation times in the ischemic area (Figure 2A and 2B). T2 relaxation time in patients with STEMI showed a systematic and significant decrease at 24 hours post-MI. This was followed by a rebound increase, with T2 relaxation times on day 4 postreperfusion reaching values similar to those observed during early reperfusion. Thereafter, T2 relaxation time progressively decreased, with values on day 40 similar to those observed at 24 hours. Similar results were obtained after adjusting T2 for the amount of IMH

(online-only Data Supplement Table I). During the first week after MI, T2 relaxation time in the remote myocardium showed a linear trend toward a progressive increase, albeit slight. T2 relaxation times in the ischemic and remote myocardium at different postreperfusion time points are summarized in Table 2. T2 relaxation time was longer in the transmural ischemic myocardium than in the remote myocardium at all time points evaluated. However, the differences observed at 24 hours and 40 days, albeit statistically significant, were of small magnitude and resulted in a wide overlapping of myocardial T2 values within ischemic and remote areas (Figure 2C). Individual trajectories for T2 relaxation time in the ischemic myocardium of STEMI patients are shown in online-only Data Supplement Figure III.

Extent of Edema (CMR-MaR)

The edematous area delineated by T2W-STIR sequences was similar in CMR scans performed at hyperacute reperfusion (≤3 hours) and on day 4 and day 7 (Figure 3). Conversely, the area of edema was significantly smaller at 24 hours postreperfusion. On day 40 post-MI, the area of edema was comparable to that seen at 24 hours. This time-course pattern for edema resembles that observed for T2 relaxation time, and similar results were obtained after adjusting the area of edema for the amount of IMH evaluated by T2W-STIR (online-only Data Supplement Table II). Edematous area at different postreperfusion time points is summarized in Table 2. Individual patient trajectories for area of edema measurements are shown in online-only Data Supplement Figure IV.

Experimental Study

Dynamics of CMR-MaR After Reperfused MI in Comparison With the Reference Standard

CMR-measured MaR values at different times after reperfusion in pigs are summarized in Table 3 and online-only Data Supplement Table III. Mean MaR as assessed by the MDCT reference method was 30.5±5.0% of the LV. Because of the initial swelling of the ischemic myocardium (online-only Data Supplement Table IV), CMR-measured MaR as delineated by T2W-STIR sequence was significantly higher than MaR measured by MDCT at early reperfusion (Figure 4A and 4B). Coinciding with the dissipation of the first edema wave,¹⁰ MaR was strikingly underestimated by CMR at 24 hours postreperfusion. Conversely, CMR-estimated MaR values for day 4 and day 7 postreperfusion, coinciding with the deferred edema wave,¹⁰ were similar to values measured by MDCT (ie, no overestimation or underestimation). The dynamics of CMR-measured MaR resembled the time course for myocardial T2 relaxation time and water content in the ischemic area.¹⁰

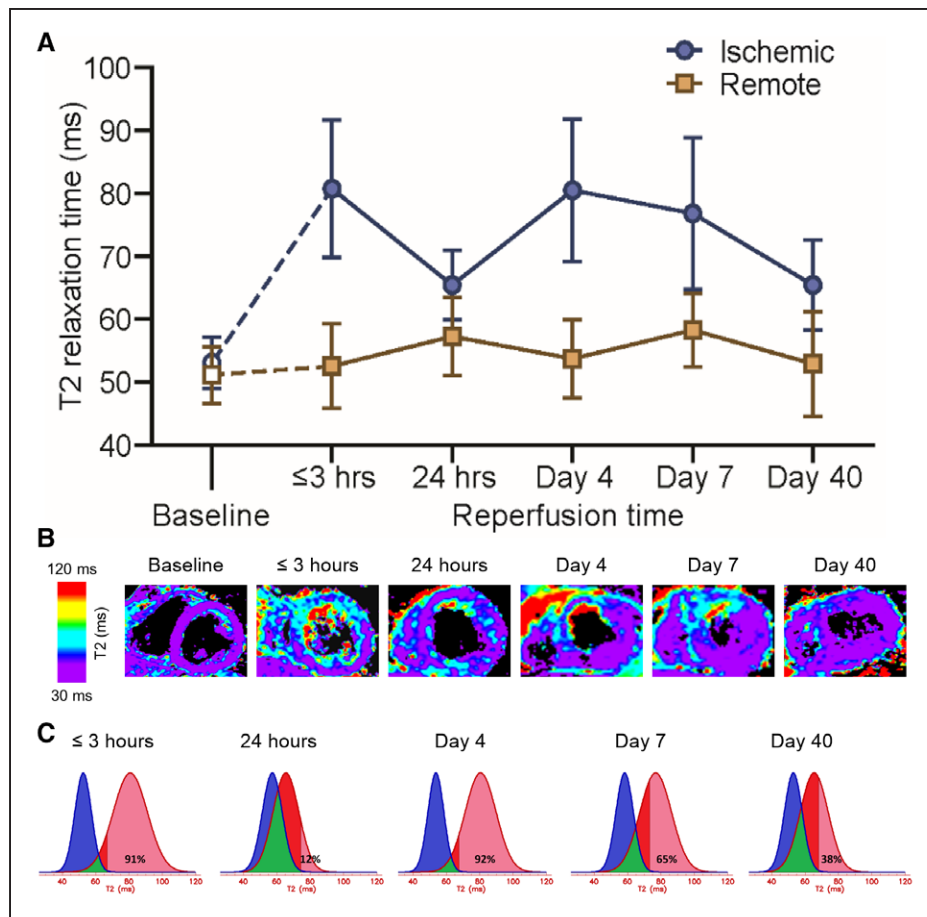


Figure 2. Temporal evolution of myocardial T2 relaxation time in patients with ST-segment-elevation myocardial infarction.

A, Time course of absolute T2 relaxation time (ms) in the ischemic and remote myocardium in patients with ST-segment-elevation myocardial infarction. Data are means and SD. For baseline values, myocardial T2 relaxation time was measured in 16 healthy age- and sex-matched volunteers. Dashed lines represent hypothetical mean trajectories for T2 from baseline to the hyperacute postreperfusion phase (≤ 3 hours). At all time points after reperfusion, T2 relaxation time in the ischemic myocardium of patients differed significantly from baseline values in healthy volunteers. It is noteworthy that cardiac magnetic resonance T2 mapping revealed similar T2 values at ≤ 3 hours and on day 4 and day 7 postreperfusion; in contrast, T2 relaxation time was significantly lower at 24 hours and on day 40 post-MI. **B**, Representative images from a patient with anterior ST-segment-elevation myocardial infarction who underwent serial cardiac magnetic resonance T2-mapping examinations at 150 minutes, 26 hours, 4 days, 7 days, and 44 days after reperfusion. For baseline cardiac magnetic resonance T2 mapping, an image from a healthy volunteer is shown. All T2 maps were scaled between 30 and 120 ms. **C**, T2 values distribution in the ischemic and remote myocardium in patients with ST-segment-elevation myocardial infarction at different time points. Mean and SD from all individual regions of interest placed in these areas at all time points were analyzed. Blue and red colors represent distribution of T2 values in the remote and ischemic myocardium, respectively. Green color represents the overlapping of T2 values, ie, pixels from both areas having the same T2. The percentages shown in each panel represent the percent of the ischemic myocardium region of interest with T2 > 2 SDs from the mean T2 in the remote myocardium (pink). Despite that the mean T2 relaxation time in ischemic myocardium at all time points was longer than mean T2 in the remote, overlapping was patent and widest at the 24-hour time point.

Dynamics of CMR-Measured IS, Myocardial Salvage, IMH, and MVO After Reperfused MI

CMR-measured IS and myocardial salvage in pigs are summarized in Table 3 and [online-only Data Supplement Table III](#). A progressive reduction of IS was observed during the first week after I/R (Figure 4C and 4D). Matching the temporal variations in CMR-MaR, CMR-estimated myocardial salvage quantification [(MaR-IS)/MaR, %]

also changed dynamically during the first week after I/R ([online-only Data Supplement Figure V](#)).

CMR-estimated IMH and MVO are summarized in [online-only Data Supplement Table V](#). IMH was apparent at 24 hours and peaked on day 4 post-I/R; in contrast, MVO was apparent at 120 minutes after reperfusion, peaking on day 1 post-I/R and progressively decreasing thereafter. The dynamics of CMR-estimated

IMH are consistent with histologically evaluated IMH in the same model previously reported.¹¹

DISCUSSION

First Demonstration of the Postinfarction Bimodal Edema Reaction in the Human Heart

This is the first comprehensive evaluation of patients with STEMI by serial CMR to include the hyperacute postreperfusion period (the first 3 hours). CMR scans timing was designed as per the protocol of our previous experimental studies, in which we demonstrated the existence of bimodal post-MI edema in pigs.^{10,11}

The main finding of the present clinical study is that, contrary to the accepted view, myocardial edema in the ischemic area after MI in humans is not stable, but rather follows a systematic bimodal pattern. An initial wave of edema appears abruptly very early after reperfusion, but it is significantly attenuated by 24 hours. This is followed by a second (deferred) wave of edema several days after reperfusion reaching a plateau \approx 4 to 7 days after MI.

The Initial Wave of Edema

To select the optimal timing for the first CMR scan in STEMI patients, we first analyzed the dynamics of the initial wave of edema in a series of 5 pigs; serial CMR scans were performed every 20 minutes until the reperfusion-related edema wave faded. It is interesting to note that this initial wave of edema peaked very early, being significantly attenuated within a few hours after MI: at 180 minutes after reperfusion, the edema had declined by \approx 50% from its maximum. In agreement with CMR data, quantification of myocardial water content and histological analysis at 6 hours after MI revealed partial resolution of the massive interstitial edema seen earlier after reperfusion (see [online-only Data Supplement Results](#)).¹¹ On the basis of these results in pigs, we decided to perform the first CMR scan in patients within a narrow 3-hour time window after primary percutaneous coronary intervention to be able to detect the noon of the initial wave of edema.

Controversy on the Bimodal Postinfarction Edema Occurrence in Humans

The recent demonstration of bimodal edema in the postischemic myocardium in pigs^{10,11} has generated intense discussion in the cardiac imaging field.^{6,22–28} Whether this phenomenon occurs in humans has been explored in 2 recent studies. Carrick and colleagues¹³ performed a longitudinal assessment of IMH and edema in 30 patients with STEMI, concluding that “myocardial edema has a unimodal time course.” This popu-

lation was more heterogeneous than the population examined here: 20% had an open artery on angiography (TIMI coronary flow grade 2–3) and only 30% had an anterior MI, whereas all patients in our study had an anterior infarction with an occluded artery on angiography. These factors might affect edema dynamics and visualization.^{11,18} In addition, patients in the Carrick et al study underwent 3 CMR examinations within the first 10 days after MI, at 8.6 ± 3.1 hours, 2.9 ± 1.5 days, and 9.6 ± 2.3 days.¹³ It is important to note that the first of these examinations was performed between 4 and 12 hours after reperfusion, which, according to the experimental data we present here, is after the dissipation of the first edema wave. Indeed, the T2 values in the infarcted zone reported for the first CMR examination in Carrick et al are similar to those observed in the second scan in our clinical study, performed 24 hours after MI.

In the second report, Nordlund et al¹² retrospectively analyzed pooled data from 3 studies assessing the MaR by qualitative CMR, concluding that no bimodal edema pattern was apparent. However, most patients in the evaluated studies underwent a single CMR scan at disparate times to from each other, and there were no systematic serial examinations. It is important to note that no CMR scans were performed on day 0, and very few were performed on day 1 after MI. Moreover, no quantitative parametric T2 mapping was performed, despite this technique being demonstrated to improve detection and quantification of myocardial edema.²⁹ Unlike these recent reports, our study was specifically designed to provide insight into the existence of bimodal edema in patients with MI by mimicking time points and CMR sequences performed in the previous experimental studies.^{10,11}

Implications of the Bimodal Edema Phenomenon for Quantifying MaR and Salvage

On the basis of an assumed stable edematous reaction lasting for several days after MI and despite recent controversy,^{30,31} T2-CMR sequences have been widely used to retrospectively quantify the MaR.^{6,29} In the present clinical study, we show that T2 relaxation time in the ischemic region changes systematically with the post-MI timing of the examination. In parallel, we confirmed significant variation in the extent of the MaR as measured by T2W-STIR. Consistent with the drop in T2 relaxation time at 1 day post-MI, T2W-estimated MaR at this time point was significantly lower than values obtained before and subsequently.

We experimentally confirmed clinical findings by accomplishing a comprehensive CMR serial imaging study in 20 pigs subjected to reperfused MI. Remarkably, we included prereperfusion MDCT imaging as a reference for the assessment of MaR,²¹ which otherwise we con-

Table 2. CMR Data of Patients

	Reperfusion Time				
	≤3 h	24 h	4 days	7 days	40 days
T2 transmural ischemic, ms	80.8 (10.9)	65.4 (5.5)	80.5 (11.3)	76.8 (12.1)	65.4 (7.2)
T2 transmural remote, ms	52.5 (6.7)	57.2 (6.2)	53.7 (6.2)	58.3 (5.9)	52.9 (8.3)
T2 infarct incl. hypointense core, ms	80.5 (16.4)	63.0 (9.0)	81.5 (15.3)	76.3 (16.6)	65.2 (8.4)
T2 infarct excl. hypointense core, ms	87.2 (15.1)	65.2 (8.8)	86.0 (16.6)	81.3 (16.9)	66.4 (7.0)
T2 salvaged, ms	70.2 (9.7)	64.4 (8.3)	78.5 (14.9)	68.9 (9.5)	62.3 (8.2)
Myocardial area at risk, % of left ventricle	39.9 (13.0)	21.8 (12.2)	42.8 (11.5)	42.9 (13.0)	20.1 (11.5)
Intramycardial hemorrhage, % of left ventricle	0.6 (0.5)	1.1 (0.6)	1.7 (1.4)	1.7 (1.8)	0.7 (0.6)
Infarct size, % of left ventricle	–	–	–	30.3 (14.6)	21.9 (11.9)
Microvascular obstruction, % of left ventricle	–	–	–	2.7 (2.4)	0.9 (0.8)

Data are presented as mean (SD). T2 maps were analyzed by placing regions of interests at the transmural ischemic, infarcted (with or without including areas suggestive of intramycardial hemorrhage), salvage, and transmural remote areas in a midapical ventricular short-axis slice corresponding to the same anatomic level in all acquisitions to track T2 relaxation time changes over time. The different myocardial states were initially defined by the localization relative to late gadolinium enhancement.¹⁷ One patient died between day 4 and day 7 cardiac magnetic resonance, and 1 patient was unable to undergo late gadolinium enhancement imaging because of severe renal impairment; therefore, T2 information from the different myocardial states within the ischemic region was obtained from 14 of 16 patients.

T2 relaxation time was longer in the transmural ischemic myocardium than in the remote myocardium at all time points evaluated (≤3 hour, day 1, day 4, day 7, and day 40 after reperfusion). At the 24-hour time point, T2 values were 65.4±5.5 ms and 57.2±6.2 ms in the ischemic and remote myocardium, respectively ($P<0.01$). Similar results (even of greater magnitude) were shown when comparing T2 in the ischemic and remote myocardium at day 40 (65.4±7.2 ms versus 52.9±8.3 ms, $P<0.01$). However, T2 relaxation time in the ischemic myocardium showed significant variations across time: T2 at 24 hours was statistically shorter than at ≤3 hours (65.4±5.5 ms versus 80.8±10.9 ms, $P<0.01$), than at day 4 (65.4±5.5 ms versus 80.5±11.3 ms, $P<0.01$), and than at day 7 (65.4±5.5 ms versus 76.8±12.1 ms, $P<0.01$). In contrast, T2 in the ischemic myocardium at 24 hours did not differ from T2 at day 40 (65.4±5.5 ms versus 65.4±7.2 ms, $P=0.99$).

CMR indicates cardiac magnetic resonance.

considered unethical to perform in patients with STEMI. In the experimental study, our results show that, because of the bimodal pattern of post-I/R edema formation, the extent of MaR delineated by T2-CMR varies during the first week after I/R. Specifically, the edema-sensitive T2W-STIR CMR sequence overestimates MaR in comparison with MDCT at early time points (120 minutes) after reperfusion, which is in agreement with previous reports.²¹ This overestimate is mainly driven by swelling of the reperfused myocardium. By 24 hours, the scenario is completely altered, with a substantial resorption of edema and normalization of T2 relaxation time,¹⁰ resulting in systematic underestimation of MaR by CMR. This underestimation resulted in biologically implausible negative myocardial salvage data at 24 hours. This finding reinforces the idea that MaR (and consequently salvaged myocardium) cannot reliably be quantified by CMR around this time point. Conversely, on days 4 and 7, CMR-measured MaR was similar to MaR measured by MDCT.

More pronounced dynamic tissue changes were shown in the experimental model. This is a common phenomenon seen in the experimental setting in which many variables are controlled, as opposed to clinical studies. In addition, the more severe ischemic process

in the porcine myocardium in the presence of poor collateral circulation, among other reasons, could influence the magnification of this phenomenon. However, the parallel courses of T2 and CMR-MaR fluctuations observed in the clinical and experimental settings strengthen the message of the present study. Thus, our data suggest that between day 4 and day 7 would be a good compromise solution for the delineation of theoretical MaR.

Nevertheless, our results highlight the need for caution in interpreting CMR of the post-MI heart. In the clinical study, 3 of the 16 patients with STEMI showed more limited changes in T2 and extent of edema (see [online-only Data Supplement Figures III and IV](#)). Remarkably, these 3 patients were older and showed significantly smaller infarcts and less extent of IMH and MVO, and greater myocardial salvage areas despite having longer intervals between symptom onset to reperfusion (data not shown). We speculate that there might be several factors affecting the dynamics of the bimodal edematous reaction such as the existence of preformed collateral circulation, episodes of spontaneous reperfusion/reocclusion during ischemia duration, or the presence of specific comorbidities. The impossibility of controlling these aspects in the clinical scenario

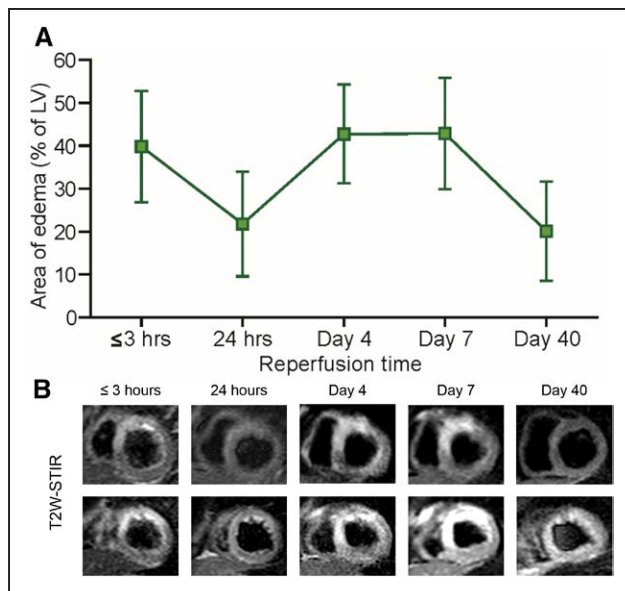


Figure 3. Time profile of edematous area in patients with ST-segment-elevation myocardial infarction.
A, Time profile of edematous area in patients with ST-segment-elevation myocardial infarction, evaluated by T2W-STIR imaging. Data are means and SD. Cardiac magnetic resonance T2W-STIR scans at ≤3 hours and on day 4 and day 7 revealed a similar edematous area (% left ventricle); in contrast, the edematous area was significantly smaller at 24 hours and on day 40 post-MI. Note the parallel courses of T2 relaxation time fluctuations and the extent of edema by cardiac magnetic resonance. **B**, Representative contiguous short-axis images from a patient with anterior ST-segment-elevation myocardial infarction who underwent serial cardiac magnetic resonance T2W-STIR examinations at 150 minutes, 26 hours, 4 days, 7 days, and 44 days after reperfusion. LV indicates left ventricle; and T2W-STIR, T2-weighted short-tau inversion recovery.

and the limited sample size preclude any definitive conclusion in this regard, but further studies are warranted.

In comparison with T2W-STIR, parametric T2 mapping might improve the detection and quantification of

myocardial edema¹⁶; however, it is unlikely to alter the dynamic pattern of post-MI edema that is attributable to pathophysiological phenomena. The deferred edema wave is related to the post-MI healing process,^{11,32} and therefore interventions that protect the myocardium could affect the dynamics of edema, and thus bias MaR estimation. This idea is supported by recent suggestions that the extent of edema can be affected by the degree of damage⁹ or exposure to infarct-limiting interventions.^{33–35} However, patients in these studies received 1 CMR examination at a single time point, which was not the same for all. Therefore, a dedicated study would be needed to provide evidence to support this hypothesis.

IMH Is Not the Main Mechanism Underlying Bimodal Post-MI Edema

In the clinical study, IMH, assessed by T2W-CMR, peaked around day 4 after reperfusion. This finding is in agreement with the present experimental CMR data and histologically validated data from our previous pig study.¹¹ Given that T2 can be affected by hemorrhage, some authors have argued that the bimodal post-MI T2-CMR pattern could be explained entirely by the destructive paramagnetic effects of deoxyhemoglobin, rather than by a real fluctuation of tissue water content.^{13,36} However, if hemorrhage was the sole explanation for the bimodal T2 pattern, it would be difficult to understand why T2 (both in the pig model¹⁰ and in the present clinical study) and water content (in the pig model)¹⁰ increased to day 4, coinciding with the maximum extent of hemorrhage.^{11,23} In fact, in the clinical study, we observed no significant influence of IMH on T2 relaxation time or area of edema delineation. The finding that infarcted (either with or without IMH areas) and salvaged myocardium displayed the same bimodal pattern strengthen our results. In line with our data, Carrick et al¹³ found small differences in T2 (<5 ms) between patients with and without hemorrhage, whereas

Table 3. Time Profile of CMR-Assessed Myocardium at Risk, Infarct Size, and Myocardial Salvage During the First Week After Reperfused Myocardial Infarction in Pigs

CMR	Follow-Up			
	120 min After Reperfusion (n=20)	24 h After Reperfusion (n=15)	Day 4 After Reperfusion(n=10)	Day 7 After Reperfusion(n=5)
MaR, % of left ventricle	48.1 (6.0)	3.6 (2.8)	30.2 (6.2)	30.1 (2.3)
Infarct size, % of left ventricle	45.1 (5.3)	35.3 (5.2)	30.2 (4.3)	25.4 (4.0)
Myocardial salvage, %	4.7 (4.7)	-1285 (858)	-2.5 (20.3)	15.7 (13.3)

Data are presented as mean (SD). CMR data for each time point correspond to pooled data from all animals undergoing 40 minutes ischemia/reperfusion. n values decrease over time because 5 pigs were euthanized after each CMR examination for histological measurement of water content.¹⁰ The extent of myocardium at risk was assessed by MDCT reference during coronary occlusion in all animals (MDCT-MaR). MDCT-MaR as assessed during the index coronary occlusion was 30.5±5.0%, 29.6±4.7%, 29.1±3.9%, and 28.3±4.3% of left ventricle; for pigs followed up to 120 minutes (n=20), 24 hours (n=15), 4 days (n=10), and 7 days (n=5) after reperfusion. Myocardial salvage as assessed by MDCT/CMR [(MDCT MaR – CMR Infarct Size) / MDCT MaR, %] in each of these groups was -50.6±24.4% at 120 minutes, -20.4±16.9% at 24 hours, -4.8±17.1% at 4 days, and 9.1±19.9% at 7 days after reperfusion, respectively. Note that MDCT was performed in all pigs only once (during the index ischemic event). Online-only Data Supplement Table III shows all individual data from animals euthanized at each time point.

CMR indicates cardiac magnetic resonance; MaR, myocardium at risk; and MDCT, multidetector computed tomography.

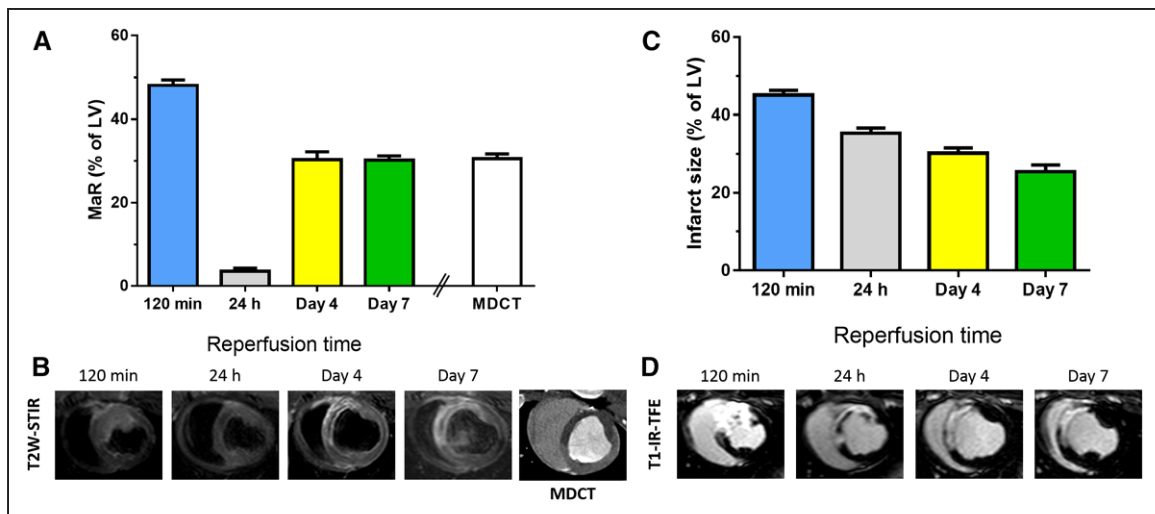


Figure 4. Temporal evolution of cardiac magnetic resonance-myocardium at risk and infarct size after reperfused myocardial infarction in the pig model.

Time profile of myocardium at risk evaluated by T2-weighted short-tau inversion recovery imaging (A) and infarct size evaluated by T1-weighted inversion recovery turbo-field echo in pigs subjected to 40 minutes inversion-recovery (C). Arterial enhanced multidetector computed tomography was performed during coronary occlusion in all pigs as a reference standard measure of myocardium at risk. Data are shown as mean±standard error of the mean. B and D, Representative images from a pig that underwent multidetector computed tomography during coronary occlusion followed by serial T2-weighted short-tau inversion recovery (B) and late gadolinium enhancement (D) examinations at 120 minutes, 24 hours, 4 days, and 7 days after reperfusion. LV indicates left ventricle; MaR, myocardium at risk; MDCT, multidetector computed tomography; T1-IR-TFE, T1-weighted inversion recovery turbo-field echo; and T2W-STIR, T2-weighted short-tau inversion recovery.

Hammer-Hansen et al¹⁷ found that T2 relaxation time differed in the infarcted and salvaged myocardium, and both were significantly longer than remote in the postreperfused dog heart. It is interesting to note that the later study followed animals at 4 and 48 hours after MI with results indicating a partial resolution of edema in the first 48 hours after reperfusion.^{17,26} Nevertheless, hemorrhage might exert some influence on T2 relaxation time, as we previously conceded.^{10,11,16,23,24}

Dynamics of Infarct Size Over the First Week After MI

Consistent with previous observations,^{3,37,38} our experimental data show a progressive decrease of CMR-based IS. The substantial swelling of the early postreperfused myocardium might explain the large IS detected in our experimental study 120 minutes after reperfusion. The early period after reperfusion is associated with significant transient expansion of extracellular volume^{11,38}; gadolinium gets trapped in this expanded extracellular volume, but when extracellular volume recedes, gadolinium no longer stays in this area. In this interpretation, acutely detected LGE does not necessarily equate to irreversible injury and may severely distort estimates of salvaged myocardium. These data highlight the importance of performing CMR infarct imaging within a consistently defined and narrow time frame, preferably at the end of the first

week, when using IS as an end point in clinical trials during the acute post-MI period.

Chronotherapeutic Approaches

New treatments demonstrating significant promise in preclinical experiments frequently produce no benefits in clinical trials,^{1,39} and the present results hint that timing of intervention might be a key determinant of this mismatch.^{40–43} We believe the discovery of the bimodal nature of post-MI edema will help in the design and new therapies for reducing infarct size and post-MI LV dysfunction.

In summary, we present the first demonstration that myocardial edema after MI is not stable in patients but instead follows a bimodal pattern, confirming recent experimental findings in pigs. The identification of such a pattern has important biological, diagnostic, prognostic, and therapeutic implications, and opens a route to further exploration of factors influencing this phenomenon. Remarkably, this bimodal edematous response after MI has a major impact on CMR-MaR, and consequently, myocardial salvage quantification given that measures of edema are greatly influenced by the timing of post-MI imaging.

LIMITATIONS

Only patients with anterior STEMI were recruited to the clinical study. The reasons for this choice include the

avoidance of possible magnetic-field nonhomogeneity related to the inferolateral wall.^{4,29} These eligibility criteria closely resemble recommendations for patient selection in clinical trials of cardioprotective interventions.^{39,44} The bimodal edema pattern may occur regardless of MI location; however, caution should be exercised when extrapolating results to other MI locations, especially regarding adequate visualization of the phenomenon by T2W-CMR in lateral MI where signal loss attributable to through-plane cardiac motion might occur.¹⁸ Given that patients were serially scanned, including 1 examination very early after reperfusion, we planned the shortest CMR protocol possible. For this reason we did not include T2* CMR as a diagnostic method for quantifying IMH in vivo.²⁹ Instead, we assessed both edema and hemorrhage by T2W-STIR imaging, a sequence validated and used for these purposes by many authors.¹⁹

Extrapolation of the experimental results to the clinic should be done with caution. Nonetheless, the pig is one of the most clinically translatable large-animal models for the study of reperfused MI.⁴⁵ The similar edema and hemorrhage time courses in the pig and the patient cohort highlight the great translational value of the pig model, especially considering the difficulty of performing a comprehensive CMR study that includes serial examinations within the first hours after reperfusion and reference techniques for the assessment of the MaR. The fact that myocardial edema and LGE follow a disparate dynamic pattern after ischemia/reperfusion highlights the complexity of measuring myocardial salvage in real practice. Thus, acutely detected LGE does not necessarily equate to irreversible injury and may contribute to severely distorted estimates of salvaged myocardium when comparing against a prereperfusion standard to assess MaR.³⁸ Other reasons might contribute to inaccurate estimations. Among them, it has been previously demonstrated that damage after ischemia/reperfusion may extend beyond the boundaries of the hypoperfused region during coronary occlusion²¹; that MaR might slightly shrink in MDCT performed during coronary occlusion because of a lack of perfusion in animal models with poor collateral circulation; and that residual edema in salvaged myocardium might contribute to the overestimation of infarct size early after reperfusion.³⁸

Last, it is fair to acknowledge that although previous studies have validated the use of MDCT to measure MaR,^{21,46} there is probably no perfect method for such purpose, because there is no consensus on a standardized method for the identification of MaR on T2W-CMR imaging.⁴⁷ Underestimation of the maximum intensity at time points exhibiting shorter myocardial T2, ie, 24 hours and day 40, could potentially bias results in the case of the full width at half-maximum method. However, we believe the region of interest selection as initial thresholding for the full width at half-maximum

method did not have a significant impact on our results for several reasons. First, the blinded analysis included manual correction and visual border delineation after initial thresholding. Second, the hemorrhagic area was larger at day 4 and day 7 coinciding with the largest edematous area delineated. Third, the demonstration of a similar bimodal edema pattern by the use of a quantitative and more objective method, ie, T2 mapping, both in the human and pig myocardium strongly supports our findings here reported.

CONCLUSIONS

Contrary to the accepted view, the post-MI edematous reaction in patients is not stable, but follows a bimodal pattern. The initial edema wave appears early on reperfusion and dissipates by 24 hours. The deferred edema wave emerges thereafter and reaches a plateau lasting from approximately day 4 to day 7 postreperfusion. Consequently, the MaR as measured by T2W-CMR changes dynamically according to timing of the CMR examination. Timing of CMR after MI for assessing MaR and salvaged myocardium needs to be standardized. According to the data presented, a time frame between day 4 and day 7 after reperfusion seems a good compromise solution although some other factors might affect these variables.

ACKNOWLEDGMENTS

The authors are greatly indebted to G. J. Lopez-Martin and M^a J. García-Sánchez for image acquisition in pigs and patient recruitment, respectively, and to the Cardiology Department at Hospital Universitario de Salamanca for patient recruitment and care. The authors thank T. Córdoba, O. Sanz, E. Fernández, and other members of the CNIC animal facility and farm for outstanding animal care and support. S. Bartlett (CNIC) provided English editing.

SOURCES OF FUNDING

This study was partially supported by a competitive grant from the Spanish Society of Cardiology (Proyectos de Investigación Traslacional en Cardiología de la Sociedad Española de Cardiología 2015, for the project Caracterización *ti*SULAR *mioc*Árdica con resonancia magnética en pacientes tras infarto agudo de *miocardio* con elevación de ST sometidos a angioplastia Coronaria primaria. Estudio SURF-CNIC), by a competitive grant from the Carlos III Institute of Health-Fondo de Investigación Sanitaria- and the European Regional Development Fund (ERDF/FEDER) (PI10/02268 and PI13/01979), the Spanish Ministry of economy, industry, and competitiveness (MEIC) and ERDF/FEDER SAF2013-49663-EXP. Dr Fernández-Jiménez holds a FICNIC fellowship from the Fundació Jesús Serra, the Fundación Interhospitalaria de Investigación Cardiovascular, and the Centro Nacional de Investigaciones Cardiovasculares Carlos III (CNIC), and Dr Agüero is a FP7-PEOPLE-2013-ITN-

Cardionext fellow. This study forms part of a Master Research Agreement between the CNIC and Philips Healthcare, and is part of a bilateral research program between Hospital de Salamanca Cardiology Department and the CNIC. This research program is part of an institutional agreement between FIIS-Fundación Jiménez Díaz and CNIC. The CNIC is supported by the MEIC and the Pro CNIC Foundation, and is a Severo Ochoa Center of Excellence (MEIC award SEV-2015-0505).

DISCLOSURES

Dr Sánchez-González is a Philips Healthcare employee. The other authors declare no conflict of interest.

AFFILIATIONS

From Centro Nacional de Investigaciones Cardiovasculares Carlos III (CNIC), Madrid, Spain (R.F.-J., J.A., C.G.-A., J.G.-P., J.S., V.F., B.I.); CIBER de Enfermedades Cardiovasculares (CIBERCV), Madrid, Spain (R.F.-J., M.B.-P., A.M.-G., J.A., C.G.-A., J.G.-P., B.G., P.L.S., B.I.); The Zena and Michael A. Wiener CVI, Icahn School of Medicine at Mount Sinai, New York (R.F.-J., J.S., V.F.); Hospital Universitario de Salamanca, Spain (M.B.-P., A.M.-G., E.D.-P., P.V., I.M., I.Z., B.G., P.L.S.); Philips Healthcare, Madrid, Spain (J.S.-G.); Cardiology Department, Hospital Universitari i Politècnic La Fe, Valencia, Spain (J.A.); and IIS-Fundación Jiménez Díaz Hospital, Madrid, Spain (B.I.).

FOOTNOTES

Received September 30, 2016; accepted June 26, 2017.

The online-only Data Supplement is available with this article at <http://circ.ahajournals.org/lookup/suppl/doi:10.1161/CIRCULATIONAHA.116.025582/-DC1>.

Circulation is available at <http://circ.ahajournals.org>.

REFERENCES

- Ibáñez B, Heusch G, Ovize M, Van de Werf F. Evolving therapies for myocardial ischemia/reperfusion injury. *J Am Coll Cardiol*. 2015;65:1454–1471. doi: 10.1016/j.jacc.2015.02.032.
- Carlsson M, Ubachs JF, Hedström E, Heiberg E, Jovinge S, Arheden H. Myocardium at risk after acute infarction in humans on cardiac magnetic resonance: quantitative assessment during follow-up and validation with single-photon emission computed tomography. *JACC Cardiovasc Imaging*. 2009;2:569–576. doi: 10.1016/j.jcmg.2008.11.018.
- Dall'Armellina E, Karia N, Lindsay AC, Karamitsos TD, Ferreira V, Robson MD, Kellman P, Francis JM, Forfar C, Prendergast BD, Banning AP, Channon KM, Kharbada RK, Neubauer S, Choudhury RP. Dynamic changes of edema and late gadolinium enhancement after acute myocardial infarction and their relationship to functional recovery and salvage index. *Circ Cardiovasc Imaging*. 2011;4:228–236. doi: 10.1161/CIRCIMAGING.111.963421.
- Friedrich MG, Kim HW, Kim RJ. T2-weighted imaging to assess post-infarct myocardium at risk. *JACC Cardiovasc Imaging*. 2011;4:1014–1021. doi: 10.1016/j.jcmg.2011.07.005.
- Aletras AH, Tilak GS, Natanzon A, Hsu LY, Gonzalez FM, Hoyt RF Jr, Arai AE. Retrospective determination of the area at risk for reperfused acute myocardial infarction with T2-weighted cardiac magnetic resonance imaging: histopathological and displacement encoding with stimulated echoes (DENSE) functional validations. *Circulation*. 2006;113:1865–1870. doi: 10.1161/CIRCULATIONAHA.105.576025.
- Heusch P, Nensa F, Heusch G. Is MRI really the gold standard for the quantification of salvage from myocardial infarction? *Circ Res*. 2015;117:222–224. doi: 10.1161/CIRCRESAHA.117.306929.
- Friedrich MG, Abdel-Aty H, Taylor A, Schulz-Menger J, Messroghli D, Dietz R. The salvaged area at risk in reperfused acute myocardial infarction as visualized by cardiovascular magnetic resonance. *J Am Coll Cardiol*. 2008;51:1581–1587. doi: 10.1016/j.jacc.2008.01.019.
- Engblom H, Heiberg E, Erlinge D, Jensen SE, Nordrehaug JE, Dubois-Randé JL, Halvorsen S, Hoffmann P, Koul S, Carlsson M, Atar D, Arheden H. Sample size in clinical cardioprotection trials using myocardial salvage index, infarct size, or biochemical markers as endpoint. *J Am Heart Assoc*. 2016;5:e002708. doi: 10.1161/JAHA.115.002708.
- Kim HW, Van Assche L, Jennings RB, Wince WB, Jensen CJ, Rehwald WG, Wendell DC, Bhatti L, Spatz DM, Parker MA, Jenista ER, Klem I, Crowley AL, Chen EL, Judd RM, Kim RJ. Relationship of T2-weighted MRI myocardial hyperintensity and the ischemic area-at-risk. *Circ Res*. 2015;117:254–265. doi: 10.1161/CIRCRESAHA.117.305771.
- Fernández-Jiménez R, Sánchez-González J, Agüero J, García-Prieto J, López-Martín GJ, García-Ruiz JM, Molina-Iracheta A, Rosselló X, Fernández-Friera L, Pizarro G, García-Álvarez A, Dall'Armellina E, Macaya C, Choudhury RP, Fuster V, Ibáñez B. Myocardial edema after ischemia/reperfusion is not stable and follows a bimodal pattern: imaging and histological tissue characterization. *J Am Coll Cardiol*. 2015;65:315–323. doi: 10.1016/j.jacc.2014.11.004.
- Fernández-Jiménez R, García-Prieto J, Sánchez-González J, Agüero J, López-Martín GJ, Galán-Arriola C, Molina-Iracheta A, Doohan R, Fuster V, Ibáñez B. Pathophysiology underlying the bimodal edema phenomenon after myocardial ischemia/reperfusion. *J Am Coll Cardiol*. 2015;66:816–828. doi: 10.1016/j.jacc.2015.06.023.
- Nordlund D, Klug G, Heiberg E, Koul S, Larsen TH, Hoffmann P, Metzler B, Erlinge D, Atar D, Aletras AH, Carlsson M, Engblom H, Arheden H. Multi-vendor, multicentre comparison of contrast-enhanced SSFP and T2-STIR CMR for determining myocardium at risk in ST-elevation myocardial infarction. *Eur Heart J Cardiovasc Imaging*. 2016;17:744–753. doi: 10.1093/ehjci/jev027.
- Carrick D, Haig C, Ahmed N, Rauhalammi S, Clerfond G, Carberry J, Moridi I, McEntegart M, Petrie MC, Eteiba H, Hood S, Watkins S, Lindsay MM, Mahrous A, Welsh P, Sattar N, Ford I, Oldroyd KG, Radjenovic A, Berry C. Temporal evolution of myocardial hemorrhage and edema in patients after acute ST-segment elevation myocardial infarction: pathophysiological insights and clinical implications. *J Am Heart Assoc*. 2016;5:e002834.
- O'Gara PT, Kushner FG, Ascheim DD, Casey Jr DE, Chung MK, de Lemos JA, Ettinger SM, Fang JC, Fesmire FM, Franklin BA, Granger CB, Krumholz HM, Linderbaum JA, Morrow DA, Newby LK, Ornato JP, Ou N, Radford MJ, Tamis-Holland JE, Tommaso CL, Tracy CM, Woo YJ, Zhao DX. 2013 ACCF/AHA guideline for the management of ST-elevation myocardial infarction: a report of the American College of Cardiology Foundation/American Heart Association Task Force on Practice Guidelines. *Circulation*. 2013;127:e362–e425. doi: 10.1161/CIR.0b013e3182742cf6.
- Steg PG, James SK, Atar D, Badano LP, Lundqvist CB, Borger MA, Di Mario C, Dickstein K, Ducrocq G, Fernandez-Aviles F, Gershlick AH, Giannuzzi P, Halvorsen S, Huber K, Juni P, Kastrati A, Knuuti J, Lenzen MJ, Mahaffey KW, Valgimigli M, van't Hof A, Widimsky P, Zahger D, Bax JJ, Baumgartner H, Ceconi C, Dean V, Deaton C, Fagard R, Funk-Brentano C, Hasdai D, Hoes A, Kirchhof P, Knuuti J, Kolh P, McDonagh T, Moulin C, Popescu BA, Reiner Ž, Sechtem U, Sirnes PA, Tendera M, Torbicki A, Vahanian A, Windecker S, Hasdai D, Astin F, Åström-Olsson K, Budaj A, Clemmensen P, Collet J-P, Fox KA, Fuat A, Gustiene O, Hamm CW, Kala P, Lancellotti P, Maggioni AP, Merkely B, Neumann F-J, Piepoli MF, Van de Werf F, Verheugt F, Wallentin L. ESC Guidelines for the management of acute myocardial infarction in patients presenting with ST-segment elevation. *Eur Heart J*. 2012;33:2569–2619.
- Fernández-Jiménez R, Sánchez-González J, Agüero J, Del Trigo M, Galán-Arriola C, Fuster V, Ibáñez B. Fast T2 gradient-spin-echo (T2-GraSE) mapping for myocardial edema quantification: first *in vivo* validation in a porcine model of ischemia/reperfusion. *J Cardiovasc Magn Reson*. 2015;17:92. doi: 10.1186/s12968-015-0199-9.
- Hammer-Hansen S, Ugander M, Hsu LY, Taylor J, Thune JJ, Køber L, Kellman P, Arai AE. Distinction of salvaged and infarcted myocardium within the ischaemic area-at-risk with T2 mapping. *Eur Heart J Cardiovasc Imaging*. 2014;15:1048–1053. doi: 10.1093/ehjci/jeu073.
- Fernández-Friera L, García-Ruiz JM, García-Álvarez A, Fernández-Jiménez R, Sánchez-González J, Rosselló X, Gómez-Talavera S, López-Martín GJ, Pizarro G, Fuster V, Ibáñez B. Accuracy of area at risk quantification by

- cardiac magnetic resonance according to the myocardial infarction territory. *Rev Esp Cardiol (Engl Ed)*. 2017;70:323–330. doi: 10.1016/j.rec.2016.07.004.
19. Robbers LF, Eerenberg ES, Teunissen PF, Jansen MF, Hollander MR, Horvoets AJ, Knaapen P, Nijveldt R, Heymans MW, Levi MM, van Rossum AC, Niessen HW, Marcu CB, Beek AM, van Royen N. Magnetic resonance imaging-defined areas of microvascular obstruction after acute myocardial infarction represent microvascular destruction and haemorrhage. *Eur Heart J*. 2013;34:2346–2353. doi: 10.1093/eurheartj/ehs100.
 20. Valle-Caballero MJ, Fernández-Jiménez R, Díaz-Munoz R, Mateos A, Rodríguez-Álvarez M, Iglesias-Vázquez JA, Saborido C, Navarro C, Domínguez ML, Gorjón L, Fontoira JC, Fuster V, García-Rubira JC, Ibanez B. QRS distortion in pre-reperfusion electrocardiogram is a bedside predictor of large myocardium at risk and infarct size (a METOCARD-CNIC trial substudy). *Int J Cardiol*. 2016;202:666–673. doi: 10.1016/j.ijcard.2015.09.117.
 21. Mewton N, Rapacchi S, Augeul L, Ferrera R, Loufouat J, Boussel L, Micolich A, Rioufol G, Revel D, Ovize M, Croisille P. Determination of the myocardial area at risk with pre- versus post-reperfusion imaging techniques in the pig model. *Basic Res Cardiol*. 2011;106:1247–1257. doi: 10.1007/s00395-011-0214-8.
 22. Fernández-Jiménez R, Fuster V, Ibáñez B. Reply: myocardial salvage, area at risk by T2w CMR: the resolution of the retrospective radio wave paradigm? *J Am Coll Cardiol*. 2015;65:2358–2359. doi: 10.1016/j.jacc.2015.02.071.
 23. Fernández-Jiménez R, Fuster V, Ibanez B. Reply: “waves of edema” seem implausible. *J Am Coll Cardiol*. 2016;67:1869–1870. doi: 10.1016/j.jacc.2016.01.052.
 24. Fernández-Jiménez R, Fuster V, Ibáñez B. Reply: myocardial edema should be stratified according to the state of cardiomyocytes within the ischemic region. *J Am Coll Cardiol*. 2015;65:2356–2357. doi: 10.1016/j.jacc.2015.02.070.
 25. Arai AE. Healing after myocardial infarction: a loosely defined process. *JACC Cardiovasc Imaging*. 2015;8:680–683. doi: 10.1016/j.jcmg.2015.02.012.
 26. Arai AE. Area at risk in acute myocardial infarction: oedema imaging and species-specific findings. *Eur Heart J Cardiovasc Imaging*. 2016;17:754–755. doi: 10.1093/ehjci/jev074.
 27. Dharmakumar R. Building a unified mechanistic insight into the bimodal pattern of edema in reperfused acute myocardial infarctions: observations, interpretations, and outlook. *J Am Coll Cardiol*. 2015;66:829–831. doi: 10.1016/j.jacc.2015.05.074.
 28. Kloner RA. New observations regarding post-ischemia/reperfusion myocardial swelling. *J Am Coll Cardiol*. 2015;65:324–326. doi: 10.1016/j.jacc.2014.11.006.
 29. Salerno M, Kramer CM. Advances in parametric mapping with CMR imaging. *JACC Cardiovasc Imaging*. 2013;6:806–822. doi: 10.1016/j.jcmg.2013.05.005.
 30. Arai AE, Leung S, Kellman P. Controversies in cardiovascular MR imaging: reasons why imaging myocardial T2 has clinical and pathophysiological value in acute myocardial infarction. *Radiology*. 2012;265:23–32. doi: 10.1148/radiol.12112491.
 31. Croisille P, Kim HW, Kim RJ. Controversies in cardiovascular MR imaging: T2-weighted imaging should not be used to delineate the area at risk in ischemic myocardial injury. *Radiology*. 2012;265:12–22. doi: 10.1148/radiol.12111769.
 32. Samouillan V, Revuelta-López E, Soler-Botija C, Dandurand J, Benitez-Amaro A, Nasarre L, de Gonzalo-Calvo D, Bayes-Genis A, Lacabanne C, Llorente-Cortés V. Conformational and thermal characterization of left ventricle remodeling post-myocardial infarction. *Biochim Biophys Acta*. 2017;1863:1500–1509. doi: 10.1016/j.bbdis.2017.02.025.
 33. Crimi G, Pica S, Raineri C, Bramucci E, De Ferrari GM, Klersy C, Ferlini M, Marini B, Repetto A, Romeo M, Rosti V, Massa M, Raisaro A, Leonardi S, Rubartelli P, Oltrona Visconti L, Ferrario M. Remote ischemic post-conditioning of the lower limb during primary percutaneous coronary intervention safely reduces enzymatic infarct size in anterior myocardial infarction: a randomized controlled trial. *JACC Cardiovasc Interv*. 2013;6:1055–1063. doi: 10.1016/j.jcin.2013.05.011.
 34. Thuny F, Lairez O, Roubille F, Mewton N, Rioufol G, Sportouch C, Sanchez I, Bergerot C, Thibault H, Cung TT, Finet G, Argaud L, Revel D, Dumeaux G, Bonnefoy-Cudraz E, Elbaz M, Piot C, Ovize M, Croisille P. Post-conditioning reduces infarct size and edema in patients with ST-segment elevation myocardial infarction. *J Am Coll Cardiol*. 2012;59:2175–2181. doi: 10.1016/j.jacc.2012.03.026.
 35. White SK, Frohlich GM, Sado DM, Maestrini V, Fontana M, Treibel TA, Tehrani S, Flett AS, Meier P, Ariti C, Davies JR, Moon JC, Yellon DM, Hausenloy DJ. Remote ischemic conditioning reduces myocardial infarct size and edema in patients with ST-segment elevation myocardial infarction. *JACC Cardiovasc Interv*. 2015;8(1 pt B):178–188. doi: 10.1016/j.jcin.2014.05.015.
 36. Berry C, Carrick D, Haig C, Oldroyd KG. “Waves of edema” seem implausible. *J Am Coll Cardiol*. 2016;67:1868–1869. doi: 10.1016/j.jacc.2015.11.073.
 37. Ibrahim T, Hackl T, Nekolla SG, Breuer M, Feldmair M, Schömig A, Schwaiger M. Acute myocardial infarction: serial cardiac MR imaging shows a decrease in delayed enhancement of the myocardium during the 1st week after reperfusion. *Radiology*. 2010;254:88–97. doi: 10.1148/radiol.09090660.
 38. Jablonowski R, Engblom H, Kanski M, Nordlund D, Koul S, van der Pals J, Englund E, Heiberg E, Erlinge D, Carlsson M, Arheden H. Contrast-Enhanced CMR overestimates early myocardial infarct size: mechanistic insights using ECV measurements on day 1 and day 7. *JACC Cardiovasc Imaging*. 2015;8:1379–1389. doi: 10.1016/j.jcmg.2015.08.015.
 39. Hausenloy DJ, Botker HE, Engstrom T, Erlinge D, Heusch G, Ibanez B, Kloner RA, Ovize M, Yellon DM, Garcia-Dorado D. Targeting reperfusion injury in patients with ST-segment elevation myocardial infarction: trials and tribulations. *Eur Heart J*. 2017;38:935–941. doi: 10.1093/eurheartj/ehw145.
 40. García-Ruiz JM, Fernández-Jiménez R, García-Álvarez A, Pizarro G, Galán-Arriola C, Fernández-Friera L, Mateos A, Nuno-Ayala M, Agüero J, Sánchez-González J, García-Prieto J, López-Melgar B, Martínez-Tenorio P, López-Martín GJ, Macías A, Pérez-Asenjo B, Cabrera JA, Fernández-Ortiz A, Fuster V, Ibáñez B. Impact of the timing of metoprolol administration during STEMI on infarct size and ventricular function. *J Am Coll Cardiol*. 2016;67:2093–2104. doi: 10.1016/j.jacc.2016.02.050.
 41. Pryds K, Terkelsen CJ, Sloth AD, Munk K, Nielsen SS, Schmidt MR, Bøtker HE; CONDI Investigators. Remote ischaemic conditioning and healthcare system delay in patients with ST-segment elevation myocardial infarction. *Heart*. 2016;102:1023–1028. doi: 10.1136/heartjnl-2015-308980.
 42. Roubille F, Mewton N, Elbaz M, Roth O, Prunier F, Cung TT, Piot C, Roncalli J, Rioufol G, Bonnefoy-Cudraz E, Wiedemann JY, Furber A, Jacquemin L, Willoteaux S, Abi-Khalil W, Sanchez I, Finet G, Sibellas F, Ranc S, Bous-saha I, Croisille P, Ovize M. No post-conditioning in the human heart with thrombolysis in myocardial infarction flow 2-3 on admission. *Eur Heart J*. 2014;35:1675–1682. doi: 10.1093/eurheartj/ehu054.
 43. Liu B, Duan CY, Luo CF, Ou CW, Wu ZY, Zhang JW, Ni XB, Chen PY, Chen MS. Impact of timing following acute myocardial infarction on efficacy and safety of bone marrow stem cells therapy: a network meta-analysis. *Stem Cells Int*. 2016;2016:1031794. doi: 10.1155/2016/1031794.
 44. Bell RM, Bøtker HE, Carr RD, Davidson SM, Downey JM, Dutka DP, Heusch G, Ibanez B, Macallister R, Stoppe C, Ovize M, Redington A, Walker JM, Yellon DM. 9th Hatter Biannual Meeting: position document on ischaemia/reperfusion injury, conditioning and the ten commandments of cardioprotection. *Basic Res Cardiol*. 2016;111:41. doi: 10.1007/s00395-016-0558-1.
 45. Fernández-Jiménez R, Fernández-Friera L, Sánchez-González J, Ibáñez B. Animal models of tissue characterization of area at risk, edema and fibrosis. *Curr Cardiovasc Imaging Rep*. 2014;7:1–10.
 46. van der Pals J, Hammer-Hansen S, NIELLES-Vallespin S, Kellman P, Taylor J, Kozlov S, Hsu LY, Chen MY, Arai AE. Temporal and spatial characteristics of the area at risk investigated using computed tomography and T1-weighted magnetic resonance imaging. *Eur Heart J Cardiovasc Imaging*. 2015;16:1232–1240. doi: 10.1093/ehjci/jev072.
 47. McAlindon E, Pufulete M, Lawton C, Angelini GD, Bucciarelli-Ducci C. Quantification of infarct size and myocardium at risk: evaluation of different techniques and its implications. *Eur Heart J Cardiovasc Imaging*. 2015;16:738–746. doi: 10.1093/ehjci/jev001.