

OSTEOARTHRITIS OF THE EQUINE TEMPOROMANDIBULAR JOINT

A Thesis Submitted to the College of Graduate and Postdoctoral Studies

In Partial Fulfilment of the Requirements

For the Degree of Master of Science

In the Department of Large Animal Clinical Sciences

Western College of Veterinary Medicine

University of Saskatchewan

Saskatoon

By

TRAVIS T. SMYTH

© Copyright Travis T. Smyth, July, 2017. All rights reserved.

PERMISSION TO USE

In presenting this thesis in partial fulfillment of the requirements for a Postgraduate degree from the University of Saskatchewan, I agree that the Libraries of this University may make it freely available for inspection. I further agree that permission for copying of this thesis in any manner, in whole or in part, for scholarly purposes may be granted by the professor who supervised my thesis work or, in their absence, by the Head of the Department or the Dean of the College in which my thesis work was done. It is understood that any copying or publication or use of this thesis or parts thereof for financial gain shall not be allowed without my written permission. It is also understood that due recognition shall be given to me and to the University of Saskatchewan in any scholarly use which may be made of any material in my thesis.

DISCLAIMER

Reference in this thesis to any specific commercial products, process, or service by trade name, trademark, manufacturer, or otherwise; does not constitute or imply its endorsement, recommendation, or favoring by the University of Saskatchewan. The views and opinions of the author expressed herein do not state or reflect those of the University of Saskatchewan, and shall not be used for advertising or product endorsement purposes.

Requests for permission to copy or to make other uses of materials in this thesis in whole or part should be addressed to:

Head of the Department of Large Animal Clinical Sciences
Western College of Veterinary Medicine
University of Saskatchewan
52 Campus Drive
Saskatoon, Saskatchewan, S7N 5B4
Canada

OR

Dean
College of Graduate Studies and Research
University of Saskatchewan
107 Administration Place
Saskatoon, Saskatchewan, S7N 5A2
Canada

ABSTRACT

Degeneration of the temporomandibular joint (TMJ) is a well reported condition in several mammalian species, including man. Yet, for the length of time that horses have been domesticated, we understand very little about the conditions affecting their TMJs. Up to this point, equine temporomandibular joint disease (TMJD) has been infrequently reported, with cases occurring secondary to a traumatic event, one that results in overt inflammation, either due to fracture, joint sepsis, or both. With various etiologic causes of degenerative joint disease (DJD) in other joints, the apparent absence of these causes within equine TMJD is an enigma. As such, the focus of this work is to characterize the clinical effect of TMJ inflammation on mastication and histologically evaluate the changes seen within equine TMJs as horses age.

The first work is a retrospective case report describing the occurrence of bilateral, non-traumatic, DJD in the TMJs, of a geriatric horse. The focus-patient had no history of trauma, but slowly developed signs of headshaking and began suffering from several bouts of impaction colic. When eating, the horse would consistently drop partially chewed feed (quid) and the jaw would make an audible ‘clicking’ sound. Computed tomography of the TMJs demonstrated bilateral mineralization of the rostral aspect of both intra-articular discs. Intraarticular injection of corticosteroid resulted in temporary resolution of the quidding behavior, the ‘clicking’ sound, and the recurrent episodes of colic. The occurrence of bilateral TMJD in an elderly horse, without evidence of trauma or sepsis, is unique. It suggests that, like many other joints, age-related changes occur within the TMJ, predisposing the joint to degeneration.

The second study examines the relationship between the onset of acute unilateral inflammation of the TMJ and the development of clinical signs; distortion of the masticatory cycle, effusion of the affected TMJ, and aversion behavior suggestive of pain. Using a three-dimensional (3-D) motion tracking system, the authors examined the masticatory cycle of six horses, free of dental abnormalities. Horses were observed chewing grass hay over three minute intervals. Regardless of the side of mastication, all horses were injected in the left TMJ with lipopolysaccharide. Six hours post-injection the horses were re-assessed. All data were compared using paired t-tests.

Four of six horses developed effusion of the injected TMJs; two also began quidding. All horses injected on the “chewing side”, switched sides post-injection; the two injected contralateral to the “chewing side” did not. All horses showed reduced vertical pitch of the mandible (mouth opening), but not lateral movement, post-injection. Overall rostrocaudal movement of the mandible did not change, but timing relative to the opening and closing phases of the cycle was different. Although horses demonstrated aversion behavior, all subjects continued to eat.

The third, and final, study analyses the histologic presence of age-related change within the TMJs of 11 clinically normal horses. Each TMJ was frozen *in-situ* and sectioned in 5 mm slices, at random (transverse or sagittal direction). A histologic assessment for age-related change was made using a modified Mankin scoring system. The horses were divided into three age groups. The overall joint score was not significantly different between left and right joints within each age group. As the age of the horses in each group increased, there was a significant increase in the total joint score (accumulation of age-related changes); the youngest group of horses were significantly different than those in the oldest group, but neither were significantly different from the middle-aged group of horses.

ACKNOWLEDGMENTS

First and foremost, I would like to thank Dr. James Carmalt, who served as my supervisor throughout both my surgical residency and post-graduate degree. I would also like thank Dr. Andy Allen for his expertise and guidance during the histologic assessment of the temporomandibular joints (TMJs) and Mrs. Leah Heasman of Prairie Diagnostics Services, for sectioning each of the TMJs.

I would like to thank the remaining co-authors on these published works: Dr. Joel Lanovaz from the College of Kinesthesiology, University of Saskatchewan and Mr. Tanner Treen.

Lastly, I would like to thank the Western College of Veterinary Medicine for graciously providing me with an Inter-provincial Graduate Fellowship throughout my term as a graduate student.

TABLE OF CONTENTS

PERMISSION TO USE	i
DISCLAIMER	ii
ABSTRACT	iii
ACKNOWLEDGMENTS	v
TABLE OF CONTENTS	vi
LIST OF TABLES	ix
LIST OF FIGURES	x
LIST OF ABBREVIATIONS	xiv
CHAPTER 1: OBJECTIVES AND HYPOTHESES	1
CHAPTER 2: LITERATURE REVIEW	2
2.1 Introduction.....	2
2.2 Evolution of the temporomandibular joint.....	3
2.3 Embryology and development	4
2.4 Epidemiology of temporomandibular joint disease.....	4
2.5 Anatomy of the temporomandibular joint	7
2.6 Joint movement and masticatory kinetics	9
2.7 Pathophysiology of degenerative joint disease	13
2.8 Causes of temporomandibular joint disease.....	14
2.9 Clinical signs.....	17

2.10 Diagnostic testing.....	18
2.10.1 Arthrocentesis.....	18
2.10.2 Diagnostic imaging.....	19
2.11 Treatment	22
2.12 Summary	23
2.13 References.....	25

CHAPTER 3: CLINICALLY SIGNIFICANT, NONTRAUMATIC, DEGENERATIVE JOINT DISEASE OF THE TEMPOROMANDIBULAR JOINTS IN A HORSE..... 36

3.1 Abstract	37
3.2 Introduction.....	37
3.3 Case history.....	38
3.4 Diagnosis.....	39
3.5 Treatment	40
3.6 Outcome	40
3.7 Post-mortem findings.....	42
3.8 Discussion	49
3.9 Footnotes	51
3.10 References.....	52

CHAPTER 4: THE EFFECT OF ACUTE UNILATERAL INFLAMMATION OF THE EQUINE TEMPOROMANDIBULAR JOINT ON THE KINEMATICS OF MASTICATION..... 56

4.1 Abstract	57
4.2 Introduction.....	57
4.3 Materials and methods.....	58
4.3.1 Animals	58
4.3.2 Kinematic data collection.....	59

4.3.3 Data analysis	60
4.4 Results	61
4.5 Discussion	67
4.6 Footnotes	70
4.7 References	70
CHAPTER 5: A HISTOLOGIC ASSESSMENT OF AGE-RELATED CHANGE IN THE EQUINE TEMPOROMANDIBULAR JOINT	74
5.1 Introduction	75
5.2 Methods	76
5.3 Results	81
5.4 Discussion	82
5.5 References	94
CHAPTER 6: GENERAL DISCUSSION	99
6.1 References	102
CHAPTER 7: CONCLUSIONS AND FUTURE STUDIES	106
7.1 General conclusions	106
7.2 General limitations	107
7.3 Future research	108
7.4 References	109

LIST OF TABLES

Table 4.1: Group means (and +/- s.d) for cycle time, ranges of motion (ROM) over the cycle and rostrocaudal mandible displacement over the closing and power stroke phases for pre- and post-temporomandibular joint (TMJ) injection..... 65

Table 5.1: Scoring criteria for histologic assessment, by region, of the TMJs. A) Condyles and B) Central disc. The total possible range per region is from zero to 16..... 77

Table 5.2: Total variable scores by anatomic region, sectioned in the sagittal plane, by age group (Pairwise comparisons were not performed when P values did not meet the criteria for significance)..... 84

Table 5.3: Total variable scores by anatomic region, sectioned in the frontal plane, by age group (Pairwise comparisons were not performed when P values did not meet the criteria for significance)..... 85

LIST OF FIGURES

- Figure 3.1:** A computed tomographic series of images (a: transverse, b: dorsal and c: sagittal planes) showing the area of increased linear attenuation suggestive of mineralized tissue (arrow) in the rostral aspect of the intraarticular disc of the right temporomandibular joint of an 18 year-old Tennessee Walking horse mare 41
- Figure 3.2:** A T1-weighted sagittal magnetic resonance image of the right temporomandibular joint showing a region of reduced signal intensity (white arrow) in the rostral aspect of the intraarticular disc suggestive of mineralized tissue 43
- Figure 3.3:** A relatively large focus of chondroid metaplasia within the intraarticular disc of the left temporomandibular joint of an 18 year-old Tennessee Walking Horse mare. (Original magnification = 20X haematoxylin and eosin stain 44
- Figure 3.4:** A large focus of chondro-osseous metaplasia at the attachment of the intraarticular disc to the joint capsule of the left temporomandibular joint. (Original magnification = 2X; haematoxylin and eosin stain)..... 45
- Figure 3.5:** A large focus of chondro-osseous metaplasia at the synovial surface of the intraarticular disc, at the attachment to the joint capsule, of the right temporomandibular joint. The articular surface and subchondral bone of the mandibular fossa of the temporal bone are present in the upper left corner of the image (Original magnification = 4X; haematoxylin and eosin stain) 46

Figure 3.6: An area of the articular surface and subchondral bone of the right mandibular condyle. There is a generalized decrease in basophilic staining of the surface cartilage, interpreted as loss of proteoglycan, and a dramatic decrease in the number of chondrocytes. (Original magnification = 10X; haematoxylin and eosin stain)..... 47

Figure 3.7: The articular surface of the mandibular fossa of the temporal bone. There are many clusters or clones of chondrocytes, referred to as chondrones. (Original magnification = 10X; haematoxylin and eosin stain)..... 48

Figure 4.1: Marker locations and kinematics definitions. Four tracking markers were placed on the skull (S1–S4) with two on either side of the midline, between the eyes. The four mandible tracking markers (M1–M4) were located in line with the caudal ramus of the mandible. The right and left articular tubercles of the skull (RT, LT) and two points along the facial crest (FC1, FC2) were located using a calibrated probe and used to generate the skull coordinate system (shown). The mandible coordinate system was defined as initially coincident with the skull coordinate system 62

Figure 4.2: Frontal view (Y-Z plane) of the mean path of the virtual mandible marker for one horse. The graph shows pre- (black) and post- (grey) injection cycle paths (in mm). The origin is arbitrarily set as the start of the closing phase for both conditions. The direction of the masticatory cycle is shown by the arrows and the cycle phases are indicated by the line types. 63

Figure 4.3: Pre- (black) and post- (grey) injection mean rostral–caudal movement of the virtual mandible marker during the 15 masticatory cycles for a typical horse. Standard deviations are shown with hatched lines and cycle phases are indicated by line types. Zero per cent of cycle time corresponds to the start of the closing phase..... 66

Figure 5.1: The two slides in each AG (a and b) are representative samples highlighting the characteristics that were used to evaluate age-related change in this study. Age group 1 possessed numerous, uniformly distributed chondrocytes. Regions of acellularity (ovals) increased in frequency with increasing AG, becoming multifocal to coalescing regions of acellularity, as seen in AG 3. Chondrocytes formed clusters with increasing frequency by AG (squares). Six or more chondrocytes in a cluster were defined as large chondrons (arrows) and also increased in frequency with age..... 78

Figure 5.2: The two slides in each AG (a and b) are representative samples highlighting the characteristics that were used to evaluate age-related change in this study. AG 1 possessed numerous, uniformly distributed chondrocytes. Regions of acellularity (ovals) increased in frequency with increasing AG. Chondroid metaplasia accumulated with increasing AG, starting as scattered individual metaplastic cells (asterisk) and later becoming aggregated into foci of more than one cell (squares). Foci of osseous metaplasia were also noted to increase with corresponding AG (triangles) 79

Figure 5.3: Box and whisker plot describing the sum of the total joint score by age group (The thick black line represents the 50th percentile and the error bars establish 95% C.I. * = 32-year-old horse that was substantially older than the rest of the horses in the study) 83

Figure 5.4: A graphical representation of histologic variables associated with sagittal plane sectioning of the mandibular condyle (Numbers without brackets represent the median section score. Numbers in within the brackets represent the minimum and maximum range). 86

Figure 5.5: A graphical representation of histologic variables associated with frontal plane sectioning of the mandibular condyle (Numbers without brackets represent the median section score. Numbers in within the brackets represent the minimum and maximum range) 87

Figure 5.6: A graphical representation of histologic variables associated with sagittal plane sectioning of the temporal condyle (Numbers without brackets represent the median section score. Numbers in within the brackets represent the minimum and maximum range). 88

Figure 5.7: A graphical representation of histologic variables associated with frontal plane sectioning of the temporal condyle (Numbers without brackets represent the median section score. Numbers in within the brackets represent the minimum and maximum range. NS or No Score indicates an area that was not assessed). 89

Figure 5.8: A graphical representation of histologic variables associated with sagittal plane sectioning of the fibrocartilaginous disc (Numbers without brackets represent the median section score. Numbers in within the brackets represent the minimum and maximum range). 90

Figure 5.9: A graphical representation of histologic variables associated with frontal plane sectioning of the fibrocartilaginous disc (Numbers without brackets represent the median section score. Numbers in within the brackets represent the minimum and maximum range) 91

LIST OF ABBREVIATIONS

3-D	Three-dimensional
A.L.A.	Andrew Allen
AG (1 to 3)	Age group (1 to 3)
Cells/L	Cells per litre
Cm	Centimetre
CT	Computed tomography
DJD	Degenerative joint disease
°C	Degrees Celsius
g/L	Grams per litre
g/dL	Grams per decilitre
Hz	Hertz
IL	Interleukin
i.v.	Intravenous
J.L.C.	James Carmalt
kg	Kilograms
LPS	Lipopolysaccharide
L	Litre
MRI	Magnetic resonance imaging
NS	No score
µg	Micrograms
µm	Micrometre
mg	Milligrams
mg/mL	Milligrams per millilitre
mL	Millilitre
mm	Millimetre
N	Newtons
N.S.	Non-significant
OA	Osteoarthritis
ROM	Range of motion

s.d.	Standard deviation
T1	Tissue relaxation type one
T2	Tissue relaxation type two
T2*	Tissue relaxation type two star
TGF- β	Tissue growth factor beta
TMJ	Temporomandibular joint
TMJD	Temporomandibular joint disease
TNF- α	Tumor necrosis factor alpha

CHAPTER 1: OBJECTIVES AND HYPOTHESES

Due to the paucity of literature surrounding the equine TMJ, the knowledge of equine TMJD is generally very poor. When combined with the obscure clinical signs common to this disease, it may leave the problem misdiagnosed or entirely unnoticed. This leads to a perception by veterinary practitioners (and horse owners) that equine TMJD is either very rare or non-painful, neither of which has been scientifically tested.

The first work, a case study, was used to highlight the presence of a previously unreported form of equine TMJD. This study suggests that factors other than trauma or sepsis may play a role in the formation of disease. The objective of this report was to characterize the presence of a novel form of equine TMJD.

The objective of the second study was to determine whether acute unilateral inflammation within the TMJ would result in the alteration of the masticatory cycle, indicating a pain response. The hypothesis of this study was that the induction of acute unilateral inflammation of the TMJ would cause derangement of the normal cycle of mastication.

Building on the information obtained from the case report, the third study was designed to observe and evaluate the presence of histologic changes within the TMJs of horses as they age. As horses age, the accumulation of these changes, may lead to clinical manifestations of TMJD. Thus, the objective of this study was to determine if a correlation exists between horse age (years) and the degree of histologic changes occurring within the joint. The hypothesis of this study was that there is a positive correlation between age and the degree of histologic change in the equine TMJ.

CHAPTER 2: LITERATURE REVIEW

2.1 Introduction:

The TMJ is singular in both form and function. Unlike the weight-bearing joints of the appendicular skeleton, each TMJ contains a unique central fibrocartilaginous disc. When paired bilaterally, these joints are responsible for the hinged motion of the mandible. Yet, despite their important function, the TMJ remains somewhat of an enigma.

Basic research into the equine TMJ is lacking and is often restricted to case reports highlighting the treatment of end-stage disease. In fact, the low rate of reported equine TMJD leads to the assumption that disease occurrence within these joints is also rare. Additionally, when disease in these joints does occur, the signs are often subtle (or sub-clinical), leading to the assumption that the disease process must be painless. If this is the case, then the characteristics of this joint effectively make it resistant to the development of, or at least the pain associated with, OA; a potentially vital question given today's aging equine and human populations.

Unfortunately, the lack of documented cases of TMJD in equids does not constitute a lack of occurrence. Research into the TMJ of horses suggests that inflammatory processes of the TMJ do occur and are analogous to those occurring in other joints (Carmalt et al. 2006; Carmalt et al. 2011). It is possible that the lack of reported cases is not due to a lack in disease occurrence or the development of pain, as much as inadequate training to recognize the clinical signs with which horses present. The TMJ is a unique fibrocartilaginous, non-weight-bearing joint, and as such horses with TMJD may not present with the same clinical signs as those seen with hyaline cartilaginous joints of the limbs. Therefore, they cannot be expected to undergo the same clinical assessment.

Examples of TMJD are seen across many species, most notably in humans (Arzi et al. 2013; Arzi et al. 2015; Henderson et al. 2015; McDonald et al. 2015). In recent years, TMJD has become somewhat of a “buzz-word”, with research in humans suggesting that not only is the disease painful, but that roughly 30% to 40% of the population experience clinical signs associated with this condition at some point in their lives (Goulet et al. 1995; Pow et al. 2001; Macfarlane et al. 2002; Lamot et al. 2013).

2.2 Evolution of the temporomandibular joint:

The TMJ appeared with the rise of mammals during the Triassic period, 230 million years ago. Until this point the mandible hinged on a rudimentary joint composed of the quadrate bone of the skull and the articular bone of the mandible; a joint seen in modern reptiles and birds. According to fossil records, the formation of this “dentary-squamosal joint” caused the bones of the pre-existing joint to be pushed caudally, forming the malleus and incus, the bones of the middle ear. Prior to this, the middle ear was composed of a single bone, the stapes. Fusion of the styloid process, tympanic, petrosal and mastoid bones then completed the formation of the TMJ. Subsequently, cartilage over the condylar process of the mandible led to the formation of the current synovial joint (Anthwal et al. 2013). The ossification of cartilage secondary to formation, likely allows for alteration of the shape and size of the processes during growth and dietary change. The size, position, and distribution of the condylar processes is reported to be species specific (Anthwal et al. 2013). For example, omnivorous species, whose diets consist of large quantities of cellulose, tend to have larger angular processes than closely related species that consume less cellulose subsistent diets. Animals that have a wide gape and strong bites, such as carnivores, tend to have robust angular and condylar processes (Anthwal et al. 2013). This characteristic has yet to be described in the horse.

2.3 Embryology and development:

The temporal and mandibular condyles form from mesenchymal stem cells. Studies examining the activation of the Sox9 and Runx2 genes have shown that a failure to express these genes prevents mesenchymal cell condensation within the TMJ (Hinton 2014). This is followed by the formation of cancellous bone in the mandibular ramus and endochondral ossification of condylar cartilage. Almost simultaneously, a cleft will form in each the condylar process and the temporal mesenchyme. A sheet of cells, activated by the hedgehog signaling gene, lifts from the condyle to create a space for the TMJ's inferior synovial pouch. The superior synovial pouch forms soon after, leaving the mesenchymal stem cells between the two synovial cavities to condense into the fibrocartilaginous disc (Ögütçen-Toller and Keskin 2000). Evidence suggests that signals from both the temporal fossa and the mandibular condyle, are required to result in proper disc formation; when the condyle does not contact the fossa, disc formation remains incomplete (Wang et al. 2011).

An embryological study of the formation of the equine TMJ has yet to be published. In other species the developmental order of the TMJ appears static, varying only in the timespan required for formation (Ögütçen-Toller and Keskin 2000; Yamaki et al. 2005). The formation of the TMJ occurs between the first and second trimester in humans, but towards the end of gestation in rats. When compared to other joints of the body (of the same species), the TMJ tends to form much later in development (Ögütçen-Toller 1995; Ögütçen-Toller and Keskin 2000).

2.4 Epidemiology of temporomandibular joint disease:

Unlike the plethora of research into human TMJD, the dearth of reported cases in equids precludes any attempt at accurate epidemiology. Fortunately, the universal evolution of the TMJ among mammals can possibly shed light on the physiognomies of this unique joint. Diseases of the TMJ are not restricted merely to equids (Arzi et al. 2013; Arzi et al. 2015; Murphy et al. 2013; Ikeda et al. 2014; Rafalelyan et al. 2015). While the specifics of TMJD should be viewed with caution when attempting to apply cross-species comparisons, a few general trends may exist. In

humans, for example, the rate of TMJD is three times higher in women than in men and may be linked to endogenous levels of circulating hormones, namely estrogen and testosterone (Goulet et al. 1995; Macfarlane et al. 2002; Johansson et al. 2003; Wang et al. 2008; Bagis et al. 2012). Many studies have also reported an increased rate of OA-related TMJD in older individuals (Bagis et al. 2012; Lamot et al. 2013). However, it is likely that equine TMJD, like human TMJD, is multifactorial and unidentified factors may play a role in its development.

Equine literature discussing the prevalence or development of TMJD as horses age, is limited to a single large multicenter study (Carmalt et al. 2016). In this paper, the authors examined the CT images from the heads of 1018 horses. The group found that mandibular condyles changed shape as horses matured. Often beginning as globoid in nature and flattening out over time, the changes occurred at an equal rate between each of the two mandibular condyles. The group also examined sex predisposition and found that geldings were significantly more likely to develop condylar changes than mares, but were not significantly different than stallions. The rate of change in stallions and mares were not significantly different from each other. There was also a tendency for older horses to develop bony regions of hyper-density within the intraarticular disc, indicating either age-related change, the development of OA, or both. Other authors have noted that the thickness of the articular cartilage decreases as horses age, measuring nearly 3 mm in foals and becoming almost immeasurable in older horses (Weller et al. 1999b; Rodriguez et al. 2010).

The degree of osteoarthritic change may not be highly correlated with the degree of pain. Carmalt et al. (2016) found that roughly 30% of cases presenting for signs unrelated to TMJD, showed irregularities consistent with DJD in the TMJ's. To date, there are only two publications that highlight the presence of clinically relevant primary OA in the equine TMJ (Jørgensen et al. 2014; Smyth et al. 2015).

The majority of reported cases of equine TMJD cases have been trauma-related, commonly leading to a combination of fracture of the mandibular condyle or temporal bone and tearing or displacement of the fibrocartilaginous disc. Additionally, the joint cavity may be opened, leading to sepsis and secondary OA (Weller et al. 2002). Four reported cases of septic arthritis have been unrelated to trauma (Warmerdam et al. 1997; Carmalt and Wilson 2005; Nagy and Simhofer 2006;

Perrier et al. 2010). It is possible that the signs of external trauma, such as a puncture wound, occurred at a time distant to the development of clinical signs. If the bacterial inoculation is small, the external wound may have healed before the development of sepsis. Alternatively, the joints in these cases may have become infected through the hematogenous spread of bacteria, as has been documented in other joints (Hardy 2006).

While it has never been demonstrated in a controlled study, it is plausible that the onset of equine TMJD could be related to oral pathology. May (1996) suspected an association between horses exhibiting pain on TMJ palpation and those having incisor abnormalities. Equilibration of the incisors led to resolution of the pain response, but diagnostic imaging or intraarticular anesthesia were never performed to confirm the presence of pathology. Controlled studies examining the effect of dental pathology on the equine TMJ are also limited (Carmalt et al. 2006). Human studies have shown a limited correlation between missing teeth and the development of TMJD (Johansson 2003; Bagis et al. 2012; Lamot et al. 2013). Conversely, studies in mice and rabbits have found that artificially changing the height of either the incisors or molars can quickly lead to the formation of TMJ OA (Ramirez-Yañez et al. 2004; Chen et al. 2009; Henderson et al. 2015). It is worth noting that Wintzer (1999) highlighted a case of iatrogenic TMJD in a horse, secondary to the prolonged use of a ratchet-type oral speculum under general anesthesia. This may be important, as it signifies the potential for iatrogenic trauma to the TMJ, not only during dental examinations, but through equitation as well.

The external forces placed on the TMJs by the bit and bridle, may also lead to damage of the TMJ. In their most simplistic form, the function of the reins is to provide a biomechanical advantage to a rider, allowing small, gentle movements to initiate control of the horse. However, the lever action created by the reins is also thought to be able to create substantial vector forces in both the ventral and caudal directions, possibly leading to excessive pressure on the TMJ (Clayton 1985; Geyer and Weishaupt 2006). Though this theory has yet to be tested empirically, some have been promoting the use of bitless bridles, which have been gaining in popularity (Cook 1999).

2.5 Anatomy of the temporomandibular joint:

In the horse, the TMJ can be located by tracing a line between the lateral canthus of the eye and the tragus of the ipsilateral ear. On the caudal aspect of the joint, the parotid salivary gland, as well as the maxillary artery and vein, the transverse facial branch of the auriculotemporal nerve, and the facial nerve, lie superficial to the synovial cavity. The parotidauricular muscle, temporalis muscle and masseter muscle also cover a portion of the equine TMJ (Rodriguez et al. 2006). The parotidauricular muscle extends in a vertical direction, passing over the lateral surface of the joint, while the temporalis muscle inserts on the rostromedial and medial aspects of the joint capsule and the masseter inserts on the rostromedial and lateral aspect of the capsule (Nickel et al. 1986; Getty 2001; Rodriguez et al. 2006). Deep to the TMJ are the temporohyoid joint, the stylohyoid bone, guttural pouch, external acoustic meatus of the ear, pterygoid venous plexus, and a portion of the mandibular nerve (Rosenstein et al. 2001; Weller et al. 2002; Rodriguez et al. 2006).

The TMJ is a synovial condylar joint that is bordered dorsally by the zygomatic process of the temporal bone and ventrally by the condylar process of the mandible. The mandibular condyle is ovoid in shape, being approximately three times longer in the lateromedial axis, than in the rostrocaudal axis (Nickel et al. 1986; Rodriguez et al. 2006). More accurately, the concave zygomatic process, is composed of the Articular tubercle (*Tuberculum articulare*), the Mandibular fossa (*Fossa mandibulae*), and the Retroarticular process (*Processus retroarticularis*). The convex Mandibular condyle (*Caput mandibulae*) is complementary to the zygomatic process, contacting the mandibular fossa when the mandible is at rest and moving to the articular tubercle when masticatory movements are performed. The retroarticular process limits the extent of the mandibles caudal ROM (Adams et al. 2016). However, for the purposes of this work, the composition of the zygomatic process will further be referred to as the temporal condyle.

Laying between the surfaces of each condyle is an ovoid, bi-concave, fibrocartilaginous, articular disc. The disc divides the joint space into two separate synovial pouches (May et al. 2001; Weller et al. 1999b; Weller et al. 2002; Rodriguez et al. 2006). Some of the earlier work had suggested that the disc was attached circumferentially to the articular capsule, with no visible communication between the two pouches (May et al. 2001). However, based on the diffusion of

methylene blue (injected into the dorsal pouch), Rosenstein et al. (2001) surmised that communication between the dorsal and ventral pouches exists; more recent literature also confirms communication (Rodriguez et al. 2006). On the lateral aspect, the disc is attached ventrally to the mandibular condyle; medially an attachment runs dorsally to the temporal bone. Caudomedially the disc is attached to the retroarticular space, whereas caudolaterally the disc is reported to have a fibrous expansion and a fat pad that causes the disc to be mildly “L-shaped” (Weller et al. 2002; Rodriguez et al. 2006). The normal angle of the disc to the mandibular condyle has been determined to be between 20° to 30° in the rostrocaudal axis (Rodriguez et al. 2010).

The dorsal (discotemporal) pouch is larger than the ventral (discomandibular) pouch, holding approximately 5 mL, while the latter holds less than 3 mL (May et al. 2001; Weller et al. 2002; Rodriguez et al. 2006). Each of the dorsal and ventral pouches contains a cranial and caudal outpouching, with the caudolateral pouch accounting for roughly 80% of the space of the discotemporal space (Weller et al. 2002; Rodriguez et al. 2006). A few authors have reported the presence of synovial villi in both the upper and lower compartments on arthroscopic examination, but there is some variance in their abundance and shape (Weller et al. 2002; Rodriguez et al. 2006).

Blood supply to the TMJ arises from four main arteries: transverse facial, superficial and deep temporal, and tympanic (Weller et al. 1999b; May et al. 2001; Weller et al. 2002; Rodriguez et al. 2006). The blood supply to the disc itself is more limited, however, receiving blood rostrally from the transverse facial artery and caudally from the deep temporal artery (Rodriguez et al. 2006).

Similar to the human TMJ (Schmolke 1994; Lippert 2000), the equine joint has an intraarticular neurovascular bundle, involving the masseteric branch of cranial nerve V, entering through the caudal aspect of the articular capsule and disc, travelling between the coronoid process of the mandible and mandibular caput in a rostroventral direction to the masseter (May et al. 2001; Weller et al. 2002; Rodriguez et al. 2006). The auriculopalpebral nerve is present both caudal and dorsal to the joint (Weller et al. 2002). The equine joint is reported to have two ligaments providing capsular reinforcement (Cheynet et al. 2003; Rodriguez et al. 2006). These ligaments are located on the lateral and caudal aspects of the joint (Nickel et al. 1986, Weller et al. 1999a; Sandoval and

Agüera 2000; Getty 2001; May et al. 2001; Weller et al. 2002; Rodriguez et al. 2006). The caudal ligament lies in close proximity to a portion of the facial nerve, the tympanic portion of the temporal bone, the petrotympanic fissure, and the external acoustic meatus of the ear. Barone (1980) noted a third intracapsular ligament known as the pterygomandibular ligament, located on the medial side of the joint, but more recent anatomical studies have failed to identify this structure (Rodriguez et al. 2006).

Several muscles effect movement of the TMJ, and in several instances are continuous with both the capsule and the disc. The temporalis muscle is attached to both the capsule and the disc, on the medial and rostral aspects. On the rostral aspect, a portion of the masseter muscle is attached to the capsule and the disc, but attaches only to the disc caudally. The lateral and medial pterygoid muscles also have minor attachments to the joint, with the lateral pterygoid attaching to the disc and capsule on the rostromedial side, and the medial pterygoid attaching to the capsule only (Nickel et al. 1986; Getty 2001; Rodriguez et al. 2006).

2.6 Joint movement and masticatory kinetics:

Simply stated, having bilateral TMJs allows for opening and closing of the mouth. They are responsible for the evolution of the complex 3-D cycle of mammalian mastication. The fibrocartilaginous disc serves a multitude of functions, one of which is to eliminate articular incongruences and to distribute loads on the TMJ over a larger surface area (Baker 2002; Commiso et al. 2014). In humans, it is thought that the discomandibular compartment allows for rotational movement in both the frontal and sagittal planes during opening, whereas the superior discotemporal compartment is mainly restricted to translational movement, utilized at the limits of the mandible's ROM (Ramzan 2006; Anthwal 2013). The small intracapsular ligaments attaching to the disc are thought to stabilize the disc throughout the 3-D movements of mastication (Baker 2002).

In both humans and horses, the collagen fiber orientation within joints has been established as a biomechanical adaptation to applied loads and movement (Below et al. 2002; Van Turnhout

et al. 2008; Adams et al. 2016). Through the use of split-line patterns, Adams et al. (2016) was able to analyze the architectural pattern of collagen fibers within the equine TMJ. The group showed that the central two-thirds of the articular disc, mandibular condyle, and articular tubercle, expressed a rostrocaudal fiber orientation, suggestive of movements in a rostrocaudal direction. The lateral and medial aspects of the joint, exhibited a curved fiber orientation in the dorsoventral axis, suggestive of rotational movement. Sharp changes in the direction of the split-line orientation (attractive singular points) were located within the medial and lateral aspects of the fibrocartilaginous disc which have previously been associated with points of high stress (Lieser 2003; Adams et al. 2016).

Having a greater surface area in the lateromedial direction, is thought to allow for an increased lateromedial ROM (May et al. 2001). Equids have exploited this by having mandibular condyles that are roughly three times longer lateromedially than rostrocaudally, which enables the lateromedial motion of the mandible while chewing forage (Noble 1973; Nickel et al. 1986).

Jaw opening is initiated by contraction of the digastricus, geniohyoideus, genioglossus, sternohyoideus and omohyoideus muscles and relaxation of the opposing muscle bellies; the masseter, temporalis, and pterygoideus. Contraction of the masseter and temporalis muscles closes the jaw and simultaneously pull it towards the side of contraction. As with most species, the muscle mass required to close the jaw greatly outweighs those required to open it. This is because jaw opening is gravity assisted, while closing the jaw (by mandibular elevation) works against gravity, and against the resistance of grinding feed (Baker 2002). The mandible and TMJ act biomechanically similar to a lever and fulcrum, it is suspected that the forces placed on the dental arcade can be greatly exaggerated at the level of the TMJ. A quartz crystal force plate has been used to determine the bite force applied at the triadan #06 tooth during a regular chewing cycle and found that the peak force ranged between 875 N to 1758 N (Staszuk et al. 2006). Subsequently biomechanical models have suggested that the bite force increases caudally, beginning with 141 N at the incisors and peaking at 1956 N over the triadan #311/411 (Hongo and Akimoto 2003). A subsequent study by Huthmann et al. (2009) created a model to estimate the biomechanical bite forces of the equine cheek teeth. What the group found was that bite pressure

was greatest on the caudal most cheek tooth (triadan # 111/211/311/411), with the height of the Curve of Spee acting as a potential lever, and increasing pressure on the TMJ.

At the start of the chewing cycle, the incisors grasp feed, sliding across each other, cutting material to fill the interdental space (rostral portion of the mouth). It is thought that grinding of the cheek tooth battery is only initiated when the interdental space becomes full. The cheeks help to keep feed contained within the interdental oral cavity. Upon reaching the level of the rostral most cheek tooth (triadan #06) the interdigitating lophs (ridges) and donts (troughs) allow for the grinding of feed stuffs. On gross observation, the masticatory cycle of horses creates a circular pattern. However, horses like many species, are restricted to chewing food on one side of their mouth at any one time, and as such, the active arcade (the chewing side) can be identified by the circular direction of the chewing cycle. Although the width of the mandible is less than that of the maxilla, the maxillary teeth force both arcades to come into contact at the same time, with the majority of pressure being applied to the active side. When viewing the horse from the front, a clockwise chewing pattern is thought to denote a horse that is activating the right dental arcade, known as a 'right-sided chewer'. Alternatively, a counter-clockwise pattern is considered a 'left-sided chewer' (Baker 2002; Bonin et al. 2006; Bonin et al. 2007). A study observing the masticatory movements of over 400 horses, observed the majority of horses to be right-sided chewers, with 32% being left-sided chewers, and 11% to chew on both sides (Baker 2002). For a time, it was suggested that a preferred chewing side might predispose horses to unequal attrition, but horses have the ability to choose the active side of mastication (Smyth et al. 2015).

The cyclic chewing pattern of the horse can be further dissected into three smaller phases, the opening, closing and power phase. Each cycle is then completed by a short resetting phase that allows the mandible and maxilla to return to a neutral, closed mouth position (Collinson 1994; Bonin et al. 2006; Bonin et al. 2007). Thorough 3-D mapping each of the phases of the chewing cycle have been examined (Bonin et al. 2006; Bonin et al. 2007; Smyth et al. 2015). During the opening phase, the mandible moves in the vertical and lateral planes, dropping ventrally and sliding abaxially away from the chewing side. Upon transitioning to the closing phase, the mandible reaches its vertical limit and begins reversing direction towards the maxilla. During the closing phase the mandible and the maxilla also reach their maximum offset horizontally; after

which the mandible begins sliding back towards the axial position. At the start of the power phase or “grinding phase”, the cheek teeth are approaching occlusion, moving mainly in the horizontal direction. A small amount of vertical movement is seen during the power phase, likely to maintain resistance as the feed is ground along the tooth battery. At the end of the power phase, the mandible will have moved passed the midline towards the inactive side of the mandible. Continuing movement, in the horizontal direction, allows for a greater surface area to grind feed. Both the closing phase and the power phase of the cycle are thought to be the high pressure portions of the cycle, responsible for placing the most force on the TMJ (Staszyk et al. 2006). For the duration of the cycle, there is only a small amount of movement in the rostrocaudal direction. In the opening and closing phases the mandible moves caudally and rostrally, respectively (Bonin et al. 2006; Bonin et al. 2007). There has been some suggestion that the TMJs can move independently of one another in the rostrocaudal direction during the masticatory cycle. This could theoretically be achieved by configuring the TMJ such that contraction and relaxation of the masseter and medial pterygoid muscles allows for oblique movements of the upper and lower dental arcades (Baker 2002).

The equine mouth contains 18 paired palatine ridges that are angled and slope from midline buccally, in a rostral to caudal direction (Baker 2002). It has been theorized that the tongue and the paired palatine ridges of the roof of the mouth, function in a rotary motion similar to an auger, moving the food caudally toward the oropharynx (Collinson 1994). On reaching the pharynx, constriction, elevation of the soft palate, and retraction of the epiglottis, allow movement of the food into the esophagus.

The type of feed can influence the chewing pattern (Leue 1941). Collinson (1994) showed that horses were able to chew more quickly (up to 11 cycles per second) with drier feeds or those with higher crude fiber. A previous study examining the chewing kinematics of different types of feed, found that larger chewing cycles were required for long stemmed forage as opposed to short concentrated (pelleted) ration (Bonin et al. 2007). Because the velocity of these cycles were not significantly different, it led to a reduced overall frequency. The authors reasoned that the increased lateral excursion when chewing long stem feed was due to the longer feeds being more easily contained on the occlusal surface, thereby allowing the jaw to move to its full lateral extent.

Conversely, particulate-type feeds would allow only small quantities of food to be positioned over the occlusal surface, causing movement to be more vertical in direction (Bonin et al. 2007).

It is worth noting that despite that fact that the TMJ is pivotal to the movement of the mandible, only one record of 3-D masticatory kinetics has been monitored in horses with TMJD (Smyth et al. 2015). One additional clinical study described the visual chewing motions of a horse with a septic TMJ, which had very little lateral excursion of the mandible with excessive motion dorsoventrally (Carmalt and Wilson 2005).

2.7 Pathophysiology of degenerative joint disease:

The entire body of work surrounding the pathophysiology of OA of the equine TMJ, is restricted to two studies by a single groups of authors. The first was an observational study examining the inflammatory cytokine profiles (IL-1, IL-6, IL-8, TNF- α , TGF- β 1, TGF- β 2, TGF- β 3) of horses across different ages and dental pathology scores (Carmalt et al. 2006). Using the same cytokine profiles, the second study, compared the inflammatory responses of the TMJs and metacarpophalangeal joints, following exposure to a sterile inflammatory mediator (*Escherichia coli* derived LPS; Carmalt et al. 2011).

In the first study, the group found that foals showed lower levels of IL-8 and TGF- β 1 and increased levels of TGF- β 2 than adults horses. Mature horses showed a trend toward increasing dental pathology score with age, but there was no significant correlation of any of the measured cytokines suggesting a trend toward OA (Carmalt et al. 2006).

The second study showed that the levels of total protein and Il-6 were similar between the two joints after inflammation. However, the fetlock showed an increased level of TGF- β and the TMJ showed higher levels of TNF- α . Overall, the authors concluded that the inflammatory response in the TMJs was attenuated more quickly than in the fetlocks, possibly guarding the TMJ against the development of OA, compared to other joints (Carmalt et al. 2011).

While Carmalt et al. (2011) could not find evidence to support the development of primary OA, it is interesting to note that Weller et al. (2002) reported finding the development of both filiform and conical villi of differing sizes while performing an arthroscopy of the discotemporal pouch of a TMJ of an aged horse. Rodriguez et al. (2006) did not find villi while performing an anatomical study to map the TMJ of younger horses. The findings may suggest the development of synovial hypertrophy over time due to continued wear on the joint surface. Additionally, several authors have reported a thinning of the fibrocartilaginous disc as horses age, a possible hallmark of degeneration (Weller et al. 1999b; Rodriguez et al. 2007; Rodriguez et al. 2010).

It is worth noting that the unique structure of the equine TMJ does not extend to the cytological characteristics of the synovial fluid, which have been reported to be equivalent to that of the hyaline cartilaginous joints (Fonseca et al. 2009).

2.8 Causes of TMJD:

The vast majority of equine TMJD reports have been secondary to an acute traumatic incident, often resulting in fracture of the mandibular or temporal condyles (Devine et al. 2005; Barnett et al. 2014). Though little research has been done on the subject, the traumatic events that occur in horses appear less likely to result in luxation or tearing of the fibrocartilaginous disc, than occurs in humans (Weller et al. 2002; Rodriguez et al. 2010). During these traumatic events, abrasion of the tissues surrounding the joint, commonly leads to opening of the joint capsule and development of septic arthritis. This has the potential to have lasting effects far beyond the removal of the infection. Rare cases of septic arthritis have been reported where no signs of trauma or superficial abrasion has occurred (Warmerdam et al. 1997). In these cases, it is possible that hematogenous spread of bacteria from a distant area of infection led to seeding of bacteria in the joint (Hardy and Shiroma 1991). A previous report of TMJ sepsis, cited a total nucleated cell count of 9.8×10^{10} cells/L and a total protein of 7.8 g/dL, suggesting that cytological counts in septic TMJs may be comparable to sepsis in other joints (Carmalt and Wilson 2005).

It has long been considered that oral pathology may play a role in the development of equine TMJD (May 1996; Wintzer 1999). The concept behind why dental irregularities could lead

to TMJD is mostly theoretical, as it remains largely untested. At the start of normal mastication, when incisors reach a point of contact, the molars remain apart. Movement of the mandible is initiated rostrally, followed by the phase of lateral movement, in which molar occlusion and shearing occurs. If molar malocclusion is such that the molars remain in contact at the beginning of the chewing cycle, rostral motion of the mandible will be inhibited, leading to TMJ discomfort. However, research by Carmalt et al. (2003) may not support this. By measuring the effect of dental floatation on the ROM in the equine mandible, the group was able to show that dental equilibration led to an increased ROM, in the rostrocaudal direction; there was no correlation between the ROM and the number or type of dental lesions. More recently, the same group found that horses eating with a reduced range of mandibular motion did not affect the feed digestibility, fecal particle size, or weight gain of challenged individuals (Carmalt et al. 2006). It is worth noting that a similar study by Simhofer et al. (2011) found opposite results.

May (1996) published a case series of several horses that presented with clinical signs consistent for TMJD, each of which had severe incisor abnormalities and whose clinical signs for TMJD improved following dental equilibration. It is important to note that neither diagnostic imaging nor intraarticular anesthesia were used to confirm diagnosis of TMJD in these cases. In support of this, a controlled study in rats found that artificial incisor abnormalities quickly led to abnormalities in the TMJs (Ramirez-Yañez et al. 2004). Ishimaru et al. (1994) also showed that tooth loss leading to overbite and malocclusion in sheep, also led to TMJD. A limited number of studies focusing on human TMJD, have also suspected a link between missing teeth and the formation of TMJD (Johansson et al. 2003; Bagis et al. 2012; Lamot 2013).

It has also been suggested that prolonged or excessive pressure on the TMJ can lead to degenerative disease. This has been reported in horses following the use of a ratchet type oral speculum under general anesthesia (Wintzer 1999). The direction of forces placed on the equine TMJ through the use of a bitted bridle during exercise have been well documented, but the link between biting and TMJD has never been tested (Clayton 1985; Geyer and Weishaupt 2006).

To date there has been little evidence to suggest that the formation of equine TMJD is due to anything other than trauma or sepsis. Despite being the most active joint in the body, there has

been only two reports to highlight the possibility of OA due to the regular wear and tear of normal activities (Smyth et al. 2015; Carmalt et al. 2016). As discussed previously, the equine TMJ does exhibit an inflammatory response, but appears to react with a shortened, albeit more agitated, inflammatory phase, compared that of other joints in equids (Carmalt et al. 2011). The significant difference that occurs in the inflammatory response, and by extension, the overall lack of degenerative disease found in this joint, is likely linked to the unique fibrocartilaginous disc situated in the center of the joint. It could be suggested that the lack of primary OA in the TMJ is due, in part, to its function as a non-weight-bearing joint. Though not truly weight-bearing, it is expected that the act of mastication causes these small joints to repeatedly bear forces in excess of 1900 N (Huthmann et al. 2009). It is also possible that the small amount of research in this area allows cases of primary TMJ OA to exist unidentified, or simply be misdiagnosed. Weller et al. (1999b), for example, observed a trend for articular cartilage to become thinner in aged horses on ultrasound, further noting a particular case in an aged pony, which had irregular bony proliferation on the temporal bones in each TMJ. Despite these findings, each of the horses in the study were clinically normal, showing no clinical signs of TMJD.

In other species, the condyles of the TMJ have been shown to have an ability to remodel throughout the age of the animal (Xiong et al. 2004; Owtad et al. 2013). In humans, this plasticity is known as the concept of dynamic individual occlusion, suggesting that the joint can adapt to the capacity of stresses placed upon it (Dimitroulis 2005). Given this, it is possible that the malleability of the joint to adapt to stress, precludes the formation of primary OA and the associated pain.

In the human literature, there are currently two categories of TMJ associated disorders; those directly affecting the joint (e.g, fracture, OA and ankyloses), and disorders affecting the surrounding tissues (e.g, disease of masticatory muscles or inner ear) (Ramzan 2006). In equids, it is feasible that the cases that are more difficult to diagnose, may not be directly related to the joint, but are instead originating from the surrounding soft tissues. While no cases of soft tissue disease have been connected to pain in the TMJ of horses, the presence of such would be more akin to a syndrome, than one particular disease entity.

2.9 Clinical signs:

Although only a few case reports of equine TMJD are cited in the veterinary literature, there are a plethora of clinical signs that have been attributed to the disease (Hurtig et al. 1984; Hardy and Shiroma 1991; Warmerdam et al. 1997; Weller et al. 1999a; Devine et al. 2005; Carmalt and Wilson 2005; Hardy 2006; Nagy and Simhofer 2006). Unfortunately, most of the clinical signs that accompany equine TMJD are either ambiguous or very subtle, having the potential to be caused by myriad etiologies, or entirely overlooked. The clinical signs related to TMJD are also very different from that which is expected to occur in weight-bearing joints of the limbs. As a result, the shallow depth of knowledge about this joint may leave clinicians with inadequate skills to recognize signs of disease.

One of the most common signs of equine TMJD is dysmastication, or the inability to effectively breakdown food for digestion. This is characterized by a reduced range of movement or a slower than normal chewing cycle (Hardy and Shiroma 1991; Warmerdam et al. 1997; Weller et al. 1999a; Carmalt and Wilson 2005; Devine et al. 2005; Perrier et al. 2010). In some horses dysmastication can be more severe, leading to quidding, the balling up and ejecting of partially chewed forage (Warmerdam et al. 1997; May et al. 2001; Carmalt and Wilson 2005; Ramzan 2006). During TMJD, the pain associated with mastication can lead to dysmastication, reduced food intake or even anorexia in some horses (Carmalt and Wilson 2005; Perrier et al. 2010). The preponderance of cases of TMJD presenting with secondary impaction has led to the theory that the pain of mastication may cause inadequately chewed feed bolus' to be swallowed, thereby predisposing these horses to impaction colic (Carmalt and Wilson 2005; Smyth et al. 2015). Inspection of the teeth can reveal incisor malocclusion or an inability to oppose the upper or lower incisors (Hurtig et al. 1984; Hardy and Shiroma 1991; Devine et al. 2005; Nagy and Simhofer 2006). Chronic forms of the disease can be accompanied by masseter muscle atrophy, bony proliferation or joint effusion, seen externally (Nagy and Simhofer 2006). Palpation of the effusive joints can be met with an aversion response, suggesting pain (Carmalt and Wilson 2005; Nagy and Simhofer 2006; Jørgensen et al. 2014).

Temporomandibular joint disease has also been suspected to cause behavioral issues, such as head-shaking, fighting the bit, bit chomping, sour attitude, and even gait changes or ataxia (May et al. 2001; Ramzan 2006; Barnett et al. 2014; Jørgensen et al. 2014). It has been suggested that these undesirable behavioral changes are due to the intimate anatomical proximity of the TMJ to the middle ear (Weller et al. 1999a). It is possible that the intraarticular nerve in the caudal portion of the capsule, may also play a role in this behavior. When seen secondary to trauma, the disease is typically accompanied by abrasions or facial swelling. If the joint has become septic, the horse may present with a fistulous draining tract (Warmerdam et al. 1997; Devine et al. 2005; Nagy and Simhofer 2006; Perrier et al. 2010; Barnett et al. 2014).

2.10 Diagnostic testing:

2.10.1 Arthrocentesis

Reaching a diagnosis of equine TMJD is not unlike the approach to disease in any other equine joint. Intraarticular administration of local anesthetic should lead to improvement or resolution of clinical signs. In cases of sepsis, prior to the administration of the local anesthetic, centesis should be performed to obtain synovial fluid for cytologic analysis and culture (Carmalt and Wilson 2005; Carmalt 2014; Jørgensen et al. 2014).

Entrance into the equine TMJ is most commonly performed using a 20-gauge needle, inserted rostroventrally at 45° to the transverse plane and 45° to the surface of the skin (Rosenstein et al. 2001). This allows 5 to 10 mL of local anesthetic to be administered directly into the caudal pouch of the discotemporal joint. Current research suggests that both the upper and lower synovial pouches communicate (Weller et al. 2002; Rodriguez et al. 2006).

When blocking the TMJ with local anesthetic, one must be cognizant that there is currently no literature to determine how far the local anesthetic will diffuse, or exactly what structures will be affected (Schumacher 2006). It is possible that middle ear disease or temporohyoid osteoarthropathy may present with similar signs to TMJD, such as dysmastication, ataxia and head-

shaking. The intimate relationship between these structures and the TMJ could potentially lead to a misdiagnosis if diffusion of local anesthetic occurs, making supplemental diagnostic tests necessary (Carmalt 2015).

2.10.2 Diagnostic imaging

Several modalities have been employed in an attempt to adequately image the equine TMJ, each having unique advantages and drawbacks. Perhaps the least expensive and most widely available method is radiography. However, interpretation of radiographic imaging of the head is notoriously difficult. Superimposition of adjacent bony structures not only makes diagnosis challenging, but repeatable positioning of the beam angle is unreliable (Weller et al. 1999a; Ramzan 2008; Townsend et al. 2009). In an effort to minimize the degree of superimposition of the TMJ, two groups have developed novel, yet similar, radiographic projections (Ebling et al. 2009; Townsend et al. 2009). Using a 70° tangential-caudodorsal to rostroventral radiographic projection, one group was able to image the lateral half of the TMJ free of superimposition. The group noted that the most common superimposition artifact during this view arose from the pinna of the ear, which increased in occurrence with angles less than 70°; angles steeper than 70° had less superimposition, but greater angular distortion (Townsend et al. 2009). The other group used CT images to discern a projection of rostral 45° ventral-caudodorsal oblique view. Of the six horses imaged in the study, three showed radiographic abnormalities in one of the two joints (Ebling et al. 2009). Radiography has been reported to confirm TMJ luxation, as well as bone lysis and proliferation, in clinical cases (Hurtig et al. 1984).

Another readily available imaging technique is ultrasound (Weller et al. 1999b; Rodriguez et al. 2007). First described by Weller et al. (1999b), ultrasound was used to image the lateral aspect of the joint, including the joint capsule articular disc, joint spaces, articular cartilage and bone surface. It was noted that the small pterygoid ligaments and joint fluid were not visible. In cases of TMJD, ultrasound has been used to establish the presence of osteomyelitis, bone necrosis, narrowed joint space, and disc luxation (Weller et al. 1999b). On ultrasound, the articular cartilage appears hypoechoic. The disc appears as a triangular structure which is thick caudally and becomes

thinner rostrally. Although a case of primary OA has never been published, the authors did notice a trend for articular cartilage to become thinner in aged horses (Weller et al. 1999b). The allure of ultrasound for diagnosing TMJD is that it is widely available in most practices and quick to perform. The drawback, however, is that the required technique can be difficult to perfect, making routine use challenging. Lastly, the structures on the medial side of the joint cannot be seen by ultrasound, potentially leaving the modality with inconclusive results.

Computed tomography has been shown to provide excellent detail for bony structures, but is less useful for surrounding soft tissues. The inability to clearly image soft tissues is likely due to the difference in density between the soft tissues and bony structures, especially the petrous temporal bone. Due to its high cost, CT is often inconvenient for many private practitioners, usually limiting this type of diagnostic methodology to large referral centers. Additionally, the time involved in transport and the cost of diagnosis using CT may also deter owners. Until recently, equine CT also required the use of general anesthesia to attain adequate images but an increasing number of centers now have standing CT capability.

The anatomy of the equine TMJ has been described using CT. One millimeter slices from the rostral aspect of the zygomatic process, to the caudal aspect of the occipital condyles of the head were used. The majority of soft tissue structures, such as the major masticatory muscles, superficial and temporal artery and vein, transverse facial vessels and also the major nerves (facial, mandibular and masseteric) were identified. Smaller structures were also imaged, including the caudal expansion of the articular disc, and both the ventral and dorsal joint pouches. Like ultrasound, the caudal ligament of the articular capsule was not visualized. The denser cartilage and bone structures were easily seen, the articular cartilage appearing as a hyperattenuated band over the low attenuation of the subchondral bone. Computed tomography has been successfully used to aid in the diagnosis of a few reported cases of equine TMJD (Warmerdam et al. 1997; Devine et al. 2005; Nagy and Simhofer 2006). One case in particular highlighted the diagnostic advantages of CT over radiography, where no abnormalities could be identified radiographically, but marked osseous changes were seen on CT (Nagy and Simhofer 2006).

Nuclear scintigraphy has rarely been used as a method for determining TMJD in equids. While highly sensitive, it lacks the specificity to characterize pathology in this small joint (Weller et al. 1999b, Weller et al. 2001). In addition, the normal TMJ has a tendency to have increased radiopharmaceutical uptake, and the close proximity of the hyoid apparatus and the middle ear, can potentially skew its diagnostic ability (Dyson et al. 2003).

Magnetic resonance imaging is generally regarded as the gold standard for diagnostic imaging of the TMJ of both humans and horses. In humans, MRI has been shown to be up to 82% sensitive and 98% specific in the detection of osseous changes of the TMJ (Alkhader et al. 2010). While mapping the equine TMJ, Rodriguez et al. (2010) established that views from the oblique and transverse planes were the most anatomically revealing, and should be a requirement for diagnosis. Spin echo T1 weighted sequences resulted in the best anatomic detail and spatial resolution. Whereas T2* and fat suppression sequences revealed the highest contrast of structures like the fibrocartilaginous disk, synovial fluid, synovial pouches and articular cartilage. These researchers also noted that the thickness of articular cartilage was increased in immature animals when compared to their mature counterparts; a finding identical to that of Weller et al. (1999a).

Arthroscopy is singular in its ability to bridge the gap between diagnostic imaging and therapeutic treatment; through debridement and the removal of possible adhesions (Nagy and Simhofer 2006). Unfortunately, the small joint size often limits both observation and the use of instruments (Weller et al. 2002; Carmalt and Wilson 2005). Typically, this is performed by entering through a caudodorsal approach similar to the one described earlier for centesis. A 20-gauge needle can be used to distend the joint with sterile saline (8 to 12 mL). A 1 cm incision into the joint is made at the most prominent outpouching of the joint space; a 4 mm, 30° angled scope is inserted. Arthroscopy of the equine TMJ can be used to assess both the rostral and caudal synovial pouches of the discotemporal space, but is mostly limited to the lateral aspect of the joint. A small portion of the medial aspect of the joint can be observed at the most rostral and caudal reaches of each pouch. It has been noted that translational movement of the mandible away from the surgeon can cause joint distraction and improved visualization, but instrument access remains a problem. Using a probe to separate the joint space is not recommended as it can lead to marked cartilage damage (Weller et al. 2002). The use of a wedge in the caudal molars can however lead

to distraction and improved observation in the joint space (Weller et al. 2002). So far, entry into the discomandibular space has been less common (Weller et al. 2002). Due to the small space and close proximity to the facial artery and vein, some authors elect not to explore the lower joint space (Carmalt and Wilson 2005). It is possible that a smaller, 2 mm arthroscope may be more successful in gaining access to the discomandibular pouch, but this has yet to be reported. A commonly reported complication of this procedure is puncture through the parotid salivary gland, as well as iatrogenic damage to the articular disc upon entry (Weller et al. 1999a; Carmalt and Wilson 2005).

2.11 Treatment:

The treatment of equine TMJD is highly dependent on the inciting cause. In cases of sepsis, the bacterial isolates common to environmental or resident skin flora (*Staphylococcus aureus*, *Escherichia coli*, *Streptococcus epidemicus*, *Proteus mirabilis*, and *Clostridium* species) have been isolated. While some of these cases have been treated successfully with intraarticular antibiotics, systemic antibiotics, or both (penicillin, potentiated sulfonamides, tetracycline, pivampicillin and gentamycin), many clinicians have elected to flush the joint (Weller et al. 1999a; Carmalt and Wilson 2005). Recently, surgical arthroscopy has been used to assess the joint surface and remove visible adhesions or foreign material (Warmerdam et al. 1997; Carmalt and Wilson 2005).

In cases of sepsis without fracture, arthroscopy can provide a much less invasive alternative to condylectomy. Following arthroscopic lavage of a septic TMJ, the few reported cases have recovered well, appearing comfortable and symptom free within a year after surgery (Warmerdam et al. 1997; Carmalt and Wilson 2005). When joint associated fracture or bony ankylosis of the TMJ is present, a more aggressive surgical intervention is warranted. This includes arthrotomy of the joint, with either removal of the fibrocartilaginous disc alone, or in combination with removal of the fractured condyle (condylectomy) (Hurtig et al. 1984; Devine et al 2005; Nagy and Simhofer 2006; Bienert-Zeit and Rötting 2011; Barnett et al. 2014). When an acute traumatic fracture has occurred, conservative management can lead to the development of bony ankylosis, limiting the horse's capacity for normal mastication (Nagy and Simhofer 2006). Following meniscectomy or condylectomy, the development of a pseudoarthrosis has been documented, which is considered

relatively pain free as the horses are without obvious clinical problems (Devine et al. 2005; Nagy and Simhofer 2006). Horses undergoing unilateral condylectomy appear to have a much better prognosis for return to comfort than those requiring bilateral condylectomy (Hurtig et al. 1984). Transection of the auriculopalpebral nerve during surgery of the TMJ has been reported as a possible complication (Warmerdam et al. 1997).

While no research has been performed to prove their efficacy in the TMJ, in cases of non-septic arthritis, the use of intraarticular injections of chondroprotectants (hyaluronic acid) and corticosteroids (triamcinolone), may be beneficial in reducing clinical signs of disease (Schumacher 2006; Jørgensen et al. 2014).

If dental abnormalities are suspected as the cause of pain in the TMJ, regular dental equilibration, as well as dietary changes (shorter, less fibrous feeds), may be indicated (May 1996, Bonin et al. 2006; Bonin et al. 2007). It is possible that reducing the tooth height at the Curve of Spee, may reduce the pressure placed on the TMJ but this hypothesis has never been tested (Huthmann et al. 2009). A single report of TMJ luxation was successfully corrected through the use of manual manipulation under general anesthesia. Through the use of the interdental mouth gag, pressure was applied to the rostral maxilla and mandible, acting as a lever and sliding the joint back into correct alignment (Hardy and Shiroma 1991).

2.12 Summary:

A lack of knowledge concerning the equine TMJ, including its unique anatomy, and complex function, continue to make the equine TMJ a mystery. Research suggests that inflammatory processes do occur within the TMJ but that the inflammatory profiles appear unique to the TMJ and may confer a degree of resistance to degenerative disease. However, the handful of existing case reports, which highlight severe advanced stages of equine TMJD, suggests that the end result of equine TMJ inflammation is not dissimilar to that which occurs in other joints. The majority of these cases are secondary to trauma involving fracture or sepsis. While some

evidence suggests that age-related changes do occur, definitive diagnoses occurring in the absence of trauma have yet to be reported.

As the function of this small joint is drastically different from that of the other joints in the body, it is logical to consider that the clinical signs accompanying TMJ disease may also be significantly different. These differences may be compounded by a lack of training by horse owners and veterinarians to recognize the presence of disease. When clinical signs are recognized, they may be very subtle or non-specific to the TMJ. The close proximity of other vital structures, such as the hyoid apparatus and middle ear, make localization of the clinical signs difficult. Additionally, the superimposition of these anatomical structures during imaging, can make the more common modalities insufficient for diagnosis, leading to an increased time investment and cost.

Currently, the few reported cases of the treatment of equine TMJD have been restricted to horses presenting with debilitating end stage disease, most of which require invasive surgery to correct the problem. Though initial treatment protocols appear efficacious and lead to a good prognosis, therapy has been based largely on extrapolation from the results achieved in other synovial joints. So far, the ability to recognize and treat anything other than end-stage disease in the TMJ, is largely limited by our lack of knowledge surrounding this subject.

The lack of evidence to support clinical signs of pain, or age-related change of this joint, is intriguing. If age-related OA does not exist in the equine TMJ it would be a singular finding, and one that may shed light on the treatment of OA in other synovial joints. As such, the objectives of this thesis are two-fold: (1) to determine whether disease states of this joint effect the biomechanics of mastication; (2) to further characterize the process of the equine TMJD, by determining if a histologic component of primary OA or age-related change exists within the joint.

2.13 References:

Adams, K., Schulz-Kornas, E., Arzi, B. et al. (2016) Functional anatomy of the equine temporomandibular joint: Collagen fiber texture of the articular surface. *The Vet Journal*. 217, 58-64.

Alkhader, M., Ohbayashi, N., Tetsumura, T. et al. (2010) Diagnostic performance of magnetic resonance imaging for detecting osseous abnormalities of the temporomandibular joint and its correlation with cone beam computed tomography. *Dentomaxillofacial rad*. 39, 270-276.

Anthwal, N., Joshi, L., Tucker, A.S. (2013) Evolution of the mammalian middle ear and jaw: adaptations and novel structures. *J Anat*. 222, 147-160.

Arzi, B., Murphy, M.K., Leale, D.M. et al. (2015) The temporomandibular joint of California sea lions (*Zalophus californianus*): Part1- Characterization in health and disease. *Arc Oral Biol*. 60, 208-215.

Arzi, B., Cissell, D.D., Verstraete, F.J.M. et al. (2013) Computed tomographic findings in dogs and cats with temporomandibular joint disorders: 58 cases (2006-2011). *J Am Vet Assoc*. 242, 69-75.

Bagis, B., Ayaz, E.A., Turgut, S. et al. (2012) Gender difference in prevalence and Symptoms of temporomandibular joint disorders: A retrospective study on 243 consecutive patients. *Int J Med Sci*. 9, 539-544.

Baker, G.J. (2002) Equine temporomandibular joints (TMJ): Morphology, function, and clinical disease. *Proc Am Assoc Equine Pract*. 48, 442-447.

Barnett, T.P., Powell, S.E., Head, M.J. et al. (2014) Partial mandibular condylectomy and temporal bone resection for chronic, destructive, septic arthritis of the temporomandibular joint in a horse. *Equine Vet Educ*. 26, 59-63.

Barone, R. (1980) Articulations de la tete. Muscles masticateurs. In:Anatomie Comparee des Mammiferes Domestiques, Arthrologie et Miologie, Vigot, Paris. 2, 28-34, 467-476.

Below, S., Arnoczky S., Dodds, J. (2002) The split-line pattern of the distal femur: A consideration in the orientation of autologous cartilage grafts. *Arthroscopy*. 18, 613-617.

Bienert-Zeit, A. and Rötting, A. (2011) Unilateral mandibular condylectomy in an adult warmblood gelding. *Pferdheilkunde*. 27, 231-236.

Bonin, S.J., Clayton, M.S., Lanovaz, J.L., et al. (2006) Kinematics of the equine temporomandibular joint. *Am J Vet Res*. 67, 423-428.

Bonin, S.J., Clayton, M.S., Lanovaz, J.L. (2007) Comparison of mandibular motion in horses chewing hay and pellets. *Equine Vet J*. 39, 258-262.

Carmalt, J.L. (2014). Equine temporomandibular joint (TMJ) disease: Fact or fiction. *Equine Vet Educ*. 26, 64-65.

Carmalt, J.L. (2015) Equine temporomandibular joint (TMJ) disease: Professional polarity and caregiver bias. *Equine Vet Educ*. 27, 11-132.

Carmalt, J.L. and Allen, A.L. (2006) Effect of rostrocaudal mobility of the mandible on feed digestibility and fecal particle size in horses. *J Am Vet Assoc*. 229, 1275-1278.

Carmalt, J.L., Bell, C.D., Tatarski, D.M. et al. (2011) Comparison of the response to experimentally induced short-term inflammation in the temporomandibular and metacarpophalangeal joints of horses. *Am J Vet Res*. 72, 1586-1591.

Carmalt, J.L., Gordon, J.R., Allen, A.L. (2006) Temporomandibular joint cytokine profiles in the horse. *J Vet Dent*. 23, 81-86.

Carmalt, J.L., Kneiss, S., Rawlinson, J.E. et al. (2016) Computed tomographic appearance of the temporomandibular joint in 1018 asymptomatic horses: A multi-institution study. *Vet Rad Ultra*. 57, 237-245.

Carmalt, J.L., Townsend, H.G.G., Allen, A.L. (2003) Effect of dental floating on the rostrocaudal mobility of the mandible of horses. *J Am Vet Med Assoc*. 223, 666-669.

Carmalt, J.L. and Wilson, D.G. (2005) Arthroscopic treatment of temporomandibular joint sepsis in a horse. *Vet Surg*. 34, 55-58.

Cheyne, F., Guyot, L., Richard, O. (2003) Discomalleolar and malleomandibular ligaments: anatomical study and clinical applications. *Surg Radiol Anat*. 25, 152-157.

Chen, J., Sorensen, K.P., Gupta, T. (2009) Altered functional loading causes differential effects in the subchondral bone and condylar cartilage in the temporomandibular joint from young mice. *Osteoarth Cart*. 17, 354-361.

Clayton H.M. (1985) A fluoroscopic study of the position and action of different bits in the horse's mouth. *Equine Vet J*. 5, 68-77.

Collinson, M. (1994) Food Processing and Digestibility in Horses (*Equus caballus*). BSc dissertation, Monash University, Diss.

Commisso, M.S., Martinez-reina, J., Ojeda, J. (2014). Finite element analysis of the human mastication cycle. *J Mech Behav Biomed Mat*. 41, 23-35.

Cook, R.W. (1999) Pathophysiology of bit control in the horse. *J. Equine. Vet. Sci*. 19, 196-204.

Devine, D.V., Moll, D.H., Bahr, R.J. et al. (2005) Fracture, luxation, and chronic septic arthritis of the temporomandibular joint in a juvenile horse. *J Vet Dent*. 22, 96-99.

Dimitroulis, G. (2005) The prevalence of osteoarthritis in cases of advanced internal derangement of the Temporomandibular Joint: a clinical, surgical and histological study. *Int J Oral Max Surg.* 34, 345-349.

Dyson, S.J., Pilsworth, R.C., Twardock, A.R. (2003) *Equine Scintigraphy*. Equine veterinary Journal Ltd. 351 Exning road, Newmarket, Suffolk CB8 0AU, UK. Chapter 5 pp 225.

Ebling, A.J., McKnight, A.L., Seiler, G., et al. (2009) A complimentary radiographic projection of the equine temporomandibular joint. *Vet Rad Ultra.* 50, 385-391.

Embree, M.C., Kilts, T.M., Ono, M., et al. (2010) Biglycan fibromodulin have essential roles in regulating chondrogenesis and extracellular matrix turnover in TMJ osteoarthritis. *Am J Path.* 176, 812-826.

Fonseca, F.A., Zambrano, R.O., Dias, G.M.B. et al. (2009) Physical, biochemical and cytological characteristics of the equine temporomandibular joint synovial fluid. *Pesq Vet Bras.* 29, 829-833.

Getty R. (2001) Osteologia, sindesmologia y miologia de los equinos. In: *sissin y Grossman's Anatomia de los Animales Domesticos*, Masson S.A., Barcelona. Vol. 1, 5th edn. pp 357-359, 420-434.

Geyer, H. and Weishaupt, M.A. (2006) The influence of the rein and bit on the movements of the horse; anatomical-functional considerations. *Pherdheilkunde.* 22, 597-600.

Goulet, J.P., Lavigne, G.J., Lund, J.P. (1995) Jaw pain prevalence among French-speaking Canadians in Quebec and related symptoms of temporomandibular disorders. *J Dent Res.* 74, 1738-1744.

Hardy, J. (2006) Etiology diagnosis, and treatment of septic arthritis, and osteomyelitis in foals. *Clin Tech Equine Pract.* 5, 309-317.

Hardy, J. and Shiroma, J. (1991) What is your diagnosis? Rostral luxation of the right temporomandibular joint. *J Am Vet Med Ass.* 198, 1663-1664.

Henderson, S.E., Lowe, J.R., Tudares, M.A. et al. (2015) Temporomandibular joint fibrocartilage degeneration from unilateral dental splints. *Arc Oral Bio.* 60, 1-11.

Hinton, R.J. (2014) Genes that regulate morphogenesis and growth of the temporomandibular joint: A review. *Dev Dynamics.* 243, 864-874.

Hongo, A. and Akimoto, M. (2003) The role of incisors in selective grazing by cattle and horses. *J Ag Sci.* 140, 469-477.

Hurtig, M.B., Barber, S.M., Farrow, C.S. (1984) Temporomandibular joint luxation in a horse. *J Am Vet Med Assoc.* 185, 78–80.

Huthmann, S., Staszky, C., Jacob, H. (2009) Biomechanical evaluation of the equine masticatory action: Calculations of the masticatory forces occurring on the cheek tooth battery. *J Biomech.* 42, 67-70.

Ikeda, Y., Yonemitsu, I., Takei, M. et al. (2014) Mechanical loading leads to osteoarthritis-like change in the hypofunctional temporomandibular joint in rats. *Arc Oral Bio.* 59, 1368-1376.

Ishimaru, J., Handa, Y., Kurita, K. et al. (1994) The effect of occlusal loss on normal and pathological temporomandibular joints: an animal study. *J Cran Surg.* 22, 95-102.

Lamot, U., Strojjan, P., Surlan, P. et al (2013) Magnetic resonance imaging of temporomandibular joint dysfunction-correlation with clinical symptoms, age, gender. *J Oral Maxillofac Radiol.* 116, 258-263.

Leue, G. (1941) Beziehungen zwischen Zahnanomalien und Verdauungsstörungen beim Pferd unter Heranziehung von Kaubildern. PhD dissertation, University of Hannover.

Lippert, H. (2000) Cabeza II y Cuello. Dentadura y articulación temporomandibular. In: Anatomía. Estructuray Morfología del Cuerpo Humano, Editions Marbán S.L., Madrid. 4th edn. pp 509-511, 551-554.

Lieser, B. (2003) Morphologische und biomechanische eigenschaften des Hüftgelenks (Articulato coxae) de hundes (Canis familiaris)[thesis]. Doctor of Veterinary Medicine, University of Munich.

Johansson, A. (2003) Gender difference in symptoms related to temporomandibular disorders in a population of 50-year-old-subjects. J Oro Pain. 17, 29-35.

Jørgensen, E., Christopherson, M.T., Kristoffersen, M. (2014) Does temporomandibular joint pathology affect performance in an equine athlete? Equine Vet Educ. 27, 126-130.

McDonald, M., Vapniarsky-Arzi, N., Verstraete, F.J.M. et al. (2015) Characterization of the temporomandibular joint of the harbor porpoise (phocena phocena) and risso's dolphin (grampus griseus). Arch Oral Bio. 60, 582-592.

Macfarlane, T.V., Blinkhorn, A.S., Davies, R.M. et al. (2002) Oro-facial pain in the community: Prevalence and associated impact. Comm Dent Oral Epidemiol. 30, 52-60.

May, K.A., Moll, H.D., Howard, R.D. (2001) Arthroscopic anatomy of the equine temporomandibular joint. Vet Surg. 30, 564-571.

May, K.J. (1996) Incisor problems that may result in inflammation of the temporomandibular joint. Pferdeheilkunde. 12, 716.

Moll, H.D. and May K.A. (2002) A review of conditions of the equine temporomandibular joint. Proc Am Assoc Eq Pract. 48, 240-243.

Murphy, M.K, Arzi, B., Vapniarsky-Arzi, N. et al. (2013) Characterization of Degenerative Changes in the Temporomandibular Joint of the Bengal Tiger (*Panthera tigris tigris*) and Siberian Tiger (*Panthera tigris altaica*). *J Comp Path.* 149, 495-502.

Nagy, A.D. and Simhofer, H. (2006) Mandibular condylectomy and meniscectomy for the treatment of septic temporomandibular joint arthritis in a horse. *Vet Surg.* 35, 663-668.

Nickel, R., Schummer, A., Seiferle, E. (1986). Articulations of the bones of the head. Muscles of the mastication and superficial mandibular muscles. In: *The anatomy of the Domestic Animals: The Locomotor System*, Verlag Paul Parey, Berlin and Hamburg. Vol. 1, 5th edn. pp 172-173, 257.

Noble, H.W. (1973) Comparative functional anatomy of temporomandibular joint. *Oral Sci Rev.* 2, 3-28.

Ögütçen-Toller, M. (1995) The morphogenesis of the human discomalleolar and sphenomandibular ligaments. *J Craniomaxillofac Surg.* 23, 42–46.

Ögütçen-Toller, M., Keskin, M. (2000) Computerized 3-dimensional study of the embryologic development of the human masticatory muscles and temporomandibular joint. *J Oral Maxillo Surg.* 58, 1381-1386.

Owtad, P., Park, J.H., Shen, G. et al. (2013) The Biology of TMJ Growth Modification: A Review. *J Dent Res.* 92, 315-321.

Pow, E.H.N., Leung, K.C.M., McMillan, A.S. (2001) Prevalence of symptoms associated with temporomandibular disorders in Hong Kong Chinese. *J Orofacial pain.* 15, 228-234.

Perrier, M., Schwarz, T., Gonzalez, O. et al. (2010) Squamous cell carcinoma invading the right temporomandibular joint in a Belgian mare. *Can Vet J.* 51, 885-887.

Quick, J.S. and Warren-Smith, A.K. (2009) Preliminary investigations of horses' (*Equus caballus*) responses to different bridles during foundation training. *J Vet Behav.* 4, 169-176.

Rafalelyan, S., Radlanski, R.J., Minden, K. et al. (2015) Histomorphometry in antigen-induced arthritis of the rabbit temporomandibular joint. *J. Oral Pathol Med.* 44, 67-74.

Ramirez-Yañez, G.O., Daley, T.J., Symons, A.L. et al. (2004) Incisor disocclusion in rats affects mandibular condylar cartilage at the cellular level. *Arch Oral Bio.* 49, 393-400.

Ramzan, P.H.L. (2006) The temporomandibular joint: component of clinical complexity. *Equine Vet J.* 38, 102-104.

Rodriguez, M.J., Agut, A., Gil, F. et al. (2006) Anatomy of the Equine temporomandibular joint: Study by gross dissection, vascular injection and section. *Equine Vet J.* 2, 143-147.

Rodriguez, M.J., Latorre, R., Lopez-Albors, O. (2008) Computed tomographic anatomy of the temporomandibular joint in the young horse. *Equine Vet J.* 40, 566-571.

Rodriguez, M.J., Soler, M., Latorre, R. (2007) Ultrasonographic anatomy of the temporomandibular joint in healthy pure-bred Spanish horses. *Vet Rad Ultra.* 48, 149-154.

Rodriguez, M.J., Agut, A., Soler, M. (2010) Magnetic resonance imaging of the equine temporomandibular joint anatomy. *Equine Vet J.* 42, 200-207.

Rodriguez-Vazquez, J.F., Merida-Velasco, J.R., Merida-Velasco, J.A., et al. (1997) Development of Meckel's cartilage in the symphyseal region in man. *Anat Rec.* 249, 249–254.

Rosenstein, S., Bullock, F., Ocello, J. et al. (2001) Arthrocentesis of the temporomandibular joint in adult horses. *Am J Vet Anat.* 62, 729-735.

Sandova, J. and Agüera, E. (Eds). 1999. Cabeza y cuello. Cavidad bucal. Estructuras orgánicas del tránsito cervicofacial. In: Anatomía Aplicada Veterinaria del Caballo. Editions Harcourt Brace Publishers, International Division Iberoamericana, Madrid. pp 24-26, 41-43.

Schmolke, C. (1994) The relationship between the temporomandibular joint capsule, articular disc and jaw muscles. *J Anat.* 184, 335-345.

Schumacher, J. (2006) The equine temporomandibular joint. Published in IVIS with permission of Proc Am Assoc Eq Pract. IN. USA.

Simhofer, H., Niederl, M., Anen, C. et al. (2011) Kinematic analysis of equine masticatory movements: Comparison before and after routine dental treatment. *The Vet Journal.* 190, 49-54.

Smyth, T.T., Allen, A.L., Carmalt, J.L. (2015) Clinically significant, non-traumatic, degenerative joint disease of the temporomandibular joint in a horse. *Equine Vet Educ.* 48, 523-7.

Smyth, T.T., Carmalt, J.L., Treen, T.T. et al. (2015) The effect of acute unilateral inflammation of the equine temporomandibular joint on the kinematics of mastication. *Equine Vet J.* 48, 523-527.

Staszuk, C., Lehmann, F., Bienert, A. (2006) Measurement of masticatory forces in the horse. *Pferdeheilkunde.* 22, 12-16.

Townsend, N.B., Cotton, J.C., Barakzai, S.Z. (2009) A tangential radiographic projection for investigation of the equine temporomandibular joint. *Vet Surg.* 38, 601-606.

Wang, J., Chao, Y., Wan, Q. et al. (2008) The possible role of estrogen in the incidence of temporomandibular disorders. *Medical Hypotheses.* 71, 564-567.

Wang, Y., Liu, C., Rohr, J. et al. (2011) Tissue interaction is required for glenoid fossa development during temporomandibular joint formation. *Dev Dyn.* 240, 2466–2473.

Warmerdam, E.P.L., Klein, W.R., Van Herpen, B.P.J.M. (1997) Infectious temporomandibular joint disease in the horse: computed tomographic diagnosis and treatment of two cases. *Vet Rec.* 141, 172-174.

Weller, R., Cauvin, E.R., Bowen, I.M. (1999a) Comparison of radiography, scintigraphy and ultrasonography in the diagnosis of a case of temporomandibular joint arthropathy in a horse. *Vet Rec.* 144, 377-379.

Weller, R., Maierl, J., Bowen, I.M., et al. (2002) The arthroscopic approach and intra-articular anatomy of the equine temporomandibular joint. *Equine Vet J.* 34, 421-424.

Weller, R., Taylor, S., Maierl, J. (1999b) Ultrasonographic anatomy of the temporomandibular joint. *Equine Vet J.* 31, 529-532.

Wintzer, H.J. (1999) *Krankheiten des Pferdes*. 3rd edn., Blackwell Wissenschaften, Berlin.

Van Turnhout, M.C., Haazelager M.B., Gijzen, M.A.L. (2008) Quantitative description of the collagen structure in the articular cartilage of the young and adult equine distal metacarpus. *Animal Biology.* 58, 353-370.

Xiong, H., Hagg, U., Tang, G.H. et al. (2004) The effect of continuous bite-jumping in adult rats: a morphological study. *Angle Orthod* 74: 86-92.

Yamaki, Y., Tsuchikawa, K., Nagasawa, T. (2005) Embryological study of the development of the rat temporomandibular joint: highlighting the development of the glenoid fossa. *Odontology.* 93, 30-34.

Zambrano, R.S., Fonseca, F.A., Moraes, J.M. (2009) Physical, biochemical and cytological characteristics of the equine temporomandibular joint synovial fluid. *Pesq Vet Bras.* 29, 829-833.

CHAPTER 3: CLINICALLY SIGNIFIGANT, NON-TRAUMATIC, DEGENERATIVE JOINT DISEASE OF THE TEPROMANDIBULAR JOINTS IN A HORSE

This chapter represents a prelude to the main thesis, offering a report of bilateral, non-traumatic, non-septic, synovitis and OA of the equine TMJ, manifesting as TMJD. While theorized to exist, this form of disease has never been reported in a scholarly fashion. This demonstrates that the cause of equine TMJD is likely multifactorial but also highlights the lack of knowledge that surrounds pathophysiology of equine TMJ.

Copyright statement: Chapter 3 has been published and is reproduced here with the permission of the copyright owner (Equine Veterinary Education).

Full citation: Smyth, T.T, Allen, A.L., Carmalt, J.L. (2017) Clinically significant, non-traumatic, degenerative joint disease of the temporomandibular joints in a horse. *Equine Vet Educ.* 29, 72-77.

Author contributions: Carmalt was responsible for clinical examination and work up of the case. Allen performed the histologic examination of the TMJs. Smyth and Carmalt completed the write-up of the case report.

CHAPTER 3: CLINICALLY SIGNIFICANT, NON-TRAUMATIC, DEGENERATIVE JOINT DISEASE OF THE TEMPOROMANDIBULAR JOINTS IN A HORSE

T. Smyth, BSc, DVM[†], A. L. Allen, DVM, MVetSc, PhD[‡]

and J. L. Carmalt, VetMB, MVetSc, FRCVS, DABVP, DAVDC, DACVS, DACVSMR[†]

Institutional affiliations: [†]Department of Large Animal Clinical Sciences, Western College of Veterinary Medicine, University of Saskatchewan; and [‡]Department of Veterinary Pathology, Western College of Veterinary Medicine, University of Saskatchewan, Saskatoon, Saskatchewan.

Source of funding: No sources of funding were provided for this project.

Authors' declaration of interests: No conflicts of interest have been declared.

Ethical animal research: No ethical review was required as this is a case study. The owners of the horse indicated that they hoped that something could be learned from this case.

3.1 Abstract:

Horses with DJD of the TMJ, also known as TMJD, have been reported infrequently, with the majority of cases describing the disease as a consequence of an earlier traumatic event. A case of clinically significant TMJD due to a non-traumatic event has not been published. This retrospective case report describes a case of bilateral, DJD of the TMJ. Case management, subsequent review and interpretation of the clinical records, tangential radiographic views of each TMJ, CT and MRI of the head, and post-mortem histologic examination of the TMJs were performed. The horse exhibited both quidding and a ‘clicking’ sound during mastication; episodes of intermittent colic were also prevalent in the horse’s history. Computed tomography illustrated bilateral mineralization of the rostral aspect of both intraarticular discs. Treatment, by intraarticular injection of corticosteroid, resulted in temporary resolution of both the quidding and the ‘clicking’ sound, as well as the recurrent episodes of colic. Repeated treatment over time was required. Ultimately the horse was subjected to euthanasia for reasons other than disease of the TMJ. The development of TMJD may not be confined to traumatic events. Age-related degeneration of this joint may occur and manifest through quidding and abnormal sounds noted during mastication.

3.2 Introduction:

Degenerative joint disease or OA of the equine TMJ is an infrequently recognized and studied condition. The cause and clinical significance of TMJD have yet to be fully understood. Due to the non-descript signs, it is possible that cases of TMJD are either missed or incorrectly diagnosed (May et al. 2001; Rodriguez et al. 2010). The diagnostic methods of choice for this nebulous disease include physical examination, palpation, arthrocentesis, and medical imaging, for which only the latter two have been consistently reported as generating useful diagnostic information. Clinical presentations include problems during mastication (dysphagia, or quidding, i.e. dropping food from the mouth), behavioural issues such as fighting the bit or changes in head carriage, and occasionally head-shaking (Warmerdam et al. 1997; Weller et al. 1999a,b; May et al. 2001; Moll and May 2002; Carmalt and Wilson 2005; Devine et al. 2005; Barnett et al. 2014; Jørgensen et al. 2014). Long-standing cases may develop atrophy of the masseter muscles, bony

enlargement of the TMJ, weight loss and dental malocclusions (Baker 2002; Nagy and Simhofer 2006). The small size of the joint space and the complexity of overlapping anatomic structures in the equine head can complicate the interpretation of radiographs of the TMJ (Wyn-Jones 1985). As such, newer (tangential and rostral 45° ventral-caudodorsal oblique), projections of this region have recently been described (Ramzan et al. 2008; Ebling et al. 2009; Townsend et al. 2009). Even with these new techniques, the incident angle will have to be perfect to enable visualization of small, but possibly important irregularities in the joint due to its undulant surface (Rodriguez et al. 2010). Ultrasound has been used with some success, but the information gained is limited to the lateral and superficial aspects of the joint (Rodriguez et al. 2007). The combination of non-specific clinical signs and the insidious onset of DJD may confound equine veterinarians and frustrate owners, preventing advanced diagnostic imaging (CT and MRI) from being performed.

In both horses and people, a common cause of TMJD is trauma, which can lead to fracture of the mandibular condyle, disrupting the articular surface (May et al. 2001; Carmalt and Wilson 2005; Rodriguez et al. 2010; He et al. 2013). A putative link between equine TMJ disease and dental malocclusion has been made, but remains unsubstantiated (May 1996). To the authors' knowledge, this report is the first to describe degenerative changes of the TMJ that are unrelated to any known trauma, or sepsis. Instead it follows a pattern of disease and response to treatment commonly seen in appendicular joints with DJD.

3.3 Case history:

An 18 year-old Tennessee Walking Horse mare was referred to the Veterinary Medical Center at the Western College of Veterinary Medicine, University of Saskatchewan, because of colic. The mare had a history of intermittent colic episodes spanning seven years, with eight episodes occurring over the last year alone. Over the previous three years, the mare had also been examined multiple times for behavioural issues, reportedly quidding, becoming very agitated and difficult to ride. The horse had developed a hypersensitivity to touch on the right hand side of its face, headshaking and fighting the bit during riding. At the onset of adverse reaction to being touched an ophthalmic examination had been performed, revealing mild incipient cataracts and a

‘non-ophthalmic’ sensitivity to the periocular region of the right side, but no other ocular cause of the apparent discomfort exhibited by the mare.

The horse had lost approximately 60 kg over the previous year. The owner noted that the horse, while masticating, would emit an audible clicking noise often dropping feed (quidding) as she ate. Neither of these abnormalities was noted at the time of admission for colic. The horse was also reported to have been off feed for the entire day, and passing looser than normal feces. Assessment of vital parameters revealed a heart rate of 42 beats/minute, respiratory rate of 16 breaths/min and a rectal temperature of 38 °C. The mucous membranes were pink and moist and the capillary refill time was noted as less than three seconds. Packed cell volume and total protein were 35% and 66 g/L, respectively. Rectal examination revealed no abnormal findings.

3.4 Diagnosis:

The presenting bout of colic was tentatively diagnosed as being caused by a large colon impaction and treated by the administration of water (5 L), mineral oil (2 L) and electrolyte powder via a nasogastric tube, which required i.v. sedation of the horse using a combination of xylazine hydrochloride (Rompun)¹ and butorphanol tartrate (Torbugesic)², in addition to i.v. flunixin meglumine (Flunixin injection)³. Following resolution of the colic symptoms, a complete oral examination was performed. Focal overgrowths (hooks) were present on the rostral aspect of the 106 and 206 teeth as were slight overgrowths on the lingual aspect of the mandibular cheek teeth and the buccal aspect of the maxillary cheek teeth. The incisors were in normal occlusion and mandibular excursion to the left and right was normal. Odontoplasty was performed, which did not subsequently alter the behavioural issues during riding, or the sensitivity to touch on the right hand side of the face. Standard radiographic (dorsoventral, lateral and oblique) views of the head, including specific tangential projections of the TMJs, were performed (Townsend et al. 2009). No abnormalities of the soft tissue, bony, sinonasal, or dental structures (including the TMJs), were found. Despite the absence of palpable joint effusion ultrasound examination of the joint was performed and no abnormalities were detected. A CT (Aquilion 16)⁴ examination of the head, using 1 mm slices, was performed under general anesthesia. This examination showed

osteophytosis of the medial aspect of the mandibular condyles in the region of the insertion of the medial pterygoid muscles, as well as the presence of two distinct regions of soft tissue mineralization within the rostral aspect of both intraarticular discs (Figure 3.1). The mineralization of the articular disc of the left TMJ was 11 X 6 X 5 mm in size (mediolateral by dorsoventral by rostrocaudal dimensions) whereas the right was 10 X 6 X 5 mm. The left TMJ showed mild subchondral bone sclerosis on the medial aspect of the mandibular condyle and osteophytosis on the lateral aspect of the zygomatic process of the left temporal bone. No evidence of fracture or subluxation of either mandibular condyle was noted.

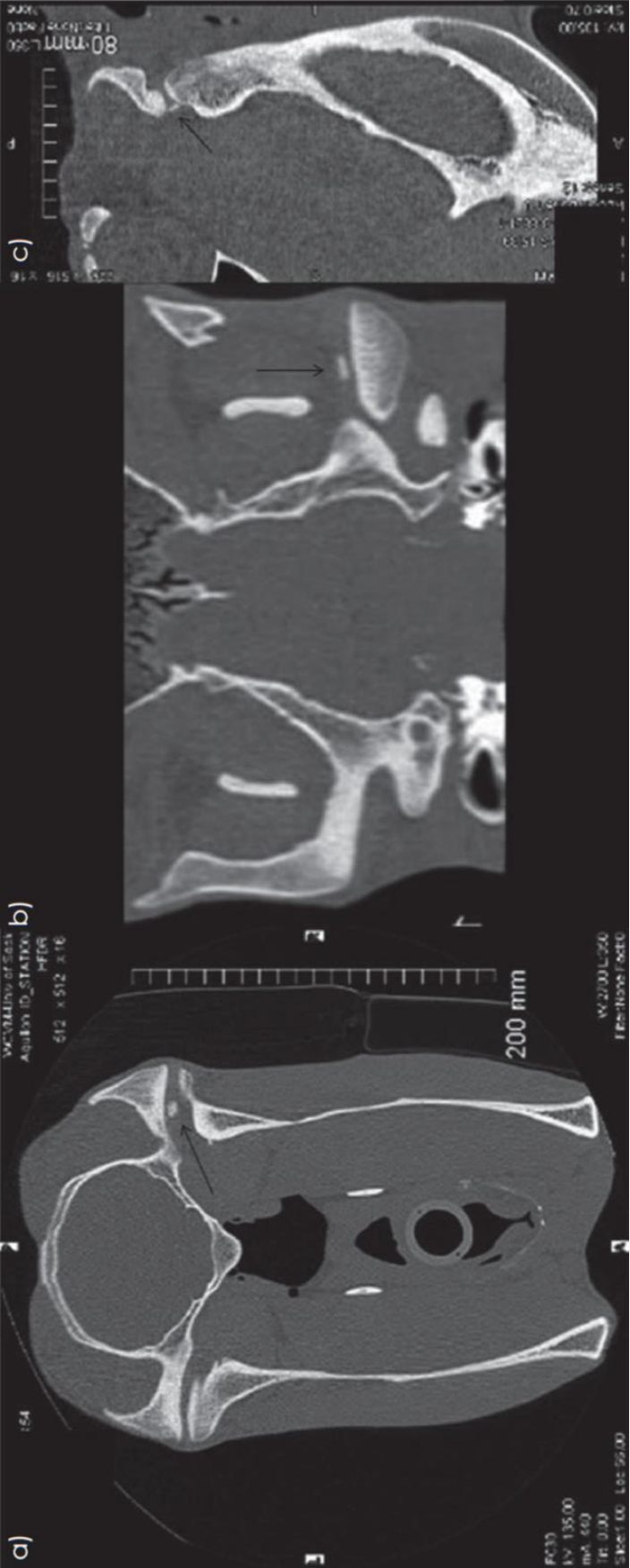
3.5 Treatment:

Following CT, an arthrocentesis of each TMJ was performed, a synovial fluid sample obtained, and each joint injected with 60 mg of methylprednisolone acetate (Depomedrol)⁵. The choice of intraarticular medication was based on the presumptive need for long term therapy, which would be afforded by this steroid choice. Both synovial fluid samples were placed in EDTA tubes, despite which they clotted and were unsuitable for laboratory analysis. Local analgesia was not performed to localize the clinical signs further because the clicking sound and quidding during mastication were not present at the time of examination making the diagnosis of a ‘positive’ block impossible to determine.

3.6 Outcome:

The owner was contacted one week post-injection; the head-shaking, masticatory clicking and quidding had ceased. Communication with the owner indicated that the horse had regained the weight lost over the previous year and there were no further reports of episodic colic. Ten months’ post-injection, the episodes of colic, quidding and the masticatory click had returned. Additionally, the horse had become ataxic (in the owner’s opinion). At this time, a second injection of the intraarticular corticosteroids was administered (60 mg methylprednisolone acetate⁵). A neurological examination by the attending veterinarian was inconclusive and did not differentiate

Figure 3.1: A computed tomographic series of images (a: transverse, b: dorsal and c: sagittal planes) showing the area of increased linear attenuation suggestive of mineralized tissue (arrow) in the rostral aspect of the intraarticular disc of the right temporomandibular joint of an 18 year-old Tennessee Walking horse mare.



between ‘true’ ataxia and weakness. The response to intraarticular treatment was short lived, lasting approximately four months and no improvement in the ‘ataxia’ was seen following treatment. At the end of four months, the horse refused to eat and became recumbent. At this point, due to the poor prognosis, the owner elected to euthanase the horse.

3.7 Post-mortem findings:

A full post-mortem examination was performed by the attending pathologist, but failed to find any abnormality in the gastrointestinal tract or the spinal cord to account for the colic episodes or signs of ataxia. The TMJs were not opened for gross examination as this would have destroyed the integrity of the joints. Instead the head (and brain) were subjected to MRI (Siemens MAGNETOM Symphony)⁶ and subsequently frozen. T1-weighted sagittal, transverse and dorsal plane, T2-weighted sagittal and transverse, as well as proton density transverse sequences were performed and confirmed the CT findings regarding the presence of the mineralized portion of the intraarticular disc (Figure 3.2). No abnormalities of the brain were seen. The skull, including the TMJs was then sectioned in the sagittal plane, into multiple 4 to 5 mm thick slabs, using a bandsaw. Sections were fixed in 10% neutral buffered formalin, decalcified in 20% formic acid, and routinely processed (i.e. embedded in paraffin, cut at 4 µm, mounted on glass slides, stained with haematoxylin and eosin, and cover slipped, for routine microscopic examination). Microscopic examination of the histologic sections of both TMJs, by a consulting veterinary pathologist (A.L.A.), revealed similar changes in each. There were foci of chondroid metaplasia within the intraarticular disc and foci of chondro-osseous metaplasia of the intraarticular disc at the attachment to the joint capsule (Figures 3.3, 3.4 and 3.5). The articular cartilage of both the mandibular fossa of the temporal bone and the condylar process of the mandible exhibited extensive degenerative changes. There was a general decrease in basophilic staining of the extracellular matrix, interpreted to be a loss of proteoglycan, a decrease in the number of chondrocytes, which was dramatic in some areas (Figure 3.6) and many clusters or clones of chondrocytes, also referred to as chondrones (Figure 3.7).

Figure 3.2: A T1-weighted sagittal MRI of the right TMJ showing a region of reduced signal intensity (white arrow) in the rostral aspect of the intraarticular disc suggestive of mineralized tissue.

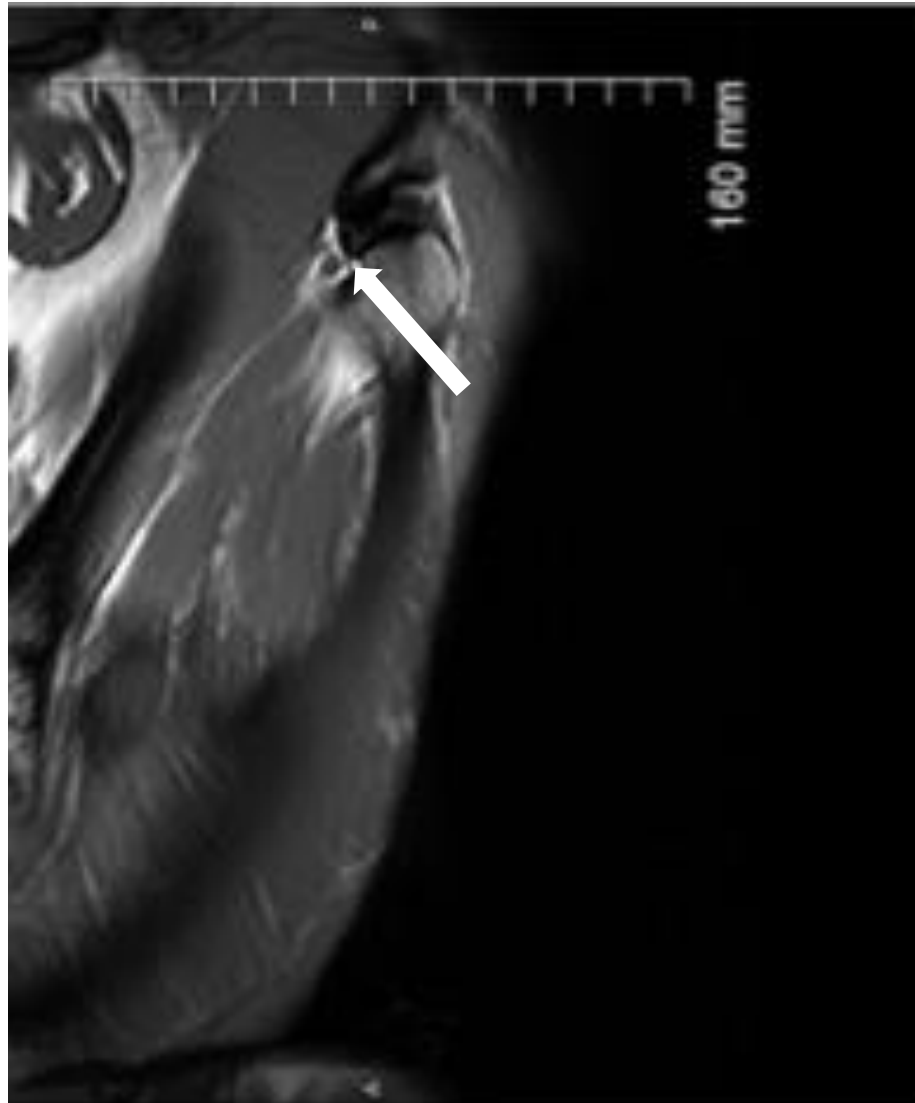

Figure 3.3: A relatively large focus of chondroid metaplasia within the intraarticular disc of the left TMJ of an 18 year-old Tennessee Walking Horse mare. (Original magnification = 20X; haematoxylin and eosin stain).

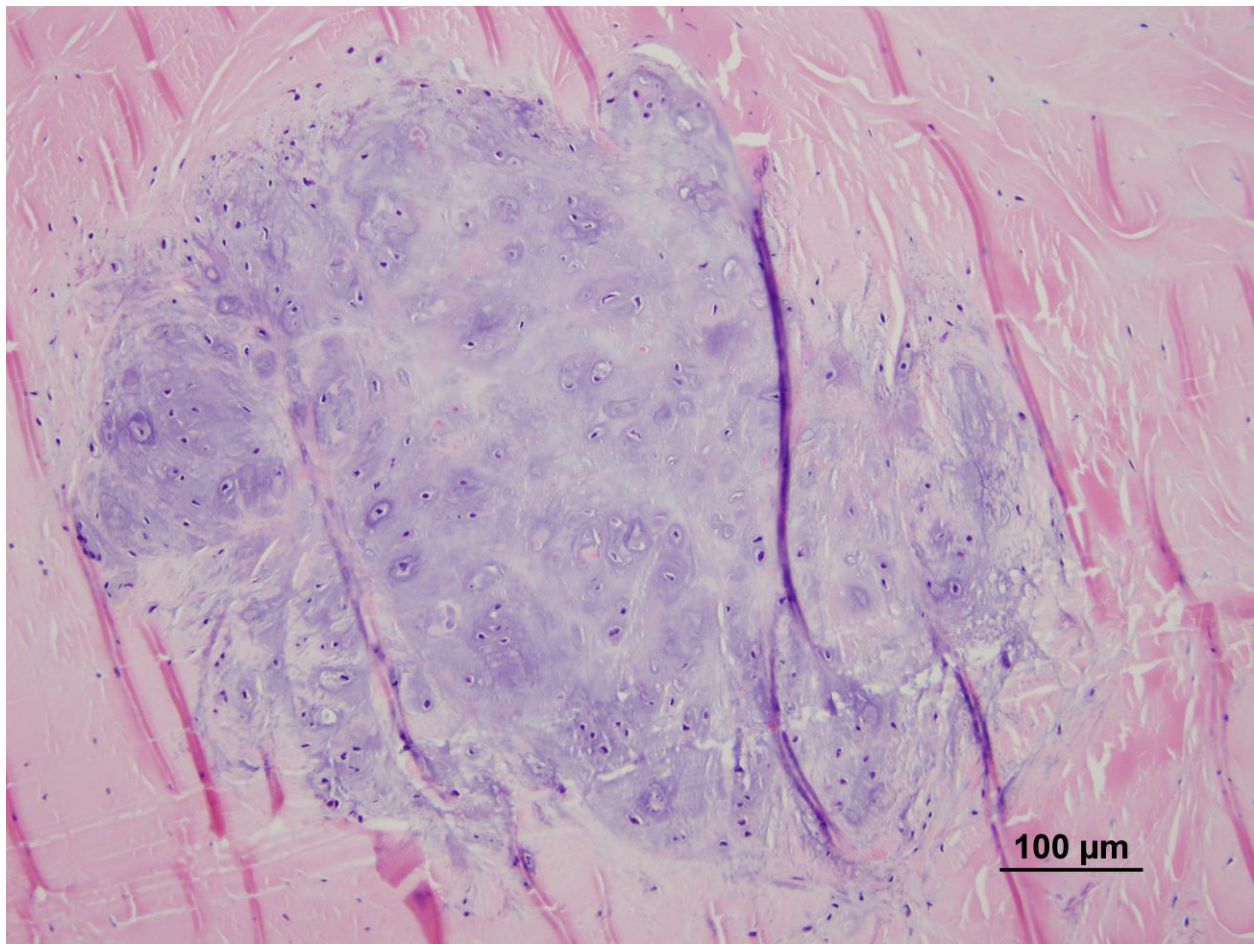


Figure 3.4: A large focus of chondro-osseous metaplasia at the attachment of the intraarticular disc to the joint capsule of the left TMJ. (Original magnification = 2X; haematoxylin and eosin stain).

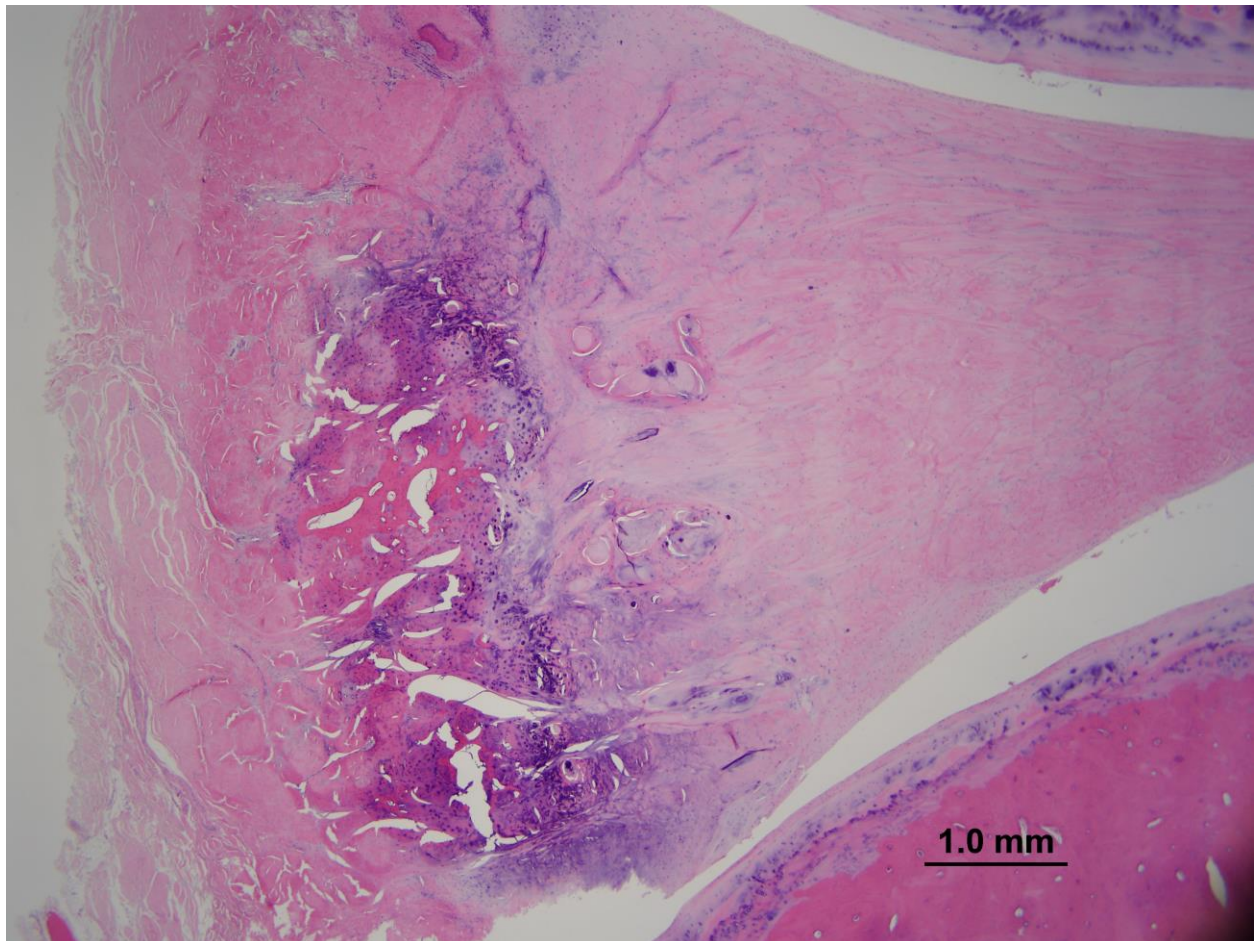


Figure 3.5: A large focus of chondro-osseous metaplasia at the synovial surface of the intraarticular disc, at the attachment to the joint capsule, of the right TMJ. The articular surface and subchondral bone of the mandibular fossa of the temporal bone are present in the upper left corner of the image. (Original magnification = 4X; haematoxylin and eosin stain).

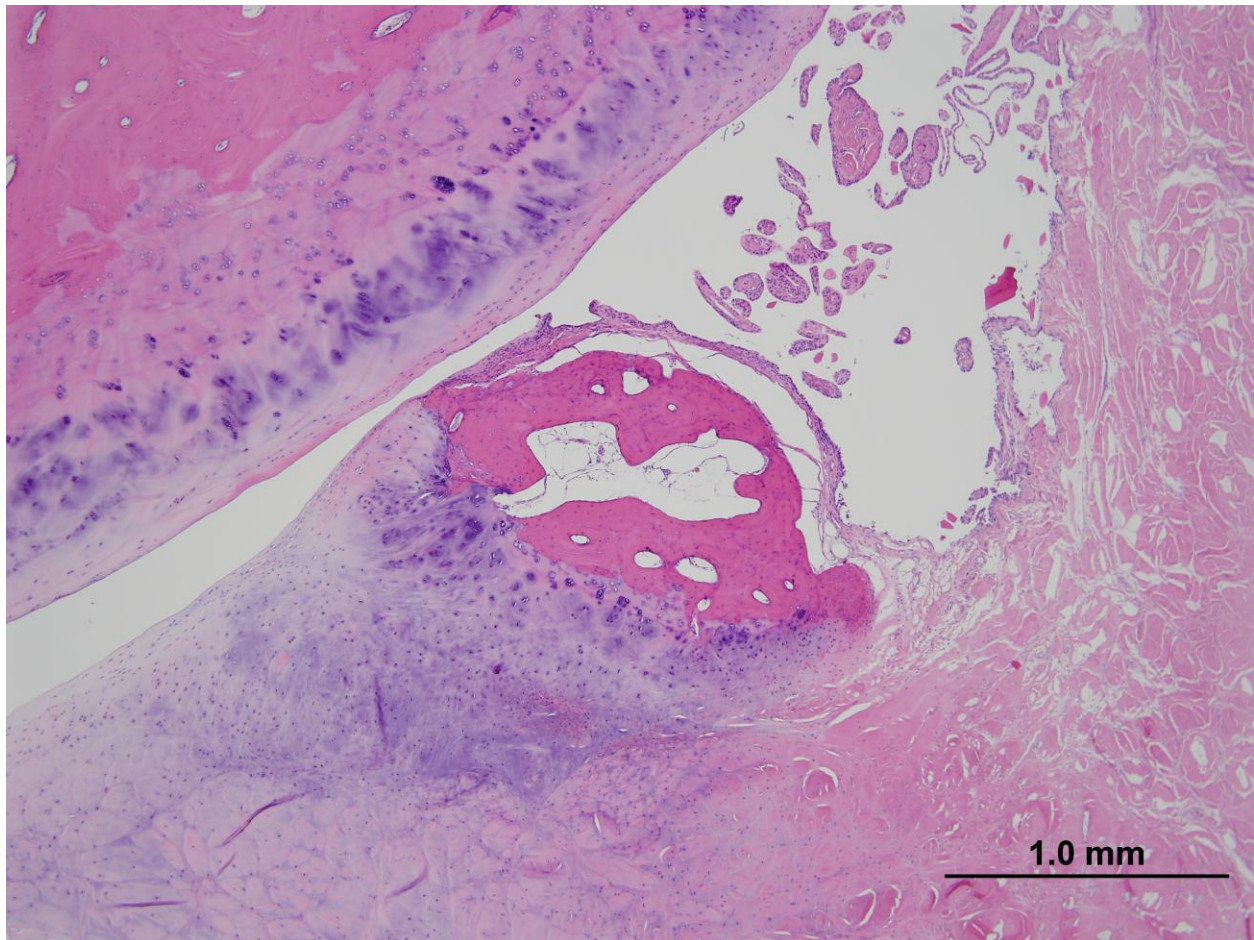


Figure 3.6: An area of the articular surface and subchondral bone of the right mandibular condyle. There is a generalized decrease in basophilic staining of the surface cartilage, interpreted as loss of proteoglycan, and a dramatic decrease in the number of chondrocytes. (Original magnification = 10X; haematoxylin and eosin stain).

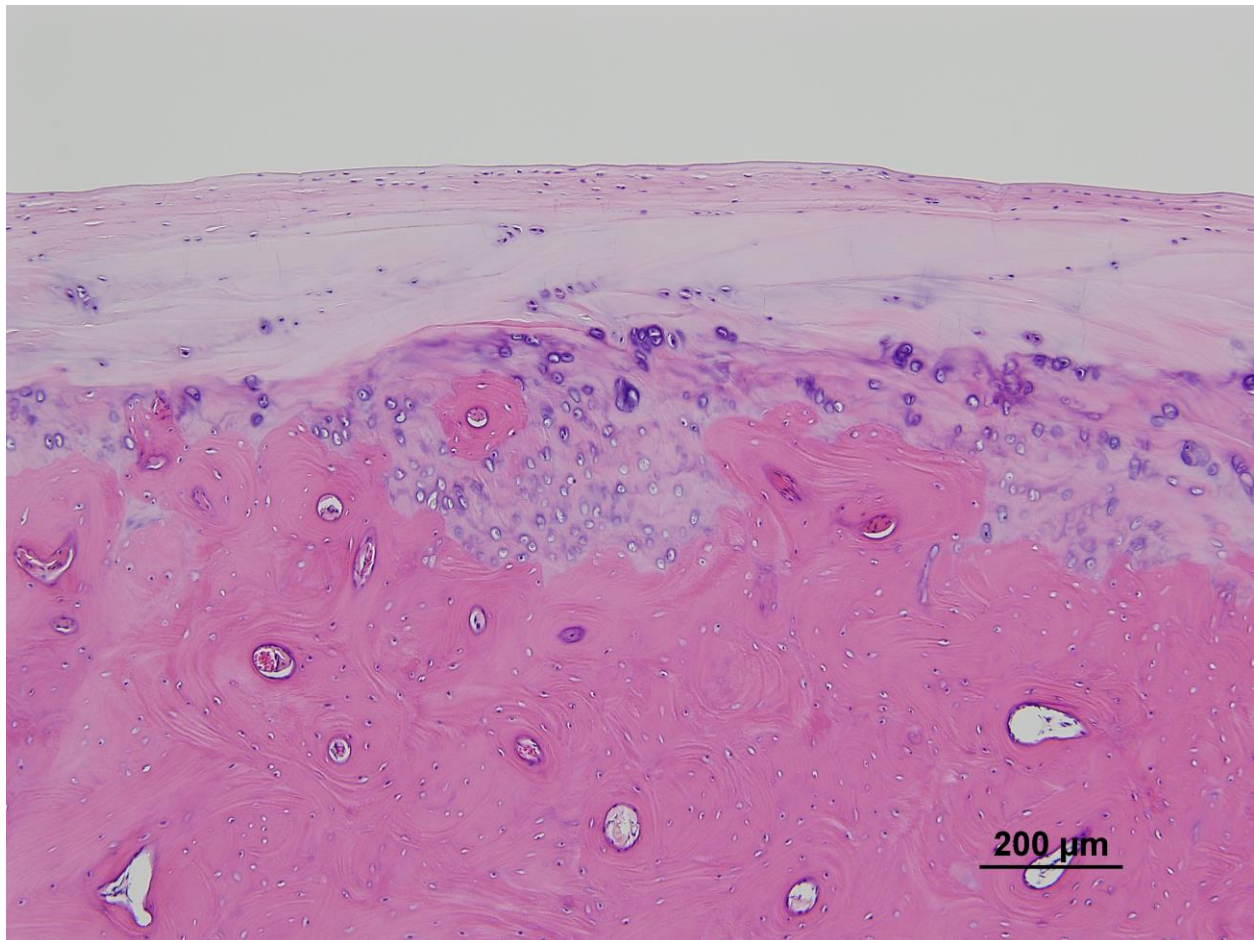
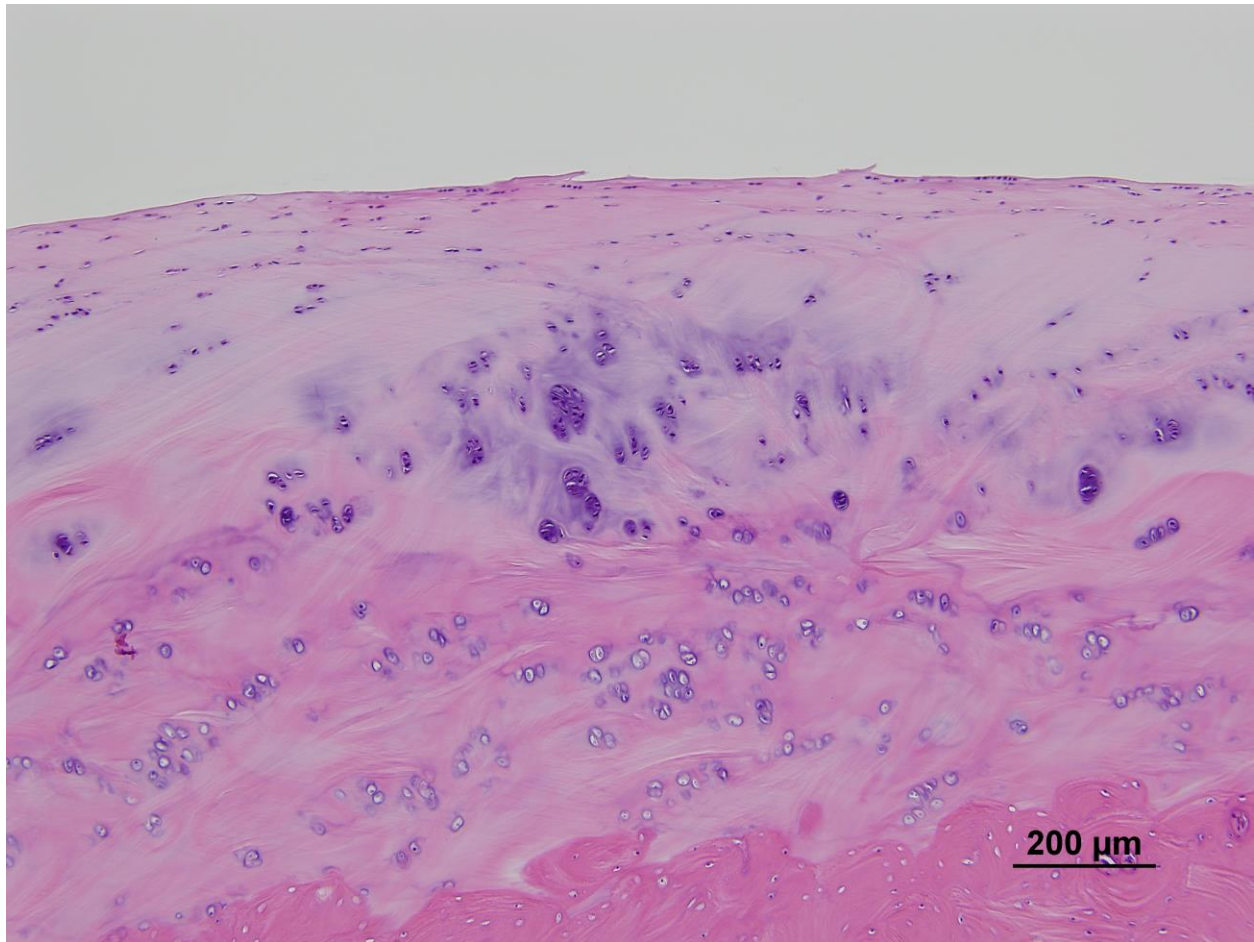


Figure 3.7: The articular surface of the mandibular fossa of the temporal bone. There are many clusters or clones of chondrocytes, referred to as chondrons. (Original magnification = 10X; haematoxylin and eosin stain).



3.8 Discussion:

The most common cause of TMJ disease, in both man and horses, is trauma (Hurtig et al. 1984; Patterson et al. 1989; Leighty et al. 1993; Warmerdam et al. 1997; He et al. 2013). In horses, these injuries often occur in combination with fracture, subluxation, or both, of the mandibular condyle and subsequent sepsis through the introduction of bacteria into the joint space or surrounding tissue (Barber et al. 1985; Patterson et al. 1989; Warmerdam et al. 1997; Weller et al. 1999a,b; Carmalt and Wilson 2005; Nagy and Simhofer 2006; Barnett et al. 2014). In the present case, there was no history or evidence suggesting trauma. CT examination revealed bilateral mineralization of the intraarticular discs and periarticular osteophyte formation. The failure of the radiographs to highlight the presence of osteophytosis seen on CT, emphasizes the utility of using advanced imaging techniques (MRI and CT). In order to adequately visualize these small changes radiographically, a very precise angle would have been required. Even the smallest variation would create overlap, obscuring the bony projections from view.

Medial osteophytosis has been noted in other, older horses by the senior author (J.L.C.), but osteophytosis of the lateral aspect of the joint is not common. A few reports postulating the link between dental pathology (specifically pertaining to incisors) and equine TMJ disease have been published, but the causal relationship has yet to be determined (May 1996; Carmalt et al. 2003; Carmalt 2014). The horse in this report showed little evidence to suggest that dental disease was the cause, or the sequelae, of TMJD. Historical oral examinations performed at the time of diagnosis of TMJD yielded little beyond that noted in the majority of horses undergoing regular oral examination.

The clinical signs that accompany cases of TMJD, while subtle, are paramount to understanding the extent of its effect on a horse's overall health. The chewing motion in horses has been theorized to act like an auger, with each piece of feed given a single opportunity to pass over a grinding surface (Collinson 1994). Once passed, the tongue and palatine ridges, act as a one-way conduit to direct feed toward the back of the oral cavity. Episodes of quidding are suggested to be a failure of the auger-like action of the mouth, to grind the feed down to a size manageable for swallowing. As a result, the horse rejects the feed to prevent choking. If pain is

associated with the chewing process, the horse may try to reduce the overall number of chewing cycles, leading to larger particles of feed at the back of the oral cavity.

Together with the loss of feed through excessive quidding, the pain of mastication may have been sufficient to prevent this horse from eating as readily, leading to the weight loss appreciated in physical examination. It may also be argued that the recurrent episodes of colic could have been related to inefficient or ineffective mastication that, in turn, may have predisposed the horse to large colon impaction colic. While an attractive theory, previous published work looking at the effect of dental pathology on fecal particle size in horses with large colon impaction does not support this argument (Carmalt and Allen 2006; Gunnarsdottir et al. 2014). It is possible that well-nourished horses have the privilege of being more selective in their forage choice and despite oral or TMJ pain, continue to chew their feed, whereas horses that are malnourished may be more ravenous, swallowing the feed that is not properly processed.

Headshaking during riding has been reported as a clinical sign associated with diseases of the TMJ (May et al. 2001; Devine et al. 2005). The use of a bit in the mouth of the horse allows rider control by placing pressure on the mandible, pulling it in the caudal direction (Cook 1999; Geyer and Weishaupt 2006). In the ‘collected’ position (neck flexion), the mandible must slide forward. It is possible that inflammation in the TMJs will create pain during these times and manifest as headshaking (Geyer and Weishaupt 2006). It is extremely important to note that the correlation between TMJ disease and impaction colic or headshaking or even the presence of dental disease is speculative as there are no data to support these associations at present.

The cause of the ataxia, and ultimately recumbency, remains obscure. While MRI imaging of the brain did not reveal any abnormalities, it is recognized that subtle brain lesions, especially without the use of contrast, can remain undiagnosed. As such, a complete histologic examination of this anatomical structure is the gold standard. The etiology of the ataxia and repeated colic episodes could not be found. In retrospect, it is possible that the clinical signs interpreted as colic were actually the manifestation of an anorexic horse that had the urge to eat but could not open its mouth, due to pain. It is also possible that the ‘ataxia’ was truly weakness associated with weight-loss and an inability to eat effectively. It is suspected that a combination of age, prolonged

anorexia, depression and weakness ultimately led to the horse becoming recumbent. In reality, however, these justifications remain conjecture on the part of the authors.

The histologic examination of the TMJs gave definitive evidence of degeneration of the articular cartilage and intraarticular discs in this horse in the absence of sepsis. These findings correlate with the clinical history of a degenerative joint and the need for repeated intermittent intraarticular medications to ameliorate the apparent discomfort exhibited by the horse. The problem is that the literature contains no evidence supporting age-related degeneration of the equine TMJ as occurs in other joints. It is possible that the horse in the present report had normal age-related TMJ degeneration associated with ‘wear and tear’ of the joint and concurrent pain from a local region that was mitigated by diffusion of the steroid from the joint following injection. Work is currently underway to further investigate the relationship between age and histologic evidence of DJD in the equine TMJ.

In conclusion, the authors report the investigation and treatment of bilateral TMJD of an aged horse that responded to intraarticular medication in a manner akin to other appendicular joints.

3.9 Footnotes:

¹Bayer HealthCare, Toronto, Ontario, Canada.

²Wyeth Animal Health, Guelph, Ontario, Canada.

³Norbrook Laboratories Ltd., Newry, Co. Down, UK.

⁴Toshiba, Tustin, California, USA.

⁵Pfizer Animal Health, Kirkland, Quebec, Canada.

⁶Siemens AG, Erlagen, Germany.

3. 10 References:

Baker, G.J. (2002) Equine temporomandibular joints (TMJ): morphology, function, and clinical disease. *Proc Am Assoc Equine Pract.* 48, 442-447.

Barber, S.M., Doige, C.E. and Humphreys, S.G. (1985) Mandibular condylectomy-technique and results. *Vet Surg.* 14, 79-86.

Barnett, T.P., Powell, S.E., Head, M.J. et al. (2014) Partial mandibular condylectomy and temporal bone resection for chronic, destructive, septic arthritis of the temporomandibular joint in a horse. *Equine Vet Educ.* 26, 59-63.

Carmalt, J.L. (2014) Equine temporomandibular joint (TMJ) disease: fact or fiction? *Equine Vet Educ.* 26, 64-65.

Carmalt, J.L. and Allen, A.L. (2006) Effect of rostrocaudal mobility of the mandible on feed digestibility and fecal particle size in horses. *J Am Vet Med Assoc.* 229, 1275-1278.

Carmalt, J.L., Townsend, H.G. and Allen, A.L. (2003) Effect of dental floating on the rostrocaudal mobility of the mandible of horses. *J Am Vet Med Assoc.* 223, 666-669.

Carmalt, J.L. and Wilson, D.G. (2005) Arthroscopic treatment of temporomandibular joint sepsis in a horse. *Vet Surg.* 34, 55-58.

Collinson, M. (1994) Food processing and digestibility in horses (*Equus caballus*), B.Sc. Dissertation, Monash University, Victoria, Australia.

Cook, R.W. (1999) Pathophysiology of bit control in the horse. *J Equine Vet Sci.* 19, 196-204.

Devine, D.V., Moll, H.D. and Bahr, R.J. (2005) Fracture, luxation and chronic septic arthritis of the temporomandibular joint in a juvenile horse. *J Vet Dent.* 22, 96-99.

Ebling, A.J., McKnight, A.L., Seiler, G. et al. (2009) A complementary radiographic projection of

the equine temporomandibular joint. *Vet Radiol Ultra.* 50, 385-391.

Geyer, H. and Weishaupt, M.A. (2006) The influence of the rein and bit on the movements of the horse; anatomical-functional considerations. *Pferdeheilkunde* 22, 597-600.

Gunnarsdottir, H., Van der Stede, Y., De Vlamynck, C. et al. (2014) Hospital-based study of dental pathology and fecal particle size distribution in horses with large colon impaction. *The Vet Journal.* 202, 153-156.

He, D., Yang, C., Chen, M. et al. (2013) Effects of soft tissue injury to the temporomandibular joint: report of 8 cases. *Br J Oral Maxillofac Surg.* 51, 58-62.

Hurtig, M.B., Barber, S.M. and Farrow, C.S. (1984) Temporomandibular- joint luxation in a horse. *J Am Vet Med Assoc.* 198, 78-80.

Jørgensen, E., Christophersen, M.T., Kristoffersen, M. et al. (2014) Does temporomandibular joint pathology affect performance in an equine athlete? *Equine Vet Educ.* 27, 126-130.

Leighty, S.M., Spach, D.H., Myall, R.W.T. et al. (1993) Septic arthritis of the temporomandibular joint: review of the literature and report of two cases in children. *Int J Oral Maxillofac Surg.* 22, 292-297.

May, K.A., Moll, D.A., Howard, R.D. et al. (2001) Arthroscopic anatomy of the equine temporomandibular joint. *Vet Surg.* 30, 564-571.

May, K.J. (1996) Incisor problems that may result in inflammation of the temporomandibular joint. *Pferdeheilkunde* 12, 12.

Moll, D.H. and May, K.A (2002) A review of conditions of the equine temporomandibular joint. *Proc Am Assoc Eq Pract.* 48, 240-243.

Nagy, A.D. and Simhofer, H. (2006) Mandibular condylectomy and meniscectomy for the

treatment of septic temporomandibular joint arthritis in a horse. *Vet Surg.* 35, 663-668.

Patterson, L.J., Shappell, K.K. and Hurtig, M.B. (1989) Mandibular condylectomy in a horse. *J Am Vet Med Assoc.* 195, 101-102.

Ramzan, P.H., Marr, C.M., Meehan, J. et al. (2008) Novel oblique radiographic projection of the temporomandibular articulation of horses. *Vet Rec.* 162, 714-716.

Rodriguez, M.J., Agut, A., Soler, M. et al. (2010) Magnetic resonance imaging of the equine temporomandibular joint anatomy. *Equine Vet J.* 42, 200-207.

Rodriguez, M.J., Soler, M., Francisco, G. et al. (2007) Ultrasonic anatomy of the temporomandibular joint in healthy pure-bred Spanish Horses. *Vet Radiol Ultra.* 48, 149-154.

Townsend, N.B., Cotton, J.C. and Barakzai, S.Z. (2009) A tangential projection for investigation of the equine temporomandibular joint. *Vet Surg.* 38, 601-606.

Warmerdam, E.L., Klein, W.R. and Van Herpen, B.M. (1997) Infectious temporomandibular joint disease in the horse: computed tomographic diagnosis and treatment in two cases. *Vet Rec.* 141, 172-174.

Weller, R., Cauvin, E.R., Bowen, I.M. et al. (1999a) Comparison of radiography, scintigraphy and ultrasonography in the diagnosis of a case of temporomandibular joint arthropathy in a horse. *Vet Rec.* 144, 377-379.

Weller, R., Taylor, S., Maierl, J. et al. (1999b) Ultrasonographic anatomy of the equine temporomandibular joint. *Equine Vet J.* 31, 529-532.

Wyn-Jones, G. (1985) Interpreting radiographs 6: radiology of the equine head (Part 2). *Equine Vet J.* 17, 417-425.

CHAPTER 4: THE EFFECT OF ACUTE UNILATERAL INFLAMMATION OF THE EQUINE TEMPORMANDIBULAR JOINT ON THE KINEMATICS OF MASTICATION

This chapter utilizes a model of transient iatrogenic synovitis to not only confirm a putative link between inflammation of the equine TMJ and the clinical signs experienced in cases of disease, but to further characterize the clinical changes that occur to the masticatory cycle during episodes of inflammation.

Copyright statement: Chapter 4 has been published and is reproduced here with the permission of the copyright owner (The Equine Veterinary Journal).

Full citation: Smyth, T.T., Carmalt, J.L., Treen, T.T., Lanovaz, J.L. (2016) The effect of acute unilateral inflammation of the equine temporomandibular joint on the kinematics of mastication. *Equine Vet J.* 48, 523-527.

Author contributions: Smyth and Carmalt were responsible for the experimental design, and write-up. Treen and Lanovaz were essential in the setup and use of the kinematic motion tracking system.

CHAPTER 4: THE EFFECT OF ACUTE UNILATERAL INFLAMMATION OF THE EQUINE TEMPORMANDIBULAR JOINT ON THE KINEMATICS OF MASTICATION

T. Smyth, BSc, DVM[†],

J. L. Carmalt, VetMB, MVetSc, FRCVS, DABVP, DAVDC, DACVS, DACVSMR,[†]

T.T. Treen, BSc* and J.L. Lanovaz, PhD*

Institutional affiliations: [†]Department of Large Animal Clinical Sciences, Western College of Veterinary Medicine, University of Saskatchewan, Saskatoon, Canada; and ^{*}College of Kinesthesiology, University of Saskatchewan, Saskatoon, Canada.

Source of funding: No sources of funding were provided for this project.

Authors' declaration of interests: No conflicts of interest have been declared.

Ethical animal research: All animal procedures were approved by the Animal Use and Care Committee at the University of Saskatchewan.

4.1 Abstract:

Diseases of the TMJ are well reported in man and some domestic animals other than the horse. The pathophysiology of equine TMJ disease and the effects of disease on the kinematics of mastication are unknown. The objective of this study is to determine whether transient unilateral inflammation of the equine TMJ results in alterations in the masticatory cycle. Utilizing six horses of various ages with normal dentition, each horse was equipped with an optical motion tracking (kinematic) system. Horses were observed chewing grass hay over three minute intervals. Regardless of the initial side of the power stroke in the masticatory cycle, LPS was injected in the left TMJ in each horse and the horses were reassessed after six hours. Four horses developed effusion of the injected TMJs; two of these also began quidding. All horses injected on the original side of the power stroke switched sides while the two injected on the contralateral side did not. All horses developed reduced vertical pitch (vertical opening) of the mandible. Overall, rostrocaudal movement of the mandible did not change; however, the timing of this movement relative to the phase of the masticatory cycle did. Injection with LPS did not affect the amount of lateral movement of the mandible. Injection of LPS into the TMJ significantly altered the masticatory cycle compared with baseline values representing avoidance behavior due to inflammation of the joint, despite which the horses continued to eat using the contralateral mandible. Lipopolysaccharide administration also led to quidding and a loss of feed efficiency (in some individuals).

4.2 Introduction:

The arthrology of the equine TMJ has been well described and yet studies of pathology and pathophysiology of this unique joint remain absent (Weller et al. 1999a; May et al. 2001; Rodriguez et al. 2006; Rodriguez et al. 2008; Rodriguez et al. 2010). Sporadic reports of DJD of the TMJ have been limited to severe cases involving fracture of the mandibular condyle and secondary or primary sepsis, both followed by subsequent degeneration of the joint (Carmalt et al. 2005; Nagy and Simhofer 2006; Bienert-Zeit and Rötting 2011; Barnett et al. 2014). Reports

detailing idiopathic clinical OA due to degenerative change are limited to a single publication and a citation in a surgical text (Stadtbaumer and Boening 2002; Boening 2012).

Equids have a tightly controlled masticatory cycle. Horses tend to chew predominantly to one side (Baker 2005). The normal mastication cycle can be divided into three phases: the opening, closing and power strokes (Leue 1941; Carmalt 2011), which have been evaluated during mastication (Bonin et al. 2006; Bonin et al. 2007). Research into the human masticatory cycle has shown that TMJ abnormalities can lead to changes in both the angle and translocation of the jaw, reducing the amount of lateromedial and rostrocaudal movement (Celic et al. 2004; Yoon et al. 2007). This, in turn, changes the rate of movement through different phases of the cycle, resulting in faster opening phases and slower closing phases. When it develops in the absence of trauma or sepsis, it is possible that the progressive onset of TMJD in the horse allows for a spectrum of initially subtle and possibly compensatory clinical signs, similar to those described in studies in man.

The objective of this study was to describe the effect of acute unilateral inflammation of the TMJ using an injection of LPS on the kinematics of mastication in the horse. The hypothesis was that TMJ inflammation in the horse would change masticatory kinematics.

4.3 Materials and methods:

4.3.1 Animals

Six healthy Quarter Horses, free of dental abnormalities ranging from six to 15 years of age were used. Horses were evaluated for TMJ disease by subjectively assessing mastication and by palpating the region of the TMJs.

Radiographs and advanced diagnostic imaging were not performed. Prior to the study each horse was acclimated to being restrained in stocks for extended periods of time. Feed was withheld for 12 hours prior to the study. Access to fresh water was allowed at all times.

4.3.2 Kinematic data collection

Kinematics of the head and mandible were recorded using an active-marker motion capture system (Visualeyez VZ3000)¹ that tracks the 3-D locations of small (~5 mm diameter) infrared emitting markers (nominal resolution of 0.3 mm). The day prior to data collection, each horse was sedated and clipped in preparation for placement of the kinematic tracking markers. The following day, each horse was restrained unsedated in stocks, allowing free head movement. Hook-and-loop (Velcro) tabs were fixed to each of the shaved locations using cyanoacrylate glue and the tabs used to secure four tracking markers on the skull and four tracking markers on the mandible (Figure 4.1).

In a fashion similar to Bonin et al. (2006), a coordinate system for the skull was established using four distinct palpable, bony, landmarks; each of the right and left articular tubercles of the skull and two along the facial crest (Figure 4.1) (Bonin et al. 2006). The 3-D locations of the landmarks with respect to the skull tracking markers were recorded before each data collection session using a calibrated probe. These landmarks were marked in ink so that they could be consistently located between data collection sessions. The origin of the skull coordinate system was located midway between the articular tubercles, the y axis along the vector between the articular tubercles (pointing to the left), the x axis in the forward direction based on the facial crest landmarks and the z axis pointing vertically, perpendicular to the x and y axes (Figure 4.1). The skull coordinate system was then rotated by 15° about the y axis to bring the x–y plane parallel to the occlusal surfaces of the teeth. The skull coordinate system was tracked during mastication using the skull tracking markers, while the mandible coordinate system was set to be initially coincident to the skull coordinate system and tracked using the mandible tracking markers.

During each of the feeding trials, the horses were hand fed small bundles of grass-alfalfa hay. All hay for the study was taken from the same sliced bale and each horse received hay from the same slice. Hay-stem length was measured and recorded. The horses were allowed to chew each bundle completely before receiving another. Head and mandible kinematics were recorded while masticating each bundle. Between eight and 10 masticatory cycles were recorded for each mouthful (bundle) of hay. No attempt was made to restrain head movement during data collection.

To ensure feed had entered the caudal portions of the mouth, recording started two minutes after horses had initially begun chewing. Recording was suspended if the horses shook their head, moved their head out of the range of the motion capture system or reached for additional bites of feed. Collection was complete after feeding six to eight bundles of hay (each of which resulted in between eight and 10 masticatory cycles). Once a satisfactory number of masticatory cycles had been recorded, the kinematic tracking markers were removed, leaving the Velcro pads in place for later reattachment.

The horses were sedated with 200 mg xylazine (Rompun 100 mg/mL)² intravenously and the skin over the left TMJ aseptically prepared with Chlorhexidine scrub and 70% isopropyl alcohol. Lipopolysaccharide (0.0025 µg) in 1 mL sterile saline was titrated from a 30 mg/mL frozen stock solution (*Escherichia coli* 055:B5)³ and prepared immediately pre-injection in each case (Carmalt et al. 2011). The left TMJ was injected with 0.0025 µg of LPS. The horses were then returned to a group pen (without feed) for six hours to allow a clinically detectable inflammatory response to develop (Carmalt et al. 2011). After six hours, the horses were returned to the stocks, in the same order as pre-injection, the kinematic tracking markers refastened to the pre-existing Velcro pads, reference landmarks identified and the feeding protocol and concurrent kinematic recordings repeated. All kinematic data were collected at a sampling rate of 100 Hz and filtered after collection using a fourth order Butterworth low-pass filter, with a cut-off frequency of 10 Hz.

4.3.3 Data analysis

During post-processing, a virtual marker was created to track mandible displacement (Bonin et al. 2006). Located on the skull midline, at the level of the most caudal mandible tracking marker, the virtual mandible marker was tracked using the mandible tracking markers and its location was expressed with respect to the skull coordinate system. The angular displacements of the mandible coordinate system, with respect to the skull, were calculated using standard 3-D kinematics techniques and expressed as pitch, yaw and roll angles (Figure 4.1) (Soderkvist et al. 1993; Bonin et al. 2006). Each recording session was processed by manually identifying the start

and end of each opening–closing cycle with custom software (Matlab)⁴ using the minimum and maximum mandible pitch angle and z axis displacement of the virtual mandibular marker. Since different horses had varying amounts of useable, steady-state masticatory cycles, 15 cycles were randomly selected for analysis from each horse, both pre- and post-injection. Data were averaged across the 15 cycles. The three phases of the masticatory cycle were identified from the kinematics, with the start of the power stroke defined as the most lateral displacement (i.e. y axis) of the virtual mandible marker after the start of the closing phase. Variables selected for analysis were total cycle time, virtual mandible marker displacement ranges and mandible angular ranges of motion. Additionally, the x axis displacements of the virtual mandible marker during the closing and power stroke phases were calculated. Data were compared between conditions using paired t-tests (SPSS Statistics, Version 22)⁵ with the significance level set at $P < 0.05$.

4.4 Results:

Hay stems had a mean length of 420 mm (+/- s.d. 202 mm). At baseline, four of the six horses had a counter clockwise masticatory cycle (when observed from the front), meaning that the mandible extended to the left side of the head at the start of the power stroke. Following LPS administration into the left TMJ, all six horses had a clockwise cycle motion, meaning that the mandible extended to the right side of the head at the start of the power stroke (Figure 4.2).

Four horses developed visible swelling in the area of the left TMJ with palpation of the area revealing heat, pain sensitivity and joint effusion. Two of these four horses developed dysmastication, manifesting as quidding, in which the feed was either balled up and ejected from the mouth, or increased chewing time to swallowing. Subjectively, it was noted that both horses quickly developed an aversion for long stemmed hay, but would readily chew the short, leafy stems.

Figure 4.1: Marker locations and kinematics definitions. Four tracking markers were placed on the skull (S1–S4) with two on either side of the midline, between the eyes. The four mandible tracking markers (M1–M4) were located in line with the caudal ramus of the mandible. The right and left articular tubercles of the skull (RT, LT) and two points along the facial crest (FC1, FC2) were located using a calibrated probe and used to generate the skull coordinate system (shown). The mandible coordinate system was defined as initially coincident with the skull coordinate system.

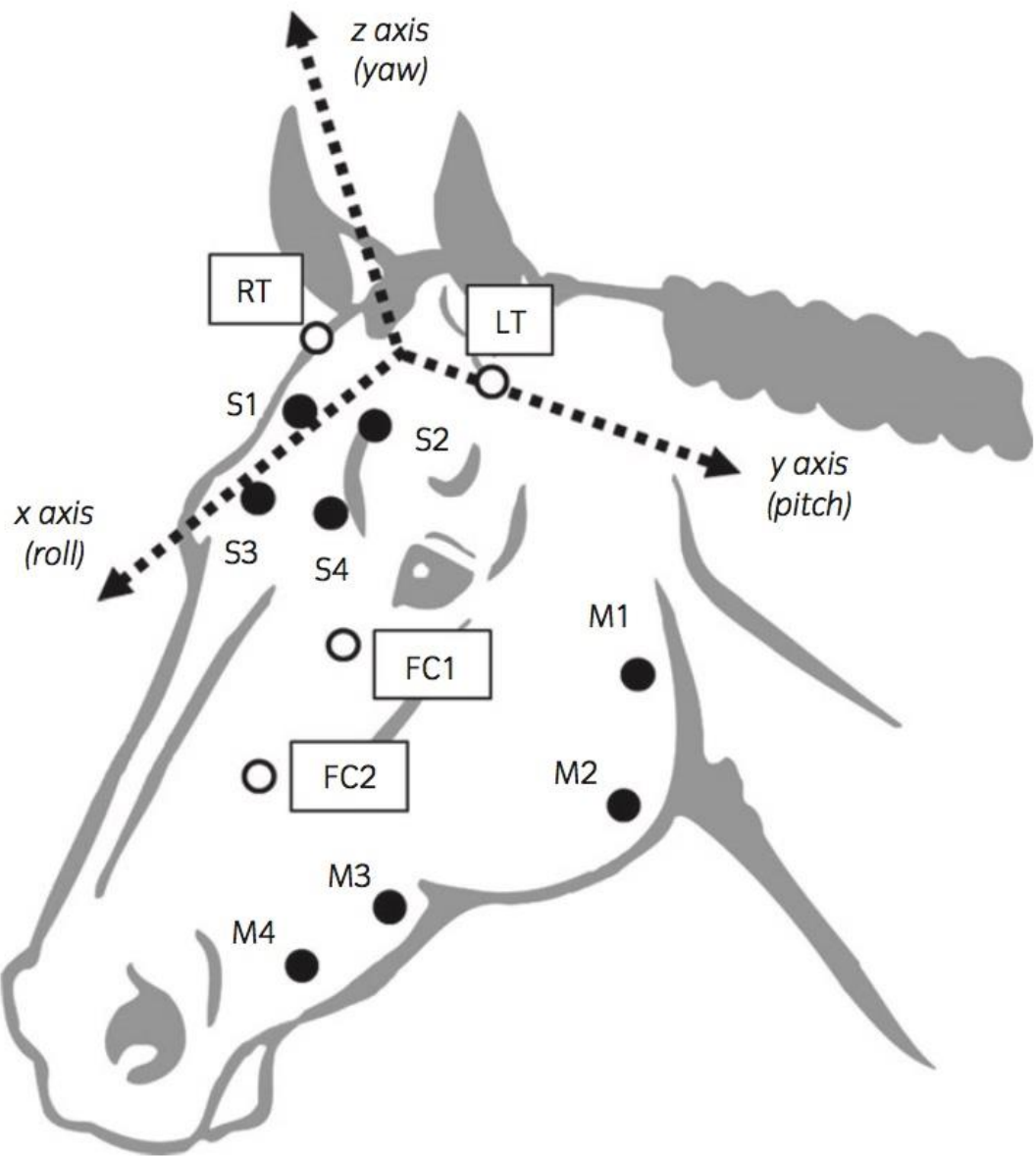
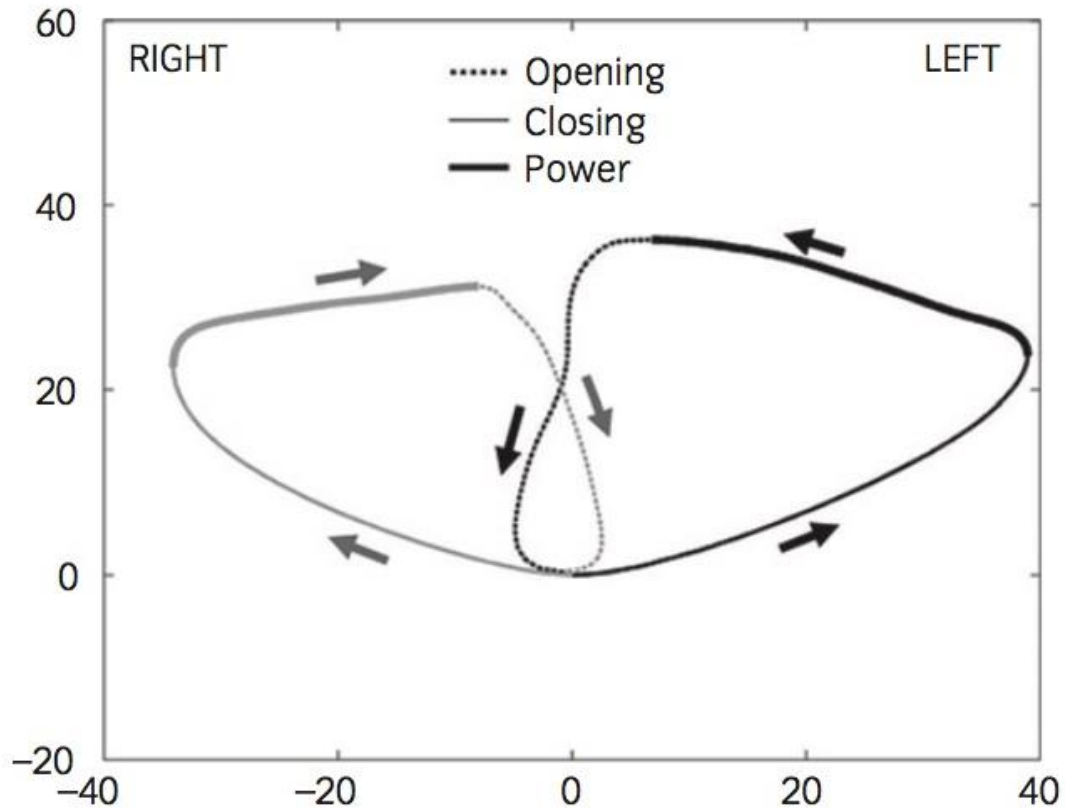


Figure 4.2: Frontal view (Y-Z plane) of the mean path of the virtual mandible marker for one horse. The graph shows pre- (black) and post- (grey) injection cycle paths (in mm). The origin is arbitrarily set as the start of the closing phase for both conditions. The direction of the masticatory cycle is shown by the arrows and the cycle phases are indicated by the line types.



A significant difference pre- and post- LPS injection was seen in pitch angle ROM (i.e. opening/closing of the mandible) with horses having a smaller ROM post-injection (Table 4.1). The mean change of the pitch angle was 0.74° , translating to a mean change in the vertical ROM of the virtual mandible marker of 3.3 mm. No other ROM variables were significantly different (Table 4.1). Mean masticatory cycle times were not significantly different pre- to post- LPS injection. Measurement of maximal pitch angular velocity suggested horses closed their mouths faster after LPS administration; however, the difference was not significant (Table 4.1).

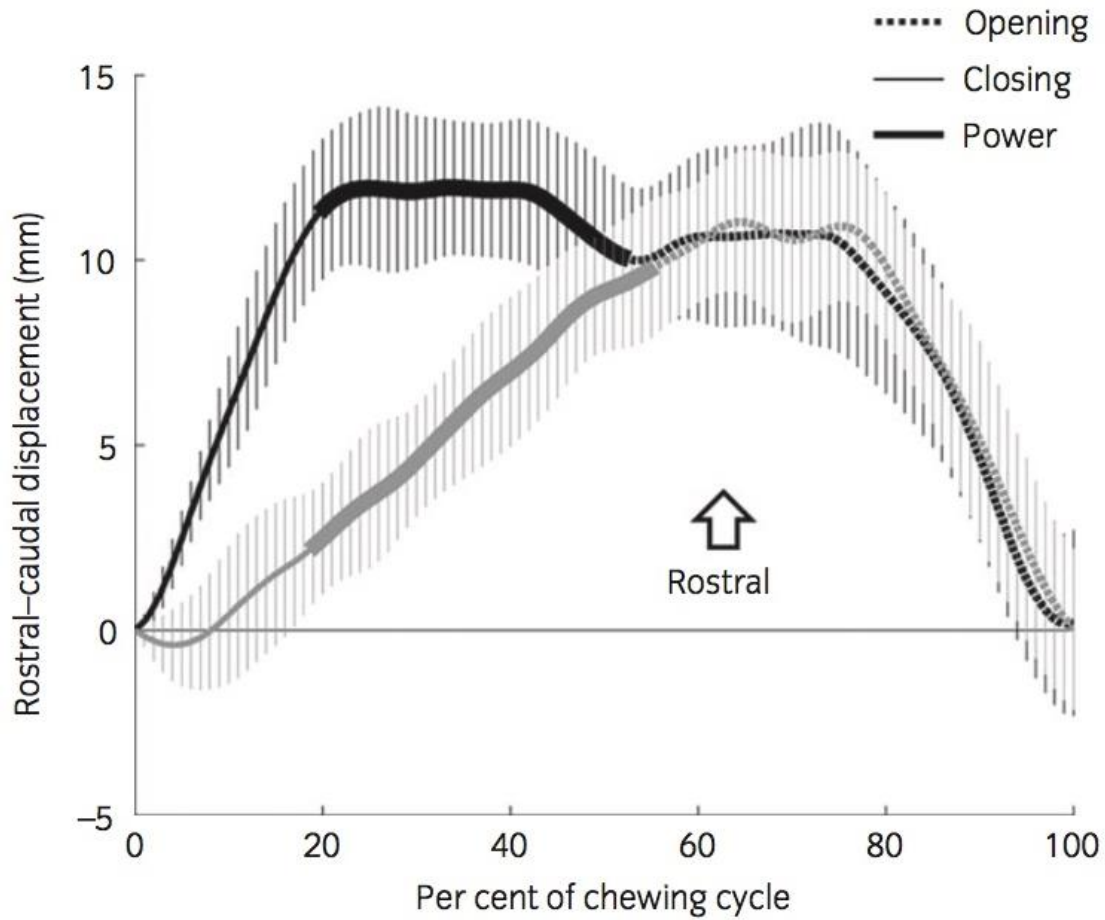
Although the virtual mandible marker rostral–caudal (x axis) total ROM was not different between pre- and post- LPS injection measurements, there was a noticeable change in the movement pattern during the closing and power stroke phases (Figure 4.3). At baseline, the mandible moved rostrally during the closing phase (which is considered normal) and following LPS injection, there was minimal rostral movement across this phase (Table 4.1). In contrast, during the power stroke, there was minimal rostral movement at baseline while there was significantly more rostral movement post-injection (Table 4.1).

Table 4.1: Group means (and +/-s. d.) for cycle time, ROM over the cycle and rostrocaudal mandible displacement over the closing and power stroke phases for pre- and post- TMJ injection.

	Baseline	Post LPS Injection	95% CI	P value
Cycle time (ms)	880 (84)	846 (95)	-46 to 113	0.3
Virtual mandible marker ROM (mm)				
Rostral-caudal (x axis)	9.8 (2.7)	10.0 (2.1)	-1.2 to 0.7	0.6
Lateral (y axis)	43.5 (5.3)	39.8 (4.2)	-0.6 to 8.0	0.08
Vertical (z axis)	31.1 (8.5)	27.8 (5.1)	-0.7 to 7.4	0.09
Mandible angular ROM (°)				
Roll (x axis)	5.3 (1.5)	4.8 (2.4)	-1.0 to 2.0	0.4
Pitch (y axis)	6.1 (1.6)	5.3 (1.3)	0.1 to 1.4	0.03
Yaw (z axis)	6.3 (1.1)	5.4 (0.3)	-0.1 to 1.8	0.06
Rostral mandible displacement (mm)				
Closing phase	5.6 (4.5)	0.6 (2.1)	1.8 to 8.3	0.01
Power stroke phase	2.0 (2.7)	6.3 (1.3)	-8.2 to -0.5	0.03

The 95% confidence intervals for the paired differences and P values for paired *t* tests are also given. LPS=lipopolysaccharide.

Figure 4.3: Pre- (black) and post- (grey) injection mean rostrocaudal movement of the virtual mandible marker during the 15 masticatory cycles for a typical horse. Standard deviations are shown with hatched lines and cycle phases are indicated by line types. Zero percent of cycle time corresponds to the start of the closing phase.



4.5 Discussion:

The masticatory motion of the normal equine mandible, utilizing 3-D kinematics to quantify rotation and movement centered around the TMJ, has been previously reported (Bonin et al. 2006; Bonin et al. 2007). There was a need, however, to determine how these were affected by disease (Ramzan 2006). Building on previously reported protocols, we were able to safely and accurately examine the masticatory cycle of horses, during experimentally induced acute inflammation of the TMJ (Bonin et al. 2006; Carmalt et al. 2011).

The baseline data recorded in the current study was similar to that presented previously (Bonin et al. 2006; Bonin et al. 2007). Following injection of the LPS, the cycle of mastication changed within all horses. Previous studies have observed that not only do individuals differ on the predominant side that they chew, but that some horses switch sides intermittently (Baker 2005). In the current study, all of the horses (four in total) that were observed to be masticating on the left side of the mandible (counter clockwise direction) prior to administration of LPS, switched to a right-sided masticatory pattern following injection (Figure 4.2). Conversely, the remaining two horses, masticating on the right arcade at baseline (clockwise direction), continued on the same side after LPS injection. We propose that inflammation within the left TMJ created sufficient discomfort to cause horses to perform the power stroke of their masticatory cycle on the unaffected side. This suggests that horses, like man, have the ability to manipulate the direction in which they chew feed.

Despite moving the power stroke to the unaffected side of their heads, horses also changed the spatial limits of their masticatory cycle. Most notably, the decrease in pitch angle (0.74°) which led to an average loss of 3.3 mm vertical motion of the mandible (Table 4.1). Additionally, the non-significant increase in closing phase pitch angular velocity post-injection suggests that the horses may have closed their mouths slightly faster. This was not simply a function of having less distance for the jaw to travel and is not unexpected, as human patients with TMJ disease commonly report pain on opening the mouth and reduced vertical limits of the mandible (Celic et al. 2004; Yoon et al. 2007). Similarly, veterinary practitioners have reported anecdotally that horses with

TMJ disease show resentment to opening the full mouth speculum and reduced voluntary opening of the mandible during dental equilibration and mastication.

Analyses of the total rostrocaudal and lateromedial directions were not significantly different pre- and post- LPS injection (Table 4.1). However, analysis of the rostrocaudal movement during each of the masticatory phases (opening, closing and power strokes), indicated that while the opening phase of the cycle is almost identical pre- and post-injection, the closing and power strokes are significantly different (Figure 4.3). Pre-injection data shows that the rostral movement of the mandible occurs during the closing stroke and that during the power stroke, when the cheek teeth are in occlusion and the feed material is being masticated, there is no rostral movement. The data makes biological sense given that the primary movement for these herbivores is lateral. If the lophs and don'ts of the occlusal surfaces are in contact and being compressed, there is no ability for rostral movement. Conversely, after LPS injection there is very little mandibular movement during the closing phase and during the power stroke a rostrolateral motion occurs, bringing the mandible into the correct position to begin the opening phase. For this sliding motion to occur during the power stroke, either the teeth are not in occlusion or the feed material is being grasped and sheared with substantially less force allowing the mandible to slide. The highest bite forces occur during the closing and power strokes of the cycle (Staszuk et al. 2006). Our data suggests that the change in the rostrocaudal motion during the masticatory cycle may be due to a reluctance by the horses to generate pre-injection bite forces during the power stroke in an effort to ameliorate pain. This may have the added effect of creating a poorly chewed cylindrical feed bolus which is ejected as a quid (Collinson 1994).

These horses developed clinical signs of synovitis following intraarticular LPS injection, similar to those previously reported by this research group (Carmalt et al. 2011). While clinical signs were not uniform throughout all horses, the majority developed marked effusions within the left TMJs, which were subjectively warm to the touch; two of these subjects began regular quidding. Despite these findings, horses failed to exhibit avoidance behaviour to palpation and none of the horses were hesitant to eat. We speculate that this behavioural modification may be a reason that DJD of the equine TMJ is so difficult to characterize and clinically evaluate. Alternatively, a greater dose of LPS may have been needed to obtain detectable clinical TMJ

changes in all horses. This suggests that the ability to eat is not necessarily reflective of the amount of pain experienced by the horse.

The current study suggests that LPS-induced inflammation of the TMJ is associated with pain. Avoidance of pain during mastication leads to a divergence of the normal masticatory cycle, possibly reducing the efficiency of the occlusal surface to grind feed. Bonin et al. (2007) reported that there was a greater mediolateral mandibular excursion exhibited by horses eating long stem fibre, than when eating feed materials of shorter length (Bonin et al. 2007). After data collection was complete, we fed grain and short leaf chaff to the horses that had developed quidding, theorizing that short fibre length feed would require less mandibular excursion and result in less pain. Neither of these feed materials resulted in quidding behaviour (data not shown). This anecdotal observation leads us to speculate that horses might mitigate TMJ pain by changing their eating habits, allowing them to maintain weight and body condition without showing overt signs of disease.

The current study is limited by the small sample size and the addition of more horses may have revealed more differences in the kinematic variables following LPS administration. Although the TMJs were assessed subjectively prior to entry into the study, no diagnostic imaging was performed. The radiographic determination of 'diseased' or 'a clinically significant change' has yet to be established for this joint and thus any deviation from normal would have been difficult to interpret. Thus, it is possible that some of these horses may have had degenerative changes. Nevertheless, in our population of horses, LPS injection into the TMJs resulted in an alteration of masticatory kinematics but the mode of this transient inflammation may be different from that occurring in naturally acquired disease, especially if chronic. By consistently injecting the left TMJ with LPS, there was a risk of creating bias; however, randomizing the side of injection would have greatly reduced the power of the study. Control horses were not used as the objective of the research was not to test whether LPS created inflammation but rather to evaluate what effect inflammation of the joint would have on masticatory kinematics, irrespective of the causative agent. Furthermore, using this study design, each horse was their own control.

This study indicates that inflammation of the TMJ, simulated by intrarticular injection of LPS, causes sufficient discomfort to significantly alter the kinematics of the mandible during mastication. Horses continued to feed, in most cases without overt signs of discomfort. The subclinical adaptations occurring may confer an evolutionary advantage to these animals as a whole but may confound current veterinary clinical examination.

4.6 Footnotes:

¹Phoenix Technologies Inc., Burnaby, British Columbia, Canada.

²Bayer Inc. Toronto, Ontario, Canada.

³Sigma-Aldrich Canada, Oakville, Ontario, Canada.

⁴Mathworks, Natick, Massachusetts, USA.

⁵IBM Corporation, Armonk, New York, USA.

4.7 References:

Baker, G.J. (2005) Dental physiology. In: Equine Dentistry, 2nd edn., Eds: G.J. Baker and J. Easley, Elsevier, London. pp 49-54.

Barnett, T.P., Powell, S.E., Head, M.J. et al. (2014) Partial mandibular condylectomy and temporomandibular resection for chronic, destructive, septic arthritis of the temporomandibular joint. Equine Vet Educ. 26, 59-63.

Bienert-Zeit, A. and Rötting, A. (2011) Unilateral mandibular condylectomy in an adult warmblood gelding. Pferdeheilkunde. 27, 231-236.

Boening, K.J. (2012) Temporomandibular joint disorders. In: Equine Surgery, 4th edn., Eds: J.A. Auer and J.A. Stick, Elsevier, London. pp 1452-1454.

Bonin, S.J., Clayton, H.M., Lanovaz, J.L. et al. (2006) Kinematics of the equine temporomandibular joint. Am J Vet Res. 67, 423-428.

Bonin, S.J., Clayton, H.M., Lanovaz, J.L. et al. (2007) Comparison of mandibular motion in horses chewing hay and pellets. Equine Vet J. 39, 258-262.

Carmalt, J.L. (2011) Dental physiology. In: Equine Dentistry, 3rd edn., Eds: J. Easley, P.M. Dixon and J. Schumacher, Elsevier, London. pp 77-84.

Carmalt, J.L., Bell, C.D., Tatarniuk, D.M. et al. (2011) Comparison of the response to experimentally induced short-term inflammation in the temporomandibular and metacarpophalangeal joints of horses. Am J Vet Res. 72, 1586-1591.

Carmalt, J.L. and Wilson, D.G. (2005) Arthroscopic treatment of temporomandibular joint sepsis in a horse. Vet Surg. 34, 55-58.

Celic, R., Jerolimov, V. and Knezovic, Z.D. (2004) Relationship of slightly limited mandibular movements to temporomandibular disorders. Braz Dent J. 15, 151-154.

Collinson, M. (1994) Food processing and digestibility in horses (*Equus caballus*). BSc dissertation, Monash University, Melbourne, Victoria, Australia.

Leue, G. (1941) Beziehungen zwischen Zahnanomalien und Verdauungsstörungen beim Pferde unter Heranziehung von Kaubilden. Veterinary Medicine Dissertation, University of Hannover, Hannover. pp 170-174.

Nagy, A.D. and Simhofer, H. (2006) Mandibular condylectomy and meniscectomy for the treatment of septic temporomandibular joint arthritis in a horse. Vet Surg. 35, 663-668.

May, K.A., Moll, D.H., Howard, R.D. et al. (2001) Arthroscopic anatomy of the equine temporomandibular joint. *Vet Surg.* 30, 564-571.

Ramzan, P.H.L. (2006) The temporomandibular joint: component of clinical complexity. *Equine Vet J.* 38, 102-104.

Rodriguez, M.J., Agut, A., Gil, F. et al. (2006) Anatomy of the equine temporomandibular joint: study by gross dissection, vascular injection and section. *Equine Vet J.* 38, 143-147.

Rodriguez, M.J., Agut, A., Soler, M. et al. (2010) Magnetic resonance imaging of the equine temporomandibular joint anatomy. *Equine Vet J.* 42, 200-207.

Rodriguez, M.J., Latorre, R., Lopez-Albors, O. et al. (2008) Computed tomographic anatomy of the temporomandibular joint in the young horse. *Equine Vet J.* 40, 566-571.

Soderkvist, I. and Wedin, P. (1993) Determining the movements of the skeleton using well-configured markers. *J Biomechanics.* 26, 1473- 1477.

Stadtbäumer, G., and Boening, K.J. (2002) Diagnostische und minimal-invasive Verfahren am Kiefergelenk des Pferdes. *Tieraerztl Prax.* 30, 99-100.

Staszyk, C., Lehmann, F., Bienert, A. et al. (2006) Measurement of masticatory forces in the horse. *Pferdeheilkunde.* 22, 12-16.

Weller, R., Cauvin, E.R., Bowen, I.M. et al. (1999a) Comparison of radiography, scintigraphy and ultrasonography in the diagnosis of a case of temporomandibular joint arthropathy in a horse. *Vet Rec.* 144, 377-379.

Yoon, H. J., Baltali, E., Zhao, K.D. et al. (2007) Kinematic study of the temporomandibular joint in normal subjects and patients following unilateral temporomandibular joint arthrotomy with metal fossa-eminence partial joint replacement. *Int J Oral Max Surg.* 65, 1569-1576.

CHAPTER 5: A HISTOLOGIC ASSESSMENT OF AGE-RELATED CHANGE IN THE EQUINE TEMPOROMANDIBULAR JOINT

Due to the putative link between age and equine TMJD, previously established in chapter three, chapter five examines equine TMJs for histologic age-related changes that occur in clinically normal subjects. While not considered pathologic, the accumulation of age-related change may predispose to the development of pathologic processes.

Copyright statement: Chapter 5 has not yet been submitted for publication.

Full citation: Smyth, T., A.L. Allen, J.L. Carmalt. (2017) A histologic assessment of age-related change in the equine temporomandibular joint.

Author contributions: Smyth was responsible for collection and sectioning of the TMJs. Histologic assessment of age-related change was performed by Allen. Analysis of the data and write-up of the article were performed by Smyth and Carmalt.

CHAPTER 5: A HISTOLOGIC ASSESSMENT OF AGE-RELATED CHANGE IN THE EQUINE TEMPOROMANDIBULAR JOINT

T. Smyth, DVM, BSc[†], A. L. Allen, DVM, MVetSc, PhD[‡]

and J. L. Carmalt, VetMB, MVetSc, FRCVS, DABVP, DAVDC, DACVS, DACVSMR[†]

Institutional affiliations: [†]Department of Large Animal Clinical Sciences, Western College of Veterinary Medicine, University of Saskatchewan; and [‡]Department of Veterinary Pathology, Western College of Veterinary Medicine, University of Saskatchewan, Saskatoon, Saskatchewan.

Source of funding: No sources of funding were provided for this project.

Authors' declaration of interests: No conflicts of interest have been declared.

Ethical animal research: No ethical review was required in this study as no live horses were used in this study's completion.

5.1 Introduction:

The development of OA is a significant clinical problem in many species. It is estimated to account for 60% of equine lameness and once initiated, is irreversible and always progressive (Caron and Genovese 2003; McIlwraith et al. 2012). The apparent inability of articular cartilage to completely heal leads to accumulated damage, increasing the prevalence of clinically apparent disease in aging populations (Brommer et al. 2003; Dillon et al. 2006; Loeser 2009). Abnormal development aside, arthritis can develop acutely following a single traumatic incident, or chronically through a series of smaller concussive forces (Frisbie 2012). However, the incidence of clinically apparent OA is not equal amongst all joints, and while certain changes accumulate with age, these changes can also occur irrespective of the development of OA (Loeser 2009).

Age-related changes in joints can appear in many forms. Some changes are considered innocuous, having no pathologic basis, while others can decrease the joint's resistance to the formation of OA, or even be directly responsible for the formation of disease (Sokoloff 1983). For example, subchondral bone has the ability to remodel based on applied forces, but the degree of remodelling can change with age. Evidence suggests that the end product is less compliant, leading to a joint that is prone to the development of OA (Bolam et al. 2006; Frisbie 2012). The mandibular condyles begin as globoid in shape in young individuals and progressively flattening over time in equids and rats (Chen et al. 1989; Carmalt et al. 2016). Rodriguez et al. (2006) also noted that the central fibrocartilaginous disc of older horses is markedly thinner than younger individuals. While never tested in horses, the reduction in disc thickness is likely due to a loss of biochemical content (water and hyaluronate), thereby reducing cushioning properties and increasing disc friction, as animals age (Nakano and Scott 1996). Without the use of histologic or biochemical analyses the differentiation between age-related and osteoarthritic change in the equine TMJ remains speculative.

In other species, histologic grading systems have been used to evaluate either OA, or age-related changes of different joints, including the TMJ (Chen et al. 1989; Luder 1998; Wadhwa et al. 2005; Pritzker et al. 2006; Leonardi et al. 2010; McIlwraith et al. 2010; Pauli et al. 2011;

Pearson et al. 2011). Unfortunately, there is no complete histologic description for this unique joint. The objective of this study was to describe the histologic changes occurring within the TMJ of a sample of clinically normal horses of varying ages. The hypothesis was that as horses age, the TMJs developed signs of age-related change that is consistent with other joints.

5.2 Methods:

The heads of 11 horses, selected by convenience sample, were frozen and categorized based on the horses' age at the time of euthanasia. Each horse in this study had been euthanized for reasons unrelated to the head or TMJs. Using a band saw, both TMJs were removed from each head and sectioned in 5 mm slices. The orientation of the slices of each joint were chosen at random to be either in the transverse or sagittal direction. Once sectioned, each joint was stored separately in 10% neutral buffered formalin, until fixed. Soft tissues were removed and each joint was disarticulated; the discs were sectioned and processed (i.e, embedded in paraffin, cut at 4 μ m, mounted on glass slides, stained with haematoxylin and eosin, and cover slipped) for routine microscopic examination. The bones of each joint were placed in 20% formic acid until decalcified and processed in a similar manner. Microscopic examination of the TMJs was performed using a modified Mankin scoring (Mankin 1974; Van der Sluijset et al. 1992) system and assessed by a veterinary pathologist (A.L.A.).

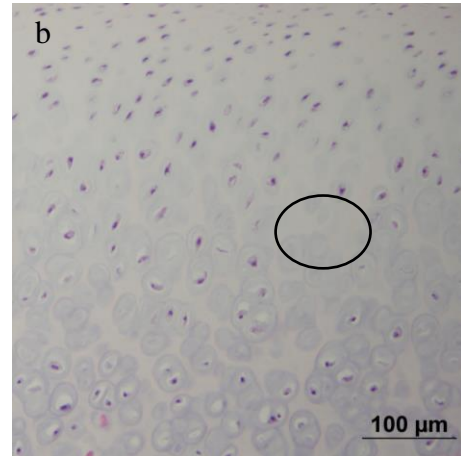
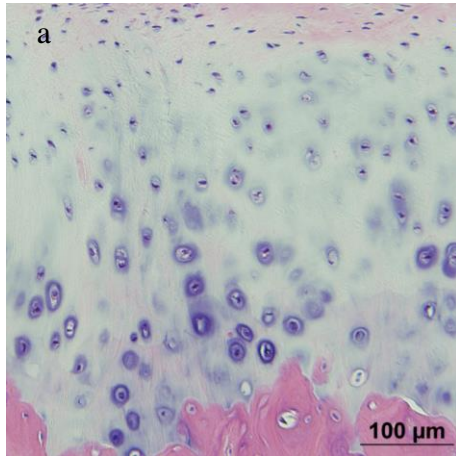
Sections of the mandibular and temporal condyles were assessed for regions of acellularity (20X magnification), chondrocyte clusters and large chondrones. Large chondrones were defined as six or more chondrocytes to a cluster. Each characteristic was graded from a score of zero to two, making up a total condylar score of a possible six points (Table 5.1, Figure 5.1). The fibrocartilaginous discs were assessed for decreased cellularity, individual scattered metaplastic chondroid cells, at least one focus of metaplasia, and at least one focus of osseous metaplasia. Each characteristic was interpreted as present or absent from the sample (ranging from zero to one), making up a total disc score that ranged from zero to four possible points (Table 5.1, Figures 5.2).

Table 5.1: Scoring criteria for histologic assessment of the TMJs, by region for each of the condyles and the central disc. The total possible range per region is from 0 to 16.

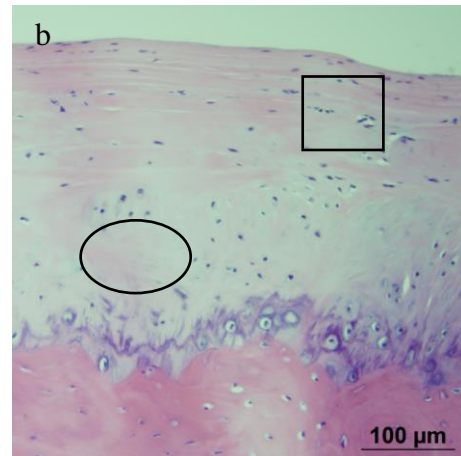
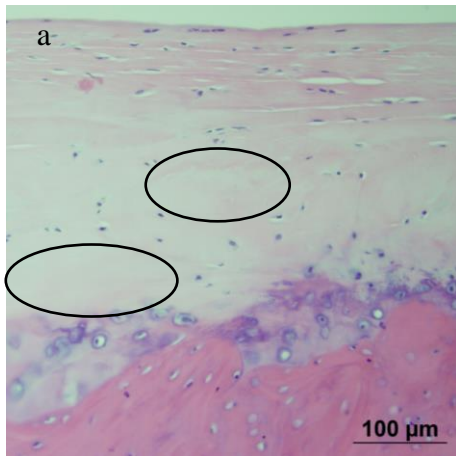
Condyle (Mandibular/Temporal)	Score
I Areas of decreased cellularity	
None	0
Multiple	1
Coalescing	2
II Chondrocyte clusters	
None	0
Rare	1
Several	2
III Large chondrones	
None	0
Rare	1
Several	2
Central disc	
I Areas of decreased cellularity	
No	0
Yes	1
II Scattered individual metaplastic chondroid cells	
No	0
Yes	1
III Focus of chondroid metaplasia(≥ 1)	
No	0
Yes	1
IV Focus of osseous metaplasia (≥ 1)	
No	0
Yes	1

Figure 5.1: A summary of the histologic changes seen within the articular cartilages of the TMJs of horses within three separate AGs (Legend on Page 80).

AG 1



AG 2



AG 3

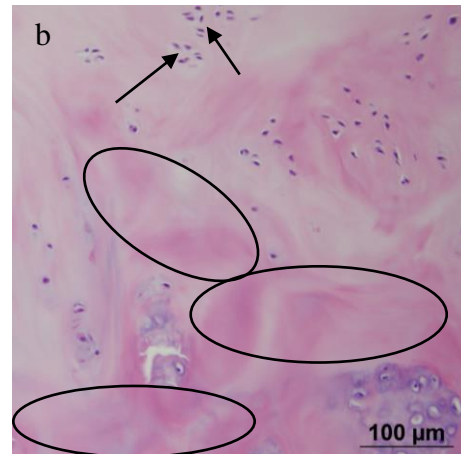
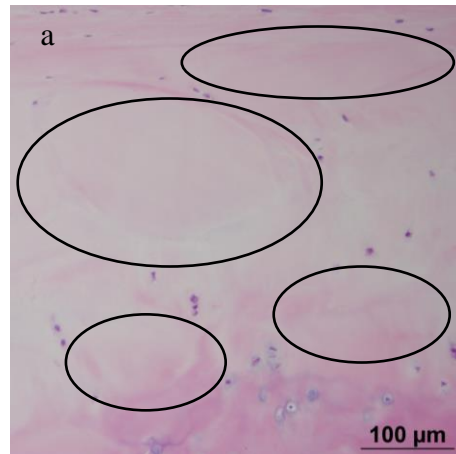
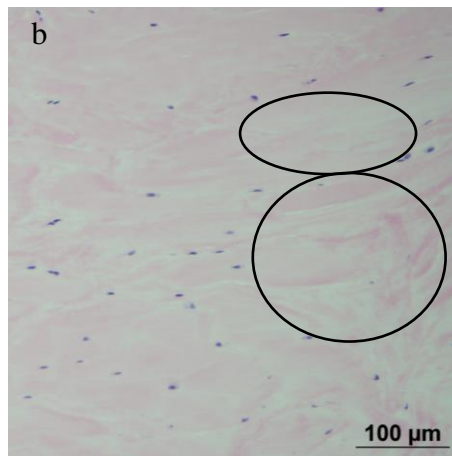
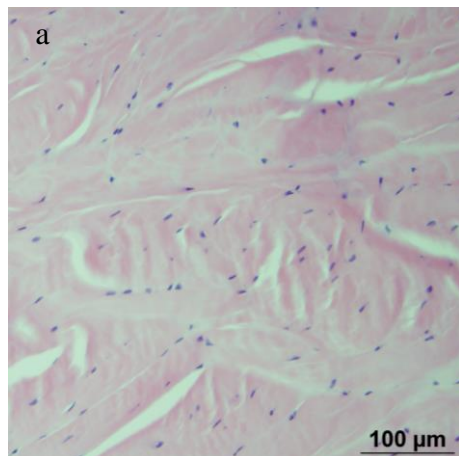
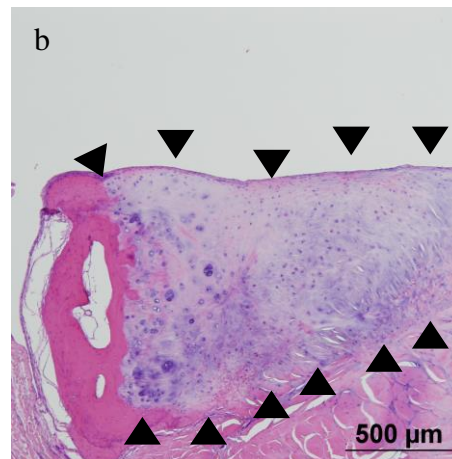
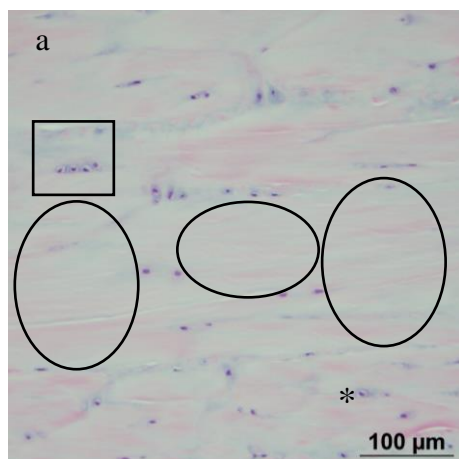


Figure 5.2: A summary of the histologic changes seen within the central discs of the TMJs of horses within three separate AGs (Legend on Page 80).

AG 1



AG 2



AG 3

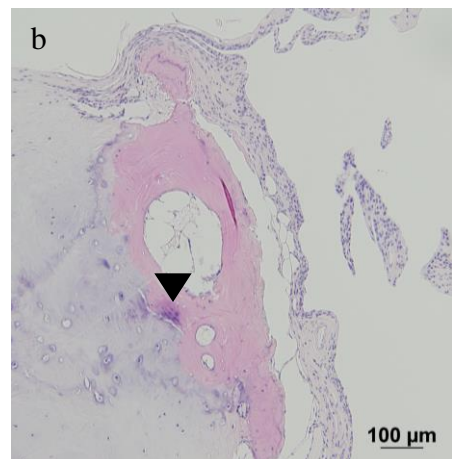
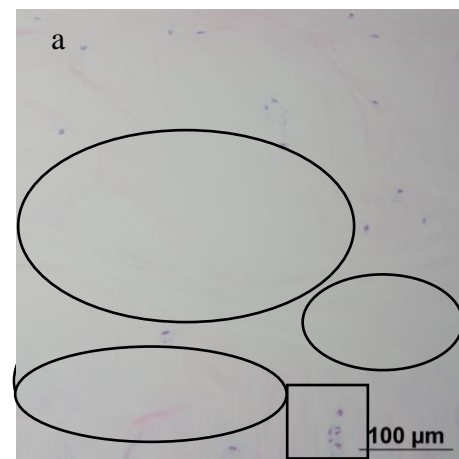


Figure Legends:

Figure 5.1: The two slides in each AG (a and b) are representative samples highlighting the characteristics that were used to evaluate age-related change in this study. Age group 1 possessed numerous, uniformly distributed chondrocytes. Regions of acellularity (ovals) increased in frequency with increasing AG, becoming multifocal to coalescing regions of acellularity, as seen in AG 3. Chondrocytes formed clusters with increasing frequency by AG (squares). Six or more chondrocytes in a cluster were defined as large chondrones (arrows) and also increased in frequency with age.

Figure 5.2: The two slides in each AG (a and b) are representative samples highlighting the characteristics that were used to evaluate age-related change in this study. AG 1 possessed numerous, uniformly distributed chondrocytes. Regions of acellularity (ovals) increased in frequency with increasing AG. Chondroid metaplasia accumulated with increasing AG, starting as scattered individual metaplastic cells (asterisk) and later becoming aggregated into foci of more than one cell (squares). Foci of osseous metaplasia were also noted to increase with corresponding AG (triangles).

There were five geldings and five mares (one sex not recorded). Horses ranged from two to 32 years of age. Horses were categorized into three AGs, based on age. Horses two to 10 years of age (n = 3) were considered AG 1, those between 11 and 20 years old (n = 3) were AG 2 and horses > 20 years old (n = 5) were AG 3. Each variable (Table 5.1) was the summation of each of the condyles and the disc, generating a mandibular condyle score, a temporal condyle score, and a disc score. The total joint score was the sum of each of these three components (mandibular condyle, temporal condyle, and disc score). Finally, a total horse score was created, which was the sum of both joints (left and right) in a single horse. A Mann –Whitney U test was used to examine the differences between sexes (male or female). The left and right TMJs, and potential differences between sagittal and frontal sections within horse were examined using a Wilcoxon sign-rank test. Differences in mean rank between total joint, total condylar and total disc score, as well as between the total score of the various histologic variables, between AGs were evaluated using a Kruskal-Wallis test with post-hoc comparisons performed using a Tukey's test where necessary. Significance was set at $p < 0.05$.

5.3 Results:

Neither the total horse score, nor the total joint score was significantly different between sexes ($p > 0.68$). Overall there was no significant difference between the total joint score in the left versus the right joints, within each horse ($p = 0.43$), nor of its composites; the condylar score ($p = 0.12$) or the disc score ($p = 0.84$). There was no significant effect of section-type (sagittal or frontal) on total horse score ($p = 0.43$). However, there was a significant effect of section-type on joint score ($p = 0.003$), with the animals whose joints were sectioned sagittally, having a greater mean rank (14.85) than those sectioned in the frontal plane (6.67). There were significant differences noted between variable scores and AG when dividing the data by plane of histologic section (Tables 5.2 and 5.3). This was a result of an increased number of sections being present in the sagittally cut versus the frontally cut plane.

Overall, when controlling for plane of section, there was a significant difference ($p = 0.003$) in total joint score between AGs. Horses in AG 1 had a significantly lower total joint score ($p = 0.002$) than those in AG 3; however, there was no significant difference between total joint scores of horses in AG 1 and AG 2 ($p = 0.17$), nor between AGs 2 and 3 ($p = 0.67$). Condylar score differed by AG ($p < 0.001$), with AG 1 being different from AG2 ($p = 0.03$) and AG 3 ($p < 0.001$), but no difference between AG 2 and AG 3 ($p = 0.39$). There was an effect of AG on total disc score ($p < 0.001$), with AG 1 not being significantly different from AG 2 ($p = 0.05$), but different from AG 3 ($p < 0.001$), and AG 2 being significantly different from AG 3 ($p = 0.02$).

Similarly, the total horse scores (the sum of left and right total joint scores) were significantly different between AGs ($p = 0.01$; Figure 5.1). Age group 1 was not significantly different from AG 2 ($p = 0.81$), but was different from AG 3 ($p = 0.01$). Age groups 2 and 3 were also not significantly different ($p = 0.23$).

5.4 Discussion:

Little work regarding the role of age-related changes in the joints of horses has been performed (Van Turnhout et al. 2008). Sokoloff (1983) suggested that age-related changes can be divided into three lines of progression. Firstly, where alterations occur independently of structural degeneration of the joint. Secondly, where mild structural alterations occur in relation to age, but are unlikely to result in deformation of the joint. Thirdly, where clinical disability results from the overt osteoarthritic deformity of age-related change (Sokoloff 1983). Unfortunately, it is difficult to know whether each of these lines of progression serve as separate entities or are merely a continuum of severity that ultimately leads to OA. The lack of clarity between the characteristics of age-related change and those of OA makes separation of the two processes difficult. Existing models of OA utilize many of the same grading characteristics as those attempting to determine age-related change, requiring clinical manifestation of disease to be the deciding factor (Bouvier 1987; Luder 1998; Loeser 2009; Leonardi et al. 2010; Pauli et al. 2011; Pearson et al. 2011).

Figure 5.3: Box and whisker plot describing the sum of the total joint score by age group
(The thick black line represents the 50th percentile and the error bars establish 95% C.I.

* = 32-year-old horse that was substantially older than the rest of the horses in the study).

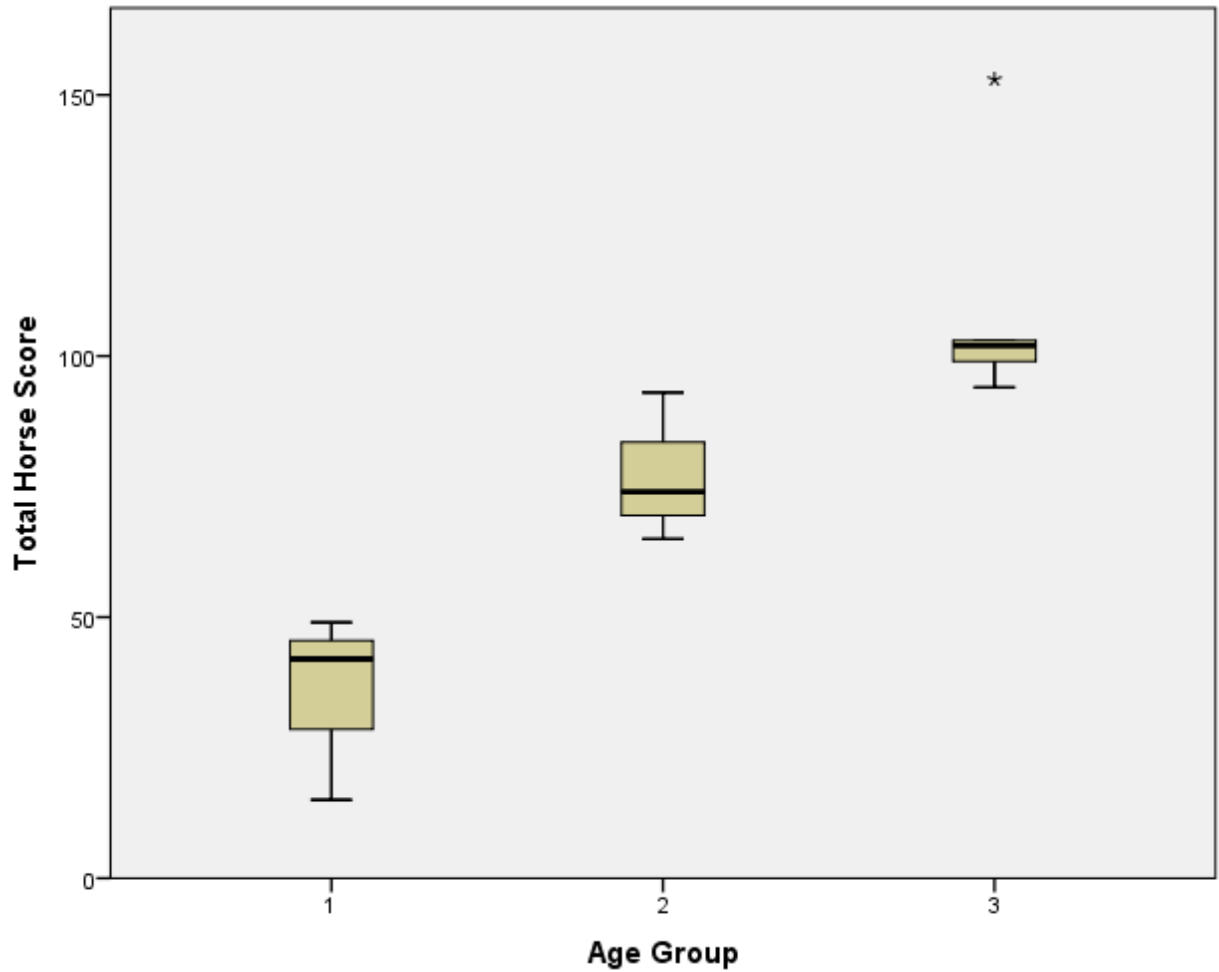


Table 5.2: Total variable scores by anatomic region, sectioned in the sagittal plane, by age group (Pairwise comparisons were not performed when P values did not meet the criteria for significance).

Anatomical Location	Histologic Variable	AG 1 Median (Min – Max)	AG 2 Median (Min – Max)	AG 3 Median (Min – Max)	P value	Pairwise Comparisons
Mandibular Condyle	Areas of Decreased Cellularity	6.0 (2-7)	7.0 (6-9)	8.5 (6-14)	0.13	No Score
Mandibular Condyle	Chondrocyte Clusters	4.0 (0-7)	5.5 (5-6)	7.0 (6-8)	0.04	AG1 - AG2 = 0.88 AG1 - AG3 = 0.04 AG2 - AG3 = 0.04
Mandibular Condyle	Large Chondrones	0.0 (0-0)	3.3 (3-5)	7.0 (2-8)	0.02	AG1 - AG2 = 0.38 AG1 - AG3 = 0.01 AG2 - AG3 = 0.54
Temporal Condyle	Areas of Decreased Cellularity	6.0 (3-8)	8.0 (6-9)	11.5 (8-14)	0.02	AG1 - AG2 = 1.00 AG1 - AG3 = 0.03 AG2 - AG3 = 0.12
Temporal Condyle	Chondrocyte Clusters	1.0 (0-6)	5.0 (4-6)	7.0 (7-8)	0.008	AG1 - AG2 = 1.00 AG1 - AG3 = 0.004 AG2 - AG3 = 0.52
Temporal Condyle	Large Chondrones	0 (0-3)	4.5 (4-5)	6.5 (3-7)	0.02	AG1 - AG2 = 0.35 AG1 - AG3 = 0.02 AG2 - AG3 = 0.76
Intraarticular Disc	Areas of Decreased Cellularity	7.0 (6-7)	6.0 (5-6)	7.0 (6-8)	0.03	AG1 - AG2 = 0.42 AG1 - AG3 = 1.0 AG2 - AG3 = 0.02
Intraarticular Disc	Scattered Individual Metaplastic Chondroid Cells	0.0 (0-2)	3.0 (3-5)	7.0 (6-7)	0.006	AG1 - AG2 = 0.58 AG1 - AG3 = 0.005 AG2 - AG3 = 0.17
Intraarticular Disc	Focus of Chondroid Metaplasia (≥ 1)	0.0 (0-0)	1.5 (0-4)	5.0 (2-6)	0.01	AG1 - AG2 = 0.84 AG1 - AG3 = 0.01 AG2 - AG3 = 0.20
Intraarticular Disc	Focus of Osseous Metaplasia (≥ 1)	0.0 (0-0)	0.5 (0-2)	1.0 (1-2)	0.06	No Score

Table 5.3: Total variable scores by anatomic region, sectioned in the frontal plane, by age group (Pairwise comparisons were not performed when P values did not meet the criteria for significance).

Anatomical Location	Histologic Variable	AG 1 Median (Min – Max)	AG 2 Median (Min – Max)	AG 3 Median (Min – Max)	P value	Pairwise Comparisons
Mandibular Condyle	Areas of Decreased Cellularity	3.0 (0-3)	4.5 (3-6)	4.0 (3-6)	0.16	No Score
Mandibular Condyle	Chondrocyte Clusters	1.0 (0-1)	4.0 (3-5)	4.0 (3-5)	0.06	No Score
Mandibular Condyle	Large Chondrones	0.0 (0-0)	0.5 (0-1)	1.5 (0-3)	0.16	No Score
Temporal Condyle	Areas of Decreased Cellularity	2.0 (0-2)	4.5 (4-5)	7 (4-10)	0.051	No Score
Temporal Condyle	Chondrocyte Clusters	0.0 (0-2)	2.5 (2-3)	5.0 (3-7)	0.04	AG1 - AG2 = 1.0 AG1 - AG3 = 0.03 AG2 - AG3 = 0.65
Temporal Condyle	Large Chondrones	0 (0-2)	2.5 (2-3)	3.0 (2-4)	0.09	No Score
Intraarticular Disc	Areas of Decreased Cellularity	4.0 (3-4)	4.0 (3-5)	5.0 (4-6)	0.18	No Score
Intraarticular Disc	Scattered Individual Metaplastic Chondroid Cells	0.0 (0-0)	1.5 (0-3)	3.5 (3-5)	0.048	AG1 - AG2 = 1.0 AG1 - AG3 = 0.047 AG2 - AG3 = 0.54
Intraarticular Disc	Focus of Chondroid Metaplasia (≥ 1)	0.0 (0-0)	1.0 (0-2)	1.5 (0-4)	0.20	No Score
Intraarticular Disc	Focus of Osseous Metaplasia (≥ 1)	0.0 (0-0)	0.5 (0-1)	0.5 (0-1)	0.50	No Score

Figure 5.4: A graphical representation of histologic variables associated with sagittal plane sectioning of the mandibular condyle (Numbers without brackets represent the median section score. Numbers in within the brackets represent the minimum and maximum range).

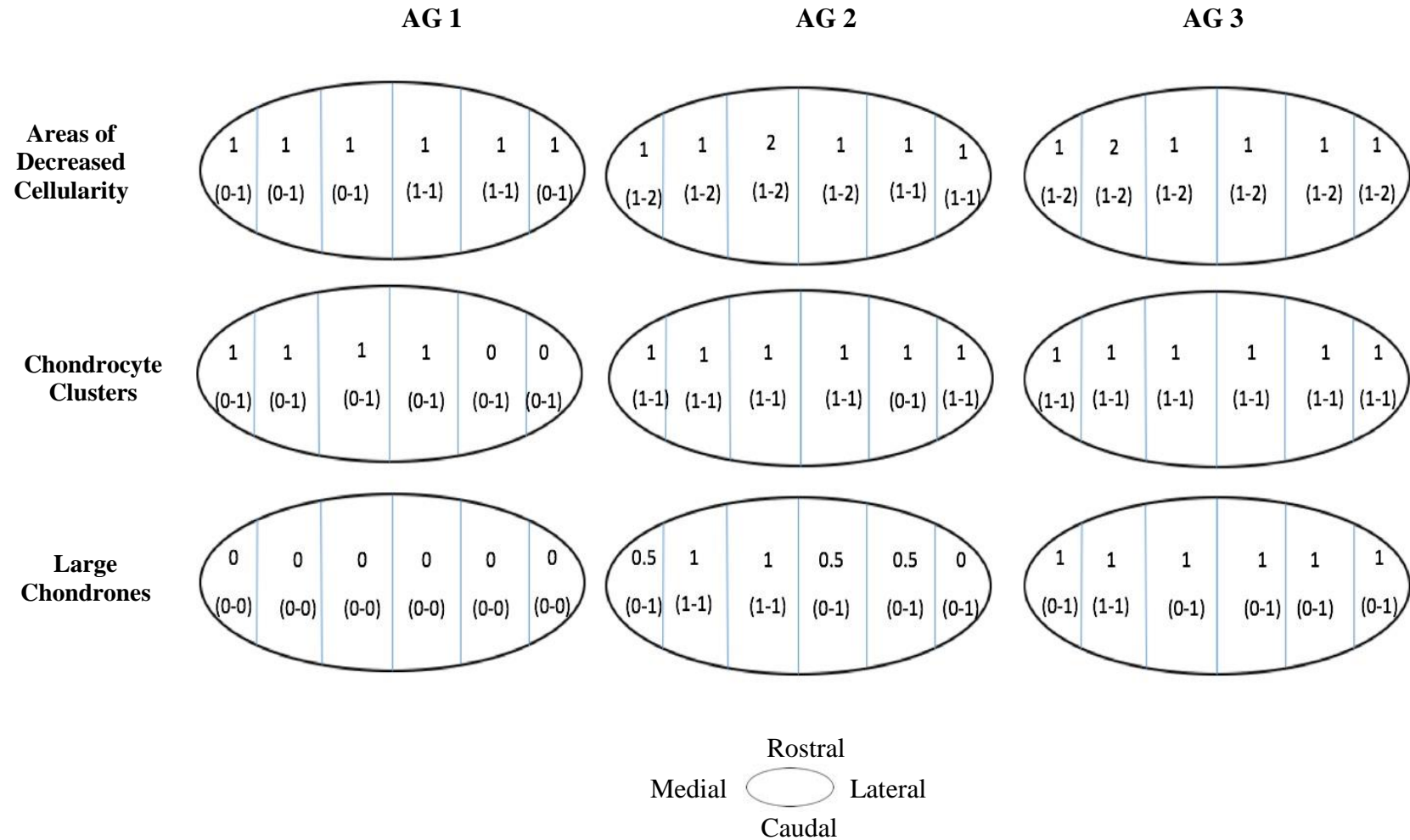


Figure 5.5: A graphical representation of histologic variables associated with frontal plane sectioning of the mandibular condyle (Numbers without brackets represent the median section score. Numbers in within brackets represent the minimum and maximum range).

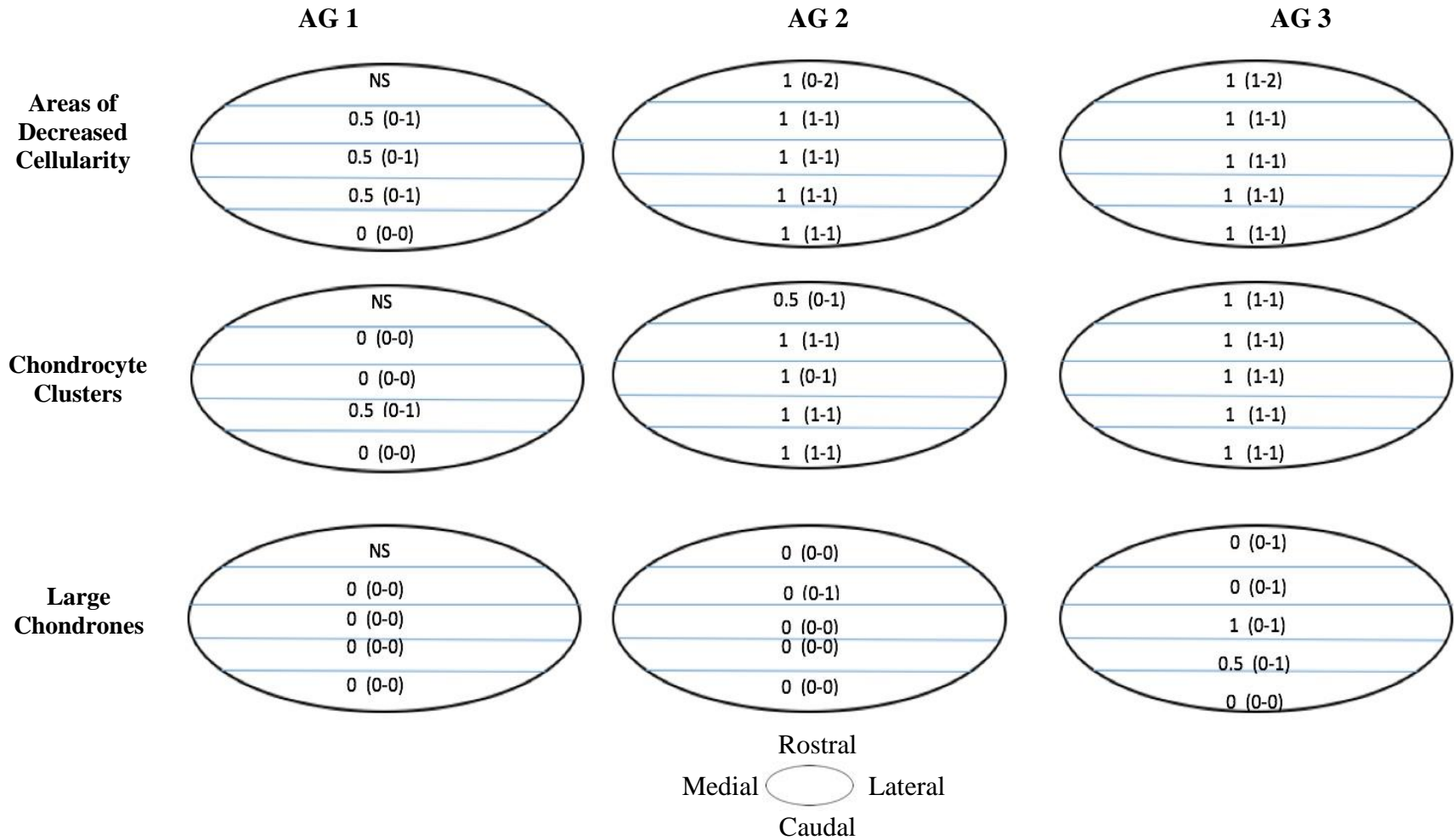


Figure 5.6: A graphical representation of histologic variables associated with sagittal plane sectioning of the temporal condyle (Numbers without brackets represent the median section score. Numbers in within brackets represent the minimum and maximum range).

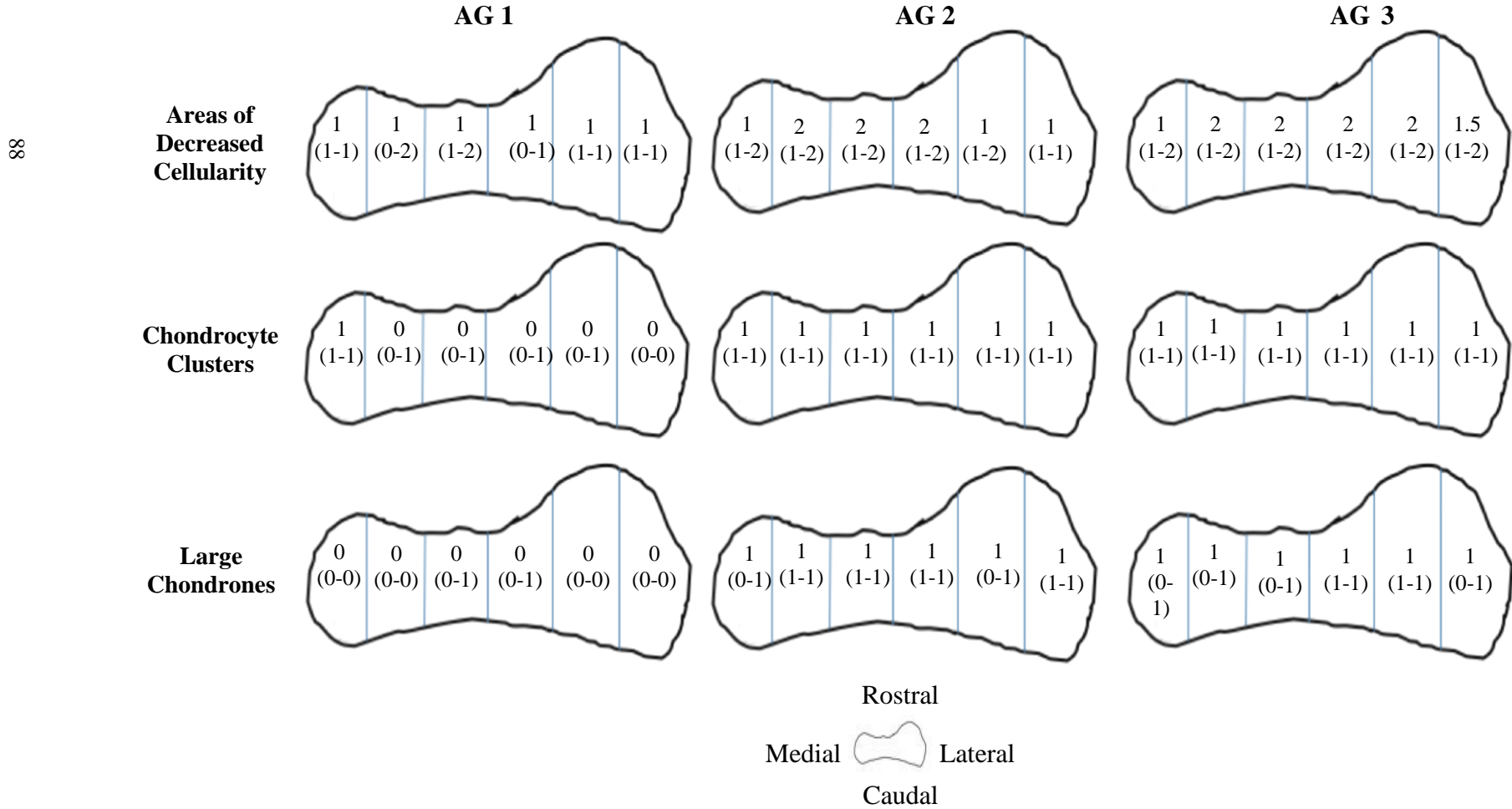


Figure 5.7: A graphical representation of histologic variables associated with frontal plane sectioning of the temporal condyle (Numbers without brackets represent the median section score. Numbers in within the brackets represent the minimum and maximum range. NS or No Score indicates an area that was not assessed).

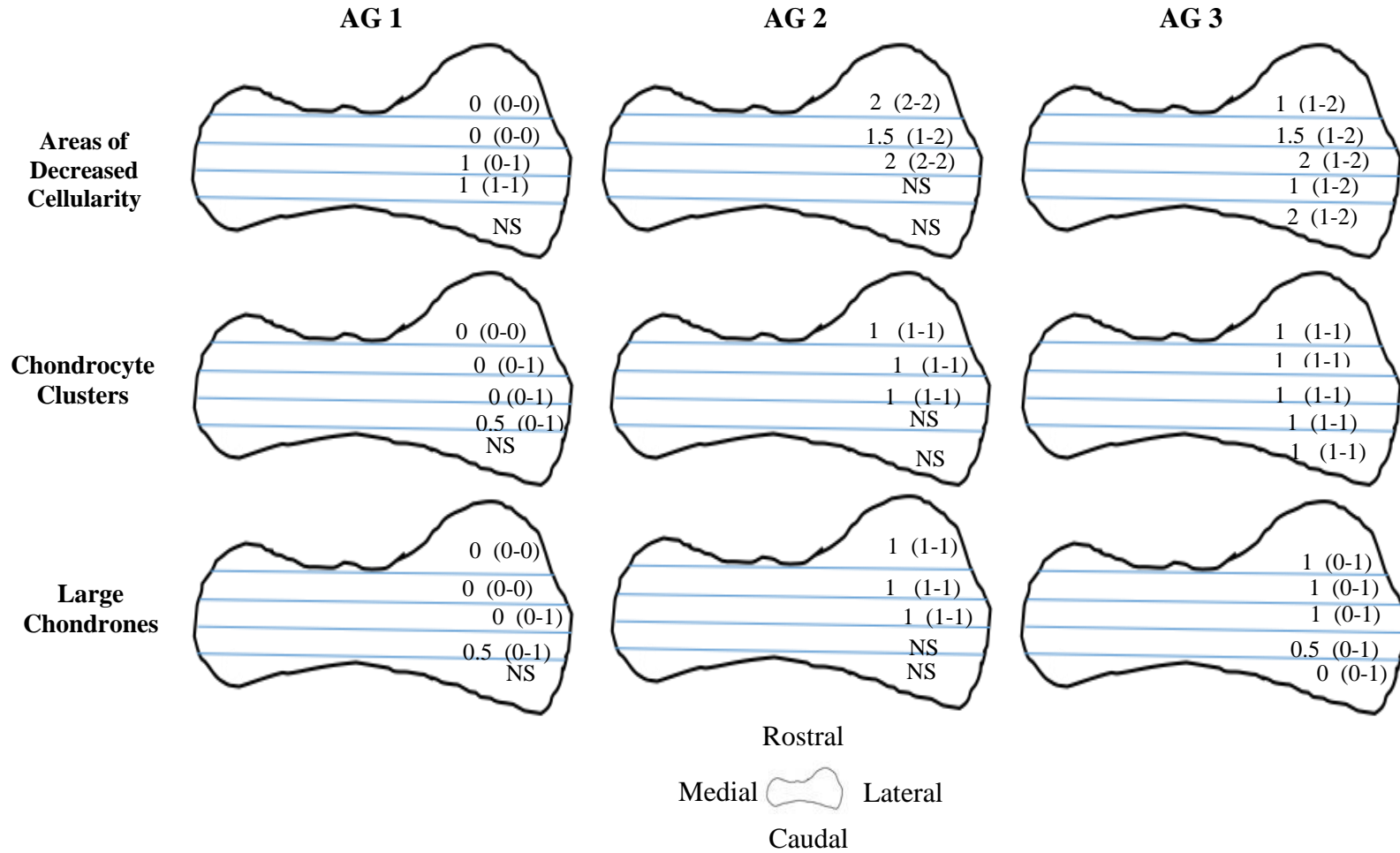


Figure 5.8: A graphical representation of histologic variables associated with sagittal plane sectioning of the fibrocartilaginous disc (Numbers without brackets represent the median section score. Numbers in within the brackets represent the minimum and maximum range).

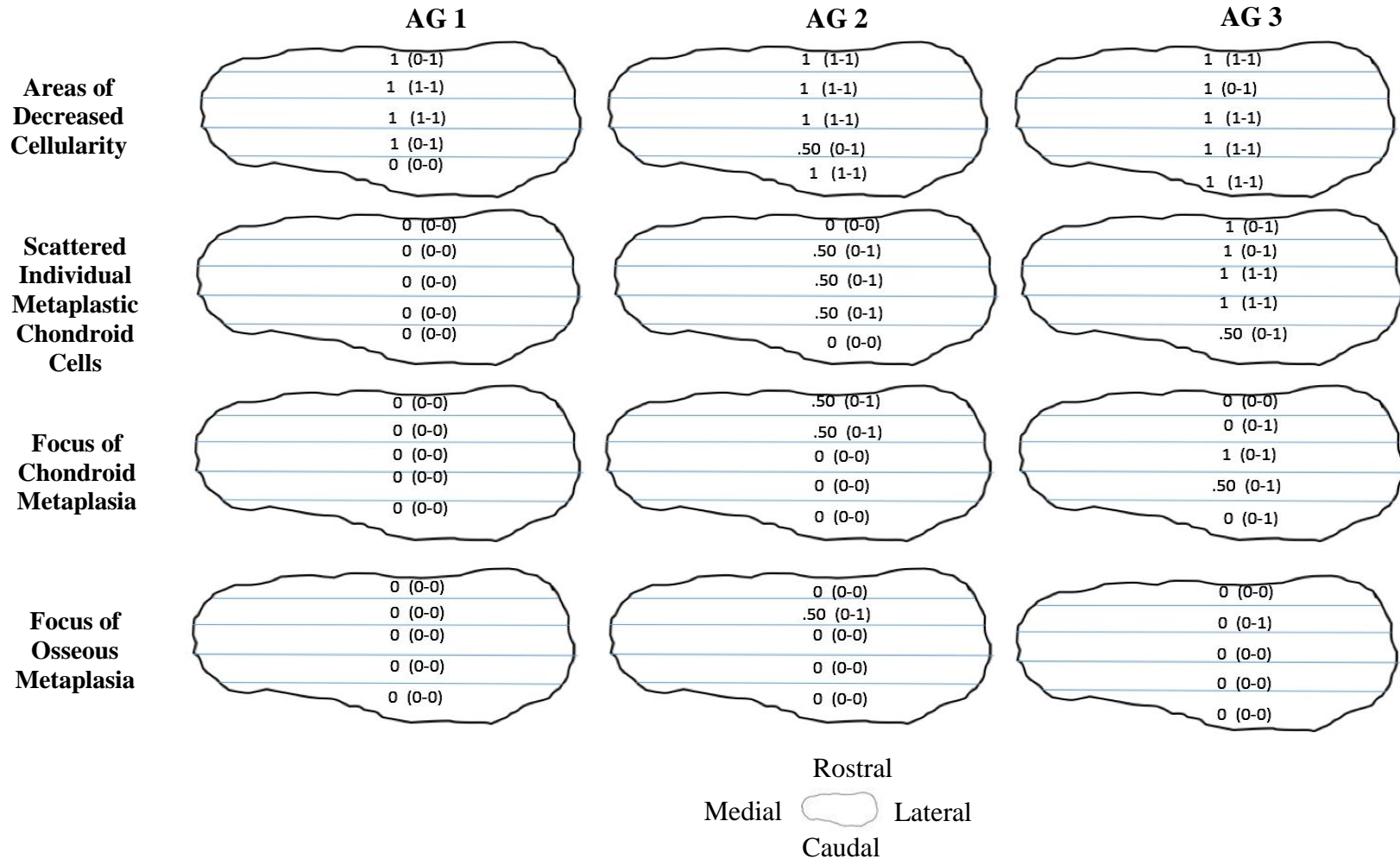
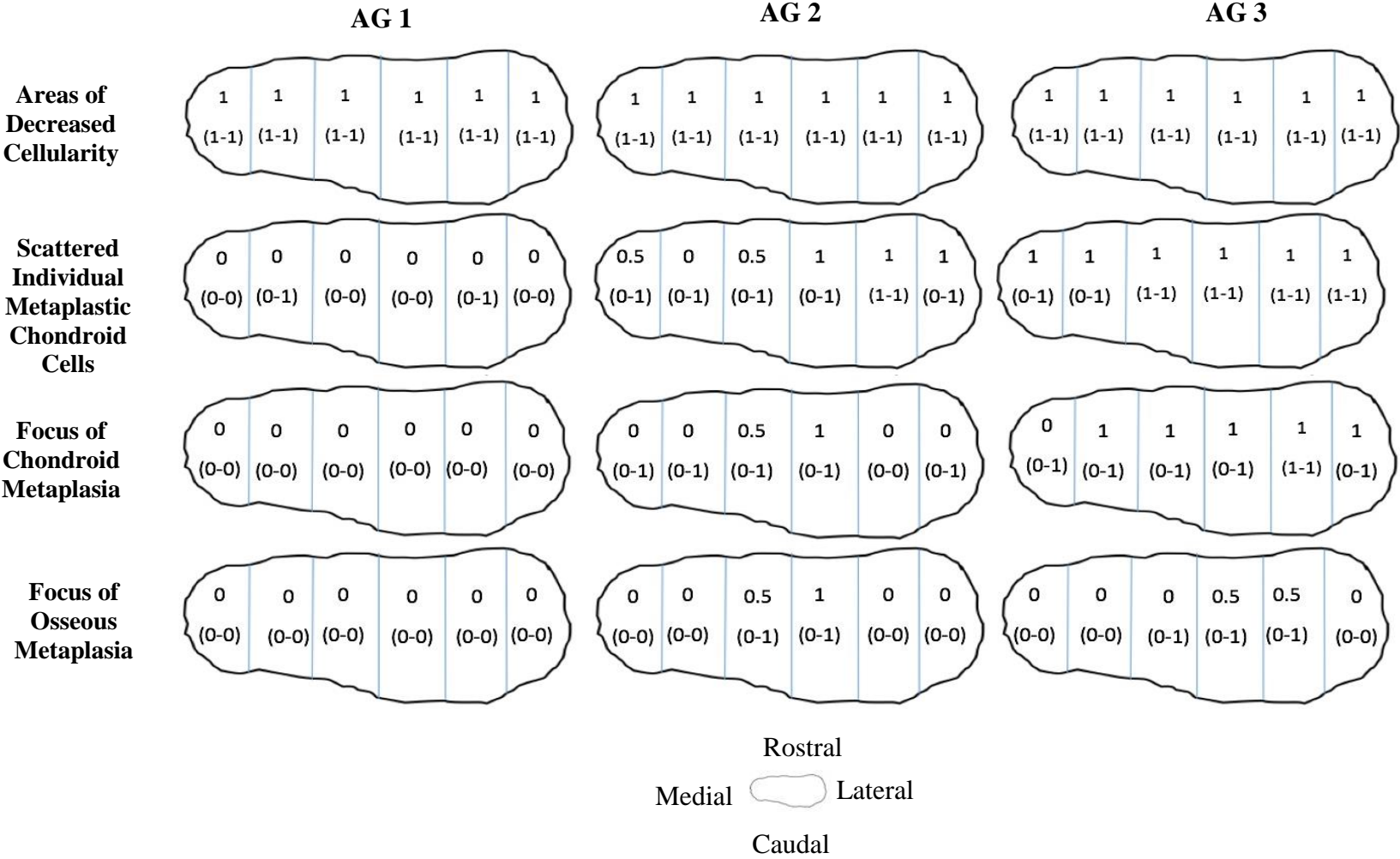


Figure 5.9: A graphical representation of histologic variables associated with frontal plane sectioning of the fibrocartilaginous disc (Numbers without brackets represent the median section score. Numbers in within brackets represent the minimum and maximum range).



Research into the TMJs of rats and humans suggests that the joint can change considerably during growth and early adulthood, having a period of senescence in middle age, and continuing with a second phase of change during later years of life. This is attributed to a decrease in synthetic activity while maintaining the ability for the production of pro-inflammatory mediators and degradative enzymes (Bouvier 1988; Loeser 2009). In support of this, a study by Carmalt et al. (2006) examined the cytokine profiles of equine TMJs of various aged horses found a correlation between advancing age and the production of the pro-inflammatory cytokine IL-8. Many human studies have also reported an increase in OA-related TMJD in older individuals, indicating a possible age-related component to this disease (Bagis et al. 2012; Lamot et al. 2013).

In the current study, several progressive changes were observed to accumulate as horses aged. However, the current lack of histologic information from reported cases of TMJD (Warmerdam et al. 1997; Carmalt and Wilson 2005; Devine et al. 2005; Nagy and Simhofer 2006, Barnett et al. 2014) makes it difficult to discern whether the changes seen here, will ultimately manifest as OA. To answer this question, a histologic assessment of several known cases of TMJD is required. Currently, a single case report discussing the histologic changes within the TMJs of a horse with TMJD, exists (Smyth et al. 2017). Unfortunately, many of the age-related changes seen in the current study (such as chondrone formation and chondro-osseous metaplasia), were also observed in the horse reported. It is possible that the characteristics described as age-related changes in the case report were an incidental finding and typical for a horse of that age (18 years). As osteophytosis was not observed in the current sample of horses, it is possible that the osteophytosis in the case report is a characteristic distinct from age-related change and instead restricted to OA.

Due to its widespread use in the histologic assessment of hyaline cartilaginous joints, assessment of each TMJ was based on a modified Mankin scoring system (Mankin 1974; Van der Sluijset et al. 1992). The scoring characteristics for this unique joint, were adapted from existing scoring systems in the TMJs of other species, as well as subjective trends seen within the condyles and discs of sectioned specimens (Chen et al. 1989; Custers et al. 2007; Wadhwa et al. 2005; Leonardi et al. 2010; McIlwraith et al. 2010; Pauli et al. 2011). Initially, vertical cleft formation was chosen as a possible scoring characteristic due its appearance within TMJs of other species.

However, unlike the scoring systems of existing studies, cleft formation was virtually non-existent in this sample. It is possible that unlike other species, the presence of vertical clefts is an insensitive measure of age-related change within the equine TMJ (Chen et al. 1989). This is supported by a previous study, which examined the TMJs of over 1000 horses, finding that only 0.7% of cases possessed vertical clefts (Carmalt et al. 2016). The low occurrence of this characteristic may suggest that cleft formation within the condyles is restricted to the process of OA and is not seen in normal horses.

The total joint score was not significantly different between left and right joints, within AGs. This is in agreement with other studies and is not surprising, since horses appear to have the ability to masticate interchangeably on both sides of the mandible (Adams et al. 2016, Carmalt et al. 2016, Smyth et al. 2016). As the age of the horse increased, there was a trend towards increasing regions of acellularity and chondrone formation in both the mandibular and temporal condyles (Figures 5.3 to 5.6). Histologic studies of the mandibular condyles in both humans and mice, showed strikingly similar trends towards acellularity and chondrone formation (Luder 1998; Wadhwa et al. 2005).

The fibrocartilaginous discs also showed a decreasing cellularity, chondroid metaplasia and chondro-osseous metaplasia, with age (Figures 5.8 and 5.9). Age-related changes within the TMJ and knee joint in humans have also shown an increase in calcification in aging patients (Luder 1998; Leonardi et al. 2010). Pauli et al. (2011), however, noted that both calcium deposition and vertical clefts formation were only seen in arthritic joints. The horses in AG 1 (youngest) had significantly fewer total joint changes than those in AG 3 (oldest), but neither were significantly different from the horses in AG 2. The continued accumulation of histologic change within joints as horses aged, suggests that the failure of all three groups to be significantly different from one another is likely due to the low power of the study (i.e., a small number of horses in each AG).

It is worth noting that the gross and histologic analysis of one of the youngest horses in the study (two years old), revealed a horizontal cleft within the left mandibular condyle. The cleft was composed of a sclerotic rim that was open to the joint space and yet the horse was clinically normal. This finding was similar to the CT scans reported in an earlier study by Carmalt et al. (2016) which

found that horses younger than one year of age had an increased prevalence of condylar cysts, not seen in older horses. Conversely, the oldest horse in this study (32 years) had acquired several age-related changes but also had no clinical signs of TMJD. It is possible that the clinical difficulty surrounding the diagnosis of TMJD, could lead to sub-clinical cases of affected individuals being mistakenly described as clinically normal (Smyth et al. 2016; Smyth et al. 2017).

A possible limitation of this study is the lack correlation between the inflammatory cytokine concentration and the histological score. Having multiple pathologists to score the joints would have also served to increase the repeatability in future cases of histologic TMJ assessment (Custers et al. 2007; Leonardi et al. 2010). However, as a pilot study, this was beyond the scope of the current research. From this study, it can be seen that clinically normal horses accumulate changes within their TMJs as they age. These are not only similar to the changes seen in the TMJs of other species, but also to hyaline cartilage joints in general. However, without a previous histologic reference to clinical cases of TMJD, the impact of the changes seen in this study remains a question. Future endeavours are underway to validate the current scoring system and report the observed histologic changes within clinical cases of equine TMJD. Examination of the biochemical age-related changes that occur within the TMJ is another possible avenue of exploration.

5.5 References:

Adams, K., Schulz-Kornas, E., Arzi, B. et al. (2016). Functional anatomy of the equine temporomandibular joint: Collagen fiber texture of the articular surfaces. *The Vet Journal*. 217, 58-64.

Barnett, T.P., Powell, S.E., Head, M.J. et al. (2014) Partial mandibular condylectomy and temporal bone resection for chronic, destructive, septic arthritis of the temporomandibular joint in a horse. *Equine Vet Educ*. 26, 59-63.

Bienert-Zeit, A., and Rötting A. (2011) Unilateral mandibular condylectomy in an adult warmblood gelding. *Pferdeheilkunde*. 27, 231-236.

Bouvier, M. (1988) Effects of age on the ability of the rat temporomandibular joint to respond to changing functional demands. *J Dent Res*. 67, 1206-1212.

Brommer, H., VanWeeren, P.R., Brama, P.A et al. (2003) Quantification and age-related distribution of articular cartilage degeneration in the equine fetlock joint. *Equine Vet J*. 35, 697-701.

Carmalt, J.L., Bell, C.D., Tatarniuk, D.M. et al. (2011) Comparison of the response to experimentally induced short-term inflammation in the temporomandibular and metacarpophalangeal joints of horses. *Am J Vet Res*. 72, 1586-1591.

Carmalt, J. L., Kneissl, S., Rawlinson, J. E. et al. (2016) Computed tomographic appearance of the temporomandibular joint in 1018 asymptomatic horses: A multi-institution study. *Vet Rad Ultra*. 57, 237-245.

Carmalt, J.L., and Wilson, D.G. (2005) Arthroscopic treatment of temporomandibular joint sepsis in a horse. *Vet Surg*. 34, 55-58.

Caron J.P., and Genovese R.L. (2003) Principles and practices of joint disease treatment. In: Ross MW, Dyson SJ, eds. *Diagnosis and management of lameness in the horse*. Philadelphia: Elsevier pp. 746-764.

Chen, W., Masonori, H., Tadao, T. et al. (1989) Age-related changes in the temporomandibular joint of the senescence accelerated mouse. *Am J Path*. 135, 379-387.

Custers, R. J. H., Creemers, L. B., Verbout, A. J. et al. (2007). Reliability, reproducibility and variability of the traditional histologic/histochemical grading system vs the new OARSI osteoarthritis cartilage histopathology assessment system. *Osteoarth Cart*. 15, 1241-1248.

Devine, D.V., Moll, D.H., Bahr, R.J. et al. (2005) Fracture, luxation, and chronic septic arthritis of the temporomandibular joint in a juvenile horse. *J Vet Dent.* 22, 96-99.

Frisbie D.D. (2012) Synovial joint biology and pathobiology. In: Auer J.A., Stick J.A, 4th Eds. *Equine Surgery.* Philadelphia: Elsevier. pp. 1096-1113.

Leonardi, R., Rusu, M.C., Loreto, C. (2010) Temporomandibular joint disc: a proposed histopathological degeneration grading score system. *Histo Histopath.* 25, 1117-1122.

Loeser, R.F. (2009) Ageing and Osteoarthritis: The role of chondrocyte senescence and aging changes in the cartilage matrix. *Osteoarth Cart.* 17, 971-979.

Luder, H.A. (1998) Age Changes in the articular tissue of human mandibular condyles from adolescence to old age: A semi quantitative light microscopic study. *Anat Rec.* 251, 439-447.

Mankin, H. J. (1974) The reaction of articular cartilage to injury and osteoarthritis. *New Eng J Med.* 291, 1285-1292.

McIlwraith, C.W., Frisbie, D.D., Kawcak, C.E. (2012) The horse as a model of naturally occurring osteoarthritis. *Bone Joint Res.* 1, 297-309.

McIlwraith, C.W., Frisbie, D.D., Kawcak, C.E. et al. (2010) The OARSI histopathology initiative recommendations for histological assessments of osteoarthritis in the horse. *Osteoarth Cart.* 18, S93-S105.

Nagy, A.D., and Simhofer, H. (2006) Mandibular condylectomy and meniscectomy for the treatment of septic temporomandibular joint arthritis in a horse. *Vet Surg.* 35, 663-668.

Nakano, T., and Scott, P. G. (1996) Changes in the chemical composition of the bovine temporomandibular joint disc with age. *Arc Oral Bio.* 41, 845-853.

Pauli, C., Grogan, S.P., Otsuki, S., et al. (2011) Macroscopic and histopathologic analysis of human knee menisci in aging and osteoarthritis. *Osteoarth Cart.* 19, 1132-1141.

Pearson, R.G., Kurien, T., Shu, K.S. et al. (2011) Histopathology grading systems for characterization of human knee osteoarthritis reproducibility, variability, reliability, correlation, and validity. *Osteoarth Cart.* 19, 324-331.

Pritzker, K.P., Gay, S., Jimenez, S.A., et al. (2006) Osteoarthritis cartilage histopathology: grading and staging. *Osteoarth Cart.* 14, 13-29.

Rodriguez, M.J., Agut, A., Gil, F. et al. (2006) Anatomy of the Equine temporomandibular joint: Study by gross dissection, vascular injection and section. *Equine Vet J.* 2, 143-147.

Smyth, T.T, Allen, A.L., Carmalt, J.L. (2017) Clinically significant, non-traumatic, degenerative joint disease of the temporomandibular joints in a horse. *Equine Vet Educ.* 29, 72-77.

Smyth, T.T., Carmalt, J.L., Treen, T.T. (2016) The effect of acute unilateral inflammation of the equine temporomandibular joint on the kinematics of mastication. *Equine Vet J.* 48, 523-527.

Sokoloff, L. (1983) Aging and degenerative diseases effecting cartilage. In: *Cartilage*. New York: BK Hall, Academic press. pp.109-141.

Stadtbäumer, G., and Boening, K.J. (2002) Diagnostische und minimal-invasive Verfahren am Kiefergelenk des Pferdes. *Tieraerztl Prax.* 30, 99-100.

Van der Sluijs, J. A., Geesink, R. G. T., Van der Linden, A. J. et al. (1992). The reliability of the Mankin score for osteoarthritis. *J Orthoped Res.* 10, 58-61.

Van Turnhout, M. C., Haazelager, M. B., Gijssen, M. A, et al. (2008) Quantitative description of collagen structure in the articular cartilage of the young and adult equine distal metacarpus. *Animal Biology.* 58, 353-370.

Wadhwa, S., Embree, M.C., Young, M.F. (2005) Accelerated osteoarthritis in the temporomandibular joint of biglycan/fibromodulin double-deficient mice. *Osteoarth Cart.* 13, 817-827.

Warmerdam, E.P.L., Klein, W.R., Van Herpen, B.P.J.M. (1997) Infectious temporomandibular joint disease in the horse: computed tomographic diagnosis and treatment of two cases. *Vet Rec.* 14, 172-174.

CHAPTER 6: GENERAL DISCUSSION

Degenerative joint disease, or OA, of the equine TMJ is an infrequently recognized and studied condition. The cause and clinical significance of TMJD have yet to be fully understood. Due to the non-descript signs, it is possible that cases of TMJD are either missed or incorrectly diagnosed (May et al. 2001; Rodriguez et al. 2010). The diagnostic methods of choice for this nebulous disease include physical examination, palpation, arthrocentesis, and medical imaging, for which only the latter two have been consistently reported as generating useful diagnostic information. Clinical presentations include problems during mastication (dysphagia, or quidding, i.e., dropping food from the mouth), behavioral issues such as fighting the bit or changes in head carriage, and occasionally head-shaking (Warmerdam et al. 1997; Weller et al. 1999a; May et al. 2001; Moll and May 2002; Carmalt and Wilson 2005; Devine et al. 2005; Barnett et al. 2014; Jørgensen et al. 2014). Long standing cases may develop atrophy of the masseter muscles, bony enlargement of the TMJ, weight loss and dental malocclusions (Baker 2002; Nagy and Simhofer 2006). The small size of the joint space and the complexity of overlapping anatomic structures in the equine head can complicate the interpretation of radiographs of the TMJ (Wyn-Jones 1985). As such, newer (tangential and rostral 45°ventral-caudodorsal oblique), projections of this region have recently been described (Ramzan et al. 2008; Ebling et al. 2009; Townsend et al. 2009). Even with these new techniques, the incident angle has to be precise to enable visualization of small, but possibly important irregularities in the joint due to its undulant surface (Rodriguez et al. 2010). Ultrasound has been used with some success, but the information gained is limited to the lateral and superficial aspects of the joint (Rodriguez et al. 2007). The combination of non-specific clinical signs and the insidious onset of DJD may confound equine veterinarians and frustrate owners, preventing advanced diagnostic imaging (CT and MRI) from being performed. In both horses and humans, a common cause of TMJD is trauma, which can lead to fracture of the mandibular condyle and disruption of the articular surface (May et al. 2001; Carmalt and Wilson 2005; Rodriguez et al. 2010; He et al. 2013). A putative link between equine TMJD and dental malocclusion has been made, but remains unsubstantiated (May 1996).

Of the few reported cases of equine TMJD, the bulk have occurred secondary to a traumatic event, often one that has led to fracture of the mandibular condyle or sepsis of the TMJ space (Warmerdam et al. 1997; Weller et al. 1999a,b; May et al. 2001; Moll and May 2002; Carmalt and Wilson 2005; Devine et al. 2005; Nagy and Simhofer 2006; Barnett et al. 2014; Jørgensen et al. 2014). Yet, unlike the pathophysiology of other synovial joints, there has been only one recorded case of naturally occurring degeneration of the equine TMJ (Smyth et al. 2017). A possible reason for this is that horses diagnosed with a traumatic sepsis of the TMJ, often present for an external wound, extensive soft tissue swelling, or anorexia. It is feasible that owners, and veterinarians, only become sensitized to the subtler clinical signs associated with TMJD, after they have noticed the proximity of the external wound to the underlying joint. Without the obvious external signs, the subtle issues such as quidding or head shyness, might never have been recognized.

The information provided earlier in this thesis suggests that severe trauma is not the only method of achieving a clinically significant inflammatory response within the equine TMJ. If true, it is possible that other causes of low grade inflammation could lead to DJD in the TMJ, as it does in other synovial joints. Evidence to suggest the occurrence of age-related TMJD was presented in the above case report. This geriatric subject lived in a controlled environment and had no history of injury, or trauma, to explain the development of bilateral TMJD. Oral examination showed little evidence to suggest dental disease and the horse had occlusal equilibration performed on a regular basis. Through diagnostic imaging (CT and MRI) as well as histology, this aged horse was diagnosed with severe DJD of the articular cartilage of both TMJs and their respective discal tissues. The presence of bilateral OA is curious, as traumatic forms of TMJD are often unilateral in nature. When combined, a lack dental abnormalities and a lack of external trauma or traumatic history, it is possible that OA in this aged horse accumulated over time as the normal wear-and-tear associated with ageing.

To determine whether the non-traumatic nature of degeneration seen in this report is an anomaly or part of a previously unrecognized trend, the last portion of this work examined the accumulation of histologic changes observed within the TMJs of normal horses of varying ages. The development of age-related change within synovial joints is considered a normal physiologic progression and has been noted in several joints of various species (Sokoloff 1983; Chen et al.

1989; Nakano and Scott 1996; Luder 1998; Wadhwa et al. 2005; Pritzker et al. 2006; Van Turnhout et al. 2008; Leonardi et al. 2010; Pauli et al. 2011; Pearson et al. 2011). The initiation, of these changes is considered innocuous. As animals age however, the accumulation of these changes are suspected to predispose to, or be directly responsible for, the development of OA. Unfortunately, this lack of semantic clarity often leads to dispute, blurring the limits of age-related change and the onset of OA (Sokoloff 1983).

Until now, the evidence for age-related change in the equine TMJ has been superficial, and only stumbled upon as an incidental finding (Chen et al. 1989; Rodriguez et al. 2006; Carmalt et al. 2016). In this study, the creation of a novel grading system was based from a modification of the Makin scoring system of hyaline cartilage, allowing a histologic assessment of the TMJ. The accumulation of changes seen here, suggest that age-related change does occur within the equine TMJD and is similar to the age-related changes seen within other synovial joints (Van Turnhout et al. 2008). Not unlike the age-related changes of other joints, the observation of age-related changes seen within this study, fails to answer whether the accumulation of these changes will ultimately lead to OA.

Within the field of equine lameness, the practice of using visual cues, such as gait abnormalities, for the presence of joint-related pain has long been the clinical standard. In recent years, equine lameness has progressed to the use of computer generated gait analysis, such as the lameness locator, to help define subtle or difficult lameness (McCracken et al. 2012). In a manner similar to lameness examination of the appendicular skeleton, it was theorized that equine TMJD would result in similar visual irregularities, such as changes in the cycle of mastication. In this work, the injection of LPS into the left TMJ of horses, led to a transient inflammatory response that effected the 3-D kinematics of the mandible during mastication. Affected horses developed the same subtle clinical signs that are typical of naturally occurring TMJD disease; heat, joint effusion, head shyness, and quidding behavior. Post-injection all horses continued eating, but only on the side of the mouth opposite to the inflamed joint, which may suggest an aversion behavior in response to pain. In addition, kinematic analysis of the masticatory cycle, suggested that horses made smaller chewing cycles post-injection and developed rostrocaudal movement in the power phase of mastication. By definition, the power phase of mastication occurs when opposite occlusal

surfaces interdigitate, moving in a lateromedial direction to allow grinding of ingested feed. Thus, the presence of rostrocaudal movement in this phase indicates a failure, on the part of the horse, to apply adequate pressure to allow the teeth to squeeze the food bolus and allow the occlusal surfaces to interdigitate; leading to a continued loss of feed efficiency and the possible formation of quidding behavior. In this study, a fraction of horses continued to show quidding behavior despite switching to the more comfortable side of mastication. This suggests that not only is a certain degree of pain unavoidable, but also that the act of quidding may be related to the level of pain experienced by the horse. If this is correct and TMJD does lead to unavoidable pain, it is interesting that none of the horses in the study became anorexic in the post-injection period. As a prey species, this may have been conferred as an evolutionary advantage. However, it is difficult to tell how the subjects' response may have changed in the face of chronic pain and the development of hyperalgesia. Overall, the subtle nature of the clinical signs associated with equine TMJD may cause the disease to be overlooked and thus, an accurate diagnosis of the disease to be under-represented in the general population.

6.1 References:

Baker, G.J. (2002) Equine temporomandibular joints (TMJ): Morphology, function, and clinical disease. *Proc Am Assoc Equine Pract.* 48, 442-447.

Barnett, T.P., Powell, S.E., Head, M.J. et al. (2014) Partial mandibular condylectomy and temporal bone resection for chronic, destructive, septic arthritis of the temporomandibular joint in a horse. *Equine Vet Educ.* 26, 59-63.

Carmalt, J.L., and Wilson, D.G. (2005) Arthroscopic treatment of temporomandibular joint sepsis in a horse. *Vet Surg.* 34, 55-58.

Chen, W., Masonori, H., Tadao, T. et al. (1989) Age-related changes in the temporomandibular joint of the senescence accelerated mouse. *Am J Path.* 135, 379-387.

Devine, D.V., Moll, D.H., Bahr, R.J. et al. (2005) Fracture, luxation, and chronic septic arthritis of the temporomandibular joint in a juvenile horse. *J Vet Dent.* 22, 96-99.

Ebling, A.J., McKnight, A.L., Seiler, G. et al. (2009) A complimentary radiographic projection of the equine temporomandibular joint. *Vet Rad Ultra.* 50, 385-391.

He, D., Yang, C., Chen, M. et al. (2013) Effects of soft tissue injury to the temporomandibular joint: report of 8 cases. *Br J Oral Maxillofac Surg.* 51, 58-62.

Jørgensen, E., Christopherson, M.T., Kristoffersen, M. (2014) Does temporomandibular joint pathology affect performance in an equine athlete? *Equine vet Educ.* 27, 126-130.

Leonardi, R., Rusu, M.C., Loreto, C. (2010) Temporomandibular joint disc: a proposed histopathological degeneration grading score system. *Histology and Histopathology.* 25, 1117-1122.

Luder, H.A. (1998) Age changes in the articular tissue of human mandibular condyles from adolescence to old age: A semi quantitative light microscopic study. *Anat Rec.* 251, 439-447.

McCracken, M.J., Kramer, J., Keegan, K.G. et al. (2012) Comparison of an inertial sensor system of lameness quantification with subjective lameness evaluation. *Equine Vet J.* 44, 652-656.

May, K.A., Moll, H.D., Howard, R.D. (2001) Arthroscopic anatomy of the equine temporomandibular joint. *Vet Surg.* 30, 564-571.

May, K.J. (1996) Incisor problems that may result in inflammation of the temporomandibular joint. *Pferdeheilkunde.* 12, 716.

Moll, D.H. and May, K.A (2002) A review of conditions of the equine temporomandibular joint. *Proc Am Assoc Eq Pract.* 48, 240-243.

Nagy, A.D. and Simhofer, H. (2006) Mandibular condylectomy and meniscectomy for the treatment of septic temporomandibular joint arthritis in a horse. *Vet Surg.* 35, 663-668.

Nakano, T., and Scott, P. G. (1996) Changes in the chemical composition of the bovine temporomandibular joint disc with age. *Arc Oral Bio.* 41, 845-853.

Pauli, C., Grogan, S.P., Otsuki, S., et al. (2011) Macroscopic and histopathologic analysis of human knee menisci in aging and osteoarthritis. *Osteoarthr Cartil.* 19, 1132-1141.

Pearson, R.G., Kurien, T., Shu, K.S. et al. (2011) Histopathology grading systems for characterization of human knee osteoarthritis reproducibility, variability, reliability, correlation, and validity. *Osteoarthr Cartil.* 19, 324-331.

Pritzker, K.P., Gay, S., Jimenez, S.A., et al. (2006) Osteoarthritis cartilage histopathology: grading and staging. *Osteoarthr Cartil.* 14, 13-29.

Ramzan, P.H.L. (2006) The temporomandibular joint: component of clinical complexity. *Equine Vet J.* 38, 102-104.

Rodriguez, M.J., Agut, A., Soler, M. (2010) Magnetic resonance imaging of the equine temporomandibular joint anatomy. *Equine Vet J.* 42, 200-207.

Rodriguez, M.J., Soler, M., Latorre, R. (2007) Ultrasonographic anatomy of the temporomandibular joint in healthy pure-bred Spanish horses. *Vet Rad Ultra.* 48, 149-154.

Sokoloff, L. (1983) Aging and degenerative diseases effecting cartilage. In: *Cartilage*. New York: BK Hall, Academic press.: pp.109-141.

Townsend, N.B., Cotton, J.C., Barakzai, S.Z. (2009) A tangential radiographic projection for investigation of the equine temporomandibular joint. *Vet Surg.* 38, 601-606.

Van Turnhout, M. C., Haazelager, M. B., Gijzen, M. A. et al. (2008) Quantitative description of collagen structure in the articular cartilage of the young and adult equine distal metacarpus. *Animal Biology*. 58, 353-370.

Wadhwa, S., Embree, M.C., Young, M.F. (2005) Accelerated osteoarthritis in the temporomandibular joint of biglycan/fibromodulin double-deficient mice. *Osteoarthr Cartil*. 13, 817-827.

Warmerdam, E.P.L., Klein, W.R., Van Herpen, B.P.J.M. (1997) Infectious temporomandibular joint disease in the horse: computed tomographic diagnosis and treatment of two cases. *Vet Rec*. 141, 172-174.

Weller, R., Cauvin, E.R., Bowen, I.M. (1999a) Comparison of radiography, scintigraphy and ultrasonography in the diagnosis of a case of temporomandibular joint arthropathy in a horse. *Vet Rec*. 144, 377-379.

Weller, R., Taylor, S., Maierl, J. (1999b) Ultrasonographic anatomy of the temporomandibular joint. *Equine Vet J*. 31, 529-532.

Wyn-Jones, G. (1985) Interpreting radiographs 6: Radiology of the equine head (Part 2). *Equine Vet J*. 17, 417-425.

CHAPTER 7: CONCLUSIONS AND FUTURE STUDIES

7.1 General conclusions:

The case study presented in this body of work, highlights evidence of bilateral TMJD in a geriatric horse. To date, cases of equine TMJD have been isolated to trauma-related causes, with sepsis as a common secondary complication to an open joint. The absence of either trauma or sepsis, in this case, suggests that age-related change may play a role in the pathophysiology of equine TMJD.

Based on the results of the presented studies we can conclude that LPS-induced inflammation of the TMJ causes sufficient discomfort to significantly alter the kinematics of the mandible during mastication, initiating the loss of feed efficiency in affected horses. Throughout the inflammatory phase horses continued eating but developed aversion behavior, switching to the side of mastication that was opposite to the side of inflammation. The development of quidding behavior and the refusal to ingest long-stemmed forage, in preference to small particulate feed, is consistent with clinical cases of TMJD.

Analysis of the TMJs over a variety of ages of clinically normal horses, showed an accumulation of histologic change to both the upper and lower bony condyles, as well as the fibrocartilaginous disc, as horses aged. The degree of histologic change was not different between the left and right joints within each AG. If a traumatic incident was responsible for these changes, significant differences between the left and right joints, would be expected. The age-related histologic changes observed within the equine TMJ were similar to those seen within appendicular synovial joints.

The separation between age-related change and the development of OA, is one of clinical distinction. Unfortunately, the inability to converse with animals creates a reliance on subjective clinical signs of pain for diagnosis. The problem inherent to the TMJ is that clinical signs of disease have not been well characterized, and most pain-related signs of OA are restricted to the

appendicular skeleton. Characterization of the chewing cycle of horses experiencing unilateral inflammation of the TMJ, is currently the only tested indicator that TMJD causes pain. It also lends credence of the keen observations required to diagnose the subtle clinical signs of TMJD.

7.2 General limitations:

To the author's knowledge, the case of equine TMJD covered in Chapter three, is the first case report describing the histologic changes within the equine TMJD. While the absence of external wounds, fractures, or history of trauma, suggests the potential for age-related DJD, the absolute possibility of a traumatic cause cannot be ruled out.

When examining the 3-D kinematics of the masticatory cycle the small number of subjects, greatly reduced the power capable of interpreting the results; using a larger number of subjects may have revealed a greater degree of difference during kinematic analysis. Additionally, the consistent injection of LPS into the left TMJ may predispose this work to selection bias. However, given the low number of subjects available, randomization of the side of injection would have decreased the power required for interpretation of the primary objective. By observing the mastication of each subject prior to injection, the subject was able to act as its own control. Sham injections using saline were not performed, as penetration of the synovium by the needle, or the injection of saline confound the study, by causing inflammation. Of the subjects that were chosen, each was found to be free of oral disease and had no prior history of TMJD. However, the lack of clinical signs does not eliminate the possibility of pathologic change within the joint. In this case, diagnostic imaging was not performed, because no study has been published to determine which pathologic changes are consistent with causing pain in the equine TMJ. It is also worth noting that the inflammatory response produced through intraarticular injection of LPS, may be different from that which develops in naturally occurring disease; the increased sensitization and hyperalgesia that occurs during chronic inflammation, may initiate a different clinical response (Arden-Nielsen et al. 2010). Lastly, the administration of intraarticular analgesia was not performed during the inflammatory phase because the limits of local analgesia diffusion have never been ascertained for this joint.

To accurately assess the histologic changes seen within the TMJs of horses of different ages, the development of a novel grading system was required. The unique fibrocartilaginous component of this joint precluded the use of existing grading systems that have been developed for other joints, consisting of hyaline cartilage. Histologic studies of the TMJs have been performed in other species, but never in the horse. Without prior knowledge of the changes that could be expected to occur in the equine TMJ, the development of the grading system was based on the changes observed within the study sample. As such, it is impossible to determine whether the changes seen in this group of horses is representative of the general population. The modest sample size of this study served to establish a correlation between the accumulation of histologic change and age, but was greatly restricted its analytical power to analyze those changes in specific regions of each joint. Therefore, region-analysis within joints was restricted to descriptive trends rather than statistical significance. Repetition of the grading system using multiple pathologists and a larger sample size may yield more reliable results.

7.3 Future research:

The lack of literature in the area of equine TMJD leaves the opportunity for multiple areas of exploration. The analysis of mastication during inflammation of the equine TMJ suggests that there is a pain component to this condition. This study focused on acute unilateral inflammation of the equine TMJ. However, because naturally occurring disease is insidious in nature, the analysis of clinical signs following chronic inflammation may yield new information. Bilateral non-septic inflammation may also lead to different, more severe clinical signs, to those seen in this study. Not all subjects in this study responded to TMJ inflammation with identical clinical signs. It is possible that certain clinical signs, such as quidding, are related to the etiology or severity of TMJ inflammation. Future studies may be able to correlate the clinical signs with degree or chronicity of inflammation.

While the kinematic role of the equine TMJ during mastication has been examined (Bonin et al. 2006; Bonin et al. 2007; Smyth et al. 2016), the role of the TMJ during equitation remains a mystery. There has been limited evidence to suggest that the mechanical pressure produced by

different types of riding bits, may have an adverse effect on the equine TMJ (Clayton 1985; Geyer and Weishaupt 2006). Despite the lack of evidence, this has helped to foster a current trend toward the use of bitless bridles (Cook 1999; Quick and Warren-Smith 2009). The finite movements detected with kinematic motion tracking systems may provide insight on this potentially important subject.

With the increased recognition and diagnosis of age-related equine TMJD, it is possible that more frequent reports on the histological changes that develop within the joint will be brought to light. Further work to validate the scoring system seen here, as well as the investigation of age-related changes in clinical cases of equine TMJD, are already underway. The difficulty with this line of research, is that a technique for biopsy of this joint has not been developed. Obtaining samples of the TMJ requires that animal to be euthanized for histologic processing. Due to the nature of TMJD it is rarely considered life-threatening and as such, access to the TMJ is unlikely to occur until the animal has been euthanized for other reasons.

7.4. References:

Ardent-Nielson, L., Nie, H., Laursen, M.B. et al. (2010) Sensitization in patients with painful knee osteoarthritis. *Pain*. 149, 573-581.

Bonin, S.J., Clayton, M.S., Lanovaz, J.L., et al. (2006) Kinematics of the equine temporomandibular joint. *Am J Vet Res*. 67, 423-428.

Bonin, S.J., Clayton, M.S., Lanovaz, J.L. (2007) Comparison of mandibular motion in horses chewing hay and pellets. *Equine Vet J*. 39, 258-262.

Clayton H.M. (1985) A fluoroscopic study of the position and action of different bits in the horse's mouth. *Equine Vet J*. 5, 68-77.

Cook, R.W. (1999) Pathophysiology of bit control in the horse. *J. Equine. Vet. Sci.* 19, 196-204.

Geyer, H. and Weishaupt, M.A. (2006) The influence of the rein and bit on the movements of the horse; anatomical-functional considerations. *Pferdeheilkunde.* 22, 597-600

Quick, J.S. and Warren-Smith, A.K. (2009) Preliminary investigations of horses' (*Equus caballus*) responses to different bridles during foundation training. *J Vet Behav.* 4, 169-176.

Smyth, T.T., Carmalt, J.L., Treen, T.T., Lanovaz, J.L. (2016) The effect of acute unilateral inflammation of the equine temporomandibular joint on the kinematics of mastication. *Equine Vet J.* 48, 523-527.