

Contents lists available at [ScienceDirect](http://ScienceDirect.com)

Molecular Genetics and Metabolism Reports

journal homepage: www.elsevier.com/locate/ymgmr

Multigene panel next generation sequencing in a patient with cherry red macular spot: Identification of two novel mutations in *NEU1* gene causing sialidosis type I associated with mild to unspecific biochemical and enzymatic findings



Ulrike Mütze^{a,b}, Friederike Bürger^c, Jessica Hoffmann^d, Helmut Tegetmeyer^e, Jens Heichel^f, Petra Nickel^b, Johannes R Lemke^g, Steffen Syrbe^{a,b,1}, Skadi Beblo^{b,*,1}

^a Department of General Pediatrics, Division of Neuropediatrics and Inherited Metabolic Diseases, University Children's Hospital Heidelberg, Im Neuenheimer Feld 430, 69120 Heidelberg, Germany

^b Hospital for Children and Adolescents, Centre for Pediatric Research Leipzig (CPL), Department of Women and Child Health, University Hospitals, University of Leipzig, Liebigstraße 20 a, 04103 Leipzig, Germany

^c Center for Pediatric Metabolic Medicine, Department of General Pediatrics, University Children's Hospital Heidelberg, Im Neuenheimer Feld 669, 69120 Heidelberg, Germany

^d Center for Human Genetics, Paul-Ehrlich-Straße 23, Tübingen, Germany

^e University Eye Hospital, Department of Head and Dental Health, University Hospitals, University of Leipzig, Liebigstr. 10-14, 04103 Leipzig, Germany

^f Department of Ophthalmology, University Hospital of Martin Luther University Halle-Wittenberg, Ernst-Grube-Straße 40, 06120 Halle (Saale), Germany

^g Institute of Human Genetics, University of Leipzig Hospitals and Clinics, Leipzig, Germany

ARTICLE INFO

Article history:

Received 22 August 2016

Received in revised form 15 November 2016

Accepted 15 November 2016

Available online xxxx

Keywords:

Multigene panel next generation sequencing

Lysosomal storage disease

NEU1 gene

Sialidosis

c.699C>A (p.S233R)

c.803A>G (p.Y268C)

ABSTRACT

Background: Lysosomal storage diseases (LSD) often manifest with cherry red macular spots. Diagnosis is based on clinical features and specific biochemical and enzymatic patterns. In uncertain cases, genetic testing with next generation sequencing can establish a diagnosis, especially in milder or atypical phenotypes. We report on the diagnostic work-up in a boy with sialidosis type I, presenting initially with marked cherry red macular spots but non-specific urinary oligosaccharide patterns and unusually mild excretion of bound sialic acid.

Methods: Biochemical, enzymatic and genetic tests were performed in the patient. The clinical and electrophysiological data was reviewed and a genotype-phenotype analysis was performed. In addition a systematic literature review was carried out.

Case report and results: Cherry red macular spots were first noted at 6 years of age after routine screening myopia. Physical examination, psychometric testing, laboratory investigations as well as cerebral MRI were unremarkable at 9 years of age. So far no clinical myoclonic seizures occurred, but EEG displays generalized epileptic discharges and visual evoked potentials are prolonged bilaterally. Urine thin layer chromatography showed an oligosaccharide pattern compatible with different LSD including sialidosis, galactosialidosis, GM1 gangliosidosis or mucopolysaccharidosis type IV B. Urinary bound sialic acid excretion was mildly elevated in spontaneous and 24 h urine samples. In cultured fibroblasts, α -sialidase activity was markedly decreased to <1%; however, bound and free sialic acid were within normal range. Diagnosis was eventually established by multigene panel next generation sequencing of genes associated to LSD, identifying two novel, compound heterozygous variants in *NEU1* gene (c.699C>A, p.S233R in exon 4 and c.803A>G; p.Y268C in Exon 5 in *NEU1* transcript NM_000434.3), leading to amino acid changes predicted to impair protein function.

Discussion: Sialidosis should be suspected in patients with cherry red macular spots, even with non-significant urinary sialic acid excretion. Multigene panel next generation sequencing can establish a definite diagnosis, allowing for counseling of the patient and family.

© 2016 The Authors. Published by Elsevier Inc. This is an open access article under the CC BY-NC-ND license (<http://creativecommons.org/licenses/by-nc-nd/4.0/>).

1. Introduction

Sialidosis (OMIM #256550) is a rare autosomal recessive lysosomal storage disorder. It is caused by mutations in the *NEU1* gene resulting in α -sialidase (α -neuraminidase) deficiency, leading to insufficient degradation of glycoproteins and subsequent accumulation and excretion of

Abbreviations: DNA, deoxyribonucleic acid; EEG, electroencephalography.

* Corresponding author.

E-mail address: Skadi.Beblo@medizin.uni-leipzig.de (S. Beblo).

¹ Contributed equally.

bound sialic-acid [12]. Two types based on the clinical presentation are described.

Type I: the more common late onset form (second or third decade) known as ‘cherry-red spot myoclonus syndrome’ with myoclonus, myoclonic epilepsy, visual impairment and ataxia;

Type II: early onset form (infancy/childhood) with progressive mental retardation, coarse facial features, hepatomegaly, skeletal dysplasia and severe ataxia [7]. Cherry red macular spots are the hallmark of both types. Milder or atypical phenotypes, even without cherry red spot, have been identified through next generation sequencing in 6 patients harboring *NEU1* variants with inconclusive or nonspecific biochemical/enzymatic profiles. [2]

We report on two novel variants in *NEU1* in a boy with marked cherry red spots but non-specific urinary oligosaccharide patterns and unusually mild urinary excretion of bound sialic acid. Diagnosis was eventually established through multigene panel next generation sequencing of genes associated to lysosomal storage diseases.

2. Materials and methods

2.1. Thin-layer-chromatography of oligosaccharides in urine

Thin-layer-chromatography was performed as previously described [1,5]. Brief, spontaneous urines were normalized to creatinine and applied to silicagel 60 plate (10 cm × 20 cm; Merck KGaA, Darmstadt, Germany). Thin-layer-chromatography was performed using a mixture of n-butanol/acetic acid/H₂O (2:1:1 (v/v)). Staining was performed with orcinol (0.1 g/100 ml) in sulfuric acid/acetone (1:50 (v/v)) at 100 °C.

2.2. Sialic acid in urine and cultivated fibroblasts

Diluted (1:20) spontaneous urines or cultivated skin fibroblasts (0.5–1.0 mg/ml) were used for the periodate/thiobarbituric assay according to the method published by Skoza et al. and Cantz et al. [3,10]. Photometric measurement was performed at an extinction of $\lambda = 549$ nm and $\lambda = 532$ nm with an infinity M200 pro microplate reader (Tecan group Ltd., Männedorf, Switzerland).

2.3. Neuraminidase assay

Neuraminidase assay was performed as previously described [4]. After skin biopsy, patient's skin fibroblasts were cultivated. Freshly prepared fibroblast pellets were homogenized under ice water cooling by using a glass potter. The homogenate was used in the neuraminidase assay immediately. The assay mixture contained 8 μ g BSA, 20–60 μ g homogenate of fibroblasts, 800 pmol 4-methylumbelliferyl- α -D-N-acetylneuraminic acid, and 2 μ mol sodium acetate buffer (pH 4.3) in a total volume of 30 μ l. After incubation at 37 °C for 30 min the reaction was stopped by adding 500 μ l 0.17 M 0.17 glycine carbonate buffer (pH 10.0). Fluorescence was measured at an extinction of $\lambda = 360$ nm and an emission of $\lambda = 465$ nm with an infinity M200 pro microplate reader (Tecan group Ltd., Männedorf, Switzerland). Protein concentration was determined according to the method of Lowry [8].

2.4. Genetic testing

Genetic testing was performed using a targeted panel sequencing approach to screen for 29 genes known to be involved in lysosomal storage disorders. Analyses were performed similar to the previously described method [6]. In brief, coding regions and exon-intron boundaries were enriched using Agilent SureSelect technology (Agilent Technologies, Santa Clara, California, USA) followed by next generation sequencing on an Illumina HiSeq2500 platform (Illumina, San Diego, California, USA). Reads were aligned using Burrows Wheeler Aligner (BWA-mem 0.7.2) using hg19 as reference genome. Unambiguous reads were removed using Picard 1.14. Annotation was performed

using SAMtools (v0.1.18) and VarScan (v2.3). Variants were selected with a minor allele frequency below 5% (according to 1000 Genomes, dbSNP, EVS and the CeGaT in-house database). >98% of targets had at least 30× coverage. Validation of suspicious variants as well as segregation analysis in both parents were performed by conventional Sanger sequencing.

2.5. Systematic literature review

A systematic literature review on sialidosis type I with abnormal metabolic findings was carried out, using PubMed. Additionally, all reported *NEU1* mutations within the Human Gene Mutation Database (HGMD, <https://portal.biobase-international.com/cgi-bin/portal/login.cgi>) that were published until October 2016 were reviewed to identify cases with atypical metabolic findings.

3. Case report and results

The patient was referred for further metabolic analysis at the age of 8 years, following the identification of cherry red macular spots by his ophthalmologist two years earlier. Fundus changes were noted, when he was screened for developing myopia.

He is the first child of non-consanguineous German parents. The family history is unremarkable for genetic disorders, visual impairment or epilepsy. He has one healthy younger maternal half-sister.

Birth and perinatal period were complicated by emergency cesarean section for intrauterine hypoxia due to placenta infarction and postnatal aspiration of amniotic fluid. However, mental and motor development was normal and he shows an age appropriate school performance. Recently, 8 years old, he received screening for attention deficit hyperactivity disorder after the parents noted overactive, twitchy and agitated behavior. As a consequence, occupational therapy and physiotherapy were initiated.

Examination revealed a good general condition. Besides atopic dermatitis, glasses for myopia, and a right convex thoracic scoliosis, internal, orthopedic, and neurological examination were normal; no facial dysmorphism, skeletal abnormalities or involuntary movements were found.

The ophthalmological examination confirmed myopia, and fundoscopy revealed the cherry red macula spots (Fig. 1) without signs of atrophy of the optic nerve or cataract.

While the patient is still free of clinical seizures, repeated EEG displayed generalized epileptic discharges. Visual evoked potentials on both sides showed a mild prolongation of P100 around 130 ms. Brain magnetic resonance imaging was unremarkable.

On psychometric testing (performed at the age of 9 years using the German versions of the Wechsler Intelligence Scale for Children (WISC-IV)), the boy performed normal average (Total Index 108; Verbal Comprehension Index 115, Perceptual Reasoning Index 108, Working Memory Index 102, Processing Speed Index 97) without signs of reduced attention, increased diversion or lack of concentration.

Extensive laboratory investigations revealed unremarkable results including complete blood count and microscopy (no vacuolated lymphocytes), glucose, lactate, ammonia, pH, plasma amino acids, sterol analysis, dried blood acylcarnitine profile, urinary organic acids, sulfatides in urine, glycosaminoglycans in urine (by electrophoresis). In leucocytes, lysosomal enzymes displayed normal activities, excluding Gaucher's disease and Niemann-Pick disease type A/B are highly unlikely according to normal enzyme analysis. Oxysterols were normal in plasma, excluding Niemann-Pick disease type C.

Thin layer chromatography of spontaneous urine and a 24-h urine sample showed an oligosaccharide pattern compatible with sialidosis, possibly GM1-gangliosidosis, mucopolysaccharidoses IV B (Morquio B), or galactosialidosis (Fig. 2).

Urine sialic acid (I: spontaneous urine and II: 24-h urine collection) analysis showed a mildly elevated excretion of bound sialic acid

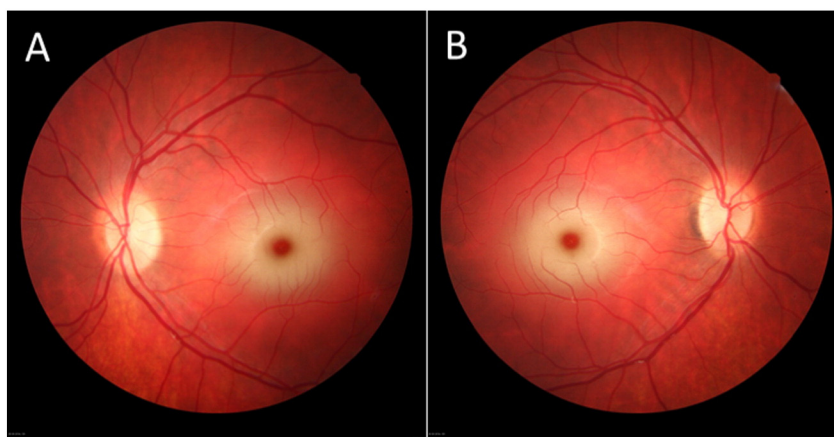


Fig. 1. Patient's funduscopy revealed bilateral (A: left; B: right) macular cherry red spot. (For interpretation of the references to colour in this figure legend, the reader is referred to the web version of this article.)

(I: 50.7 mmol/mol crea; II: 57.5 mmol/mol crea, normal range: 11.7–29.4 mmol/mol crea), while free sialic acid was in the normal range (I: 21.7 mmol/mol crea; II: 22.6 mmol/mol crea, normal range: 12.0–31.0 mmol/mol crea).

Genomic DNA was extracted from peripheral blood lymphocytes and panel based next generation sequencing was performed as previously described [6]. Two different missense variants (c.699C>A, p.S233R in exon 4 and c.803A>G; p.Y268C in Exon 5 in *NEU1* transcript NM_000434.3) were identified present in compound heterozygous state confirmed by Sanger sequencing.

Further segregational studies showed that the p.S233R variant was of maternal origin. Analysis of the Father was not possible. Both variants are absent from mutation databases, such as Human Gene Mutation Database and ClinVar. In the 60,706 controls of the ExacBrowser, the allele c.699A is found once in a heterozygous state in a control of African origin while c.803G is absent; no homozygous carriers are present in the database (<http://exac.broadinstitute.org/>). The variant p.S233R leads to an amino acid change from the highly conserved serine to arginine at position 233 and p.Y268C leads to a change from the conserved

residue tyrosine to cysteine at position 268. Both variants are predicted to damage protein function with high scores in standard *in silico* prediction tools (PolyPhen2, <http://genetics.bwh.harvard.edu/pph2>, and MutationTaster, <http://www.mutationtaster.org>) using the *NEU1* transcript NM_000434.3.

α -neuraminidase activity, measured in the patient's cultured fibroblasts, showed a markedly decreased enzyme activity to <1% of the norm. However, both bound and free sialic acid in the cultured fibroblasts were within the normal range. Additionally GM1-Gangliosidosis, mucopolysaccharidosis Type IV B and β -Galactosidase were excluded by determination of enzyme activity in cultured fibroblasts.

At last follow-up, the boy was ten years 4 month old with a good school performance (secondary school). No overt epileptic seizures have been reported although EEG displays epileptic discharges at increasing frequency/severity compatible with developing myoclonic epilepsy.

The systematic literature review on patients with sialidosis and abnormal mild metabolic findings was performed in PubMed and with the Human Gene Mutation Database. A total of 9 previously described patients with sialidosis type I or biallelic *NEU1* variants that resulted in a mild biochemical phenotype were identified. Characteristics of these patients are condensed in Table 1. Interestingly, like our index patient, all reported patients displayed not or only mildly elevated bound sialic acid excretion in urine in combination with a pronounced decrease in α -neuraminidase activity. However, our index patient is exceptional among this group, as he is by far the youngest individual and his clinical phenotype is in contrast to the group not atypical but compatible with typical sialidosis type I.

4. Discussion

The finding of cherry red macular spots is indicative for several lysosomal storage disorders. It is caused by the storage of oligosaccharides and sphingolipids in the retinal ganglionic cell layer.

Urinary oligosaccharides, urinary bound sialic acid excretion, and enzyme assay in leukocytes and cultured fibroblasts can establish the diagnosis of sialidosis. However, interpretation of pathological thin layer chromatography of urine oligosaccharides might be difficult and not specific and increased urinary sialic acid excretion is not a constant finding in patients with sialidosis I [11]. This corresponds to the still expanding clinical spectrum of sialidosis to milder or atypical phenotypes [2,9].

In contrast to the patients reported by Canafoglia and colleagues [2], our patient displayed cherry red macular spots and EEG changes compatible with developing myoclonic epilepsy which might be further suspected from the parents reports of hyperactivity and irritability. To our knowledge, we report on the youngest patient, being younger

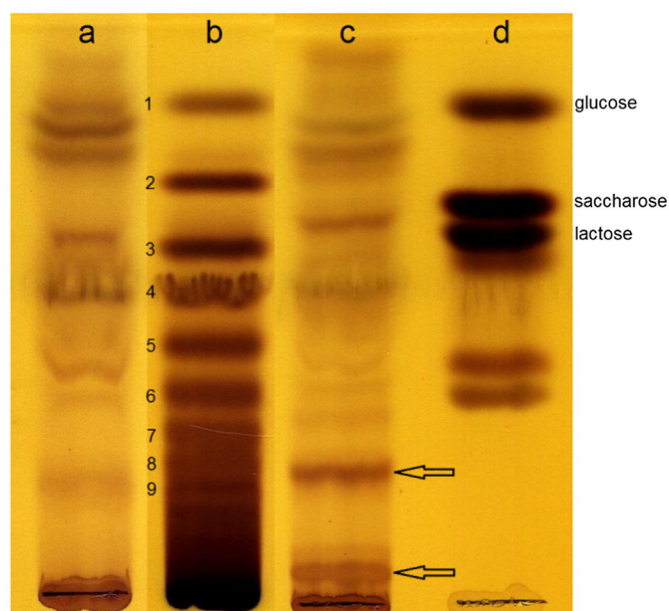


Fig. 2. Oligosaccharide thin layer chromatography with orcinol in spontaneous urine. Lane a: normal control Lane b: dextran hydrolysate Lane c: urine specimen of the patient Lane d: standard mixture of glucose, saccharose and lactose. The bands marked with arrows are the bands leading to the suspected diagnosis of sialidosis or GM1-gangliosidosis, mucopolysaccharidosis IV B (Morquio B), or galactosialidosis.

Table 1
Characteristics of reported patients with Sialidosis type I with normal/mild metabolic findings

Patient, sex	#1	#2, M	#3, F	#4, F	#5, F	#6, F	#7, M	#8, F	#9, F	Index patient
Reference	[11]	[2]						[9]		This report
Mutation, protein	n.a.	c.200C>T,p.S67I (homozygous)			c.679G>A, p.G227R; c.913C>T,p.R305C			c.1195_1200dup, p.His3999_Tyr400dup; c.679G>A, p.Glu277Arg		c.699C>A, p.S233R; c.803A>G, p.Y268C
Age at onset [y]	n.a.	23	25	22	25	25	32	12	13	6
Cherry red spot	n.a.	None	None	None	None	None	None	Yes	Yes	Yes
Seizures/myoclonus	n.a.	None	None	None	None	None	None	Yes	Yes	EEG: epileptic discharges
Ataxia	n.a.	None	Yes	Yes	None	None	None	Yes	Yes	None
Age at diagnosis [y]	48	27	34	30	42	37	36	13	14	8
Bound sialic acid ^a	normal	59	90	114	41	50	59	57	38	50.7
α -Neuraminidase ^b [%]	↓	0	0	0	1	15	3	1,1	1,1	<1

n.a. – not available

^a Normal values: <57–60 mmol/mol creatinine.

^b % of normal values/activity of the normal control.

than 10 years, presenting with a mild biochemical phenotype but developing clinical and electrophysiological signs of sialidosis.

Thus, sialidosis might be suspected in patients with cherry red macular spots even if urinary excretion of bound sialic acid is only mildly elevated and oligosaccharide pattern are suspicious. Our report further supports the aid of multigene panel sequencing to differentiate lysosomal storage diseases and to identify novel mutations. Enzymatic assays in patient's fibroblasts showed a severely impaired enzyme function and provides further evidence for the pathogenicity of both *NEU1* variants leading to compound heterozygosity of disease in our patient.

5. Conclusion

Sialidosis, and by interference other lysosomal storage disorders, should not be eliminated from the list of differential diagnosis in patients with cherry red macular spots based on normal urinary sialic excretion alone. If the level of clinical suspicion is high, even the multigene panel next generation sequencing is justified to support a definite diagnosis, in turn allowing for informed patient advice.

Funding

This research did not receive any specific grant from funding agencies in the public, commercial, or not-for-profit sectors.

Acknowledgement

We acknowledge support from the German Research Foundation (DFG) and Universität Leipzig within the program of Open Access Publishing.

References

- [1] N.G. Abeling, et al., Improved selectivity of urinary oligosaccharide screening using two one-dimensional TLC systems, *J. Inher. Metab. Dis.* 19 (2) (1996) 260–262.
- [2] L. Canafoglia, et al., Expanding sialidosis spectrum by genome-wide screening: *NEU1* mutations in adult-onset myoclonus, *Neurology* 82 (22) (2014) 2003–2006.
- [3] M. Cantz, et al., Mucopolipidosis I: increased sialic acid content and deficiency of an alpha-N-acetylneuraminidase in cultured fibroblasts, *Biochem. Biophys. Res. Commun.* 74 (2) (1977) 732–738.
- [4] K. Harzer, M. C., A.C. Sewell, S.S. Dhahreshwar, W. Roggendorf, R.W. Heckl, O. Schofer, R. Thumler, J. Peiffer, W. Schlote, Normomorphic sialidosis in two female adults with severe neurologic disease and without sialyl oligosacchariduria, *Hum. Genet.* 74 (1986) 209–214.
- [5] R. Humbel, M. Collart, Oligosaccharides in urine of patients with glycoprotein storage diseases. I. Rapid detection by thin-layer chromatography, *Clin. Chim. Acta* 60 (2) (1975) 143–145.
- [6] J.R. Lemke, et al., Targeted next generation sequencing as a diagnostic tool in epileptic disorders, *Epilepsia* 53 (8) (2012) 1387–1398.
- [7] J.A. Lowden, J.S. O'Brien, Sialidosis: a review of human neuraminidase deficiency, *Am. J. Hum. Genet.* 31 (1) (1979) 1–18.
- [8] O.H. Lowry, et al., Protein measurement with the Folin phenol reagent, *J. Biol. Chem.* 193 (1) (1951) 265–275.
- [9] I.F. Schene, et al., Pitfalls in Diagnosing Neuraminidase Deficiency: Psychosomatics and Normal Sialic Acid Excretion, 2015 (JIMD Rep).
- [10] L. Skoza, S. Mohos, Stable thiobarbituric acid chromophore with dimethyl sulphoxide. Application to sialic acid assay in analytical de-O-acetylation, *Biochem. J.* 159 (3) (1976) 457–462.
- [11] M. van der Ham, et al., Quantification of free and total sialic acid excretion by LC-MS/MS, *J. Chromatogr. B Anal. Technol. Biomed. Life Sci.* 848 (2) (2007) 251–257.
- [12] E.J. Bonten, et al., Novel mutations in lysosomal neuraminidase identify functional domains and determine clinical severity in sialidosis, *Hum. Mol. Genet.* 9 (18) (2000) 2715–2725.