

**A NOVEL APPROACH TO THE TREATMENT OF CAUDAL HEEL PAIN USING
EXTRACORPOREAL SHOCK WAVE THERAPY**

A Thesis Submitted to the College of
Graduate and Postdoctoral Studies
In Partial Fulfillment of the Requirements
For the Degree of Master of Science
In the Department of Large Animal Clinical Sciences
University of Saskatchewan
Saskatoon

By

Angela Vivien MacKay

Copyright Angela MacKay, 2019. All rights reserved.

PERMISSION TO USE

In presenting this thesis in partial fulfilment of the requirements for a Postgraduate degree from the University of Saskatchewan, I agree that the Libraries of this University may make it freely available for inspection. I further agree that permission for copying of this thesis in any manner, in whole or in part, for scholarly purposes may be granted by the professor or professors who supervised my thesis work or, in their absence, by the Head of the Department or the Dean of the College in which my thesis work was done. It is understood that any copying or publication or use of this thesis or parts thereof for financial gain shall not be allowed without my written permission. It is also understood that due recognition shall be given to me and to the University of Saskatchewan in any scholarly use which may be made of any material in my thesis.

Requests for permission to copy or to make other use of material in this thesis in whole or part should be addressed to:

Head of the Department of Large Animal Clinical Sciences
University of Saskatchewan
52 Campus Drive, Saskatoon, Saskatchewan S7N 5B4

Or

Dean of College of Graduate and Postdoctoral Studies
University of Saskatchewan
116 Thorvaldson Building, 110 Science Place, Saskatoon, Saskatchewan S7N 5C

ABSTRACT

Anecdotally, extracorporeal shock wave therapy (ESWT) is widely used in equine practice to treat a variety of musculoskeletal conditions. The therapy has been used to treat caudal heel pain of the forelimbs, a common, chronic, degenerative condition that causes lameness. The objectives of this study were to characterize the use of ESWT among equine practitioners in North America, and following this, to determine the analgesic efficacy of focused ESWT on horses with naturally occurring caudal heel pain and the effect of this therapy on the appearance of lesions diagnosed by magnetic resonance imaging (MRI) in the same group of horses. A 21-question online survey was conducted to evaluate equine practitioners' rate of use, indication for use, and opinion of efficacy and tolerability of ESWT for their equine patients. ESWT was used frequently by 65/144 (45.1%) respondents, infrequently by 61/144 (42.4%) respondents, and never by 18/144 (12.5%) respondents. The most common reason for use was to treat ligamentous injuries. Overall, the therapy was rated as a moderately effective option for various musculoskeletal conditions of the horse.

In the second experiment, 49 limbs (11 unilateral, 19 bilateral; 30 horses total) were examined using subjective lameness evaluation, kinematic gait analysis, and MRI. Following randomization, fifteen horses with naturally occurring caudal heel pain were treated with focused ESWT under standing sedation, and fifteen horses received no treatment but standing sedation. Outcome measures included change in subjective lameness grade of each limb, total lameness score of each horse, absolute change in kinematic gait analysis measures, and change in MRI grades for each included limb from day -16 to day 128. The results indicated that focused ESWT decreased subjectively assessed pain in horses with unilateral caudal heel pain for at least 128 days ($p=0.049$). No significant differences were noted in kinematic gait analysis variables between groups. Horses treated with ESWT experienced a worsening of navicular bursitis ($p=0.027$). In summary, based on the response to treatment with ESWT, we are unable to firmly recommend the therapy for horses with caudal heel pain at this time. Some horses may experience analgesia that may not be related to improvement of the lesions within the foot.

Key words: Extracorporeal shock wave therapy, Caudal heel pain, Equine, Magnetic resonance imaging

ACKNOWLEDGMENTS

My graduate studies and this thesis would not have been possible without the insights, direction, and support of several people. I would like to acknowledge my graduate committee members and mentors (Drs. Kate Robinson, Steve Manning, Greg Starrak, and Spence Barber) for their patience, encouragement and guidance.

I would like to express my gratitude to Dr. Sheryl Gow, who provided assistance with survey design and data management for Chapter 4, and was also always available to provide support and advice.

I am especially indebted to Dr. Lea Riddell and Dr. Rebecca McOnie, who donated endless amounts of their time to data collection and organization for Chapter 5, as well as all of the Equine Field Service clinicians, past and present (Drs. Michelle Husulak, Nora Chavarria, and Lindsay Rogers), who referred horses to the research project and assisted when needed. Many thanks to Dr. Natasha Werpy, who performed all of the MRI interpretations for Chapter 5, and to Dr. Sarah Parker, who provided statistical assistance for all parts of the thesis.

It is important to note that Chapter 5 would not have been possible without all of the horses and owners who participated in the research project. These owners sacrificed their time in the pursuit of science and in search for any help for their horses. To the Townsend Equine Health Research Fund and the Mark and Pat DuMont Equine Research Fund, thank you for providing financial support for this research.

On a more personal note, I am grateful for the unwavering encouragement and support from my partner, Andy.

DEDICATION

To the horses of Chapter 5:

Rio
Sneakers
Reno
Chip
Lex
Spearmint
Chic
Max
Moxie
Peppy
Daiko
Magic
Lincoln
Katy
Bubble
Cisco
Cornflake
Scooter
Heels
Rosin
Diablo
Cody
Abby
Ally
Solaira
Kidd
Leo
Audi
Mya
Slick

TABLE OF CONTENTS

	<u>Page</u>
PERMISSION TO USE	i
ABSTRACT	ii
ACKNOWLEDGMENTS	iii
DEDICATION	iv
TABLE OF CONTENTS	v
LIST OF TABLES	viii
LIST OF FIGURES	ix
LIST OF ABBREVIATIONS	x
1. GENERAL INTRODUCTION	1
2. LITERATURE REVIEW	3
2.1 Anatomy and physiology of the equine podotrochlear apparatus	4
2.1.1 Gross anatomy of the podotrochlear apparatus and relations with other structures in the foot	4
2.1.2 Histological anatomy of the podotrochlear apparatus	6
2.1.3 Physiology and function of the podotrochlear apparatus	6
2.1.3.1 Blood supply	7
2.1.3.2 Digital cushion	8
2.2 Caudal heel pain (navicular syndrome)	8
2.2.1 Definition of caudal heel pain and other terms used	8
2.2.2 Epidemiology of caudal heel pain	9
2.2.3 Pathologic lesions consistent with caudal heel pain	9
2.2.3.1 Navicular bone	10
2.2.3.2 Deep digital flexor tendon	11
2.2.3.3 Distal sesamoidean impar ligament and collateral sesamoidean ligaments	12
2.2.3.4 Navicular bursa	13
2.2.3.5 Other(s)	13
2.2.3.6 Unilateral vs bilateral disease	13
2.2.4 Possible pathogenesis of caudal heel pain	14
2.2.4.1 Cause of degeneration/syndrome	14
2.2.4.2 Cause of pain in cases of caudal heel pain	16
2.2.5 Prognosis of caudal heel pain and associated complications	17
2.3 Diagnosis of caudal heel pain	17
2.3.1 History, clinical signs, and typical case presentation	18

2.3.2 Lameness examination and diagnostic anesthesia	18
2.3.2.1 Subjective lameness examination	18
2.3.2.2 Objective lameness evaluation	21
2.3.2.3 Diagnostic anesthesia	23
2.3.3 Radiographic evaluation	25
2.3.4 Ultrasound evaluation	27
2.3.5 Magnetic resonance imaging	27
2.3.6 Computed tomography	28
2.3.7 Nuclear scintigraphy	29
2.3.8 Bursography and navicular bursoscopy	29
2.3.9 Histopathology	30
2.4 Treatment of caudal heel pain	30
2.4.1 Therapeutic trimming and shoes	31
2.4.2 Systemic anti-inflammatories	32
2.4.3 Intra-synovial injections and medications	33
2.4.4 Rest	34
2.4.5 Bisphosphonates	34
2.4.6 Isoxsuprine	36
2.4.7 Surgical treatments	36
2.4.8 Acupuncture	37
2.4.9 Experimental treatments	38
2.5 Shock wave therapy	38
2.5.1 Physics and types	38
2.5.2 Proposed mechanisms of action	39
2.5.3 Effects on tissues	40
2.5.3.1 Effects on osseous tissues	40
2.5.3.2 Effects on tendons and ligaments	41
2.5.3.3 Effects on joints and synovial structures	42
2.5.3.4 Analgesic effects	42
2.5.4 Use and efficacy for caudal heel pain	43
2.5.5 Adverse effects	44
3. SPECIFIC AIMS	45
4. CHARACTERIZATION OF THE USE OF SHOCK WAVE THERAPY AMONG EQUINE PRACTITIONERS	46
Transition Page	47
4.1 Abstract	48
4.2 Introduction	48
4.3 Materials and methods	49
4.3.1 Sample and survey	49
4.3.2 Statistical analysis	49
4.4 Results	50

4.4.1 Demographic information	50
4.4.2 Frequency of shock wave therapy use	51
4.4.3 Method of shock wave therapy use	54
4.5 Discussion	59
4.6 Footnotes	63

5. A NOVEL APPROACH TO THE TREATMENT OF CAUDAL HEEL PAIN IN HORSES USING EXTRACORPOREAL SHOCK WAVE THERAPY 64

Transition Page	65
5.1 Abstract	66
5.2 Introduction	67
5.3 Materials and methods	69
5.3.1 Animals	69
5.3.2 Design	70
5.3.3 ESWT	72
5.3.4 Subjective lameness evaluation	74
5.3.5 Kinematic gait analysis	74
5.3.6 Magnetic resonance imaging	75
5.3.7 Statistical analysis	75
5.4 Results	76
5.4.1 Subjective lameness evaluation	79
5.4.2 Kinematic gait analysis	83
5.4.3 MRI	87
5.4.4 Adverse effects	91
5.5 Discussion	91
5.6 Footnotes	97

6. GENERAL DISCUSSION 98

6.1 Introduction	99
6.2 General results and future studies	99
6.3 Conclusion	100

REFERENCES 101

APPENDIX A - SURVEY QUESTIONS USED AS PART OF CHAPTER FOUR 119

APPENDIX B - GRAPHICAL REPRESENTATION OF KINEMATIC GAIT ANALYSIS VARIABLES OVER TIME FOR UNILATERAL HORSES ONLY 140

LIST OF TABLES

<u>Table</u>	<u>Page</u>
2.1 Lameness grading scale, American Association of Equine Practitioners.	20
4.1 Number and percent of respondents who reported using ESWT as a single treatment and as part of a multi-modal treatment approach for musculoskeletal injuries (120 respondents for each question).	53
4.2 Respondents' clinical opinion of patient tolerance for ESWT applied to specified body regions. Results are shown as number and percent of respondents per rating category (131 respondents for the question).	56
4.3 Respondents' clinical opinion of ESWT efficacy for specified musculoskeletal disorders. Results are shown as number and percent of respondents per rating category (133 respondents for the question).	58
5.1 Data collection time points for the study.	71
5.2 Demographic information for the 30 horses enrolled in the study. No significant differences were noted between groups.	78
5.3 Number and proportion (%) of limbs graded 0 (normal) to 3 (severe abnormality) for lesions or signal abnormalities in podotrochlear structures on MR imaging at day -16 in horses from the treatment (15 horses, 26 limbs) and control (15 horses, 23 limbs) groups.	88
5.4 Number and proportion (%) of limbs graded 0 (normal) to 3 (severe abnormality) for lesions or signal abnormalities in podotrochlear structures on MR imaging at day 128 in horses from the treatment (15 horses, 26 limbs) and control (15 horses, 23 limbs) groups.	89
5.5 Number and proportion (%) of limbs with a change in lesion grade on MRI between day -16 and day 128 by identified lesions and signal abnormalities in podotrochlear structures in horses from the treatment (15 horses, 26 limbs) and control (15 horses, 23 limbs) groups; P value indicates comparison between groups.	90

LIST OF FIGURES

<u>Figure</u>	<u>Page</u>
2.1 Anatomical section of the equine podotrochlear apparatus and associated structures; 1: Navicular bone, 1a: Navicular bone flexor surface fibrocartilage, 2: Distal phalanx, 3: Distal sesamoidean impar ligament, 4: Navicular bursa, 5: Deep digital flexor tendon, 6: Collateral sesamoidean ligaments, 7: Digital cushion, 8: Distal interphalangeal joint, 9: Middle phalanx.	5
5.1 Angle of ESWT trode application to the heel region of the fore foot.	73
5.2 Baseline grade of lameness, by leg, separated by group (percent of legs per grade).	80
5.3 Final grade of lameness, by leg, separated by group (percent of legs per grade).	81
5.4 Change in total lameness score (0-10/10) per horse between day -16 and day 128 separated by group and by bilateral or unilateral lameness. Median values that are significantly different ($p < 0.05$) are indicated by different letters.	82
5.5 Change in kinematic gait analysis variables (VS, Hmin, Hmax) from day 0 to day 128 in a straight line (unilateral horses only), separated by group.	84
5.6 Change in kinematic gait analysis variables (VS, Hmin, Hmax) from day 0 to day 128 in a left circle (unilateral horses only), separated by group.	85
5.7 Change in kinematic gait analysis variables (VS, Hmin, Hmax) from day 0 to day 128 in a right circle (unilateral horses only), separated by group.	86
B.1 Straight line vector sum (VS) over time, separated by group (unilateral horses only).	140
B.2 Straight line Hmin over time, separated by group (unilateral horses only).	140
B.3 Straight line Hmax over time, separated by group (unilateral horses only).	141
B.4 Left circle VS over time, separated by group (unilateral horses only).	141
B.5 Left circle Hmin over time, separated by group (unilateral horses only).	142
B.6 Left circle Hmax over time, separated by group (unilateral horses only).	142
B.7 Right circle VS over time, separated by group (unilateral horses only).	143
B.8 Right circle Hmin over time, separated by group (unilateral horses only).	143
B.9 Right circle Hmax over time, separated by group (unilateral horses only).	144

LIST OF ABBREVIATIONS

AAEP	American Association of Equine Practitioners
CSL	Collateral sesamoidean ligaments
DDFT	Deep digital flexor tendon
DSIL	Distal sesamoidean impar ligament
EFD	Energy flux density
ESWT	Extracorporeal shock wave therapy
FSE	Fast spin echo
GE	Gradient echo
Hmax	Mean difference in maximum head height
Hmin	Mean difference in minimum head height
IQR	Interquartile range
MRI	Magnetic resonance imaging
µg/kg	Micrograms per kilogram
mg/kg	Milligrams per kilogram
mJ	Millijoules
mJ/mm ²	Millijoules per square millimetre
mm	Millimetres
mm ²	Millimetres squared
NB	Navicular bone
PTA	Podotrochlear apparatus
PD	Proton density
QH	Quarter Horse
STIR	Short tau inversion recovery
P3	Third phalanx
3D	Three dimensional
TGF-β1	Transforming growth factor - beta 1
VS	Vector sum

1. GENERAL INTRODUCTION

The use of new technological procedures in equine practice has advanced at a pace faster than the scientific investigation and validation of the efficacy of these procedures. Multiple treatment options are available for musculoskeletal injuries that are not supported by blinded, controlled, peer-reviewed studies. Horse owners are often aware of these different treatments and request them for their animals. The burden is placed on the veterinarian to decipher any available research in order to be able to confidently recommend or discourage the use of a particular treatment for certain conditions. Such treatments include but are not limited to: extracorporeal shock wave therapy (ESWT), low level laser therapy, pulsed electromagnetic field therapy, and certain drugs such as bisphosphonates. Many of these treatments have been used with frequency in either the human medical field or small animal veterinary medical field prior to introduction into equine clinical practice. ESWT is one such therapy, with origins in human medicine to dissolve urinary and renal calculi (Chung and Wiley, 2002; McClure and Dorfmueller, 2003).

ESWT is available in both focused and non-focused (radial/ballistic) forms. This therapy involves the use of a machine that generates a pressure wave that can be directed at a target tissue or body part. This pressure wave causes cell displacement without heating and can stimulate a change in the release or production of multiple growth factors, depending on the target tissue (Chung and Wiley, 2002). Prior research in laboratory animals and humans has suggested that ESWT may improve osseous unions at the site of chronic fractures (Schaden et al., 2001; F. S. Wang et al., 2002), may stimulate an increased quality of healing in soft tissues (F. S. Wang et al., 2002), and can reduce pain and improve quality of life when used to treat chronic degenerative conditions (Chen et al., 2014; Chow and Cheing, 2007; Mani-Babu et al., 2015).

In horses, ESWT is anecdotally used for a wide variety of musculoskeletal conditions. The true prevalence of and indication for use by equine veterinarians is unknown. Commercially available ESWT units for veterinarians may provide protocols for use with tendinitis, desmitis, osteoarthritis, epaxial muscle pain, wounds, and caudal heel pain. Research in a wide variety of conditions in the horse has been unable to determine a clear mechanism of action but some clinical benefit when compared to negative controls (Caminoto et al., 2005; Frisbie et al., 2009; Kawcak et al., 2011; McClure and Dorfmueller, 2003; Waguespack et al., 2011).

Caudal heel pain is a common cause of chronic forelimb lameness in the horse (Sampson et al., 2009). The disease is best diagnosed with the use of advanced diagnostic imaging, such as magnetic resonance imaging (MRI) (Dyson et al., 2011a). Treatment options include therapeutic farrier work, systemic anti-inflammatories, intra-articular or intra-bursal medication, systemic bisphosphonates, and vasoactive medications (Barrett et al., 2017; Bell et al., 2009; Denoix et al., 2003; Schoonover et al., 2005). ESWT has been shown to be effective at reducing pain and lameness associated with the condition, although prior work has lacked comparison to a control group (Dahlberg et al., 2006; McClure et al., 2004a).

Given the frequency with which caudal heel pain is diagnosed in horses, and the lack of scientific evidence supporting ESWT as a treatment option, it is important to explore the use of this therapy in horses. Knowledge regarding the general use of ESWT across equine musculoskeletal diseases is useful for helping equine veterinarians make informed decisions about their treatment protocols. Likewise, scientific evidence for or against the use of ESWT as a treatment for caudal heel pain will help veterinarians make logical recommendations when treating their patients. The following discussion will review caudal heel pain (pathology, diagnosis and treatment) in detail, and ESWT as it pertains to musculoskeletal conditions in the horse.

CHAPTER TWO

LITERATURE REVIEW

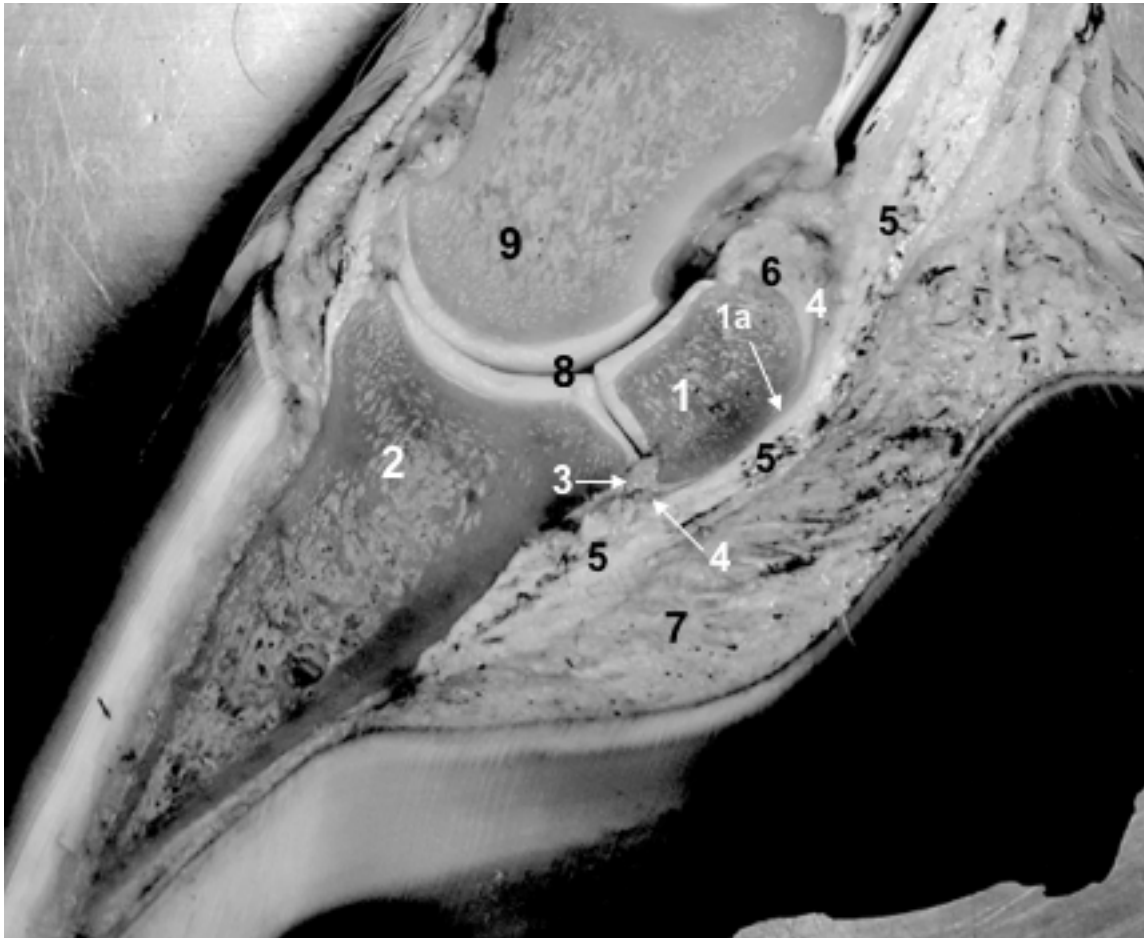
2.1 Anatomy and Physiology of the Equine Podotrochlear Apparatus

2.1.1 Gross anatomy of the podotrochlear apparatus and relations with other structures in the foot

The podotrochlear apparatus (PTA) of the equine foot is comprised of the navicular bone, the navicular bursa, the collateral sesamoidean ligaments (CSL), the distal sesamoidean impar ligament (DSIL), and the distal portion of the deep digital flexor tendon (DDFT) (Busoni and Denoix, 2001; Dyson et al., 2011a) (Figure 2.1). The navicular bone is the distal sesamoid bone for the DDFT at the angle of insertion, and is the central structure of the PTA (Gabriel et al., 1998). This small oblong bone lies palmar/plantar to the distal phalanx and palmaro/plantaro-distal to the middle phalanx, and articulates with both bones to form the distal interphalangeal joint (Kainer and Fails, 2011). The remainder of this discussion will focus on the navicular bone and PTA in the forelimb only. The navicular bone has four borders or cortices: the proximal cortex, the articular or dorsal cortex which has a hyaline cartilage surface as per its articulation, the palmar or flexor cortex, which has a fibrocartilage surface, and the distal cortex, part of which articulates with the distal phalanx (Gabriel et al., 1998; Wright et al., 1998). The CSL and DSIL make up the navicular suspensory apparatus to suspend the navicular bone in place (Kainer and Fails, 2011). The CSL extend from the distal aspect of the proximal phalanx and the middle phalanx to insert on the proximal border of the navicular bone and connect the bone to the lateral and medial collateral cartilages of the distal phalanx, providing proximal and medial-lateral support for the navicular bone (Gabriel et al., 1998; Van Wulfen and Bowker, 1997). The DSIL stabilizes the navicular bone distally by extending from the distal border to insert on the palmar aspect of the distal phalanx, dorsal to the insertion of the DDFT (Kainer and Fails, 2011). The DDFT courses palmar to and against the flexor surface of the navicular bone over the navicular bursa to insert on the palmar aspect of the distal phalanx (Dyson et al., 2003).

Other pertinent structures within the foot that are closely associated with the PTA include the distal interphalangeal joint, the collateral ligaments of the distal interphalangeal joint, the palmar processes of the distal phalanx, the digital cushion, the distal digital annular ligament, and the ligaments of the collateral cartilages of the distal phalanx (Bowker et al., 1997; Dabareiner and Carter, 2003; Kainer and Fails, 2011) (Figure 2.1).

Figure 2.1 Anatomical section of the equine podotrochlear apparatus and associated structures; 1: Navicular bone, 1a: Navicular bone flexor surface fibrocartilage, 2: Distal phalanx, 3: Distal sesamoidean impar ligament, 4: Navicular bursa, 5: Deep digital flexor tendon, 6: Collateral sesamoidean ligaments, 7: Digital cushion, 8: Distal interphalangeal joint, 9: Middle phalanx.



2.1.2 Histological anatomy of the podotrochlear apparatus

Histological anatomy of the PTA has been shown to correlate with anatomy identified on magnetic resonance imaging (MRI) (Murray et al., 2006a), so deviations from normal are important to understand. Hyaline cartilage lines the dorsal cortex and the dorsal aspect of the distal cortex of the navicular bone (Blunden et al., 2006a). The flexor cortex of the navicular bone is covered in fibrocartilage (Gabriel et al., 1998). This aspect of the navicular bone is under a high degree of compressive strain, and the trabecular alignment within the bone is oriented along the axis of the compressive forces that arise from the DDFT (Wilson et al., 2001).

Nutrient foramina are present in the distal cortex of the navicular bone. Distal nutrient foramina contain blood vessels and vary in width, but this is not related to pathology of the vasculature (Wright et al., 1998). Synovial invaginations are present primarily in the distal cortex of the navicular bone, but also in the proximal, medial and lateral cortices, and are lined with synovium (Claerhoudt et al., 2011). Olive and Videau (2017) recently determined that distal border synovial invaginations of the navicular bone communicate with the distal interphalangeal joint, but not with the navicular bursa.

The DSIL originates from the distal cortex of the navicular bone, and has linear fibers running in fascicles between the navicular bone and the distal phalanx. The interstitium between the fascicles is well vascularized and has pockets that are lined with synovial membrane. Both the origin and insertion of the DSIL represent a bone-ligament interface (Blunden et al., 2006a). The insertions of the DSIL and the DDFT have large numbers of sensory nerve endings and arteriovenous complexes (Van Wulfen and Bowker, 1997). Smooth transitional fibrocartilagenous metaplasia may be present at the edges of the CSL (Blunden et al., 2006a).

2.1.3 Physiology and function of the podotrochlear apparatus

The PTA provides palmar stability for the distal interphalangeal joint (Dyson et al., 2011a; Parkes et al., 2015) and resists hyperextension of the distal interphalangeal joint at the break-over point of the stride (Murray et al., 2006b). The navicular bone provides a constant angle of insertion to maintain mechanical advantage for the DDFT, and acts as a fulcrum to allow for flexion of the distal interphalangeal joint (Dyson et al., 2011a; Kainer and Fails, 2011). The distal third of the navicular bone experiences strong compressive forces both during the

propulsion and the stance phase of the stride as a result of the change in angle of the DDFT (Dyson et al., 2011a; Wilson et al., 2001).

The function and biomechanics of the PTA inherently lead to adaptive changes within the structures of the apparatus (Wright et al., 1998). The navicular bone experiences both tension from the suspensory apparatus and compressive forces from the DDFT during stance and propulsion during a stride (Bowker et al., 2001; Wilson et al., 2001). The flexor cortex may thicken due to increased tension within the CSL and DSIL as a result of increased exercise (Biggi and Dyson, 2012). A zone of fibrocartilage may form in the dorsal aspect of the DDFT immediately proximal to the navicular bone that is rich in elastic fibers (Blunden et al., 2006b). This is thought to represent a functional adaptation similar to the superficial digital flexor tendon at the palmar fetlock region, where the tendon experiences higher compressive force (Blunden et al., 2006b; Smith et al., 1997).

The function of the navicular bone and PTA may contribute to the development of caudal heel pain if the normal forces on the bone become altered due to external factors (McGuigan and Wilson, 2001; Wilson et al., 2001). The entire foot of the horse plays a part in maintaining normal physiology and therefore normal forces on the PTA. Key structures include the blood supply and the digital cushion.

2.1.3.1 Blood supply

The equine foot, including the PTA, is supplied by an extensive system of connected and anastomosing vessels (Rijkenhuizen et al., 1989a). The arterial supply of the foot arises from branches of the medial and lateral digital arteries, the dorsal artery of the middle phalanx, the palmar artery of the middle phalanx, and the dorsal artery of the distal phalanx. The navicular bone is supplied primarily by the branches of the medial and lateral digital arteries branching to enter the distal border, and the palmar artery of the middle phalanx that forms branches and anastomoses to enter the proximal border (Rijkenhuizen et al., 1989a). Venous drainage exits the navicular bone at the distal border through the DSIL to the solar venous plexus, which then forms the medial and lateral digital vein. Further venous branches exit the navicular bone from the proximal border to form anastomoses with the medial and lateral digital veins (Rijkenhuizen et al., 1989b, 1989a). Most veins in the foot do not have valves, so blood flow from the foot can take different routes through the various anastomoses. Normal weight bearing and movement is

critical to ensure proximal flow of blood with the assistance of the digital cushion (Bowker, 2003; Gunkelman and Hammer, 2017; Rijkenhuizen et al., 1989b, 1989a).

2.1.3.2 Digital Cushion

The digital cushion is located between the collateral cartilages of the foot and above the frog. This cushioning structure is made up of collagen, elastic fibers, fibrocartilage and adipose tissue (Bowker, 2003; Gunkelman and Hammer, 2017). The digital cushion is important for shock absorption during impact with the ground and may assist with blood pumping to encourage venous return in a proximal direction (Bowker, 2003; Bowker et al., 1998). The composition of the digital cushion changes with age from fat and elastic tissue to stronger fibrocartilage. Poor foot conformation may result in altered stride biomechanics and decreased compression of the digital cushion, consequently resulting in decreased shock absorption and blood flow efficiency, and a higher percent of impact being transferred to the bony column of the limb (Bowker, 2003).

2.2 Caudal Heel Pain (Navicular Syndrome)

2.2.1 Definition of caudal heel pain and other terms used

Caudal heel pain is defined as lameness resulting from pain associated with pathology of the navicular bone, with or without injury affecting the soft tissue structures of the PTA (Parkes et al., 2015). Other terms used to describe this syndrome include palmar heel pain, palmar foot pain, podotrochlosis, navicular syndrome, or navicular disease (Dyson et al., 2011a; Groth et al., 2009; Maher et al., 2011; Marsh et al., 2012; Murray et al., 2006b; Parkes et al., 2015; Sherlock et al., 2008). The term “navicular disease” has historically referred to pain originating from the navicular bone of the forelimbs (Baxter et al., 2011). However, pathology of the navicular bone in isolation is a rare occurrence (Dyson et al., 2012) and advances in diagnostic imaging technology have identified injury to both the osseous and the soft tissue structures of the PTA (Dyson et al., 2011a; Parkes et al., 2015). A diagnosis of caudal heel pain now describes a clinical syndrome representing a multitude of pathologic lesions within the PTA. This is important to understand when considering rational diagnostic and treatment options (Murray et al., 2006b). Reports of caudal heel pain in the hindlimbs are rare, so the syndrome is typically considered a forelimb problem (Dyson et al., 2011a).

2.2.2 Epidemiology of caudal heel pain

Large scale epidemiologic descriptions of caudal heel pain are not available (Dyson et al., 2011a). The true prevalence has not been established, but the syndrome is estimated to cause one third of all forelimb lameness in horses (Dabareiner and Carter, 2003; Sampson et al., 2009). Retrospective reports of cohorts of affected horses indicate that there is a high incidence in the Quarter Horse, Warmblood, and Thoroughbred cross breeds (Bell et al., 2009; Biggi and Dyson, 2011; Gutierrez-Nibeyro et al., 2012; Sampson et al., 2009). A genetic predisposition has been identified in Dutch Warmblood and Hanoverian breeds, primarily associated with navicular bone proximal border shape (Dik et al., 2001a, 2001b; Dik and van den Broek, 1995). No such heritability has been established in other breeds of horses.

Risk factors for syndrome development have been difficult to quantify, but it has been reported in the United Kingdom and Europe that horses with long toes and low heels may be predisposed to caudal heel pain (Dyson et al., 2011a). In North America, horses with proportionally small feet for their body size with upright foot conformation may be more predisposed. In addition, poor musculoskeletal conformation, poor farrier and hoof care, exercise on hard surfaces, and abnormal stresses placed on the foot such as tight turns at speed or landing following a jump may all predispose a horse to the development of caudal heel pain (Dabareiner and Carter, 2003).

2.2.3 Pathologic lesions consistent with caudal heel pain

A complex of degenerative changes is commonly noted in the PTA of horses affected with caudal heel pain, including abnormalities of the CSL, DSIL, and the navicular bursa, in conjunction with DDFT and navicular bone lesions (Dyson et al., 2012, 2011a, 2003; Dyson and Murray, 2007a). Pathology of the navicular bone in isolation is rarely identified, and usually cases of caudal heel pain involve injury to two or more structures of the PTA (Dyson et al., 2012; Murray et al., 2006b). Retrospective studies support this finding. Gutierrez-Nibeyro et al. (2010) evaluated 56 horses with pain localized to the palmar heel region; 50/56 horses had multiple abnormalities in closely related structures in the lamest limb, and 38% of that population had concurrent injury to the DDFT, navicular bursa, and navicular bone. Murray et al. (2006b) had similar results. It is important to note that primary injury to the DDFT within the foot in the

absence of abnormalities of the other podotrochlear structures is not considered caudal heel pain per se, but may be a precursor to the syndrome (Dyson et al., 2011a, 2003).

With the advent of MRI, accurate ante-mortem lesion identification, classification, and grading in comparison to histologic findings has been made possible. Prior to MRI, soft tissue injury would only have been suspected in horses with lameness localized to the caudal heel region of the front foot and no radiographic abnormalities. Now, these cases of caudal heel pain can be further characterized using MRI, and a range of lesions have been identified (Sampson et al., 2009). Early disease may present as navicular bone edema and dorsal fibrillation of the DDFT identified on MRI (Dyson et al., 2011a; Sampson et al., 2009), whereas advanced cases of caudal heel pain often involve navicular bone degeneration combined with fibrillation of the dorsal aspect of the DDFT and sometimes adhesion formation between the tendon and the navicular bursa and/or navicular bone (Wright et al., 1998). While usually considered in concert, each structure of the PTA can have a range of abnormalities that have been confirmed histologically.

2.2.3.1 Navicular bone

Numerous abnormalities of the navicular bone have been described. Erosive lesions through the fibrocartilage or extending into the subchondral bone may be present on the flexor cortex (Sherlock et al., 2008; Wright et al., 1998). This may represent irreversible damage. These severe cases of caudal heel pain will have histologic abnormalities consistent with fibrocartilage degeneration and subchondral bone necrosis with possible areas of fibrosis and sclerosis (Blunden et al., 2006a). In addition, concurrent degenerative lesions of the navicular bone medulla may be present. These may include lysis of the subchondral bone adjacent to the fibrocartilage defects as well as congestion, fibrosis, and bone loss within the medulla. Less advanced cases of caudal heel pain may have histopathologic findings such as thinning, fibrillation or loss of the fibrocartilage layer, including in areas with no gross pathologic evidence of fibrocartilage erosion (Blunden et al., 2006a; Dyson et al., 2012; Wright et al., 1998). Corresponding abnormalities within the subchondral bone may be noted as regions of thinned or lost bone being replaced by fibrovascular tissue (Sherlock et al., 2008).

In addition to degeneration of the flexor cortex, the distal and proximal borders of the navicular bone may also exhibit pathology. Distal border fragments are associated with caudal heel pain, but have also been observed in non-lame limbs (Biggi and Dyson, 2012).

Enthesophytes may develop in association with the attachments of the DSIL and CSL on the distal and proximal cortices, respectively (Blunden et al., 2006a; Murray et al., 2006b). Synovial invaginations on the distal aspect of the navicular bone may be enlarged, although the significance of this finding in cases of caudal heel pain is debated. This is due to the fact that these invaginations have been shown to communicate only with the distal interphalangeal joint, and not with the navicular bursa (Olive and Videau, 2017). However, chronic inflammation of the distal interphalangeal joint could contribute to local osteonecrosis of the navicular bone (Dyson and Murray, 2007a), and inflammation of the distal interphalangeal joint may occur in conjunction with injury to the PTA (Blunden et al., 2006a; Sampson et al., 2009). Osseous cyst-like lesions may be present in the navicular bone medulla, and are typically pseudocysts with a fibrous capsule upon histologic examination (Wright et al., 1998). These lytic defects can be associated with areas of thinned fibrocartilage on the flexor cortex, and some may even communicate with a cortical bone defect, although another study has observed osseous cyst-like lesions in association with distal border fragments (Biggi and Dyson, 2010). Navicular bone medullary changes may also include sclerosis, which is often adjacent to palmar cortex fibrocartilage erosion (Pool et al., 1989).

Some cases of caudal heel pain may have increased MRI signal within the navicular bone medulla on fat suppressed images as the only abnormal finding. This may represent diffuse abnormalities such as osseous edema, contusion, osteonecrosis, capillary infiltration, or hemorrhage, which can only be definitively determined with post-mortem histologic evaluation (Busoni et al., 2005; Murray et al., 2006a). Pathologic change in the navicular bone has been identified as having a symmetrical distribution with some evidence of a pattern, likely related to the compressive forces the bone experiences from the DDFT (Wilson et al., 2001; Wright et al., 1998).

2.2.3.2 Deep digital flexor tendon

Multiple lesion types have been identified in the DDFT within the foot of horses affected with caudal heel pain, including dorsal abrasions or fibrillation, parasagittal splits, core lesions, and insertional lesions (Cillán-García et al., 2013; Schramme, 2011). Dorsal fibrillation is often identified and is thought to be an important part of the disease complex. Dorsal fibrillation is associated with erosions and loss of fibrocartilage from the flexor cortex of the navicular bone,

and can contribute to the formation of adhesions between the DDFT and the navicular bone (Wright et al., 1998). This may perpetuate navicular bone damage and contribute to pain (Dyson and Murray, 2007a). Dorsal fibrillation of the DDFT has been identified in age-matched non-lame horses, but parasagittal splits have only been identified in lame horses (Dyson et al., 2011a). Parasagittal splits that propagate along septal lines within the DDFT may also be part of the degenerative process, contributing to navicular bone flexor cortex damage due to exposed sharp edges of the tendon moving along the bone surface (Blunden et al., 2006b; Dyson et al., 2011a; Dyson and Murray, 2007a). Core lesions within the DDFT above the level of the navicular bone are most likely due to primary injury of the DDFT and are not considered part of the caudal heel pain syndrome (Cillán-García et al., 2013). However, this primary damage to the DDFT may contribute to degeneration of the PTA over time (Dyson et al., 2011a; Sampson et al., 2009). Insertional lesions may include small core lesions, parasagittal splits, or enthesiopathy at the insertion site (Blunden et al., 2009; Schramme, 2011). Insertional lesions may be a distal continuation of more proximal lesions (Schramme, 2011). Degenerative changes have been identified within the DDFT on histopathology. These include focal fibroplasia and fibrocartilaginous metaplasia within the dorsal aspect or intratendonous septa of the DDFT (Blunden et al., 2006a, 2006b; Dyson et al., 2012; Wright et al., 1998). Histological studies of advanced caudal heel pain have not been able to identify acute inflammatory changes in the DDFT, which suggests that the etiology is more degenerative (Blunden et al., 2006b; Busoni et al., 2005). To the author's knowledge, histologic evaluation of early caudal heel pain has not been published.

2.2.3.3 Distal sesamoidean impar ligament and collateral sesamoidean ligaments

Abnormalities of the DSIL include insertional enthesiophytosis, fibrocartilaginous metaplasia, focal fibroplasia, degeneration of collagen, fibre pattern irregularity, palmar border disruption with adhesions between the DSIL and DDFT, and generalized ligament thickening (Blunden et al., 2006a; Murray et al., 2006b). The DSIL may be abnormal in conjunction with distal border fragments of the navicular bone, and distal border fragments have been shown to consistently be embedded within the DSIL (Biggi and Dyson, 2011).

The CSL may vary in size and signal intensity on MRI, even when normal (Murray et al., 2006b). Abnormalities noted in cases of caudal heel pain include ligament enlargement, adhesion

between the DDFT and CSL, and poorly defined margins of the CSL (Murray et al., 2006b; Sampson et al., 2009). Multiple retrospective studies have identified abnormalities in either the DSIL or the CSL in concurrence with injury to the other structures of the PTA (Dyson and Murray, 2007a; Gutierrez-Nibeyro et al., 2012; Murray et al., 2006b; Sampson et al., 2009).

2.2.3.4 Navicular bursa

Inflammation of the navicular bursa (navicular bursitis) may be identified in cases of caudal heel pain (Murray et al., 2006b; Sampson et al., 2009). Inflammation is characterized by villous hypertrophy, synovial proliferation and hyperplasia, and abnormal distension of the bursa (Blunden et al., 2006a; Murray et al., 2006b; Pleasant et al., 1993). Primary navicular bursitis is rarely identified in the absence of other abnormalities in the palmar foot (Dyson and Murray, 2007; Dyson et al., 2005; Sampson et al., 2009). Adhesions between the DDFT and the navicular bursa are often noted in conjunction with dorsal fibrillation of the DDFT (Sampson et al., 2009).

2.2.3.5 Other(s)

Other structures within the foot may have mild to moderate abnormalities in conjunction with a diagnosis of caudal heel pain. Synovitis of varying severity may be present within the distal interphalangeal joint, characterized by effusion and synovial proliferation (Blunden et al., 2006a; Gutierrez-Nibeyro et al., 2012; Murray et al., 2006b; Sampson et al., 2009). The digital flexor tendon sheath may also have increased synovial fluid (Gutierrez-Nibeyro et al., 2012; Sampson et al., 2009). Desmopathy of the collateral ligaments of the distal interphalangeal joint may be present in conjunction with a primary diagnosis of caudal heel pain (Blunden et al., 2006a; Gutierrez-Nibeyro et al., 2012). The distal phalanx may have endosteal or palmar cortical irregularity at the insertion of the DDFT and/or DSIL, particularly when these structures are abnormal (Murray et al., 2006a).

2.2.3.6 Unilateral vs bilateral disease

In unilaterally lame horses, abnormalities may be present in the PTA of the contralateral limb despite a lack of lameness in that limb (Gutierrez-Nibeyro et al., 2012; Murray et al., 2006b). It is unknown if this is due to a change in weight bearing and increase in mechanical load on the non-lame limb, or if it is early degeneration of the PTA that will lead to lameness in the

future (Murray et al., 2006b). Gutierrez-Nibeyro et al. (2012) found that of 42 horses with unilateral forelimb lameness localized to the foot, 18 of those horses had MRI abnormalities within the PTA of the non-lame forelimb that was scanned for comparison purposes. Sampson et al. (2009) evaluated bilaterally lame horses only, and 93% of those had the most severe lesions in the lamest foot; however, 7% of horses had the most severe MRI lesions in the less lame foot.

Horses with unilateral caudal heel pain may have a different inciting cause than those with bilateral caudal heel pain (Baxter et al., 2011). If no abnormalities are present on imaging of the contralateral limb, the affected limb may have been subject to trauma such as a penetrating wound or foreign body, congenital disorder such as a bi-partite navicular bone, or chronic primary DDFT injury leading to navicular bone degeneration (Dyson et al., 2011a).

2.2.4 Possible pathogenesis

2.2.4.1 Cause of degeneration/syndrome

Caudal heel pain is poorly understood in terms of pathophysiology, and the sequence of injury between multiple podotrochlear structures is unknown (Dyson et al., 2011a). Three theories have been proposed: vascular compromise with ischemic events, mechanical trauma to the bone from constant compressive forces (arising from the DDFT), and chronic degeneration related to age and use, similar to osteoarthritis (Sampson et al., 2009; Widmer et al., 2000; Wright et al., 1998). An inability to reproduce the disease experimentally means that any suggested pathogenesis is somewhat speculative (Dyson et al., 2011a).

The vascular theory suggests that thrombosis of the navicular arteries and incomplete occlusion and atherosclerosis of the distal limb arteries results in ischemia of the navicular bone and therefore, degeneration of the fibrocartilage (Colles and Hickman, 1977; Fricker et al., 1982; Rijkenhuizen et al., 1989b, 1989c, 1989a). However, podotrochlear pathology or lameness cannot be reproduced by altering blood flow (Dyson et al., 2011; Ostblom et al., 1982; Pool et al., 1989), although obstructing venous outflow to cause congestion and increased bone marrow pressure within the navicular bone may result in pain and contribute to the development of clinically apparent lameness (Rijkenhuizen et al., 1989b; Svalastoga and Smith, 1983). Furthermore, hyperemia and increased vascularization within the navicular bone has been identified in horses with podotrochlear pathology (MacGregor, 1984; Ostblom et al., 1982), and vasculitis or

hypertensive vascular changes have been noted in diseased navicular bones histologically (Wright et al., 1998). More recently, ischemia and thrombosis were not noted on histologic examination of diseased navicular bones, indicating a lack of arterial occlusion (Blunden et al., 2006a). This evidence has resulted in a rejection of this theory of pathogenesis (Dyson et al., 2011a).

The theory of mechanical induction suggests that abnormal compressive forces cause trauma to the navicular bone and contribute to tissue degeneration (Rijkenhuizen, 2006; Wright et al., 1998). Abnormal forces result from either excessive loads placed on normal structures, or normal loads placed on abnormal structures (Baxter et al., 2011). The DDFT applies compressive forces to the navicular bone during both the stance and propulsive phases of the stride (Wilson et al., 2001). The amount of force applied to the navicular bone flexor surface is affected by conformation and gait. Excessive force on the PTA can result from poor hoof conformation such as long toes and low heels or a broken-back hoof pastern axis, improper medio-lateral balance of the foot, excessive body weight, and repetitive work on hard surfaces (Dabareiner and Carter, 2003). Eliashar et al. (2004) determined that a decrease in distal phalanx palmar angle by one degree results in a 20 percent increase in force on the navicular bone in early stance in normal horses, so low heels may predispose horses to caudal heel pain due to increased force on the bone. Conversely, the peak force applied to the navicular bone is reduced by four percent for every degree of increase in the palmar angle of the distal phalanx. Horses affected by caudal heel pain tend to land toe first to guard the heel region, but this has been shown to double the force applied to the navicular bone by the DDFT as compared to normal horses (Wilson et al., 2001). This measured effect may create a feedback loop that perpetuates the abnormal biomechanical forces and disease progression once a structure in the heel region becomes injured and painful. The most prominent aspect of the navicular bone is the distal half of the flexor cortex, which is the most common location for erosions of the osseous surface (Sherlock et al., 2008; Wright et al., 1998). This is likely because this portion of the bone is subject to a higher degree of compressive force. It is assumed that all structures of the PTA experience similar biomechanical stresses to that of the navicular bone because altogether they act as a single unit (Dyson et al., 2011a).

Based on the available evidence, mechanical induction is the most supported pathogenesis of the syndrome of caudal heel pain. Regardless, the pathologic features of caudal heel pain

lesions are similar to those of degenerative joint disease with the exception that the fibrocartilage of the flexor cortex of the navicular bone is affected versus hyaline cartilage that is typically affected in joints (Gabriel et al., 1998; Wright et al., 1998). Both degenerative joint disease and pathology of the navicular bone in cases of caudal heel pain are associated with thinned cartilage, reduced cartilage cellularity, enthesophyte or osteophyte formation, and subchondral bone erosion (Wright et al., 1998). Further, dorsal fibrillation and sagittal splitting of the DDFT are thought to be associated with a degenerative process, could cause ulceration of the fibrocartilage on the flexor surface of the navicular bone, and may result in adhesion formation and reduced function over time (Blunden et al., 2006b; Dyson and Murray, 2007a; Wright et al., 1998). The sequence of injury to the PTA is unknown, but it is possible that horses will be more predisposed to clinically significant lesions when several structures in the heel have mild degenerative changes (Dyson et al., 2011a). It has been speculated that the degeneration noted pathologically in end-stage caudal heel pain may be a result of a combination of pathogeneses, which gives reason for the chronic, progressive clinical syndrome that is often noted (Wright et al., 1998).

2.2.4.2 Cause of pain in cases of caudal heel pain

Caudal heel pain is a significant source of pain and lameness for many horses. The particular source of pain can vary widely depending on the individual horse, may be due to more than one cause, and is difficult to determine apart from localization to the caudal heel region due to limitations with diagnostic anesthesia (Schumacher et al., 2001a, 2001b). Possible causes of pain include venous congestion of the navicular bone, increased intra-osseous pressure of the navicular bone or the distal phalanx at the insertion of the DSIL or DDFT, distention of the navicular bursa, adhesions between the DDFT and other PTA structures, disruption of the aforementioned adhesions, or disruption of the many sensory nerve endings within the CSL or DSIL (Bowker et al., 1997; Dyson et al., 2011a; Parkes et al., 2015). Inflammation causing pain may or may not be present in cases of caudal heel pain. Wright et al. (1998) only found histological evidence of degeneration in advanced cases, while Van Wulfen and Bowker (1997) noted inflammation at the intersection of the DDFT and DSIL in clinically affected horses.

2.2.5 Prognosis of caudal heel pain and associated complications

Caudal heel pain is associated with a poor prognosis for disease resolution, especially if advanced degenerative changes are present (Dabareiner and Carter, 2003; Dyson and Murray, 2007a; Rijkenhuizen, 2006). In particular, horses with deep digital flexor tendinopathy, navicular bone flexor surface erosions, synovial proliferation within the navicular bursa, and adhesions between the DDFT and associated structures are associated with an unsuccessful long-term outcome (Bell et al., 2009; Gutierrez-Nibeyro et al., 2010). Retrospective studies have determined that the presence of multiple abnormalities within the foot worsens the prognosis, despite attempting treatment (Gutierrez-Nibeyro et al., 2010; Lutter et al., 2015). Additionally, these and other reports indicate that the majority of horses studied have multiple abnormalities within the foot upon diagnosis (Dyson and Murray, 2007a). One study evaluating outcome following a combined treatment regimen of therapeutic shoeing, intrasynovial corticosteroids and extracorporeal shock wave therapy (ESWT) through the frog in a portion of horses only had 22/56 (39.3%) horses return to their previous level of exercise for a period of time (Gutierrez-nibeyro et al., 2010). Expected complications of caudal heel pain are dependent on the individual horse and treatment pursued. These can include complete fracture of the navicular bone, rupture of the DDFT, or chronic severe lameness that is not responsive to treatment and results in a decreased quality of life (Baxter et al., 2011).

As indicated above, there is currently no available cure for caudal heel pain, and treatment options are better thought of as pain management strategies (Baxter et al., 2011). Determining predisposing factors and attempting to prevent the disease is likely the better way to control navicular syndrome (Rijkenhuizen, 2006). The syndrome is unlikely to resolve completely, and partial improvement or temporary resolution of clinical signs can be expected for a variable time period in 40-50% of horses regardless of management used (Dyson et al., 2005; Rijkenhuizen, 2006). Optimal management strategy and prognosis are dependent on the specific lesions within the foot of the individual horse, indicating MRI as an important part of the diagnostic process (Dabareiner and Carter, 2003; Dyson et al., 2005).

2.3 Diagnosis of Caudal Heel Pain

The diagnostic criteria of caudal heel pain typically include a unilateral or bilateral forelimb lameness that is localized to the heel region of the foot with diagnostic anesthesia

(Dyson et al., 2011a; Dyson and Murray, 2007a; Parkes et al., 2015). Diagnostic imaging will show injury to one or more structures of the PTA (Bell et al., 2009; Dyson et al., 2011a; Dyson and Murray, 2007a; Parkes et al., 2015; Sampson et al., 2009). The diagnostic process involves a thorough lameness exam combined with one or more types of medical imaging.

2.3.1 History, clinical signs, and typical case presentation

Caudal heel pain in the horse often presents as a unilateral or bilateral chronic forelimb lameness with varying clinical signs and duration (Dyson et al., 2011a). The classical presentation is a middle-aged gelding that is of Quarter Horse, Thoroughbred, or Warmblood lineage (Dabareiner and Carter, 2003; Sampson et al., 2008). Horses of all types and uses can be affected. The horse may present with intermittent, slowly worsening, bilateral forelimb lameness that is worse on hard or uneven terrain (Dabareiner and Carter, 2003; Parkes et al., 2015). However, an acute onset of severe unilateral forelimb lameness is also described concurrently with an MRI diagnosis of caudal heel pain (Dyson et al., 2011a).

2.3.2 Lameness examination and diagnostic anesthesia

2.3.2.1 Subjective lameness examination

Lameness in the horse is a clinical sign representing a source of pain or mechanical obstruction (de Grauw and van Loon, 2016). A thorough lameness examination requires observation of movement at the walk and trot in straight lines and on a circle in both directions to facilitate detection of a source of pain (Mitchell, 2012). Lameness horses adapt their movement to reduce force on the painful limb by shifting their weight, abnormally moving a body part, changing joint angles, and altering foot flight (Dyson, 2011a). Vertical displacement of the head and rump from the normal plane are the most consistently observed gait alterations in lame horses. Horses with unilateral forelimb lameness may exhibit asymmetric head and neck movement (a “head nod”) to shift weight off of the lame limb (Baxter and Stashak, 2011a). If bilateral forelimb lameness is present, the severity of the head nod can be greatly reduced and a short, shuffling gait may be observed (Keegan et al., 2012). Lameness diagnosis from observation requires expertise and experience, and subjective lameness evaluation carries limited sensitivity, specificity, and repeatability between and among observers (Dyson, 2011a; Fuller et

al., 2006; Keegan et al., 2010). Reliability of subjective lameness scoring over time for a mild to moderate lameness by a single assessor is acceptable (Fuller et al., 2006), but agreement between observers for evaluation of mild lameness is poor (Donnell et al., 2015; Keegan et al., 2010). Subjective lameness assessment requires the use of a scoring system to record and characterize the lameness, and may be affected by observer bias (Keegan et al., 2012).

Several scoring systems exist for equine lameness exams. These include but are not limited to: a verbal rating scale with categories of consistency such as the one recommended by the American Association for Equine Practitioners (AAEP) (Swanson, 1984) (Table 2.1), a numerical rating system that assigns an increasing number based on severity in certain situations (Dyson, 2011a; Fuller et al., 2006), and a visual analogue scale (de Grauw and van Loon, 2016; Dyson, 2011a). Verbal rating scales can allow for more accurate score assignment to a particular lameness, but may also force a lameness to be scored in a category that is not a perfect fit (Fuller et al., 2006) and are affected by practitioner interpretation of the categories (Hewetson et al., 2006). The scale recommended by the AAEP is anecdotally the most recognized scale used in North America. Regardless of the scoring system used, consistency in application by a single observer over time is important in both clinical case situations and when assessing lameness interventions in a research setting (de Grauw et al., 2016; Dyson, 2011a).

Table 2.1 Lameness Grading Scale, American Association of Equine Practitioners (Swanson, 1984)

Grade	Description
0	Lameness not perceptible under any circumstances
1	Lameness difficult to observe; not consistently apparent regardless of circumstance (e.g. under saddle, circling, inclines, hard surfaces, etc.)
2	Lameness difficult to observe at a walk or when trotting in a straight line but consistently apparent under certain circumstances (e.g. under saddle, circling, inclines, hard surfaces etc.)
3	Lameness is consistently observable at a trot under all circumstances
4	Lameness is obvious at a walk
5	Lameness produces minimal weight bearing in motion and/or at rest or a complete inability to move

Manipulations should be performed following visual identification of the primary lame limb to further localize the source of pain. Manipulations include flexion tests, hoof tester application, direct manipulation of a joint or soft tissue structure, wedge tests, and varus or valgus stress tests (Baxter and Stashak, 2011a). Flexion tests are nonspecific, false positives are common, and many normal horses may show positive responses (Mitchell, 2012). Response of the contralateral weight bearing limb should also be recorded following a flexion test. Anecdotally, horses affected by navicular syndrome may be worse after flexion of the contralateral limb and increased weight bearing on the affected limb. Hoof tester application permits deep palpation of the sole and other external structures of the foot (Baxter and Stashak, 2011a), but findings may be nonspecific and should be interpreted cautiously (Parkes et al., 2015).

A lameness examination of a horse affected by caudal heel pain often reveals a short-strided gait in the forelimbs, and the lameness may be exacerbated when the most lame limb is on the inside of the lunging circle (Dabareiner and Carter, 2003). The lameness can be inconsistent in severity between multiple examinations and a daily fluctuation in lameness severity has even been noted in some affected horses (Parkes et al., 2015). Response to distal limb flexion and hoof tester application is variable and not predictive of a diagnosis for caudal heel pain (Parkes et al., 2015). A mild increase in lameness severity following flexion of the distal limb is a common, nonspecific finding in many horses that are exercised regularly and is not necessarily indicative of lameness originating from the distal limb (Baxter and Stashak, 2011a).

2.3.2.2 Objective lameness evaluation

Although subjective gait assessment is the time-honoured method for lameness evaluation in equine practice, concurrent real-time objective assessment of the equine gait is gaining popularity. There is an increasing availability of easy-to-use commercial systems that are scientifically validated to quantify equine lameness and have increased accuracy and sensitivity when compared to subjective examinations (Donnell et al., 2015; Moorman et al., 2017). The Lameness Locator® is one such commercially available inertial sensor system used for objective kinematic gait analysis in horses and is anecdotally the most widely used system.

Inertial sensor systems vary in specific configuration and capabilities. The Lameness Locator® uses two accelerometers attached to the head and pelvis on midline, and one gyroscope

attached to the right front pastern (Keegan et al., 2012). These sensors transmit measurements wirelessly to the accompanying software that include vertical displacement of the head and pelvis from the normal position of the sensor (measured in millimeters) in relation to the angular velocity of the right forelimb. This communicates the position of the limb in space and which limbs are on the ground at the trot to the accompanying software (Keegan et al., 2012, 2011). Asymmetric vertical movement of the torso reflects a reduction in ground reaction forces of a limb and indicates lameness (Keegan et al., 2012). The software can then localize a lameness to a particular limb based on the association of head or pelvic movement to the angular velocity of the right forelimb, and will quantify this asymmetry in torso movement between the left and right halves of the stride to determine the severity of the lameness (Keegan, 2011; Keegan et al., 2012, 2011). The Lameness Locator® inertial sensor system has been shown to be significantly more sensitive than subjective lameness evaluation by an experienced veterinarian for accurately detecting lameness in the horse (McCracken et al., 2012).

Another available method of objective lameness assessment is the use of a stationary force plate. The force plate has historically been considered the gold standard for objective lameness measurement in horses (Keegan et al., 2012). Force plate analysis of lameness measures peak vertical force and stance duration of a single limb (Donnell et al., 2015). Reduction in these parameters indicates a lameness (Keegan et al., 2012). Unfortunately, force plate analysis is impractical in a clinical setting because only one stride is recorded at a time and the force plate is limited to a stationary location (Donnell et al., 2015). Early work showed that vertical torso movement asymmetry measurements produced by inertial sensor systems have similar precision for lameness detection when compared to force plate analysis of lameness (Keegan et al., 2012). Stationary force plate analysis has recently been shown to have poor agreement with subjective evaluation when identifying mild forelimb lameness, and decreased sensitivity and agreement compared to inertial sensor system analysis (Donnell et al., 2015). While the two methods of measurement are evaluating different parameters of lameness, there is strong correlation when used to evaluate moderate forelimb lameness, and agreement increases as the severity of lameness increases (Donnell et al., 2015; Keegan et al., 2012). Asymmetric vertical movement of the torso as measured by inertial sensor systems is directly associated with measured vertical ground reaction forces, but measurement of vertical torso movement inherently produces more variable data compared to measurement of ground reaction forces by force plate evaluation,

likely due to the higher number of strides evaluated at a single time and movement of the torso unrelated to lameness during the gait examination. Accurate interpretation of kinematic gait analysis data relies on experience with the software, and is more useful when used in conjunction with the eye of a skilled lameness clinician (Donnell et al., 2015).

Both force plate and kinematic gait analysis have limitations when evaluating multiple limb lameness, such as in horses with bilateral caudal heel pain. In cases of bilateral forelimb lameness, each limb is measured individually by the force plate and compared to recognized normal values based on the body weight of the horse. This method can identify abnormal values for each forelimb compared to normal values, but takes a considerable amount of time to achieve useful data and can only be performed on a straight line. An inertial sensor system may be unable to identify a bilateral forelimb lameness in a straight line if the vertical torso movements are equal for each trot stride, although the system can be used to identify asymmetry while the horse is trotting in a circle. In horses with bilateral caudal heel pain, vertical torso movement asymmetry is theoretically decreased on the straight line, resulting in a short and choppy gait instead of obvious asymmetric movement (Keegan et al., 2012). While limitations are evident, the utility of objective lameness measurement will increase as research advances. In the interim, objective lameness evaluation with an inertial sensor system has been shown to increase sensitivity of lameness detection and reduce bias in lameness observation over time or after treatments (Keegan et al., 2013, 2012). Thus, kinematic gait analysis may serve as a valuable adjunct to subjective lameness evaluation and provides objective data when used in a research setting.

2.3.2.3 Diagnostic anesthesia

Perineural or regional nerve blocks and intra-synovial anesthesia techniques are useful for localization of pain during a lameness examination. This increases the significance of imaging findings by specifying a region of focus for diagnostic imaging (Baxter and Stashak, 2011b). However, consistency and specificity of the information gained by regional anesthesia is controversial (Schumacher et al., 2013). Perineural or regional anesthesia is typically employed to localize a region as opposed to the specific site of pain, such as a joint. This method should be used in a systematic manner, starting as distal as possible and moving proximally if adequate improvement in the lameness is not achieved (Mitchell, 2012).

The most distal location for perineural anesthesia on the limb is located axial and distal to the proximal margin of the collateral cartilages of the foot and is commonly referred to as the palmar digital nerve block (Mitchell, 2012; Schumacher et al., 2013). The structures generally desensitized by this nerve block include the sole, most of the coronary band, the PTA and soft tissues of the heel, the distal interphalangeal joint and collateral ligaments of the distal interphalangeal joint, and portions of the distal sesamoidean ligaments (Pilsworth and Dyson, 2015; Schumacher et al., 2013). However, depending on time between administration of the block and observation of lameness, proximal diffusion of the anesthetic solution can occur (Schumacher et al., 2013). In addition, this block may anesthetize or partially anesthetize the proximal interphalangeal joint, the proximal phalanx, and occasionally the metacarpophalangeal joint (Baxter and Stashak, 2011b; Pilsworth and Dyson, 2015; Schumacher et al., 2013). If the palmar digital nerve block does not resolve the lameness, anesthesia of the palmar nerves at the level of the proximal sesamoids (abaxial sesamoid nerve block) effectively anesthetizes the entire digit, including the foot, middle phalanx, the proximal interphalangeal joint, distopalmar aspects of the proximal phalanx, the distal portion of superficial digital flexor tendon and DDFT, the distal sesamoidean ligaments, and the digital annular ligament (Baxter and Stashak, 2011b).

Horses with caudal heel pain often show a marked reduction in lameness severity following anesthesia of the palmar digital nerves (Dabareiner and Carter, 2003; Dyson et al., 2011a; Sampson et al., 2008). In a recent study, approximately 45-55% of horses displayed significant improvement but not complete resolution following a low palmar digital nerve block. A higher proportion of horses in this study (75-90%) required an abaxial palmar nerve block to eliminate the lameness (Parkes et al., 2015). The reason for this could be two-fold: one, caudal heel pain tends to be chronic and/or deep pain resulting in incomplete response to local perineural anesthesia at the most distal level; two, there is a possibility of adhesions being present between the deep digital flexor tendon and the navicular bone which can result in a mechanical abnormality leading to pain referred proximal in the limb and thus an incomplete response to nerve blocks (Parkes et al., 2015). In many horses, the noted lameness may switch to the opposing forelimb following diagnostic anesthesia of the palmar digital nerves of the more severely affected forelimb (Baxter et al., 2011).

Anesthesia of the distal interphalangeal joint and/or the navicular bursa has the potential to further specify the site of pain. It was previously thought that a positive response to distal

interphalangeal joint anesthesia indicated that the source of lameness originated from the joint and not the heel region (Baxter et al., 2011), but it has been demonstrated that this is not true (Schumacher et al., 2001a). Anesthesia of the distal interphalangeal joint not only anesthetizes the distal interphalangeal joint, the navicular bone, and the PTA, but can also provide anesthesia to the sole (Schumacher et al., 2001a). It has been shown that 16-36% of horses with a clinical diagnosis of navicular syndrome improve significantly to anesthesia of the distal interphalangeal joint, and some reports are higher (Baxter et al., 2011; Parkes et al., 2015; Schumacher et al., 2001a). The palmar digital nerves are closely located to the palmar outpouchings of the distal interphalangeal joint and so may be anesthetized simply due to proximity (Schumacher et al., 2001a). Additionally, the distal interphalangeal joint has some degree of communication with the PTA which allows for anesthetic diffusion (Olive and Videau, 2017; Schumacher et al., 2013). Some authors state that anesthesia of the navicular bursa may be the most specific diagnostic anesthesia technique to localize the source of pain in horses with navicular syndrome (Schumacher et al., 2013). However, recent work indicates that a poor response to navicular bursa anesthesia does not rule out the presence of significant pathology of the PTA (Parkes et al., 2015).

2.3.3 Radiographic evaluation

Radiography is typically the initial imaging modality used for lameness diagnosis following localization of the source of pain (Dyson, 2011b). The minimum recommended views to evaluate the navicular bone and associated structures of the forelimbs include: lateromedial, dorso 60° proximal palmarodistal oblique, and palmaro 45° proximal palmarodistal (navicular skyline) oblique views (Dyson, 2011b). Further radiographic views that can provide additional information include a dorsopalmar projection and multiple oblique projections of the digit (Baxter et al., 2011; Dyson, 2011b). Thorough cleaning and preparation of the foot is paramount. This involves removing dirt and debris, paring the frog or sole, removing shoes, trimming the foot if necessary, and packing the sulci and frog with petroleum jelly or modelling dough to eliminate air that can create radiolucent artifacts. When obtaining the radiographs, particular attention must be given to appropriate positioning of the foot, especially for the navicular skyline projection. Improper positioning can artefactually increase the navicular bone medullary opacity (Dyson, 2011b).

Multiple radiographic abnormalities of the navicular bone have been described as part of a diagnosis of caudal heel pain. These include: proximal border enthesophytes, proximal or distal extension of the flexor surface, distal border fragments, enlarged synovial invaginations, new bone at the sagittal ridge, increased cortical thickness of the flexor surface, bi- or tri-partite navicular bone, osseous cyst-like lesions in the medullary cavity, radiolucencies in the flexor cortex, and medullary sclerosis, with the latter three abnormalities being most indicative of navicular bone pathology (Dabareiner and Carter, 2003; Dyson, 2011b). Normal variations that should not be considered to suggest navicular bone pathology or caudal heel pain include a smoothly outlined depression in the sagittal ridge on the lateromedial view and a crescent shaped lucent zone in the sagittal ridge on the navicular skyline view (Dyson, 2011b). Bi- or tri- partite navicular bones are probable congenital abnormalities that may be noted in a sound horse, but tend to cause lameness over time that is associated with degeneration of the navicular bone (van der Zaag et al., 2016). The shape of the proximal articular border of the navicular bone on radiographs has been shown to be genetically determined in Dutch Warmbloods (Bos et al., 1986). Horses with a concave proximal articular border of the navicular bone on the dorso 60° proximal palmarodistal oblique view may be more susceptible to the development of navicular syndrome (Dik et al., 2001a). It is important to note that a radiographically normal navicular bone does not rule out navicular bone pathology, highlighting the importance of advanced diagnostic imaging (Dyson et al., 2011a; Sampson et al., 2009). Some horses never develop any radiographic evidence of disease but still display clinical lameness and have MRI findings consistent with caudal heel pain, including osseous abnormalities (Dabareiner and Carter, 2003; Dyson et al., 2011a).

A grading system has been developed and revised to improve objectivity when assessing the navicular bone with radiographs (Biggi and Dyson, 2012, 2010; Dyson, 2008; Parkes et al., 2015). The grade ranges from 0-3, with 0 being clinically normal and 3 representing significant navicular bone pathology evident on radiographs. The radiologic grade can underestimate the severity of pathology within the navicular bone and other structures of the PTA (Dyson, 2008). Significant correlations have been determined between the overall radiologic grade and MRI grade of the navicular bone (Biggi and Dyson, 2010).

2.3.4 Ultrasound evaluation

Ultrasound has been used in a limited capacity to evaluate the palmar soft tissue structures of the distal pastern and the PTA (Bolen et al., 2007; Busoni and Denoix, 2001; Dabareiner and Carter, 2003). Imaging is performed percutaneously through the palmar pastern and the frog of the hoof. This imaging technique can provide information regarding the distal DDFT and the digital cushion, as well as the flexor cortex of the navicular bone and portions of the DSIL and CSL (Bolen et al., 2007; Busoni and Denoix, 2001). Considerable preparation is required to obtain adequate images, and the foot size and frog conformation of the horse determines the beam angle and area of imaging (Busoni and Denoix, 2001). The accuracy and utility of this imaging modality for the heel region has been questioned due to the advent of more advanced imaging techniques (Baxter et al., 2011).

2.3.5 Magnetic resonance imaging

Magnetic resonance imaging is the preferred diagnostic imaging modality for the soft tissues of the equine foot, particularly in cases that do not have any apparent radiographic changes (Dyson et al., 2011a; Werpy, 2012). When directly compared to computed tomography (CT), MRI does not show the same degree of osseous detail but is capable of identifying the same bone lesions with greater soft tissue detail (Werpy, 2012; Widmer et al., 2000). Use of MRI in cases of caudal heel pain has allowed the identification of soft tissue lesions in the PTA, especially when performed early in clinical manifestation and prior to any obvious radiographic changes (Dyson et al., 2012, 2011a; Dyson and Murray, 2007a; Sampson et al., 2009). Both low-field and high-field MRI is available, though not often at the same facility. Standing low-field MRI is advantageous in that it does not require general anesthesia for the horse, but may be inferior to high-field MRI for the diagnosis of small lesions (Werpy, 2007). However, low-field MRI can still accurately diagnose many injuries in horses (Gutierrez-Nibeyro et al., 2012; Werpy, 2007).

Using MRI, many abnormalities have been identified in the PTA of horses affected with caudal heel pain. Combinations of injuries within a single affected foot are a common finding (Dyson et al., 2012, 2011a; Dyson and Murray, 2007a; Sampson et al., 2009). A variety of lesions have been described, as stated earlier in section 2.2.3. Abnormal medullary signal intensity within the navicular bone noted on fat-suppressed MRI sequences was the most frequent

observation in one study, which indicates possible inflammation, hemorrhage, synovial fluid, bone necrosis, or fibrosis, all of which are indiscernible on MRI (Sampson et al., 2009). However, navicular bone pathology in the absence of pathology of the other structures of the PTA is rare, and lesions of the navicular bone have been observed in conjunction with pathology of the DDFT, CSL, DSIL, the navicular bursa, the distal interphalangeal joint, and the collateral ligaments of the distal interphalangeal joint (Baxter et al., 2011; Dyson et al., 2012; Dyson and Murray, 2007a; Parkes et al., 2015).

The frequency and type of soft tissue pathology noted on MRI varies; deep digital flexor tendinopathy is common with incidence ranging from 44-86% of feet examined (Dyson and Murray, 2007a; Sampson et al., 2009). Multiple lesions have been noted in the DDFT, with dorsal fibrillation, parasagittal splits, core lesions, insertional lesions, and combinations of lesions most commonly reported (Dyson et al., 2011a, 2003; Dyson and Murray, 2007a; Lutter et al., 2015). Due to the amount of detail available from MRI, there is some difficulty in determining which abnormality is the primary source of pain in the foot when multiple injuries are found. In addition, abnormalities of the PTA have been identified in a moderate percentage (27%) of non-lame limbs on MRI (Murray et al., 2006b). These findings could indicate anatomical variation, adaptation to biomechanical forces, repair of previous injuries, or early subclinical changes that could predispose horses to future lameness. Histopathologic findings correlate with the majority of lesions identified on MRI, validating this imaging modality as a diagnostic procedure for horses affected with foot pain (Dyson et al., 2012; Murray et al., 2006a). A grading system has been developed for MRI of the foot based on signal intensity and presence of abnormalities in comparison to normal (non-lame) feet and histopathological studies (Biggi and Dyson, 2011; Murray et al., 2006a, 2006b).

2.3.6 Computed tomography

Computed tomography (CT) provides good spatial resolution of the equine foot and is the best imaging modality to evaluate osseous pathology (Widmer et al., 2000). This imaging modality removes superimposition, allowing evaluation of small abnormalities, especially the presence and size of navicular bone distal border fragments (Groth et al., 2009; Widmer et al., 2000). Some soft tissue abnormalities in the foot can be detected using CT; intra-arterial contrast can improve imaging of soft tissues, but the quality of soft tissue imaging achieved using these

methods is still surpassed by MRI. In addition, the need for general anesthesia and limited access to CT decreases the usefulness of this modality (Baxter et al., 2011).

2.3.7 Nuclear scintigraphy

Nuclear scintigraphy provides information about the metabolic activity within tissues based on the uptake of a radiopharmaceutical substance (Dyson, 2002; Dyson and Murray, 2007b). Increased radiopharmaceutical uptake is reflective of abnormal osteoblastic activity within a bone, which can represent either adaptive or pathologic responses of that bone to external forces (Dyson and Murray, 2007c). Increased osteoblastic activity is not present in all cases of navicular bone pathology or caudal heel pain (Dyson et al., 2012; Dyson and Murray, 2007c). If necrosis of the bone is the primary pathogenesis, only increased osteoclastic activity will occur which could result in normal radiopharmaceutical uptake on scintigraphic examination despite lesions consistent with navicular syndrome (Dyson and Murray, 2007c). Additionally, horses with a low heel conformation but no lesions consistent with navicular syndrome can have increased radiopharmaceutical uptake in the navicular bone or at the insertion of the DDFT, possibly due to low heel conformation increasing compressive forces exerted by the DDFT (Dyson, 2002; Eliashar et al., 2004). Therefore, scintigraphy may be a useful adjunct imaging modality in cases of caudal heel pain, but has low sensitivity and specificity compared to MRI (Baxter et al., 2011).

2.3.8 Bursography and navicular bursoscopy

Navicular bursography and bursoscopy are less commonly used to diagnose caudal heel pain (Baxter et al., 2011; Dabareiner and Carter, 2003). Positive contrast radiography of the navicular bursa can highlight the navicular bone flexor surface, possibly displaying any fibrocartilage change and abnormalities of the dorsal surface of the DDFT, and has been shown to be superior to plain radiography for finding flexor surface pathology (Turner, 1998). However, this technique is used infrequently due to the increasing availability of MRI (Baxter et al., 2011). Endoscopy of the navicular bursa (bursoscopy) is more frequently used in cases of suspected septic bursitis, but can be employed as both a diagnostic and therapeutic option to evaluate the flexor surface of the navicular bone, the navicular bursa, CSL, and the dorsal aspect of the DDFT (Mählmann et al., 2015; Smith and Wright, 2012). Bursoscopy requires general anesthesia, but

may be better at identifying fibrocartilage defects on the flexor surface of the navicular bone and adhesions when compared to MRI (Mählmann et al., 2015). In this way, navicular bursoscopy may provide a more complete diagnostic picture for caudal heel pain when combined with advanced imaging techniques.

2.3.9 Histopathology

Gross pathology and histopathology are not useful in the ante mortem diagnosis of caudal heel pain in horses. However, the correlation of diagnostic imaging to pathologic findings supports the use of MRI as a gold standard diagnostic modality for injuries within the foot (Dyson et al., 2012; Murray et al., 2006a). Gross post mortem abnormalities of the navicular bone are likely to be present in cases of advanced caudal heel pain. These include: full thickness fibrocartilage defects on the flexor surface, erosion of the flexor cortex of the navicular bone, lysis of the navicular bone medulla, fibrillation of the dorsal aspect of the DDFT, parasagittal splits or core lesions within the DDFT, and adhesions between the DDFT and the navicular bone (Wright et al., 1998). Gross post mortem evaluation of early caudal heel pain may only show mild degrees of the aforementioned abnormalities (Blunden et al., 2006a, 2006b). The reader is referred to section 2.2.3 for further information regarding histopathologic findings supporting a diagnosis of caudal heel pain.

2.4 Treatment of caudal heel pain

Many treatment options have been described for caudal heel pain, but most give inconsistent results for both alleviating lameness and reversing disease changes. There is no single treatment with excellent efficacy, and often a combination of treatments is required to target the presumed or identified lesions (Bell et al., 2009; Dyson et al., 2005; Gutierrez-Nibeyro et al., 2010; Whitfield et al., 2016). Individual horse factors must be considered, such as the intended use of the horse, expectations of the owner, lameness severity, results of diagnostic procedures or lack thereof, previous treatments performed, and hoof conformation (Baxter et al., 2011; Dabareiner and Carter, 2003). The use of MRI in the diagnostic process allows for the planning of a more specific treatment plan for the individual horse. Typically, treatments are combined to produce a management strategy based on the results of diagnostic imaging. The most common treatment combinations include therapeutic trimming or shoeing coupled with

systemic and/or intra-synovial anti-inflammatory medication and a variable period of rest and rehabilitation (Dabareiner and Carter, 2003). Other approaches may include vasoactive medications, bone-modulating medications (bisphosphonates), physical therapies such as extracorporeal shock wave therapy (ESWT), alternative therapies such as acupuncture, and palliative surgical procedures such as a palmar digital neurectomy (Baxter et al., 2011; Dabareiner and Carter, 2003; Rijkenhuizen, 2006).

2.4.1 Therapeutic trimming and shoes

Corrective trimming, with or without shoes, should be the first line of treatment in all cases of caudal heel pain. Many trimming or shoeing practices have been described, but the correction of any hoof imbalance should be the first objective (Rijkenhuizen, 2006; Schoonover et al., 2005). Once the foot is balanced, additional methods commonly employed involve raising the palmar angle of the distal phalanx by increasing heel mass or elevating the heel (Eliashar et al., 2004; Schoonover et al., 2005), but providing heel support without elevation may also alleviate lameness (Schoonover et al., 2005). The palmar angle of the distal phalanx is defined as the angle made by the palmar border of the bone and the surface of the ground. It is known that a low palmar angle (less than 2-3°) causes increased extension of the distal interphalangeal joint (Eggleston, 2012; Eliashar et al., 2004; Redden, 2003) and that decreasing the palmar angle by one degree results in a twenty percent increase in the peak compressive force the navicular bone experiences (Eliashar et al., 2004). Conversely, increasing the palmar angle and improving heel support reduces the force exerted on the navicular bone by the DDFT during distal interphalangeal joint extension due to increasing the area of load distribution under the heel. However, this result depends on the type of shoe used and is not noted in healthy horses, nor in all affected horses (Eliashar, 2007; Willemen et al., 1999). Raising the palmar angle can be achieved through various techniques including careful trimming over time, various wedge pads, or different types of wedge shoes.

Techniques to provide more heel support include the use of a bar shoe, onion shoe, or a shoe fit full in the quarters to give more caudal support (Schoonover et al., 2005). In addition to increasing heel height, other methods often employed for horses with caudal heel pain include easing the breakover of the foot by decreasing toe length and/or using a rolled toe or rockered toe shoe (Eliashar et al., 2002). The breakover of the foot is defined as the period of rotation of the

heels around the point of the toe as the foot leaves the ground (Eliashar et al., 2002). Reducing the length of the toe can decrease the rotation period and create more gradual hoof movement, but has not been shown to reduce force on the navicular bone (Eliashar, 2007; Eliashar et al., 2002).

Regardless of method used, it is important to have good quality radiographs to guide corrective trimming and shoeing, as the degree of heel collapse noted externally does not correlate with the palmar angle of the distal phalanx (Dyson et al., 2011b). Case management should also include regular farrier work every four to eight weeks, and the willingness to use many different techniques, as not every horse will find relief from the same type of shoe (Dabareiner and Carter, 2003; Moleman et al., 2006). Additionally, extended shoeing intervals can increase the tension on the DDFT and the compressive force on the navicular bone by increasing extension of the distal interphalangeal joint (Cillán-García et al., 2013; Moleman et al., 2006). Horses with good foot conformation and acceptable farrier management at the time of diagnosis may not show much improvement after therapeutic shoeing. In horses that have not had regular hoof care, proper trimming by itself may provide correct hoof balance such that shoes or pads are unnecessary to achieve optimal hoof conformation and clinical improvement. Some horses with permanent structural damage such as navicular bone flexor surface erosions may not improve significantly with therapeutic farrier work (Dabareiner and Carter, 2003).

2.4.2 Systemic anti-inflammatories

Systemic non-steroidal anti-inflammatory medications are frequently used to manage horses with caudal heel pain (Rijkenhuizen, 2006). Phenylbutazone, flunixin meglumine, and firocoxib are the most commonly used medications and all options provide effective pain relief and reduction of inflammation through inhibition of prostaglandin (Baxter et al., 2011; Dabareiner and Carter, 2003; Moses and Bertone, 2002). Both phenylbutazone and flunixin have been shown to have good success for reduction of lameness in cases of caudal heel pain (Erkert et al., 2005), and firocoxib has been validated for relief of chronic lameness caused by caudal heel pain (Back et al., 2009). It is questionable if these medications target the disease process associated with caudal heel pain, because there is minimal evidence of inflammation in the affected structures, especially in cases of advanced disease (Gutierrez-Nibeyro et al., 2010). There are risks associated with the use of these medications, and although rare, administration of

systemic non-steroidal anti-inflammatory medications has been linked to right dorsal colitis, acute renal failure, and gastric ulceration (Moses and Bertone, 2002).

2.4.3 Intra-synovial injections and medications

Intra-synovial medication of either the distal interphalangeal joint, the navicular bursa, or both in combination is commonly employed for management of caudal heel pain (Baxter et al., 2011). Medications used for intra-synovial injections include: corticosteroids such as triamcinolone acetonide or methylprednisolone acetate, sodium hyaluronate, corticosteroids combined with hyaluronate, or polysulfated glycosaminoglycans (Ferris et al., 2011). Corticosteroids reduce pain and effusion associated with synovitis and induced osteoarthritis in the horse due to their potent anti-inflammatory effects (Frisbie et al., 1997). In addition, they decrease the expression of pro-inflammatory molecules in cartilage and synovial membranes (de Grauw et al., 2016). However, some corticosteroids are detrimental to articular cartilage morphology and composition, especially methylprednisolone acetate (de Grauw et al., 2016; McIlwraith, 2010). Sodium hyaluronate has been shown to decrease lameness and provide anti-inflammatory effects when injected into a diseased joint, possibly by reducing friction, cartilage fibrillation and synovial prostaglandin release (de Grauw et al., 2016). Until recently, it was thought that the use of corticosteroids and sodium hyaluronate in combination was more beneficial to treat joint disease than simply using corticosteroids and may mitigate the negative side effects of corticosteroids (de Grauw et al., 2016; Schoonover et al., 2005). However, the use of this medication may be equivocal since de Grauw et al. (2016) demonstrated that the combined use of sodium hyaluronate and triamcinolone does not improve short term lameness outcomes in horses with osteoarthritis.

Anatomical knowledge suggests that medication of the distal interphalangeal joint should provide some relief to the structures of the PTA, but the clinical response in individual horses can be inconsistent and disappointing (Schoonover et al., 2005). The distal interphalangeal joint was medicated in 56 horses and required repeat injection due to lack of response in 23 horses; however, repeated injections did not significantly affect the outcome (Gutierrez-Nibeyro et al., 2010).

Medication of the navicular bursa with corticosteroids to treat caudal heel pain has been described in several reports, with 60-80% of treated horses quickly returning to their intended use

for variable periods of time (Bell et al., 2009; Dabareiner et al., 2003; Marsh et al., 2012; Verschooten et al., 1990). Medications used include triamcinolone acetate, methylprednisolone acetate, sodium hyaluronate, and amikacin, all at varying doses determined by clinician preference. Both Marsh et al. (2012) and Bell et al. (2009) found that MRI diagnosis influenced response to treatment, with navicular bone flexor surface defects or the presence of multiple concurrent abnormalities resulting in significantly worse outcomes than other lesion groups. Mean duration of lameness resolution ranged from 4.6 to 9.6 months following navicular bursa injection, although some horses only improved for 2-3 months (Bell et al., 2009; Dabareiner et al., 2003; Marsh et al., 2012). Medication of the navicular bursa presents more possible adverse effects than just those expected for synoviocentesis. Synovial sepsis and the risks associated with using corticosteroids cannot be ignored, but all described palmar approaches to the navicular bursa involve penetration of the DDFT. While there is no evidence indicating that injection of the bursa will directly cause rupture of the DDFT, it has been reported as an unfortunate outcome by one group and is a catastrophic risk so warrants careful consideration (Dabareiner et al., 2003). Other approaches have since been developed to avoid penetration of the DDFT (Daniel et al., 2016). In addition, the use of corticosteroids concurrently with soft tissue injuries such as those often diagnosed by MRI may inhibit the inflammatory response and therefore healing of those structures (Dowling et al., 2000).

2.4.4 Rest

Long periods of rest are typically not recommended nor successful for horses with caudal heel pain due to the progressive, degenerative nature of the disease. However, a short duration of rest with a gradual return to work may help to decrease soft tissue inflammation that may be present (Dabareiner and Carter, 2003). Proper adherence to a prescribed rest and rehabilitation protocol was an important factor for an improved outcome in 56 horses evaluated with MRI. This protocol involved a 4 to 8 week period of stall rest followed by a 4 to 8 week period of controlled exercise with a gradual return to the previous level of activity (Gutierrez-Nibeyro et al., 2010).

2.4.5 Bisphosphonates

Bisphosphonates are a class of drug that are potent bone resorption inhibitors (Whitfield et al., 2016). Drugs used clinically in horses in this class include tiludronate and clodronate;

pamidronate and zoledronate have been investigated in a research setting (McLellan, 2017). These drugs bind to calcium and other divalent metal ions within the bloodstream, but also to bone mineral in areas of active osseous remodeling. Bisphosphonates act directly on osteoclasts and cause decreased cell recruitment, activity and lifespan, effectively inhibiting or reducing bone resorption (McLellan, 2017; Whitfield et al., 2016). Bisphosphonates have also been shown to have anti-inflammatory properties in non-equine species through inhibition of monocytic cytokine and nitric oxide secretion (Whitfield et al., 2016). Bone remodeling and excessive resorption is often a characteristic of caudal heel pain, likely due to increased mechanical load on the navicular bone (Dyson et al., 2011a). It is known that the bone resorption rate is increased in relation to bone formation in a diseased navicular bone compared to a normal bone (Denoix et al., 2003).

Tiludronate sodium has been shown to cause a reduction in lameness grade in horses diagnosed with caudal heel pain when administered systemically at a single intravenous dose of 1.0 mg/kg (Denoix et al., 2003; Whitfield et al., 2016). This reduction of lameness is primarily noted in horses with clinical signs of less than six months duration (Denoix et al., 2003). Only radiography has been used to determine effects of tiludronate on navicular bone pathology, and no radiographically evident effects have been noted, with reports suggesting that radiography is not a sensitive enough modality to detect the possible slight changes in bone density following administration of tiludronate to horses (Denoix et al., 2003; Whitfield et al., 2016). Therefore, the evidence only supports the use of tiludronate as a treatment to manage clinical signs associated with caudal heel pain. Clodronate is approved for use in horses to mitigate clinical signs associated with caudal heel pain. The research performed for drug approval describes mild improvement in lameness six weeks after administration of clodronate to horses diagnosed with caudal heel pain, but loss of this improvement six months following treatment (Frevel et al., 2014). There is the potential for significant side effects with bisphosphonate use in horses, some of which are suspected but as of yet unknown due to a lack of long-term safety information. Both colic symptoms and abnormalities in renal parameters have been associated with the use of tiludronate and clodronate (Soto and Chiappe, 2014). Additionally, bisphosphonates may inhibit bone microcrack healing and reduce healing of stress fractures, and have been linked to osteopetrosis and mandibular necrosis in people (McLellan, 2017).

2.4.6 Isoxsuprine

Isoxsuprine is a beta-adrenergic agonist with vasodilatory properties that has been used systemically via oral administration for the management of caudal heel pain. The mechanism of action is unknown, oral bioavailability is poor, and no measurable cardiovascular effects are present at twice the recommended dose for horses (Erkert and MacAllister, 2002). Additionally, isoxsuprine does not increase blood flow to the foot or dorsal laminae of horses (Ingle-Fehr and Baxter, 1999). Regardless, horses affected by caudal heel pain and treated with isoxsuprine show some improvement in lameness compared to placebo, although the results are better in horses that have had clinical signs for less than one year (Erkert and MacAllister, 2002). No adverse side effects are reported, even with long term continuous use of the medication (Baxter et al., 2011). Clinical use of the drug has decreased in recent years, likely due to the lack of supporting evidence for the theory of vascular compromise as the etiopathogenesis of caudal heel pain (Erkert and MacAllister, 2002).

2.4.7 Surgical treatments

Surgical treatments for caudal heel pain include navicular bursoscopy, navicular suspensory ligament desmotomy, and palmar digital neurectomy. Endoscopy of the navicular bursa can be used for both diagnosis and treatment. Horses that have navicular bone flexor surface abnormalities and dorsal fibrillation of the DDFT at the level of the navicular bone are particularly indicated to undergo this treatment, as bursoscopy provides the opportunity for lesion debridement and the removal of possible adhesions (Baxter et al., 2011). Smith and Wright (2012) reported that 61% of horses returned to some degree of work with improvement in lameness following navicular bursoscopy, but that horses with combination injuries of the navicular bone and DDFT were less likely to have a successful outcome. The surgery is technically difficult, requires general anesthesia, and there is potential for iatrogenic damage to the structures surrounding the bursa (Mählmann et al., 2015).

Desmotomy of the navicular suspensory ligament involves transection of the collateral sesamoidean ligaments, preferably via an arthroscopic approach through the palmar aspect of the distal interphalangeal joint (Sampson et al., 2010). This treatment is possibly indicated if a lesion within the collateral sesamoidean ligaments is identified on MRI (Baxter et al., 2011). An open approach was historically performed and resulted in short term improvement in lameness, but has

fallen out of favour as a treatment option due to the inability to transect the multiple attachment sites of the CSL (Sampson et al., 2010).

Palmar digital neurectomy, while considered a salvage procedure in most instances, is still commonly performed for the management of lameness associated with caudal heel pain (Baxter et al., 2011). The sensory nerves supplying the heel region are partially removed, resulting in desensitization of the foot and alleviation of pain (Maher et al., 2008). A palmar digital neurectomy is an accepted palliative treatment option for horses with caudal heel pain if they are unresponsive to other treatments (Gutierrez-Nibeyro et al., 2015). It is advised to perform a palmar digital nerve block prior to surgery to determine the amount of lameness improvement that can be expected. It is suspected that horses with lesions of the DDFT at the level of the navicular bone are poor candidates for neurectomy due to an increased risk of tendon rupture following the surgery (Baxter et al., 2011). However, there is no peer-reviewed evidence to confirm this suspicion. Palmar digital neurectomy can effectively reduce or resolve lameness associated with caudal heel pain in 74-92% horses for at least one year following surgery (Gutierrez-Nibeyro et al., 2015; Jackman et al., 1993; Maher et al., 2008). Horses with core lesions or parasagittal splits in the DDFT may have a decreased prognosis associated with residual or early recurring lameness (Gutierrez-Nibeyro et al., 2015). Complications following palmar digital neurectomy include: incomplete resolution of lameness, recurrence of lameness associated with caudal heel pain due to nerve regrowth, development of a painful neuroma, sepsis of the distal phalanx, rupture of the DDFT, luxation of the distal interphalangeal joint, sloughing of the hoof capsule, navicular bone fracture and unnoticed severe infection within the foot (Baxter et al., 2011; Maher et al., 2008).

2.4.8 Acupuncture

Acupuncture is a non-invasive, non-pharmaceutical modality that may reduce pain and lameness in horses (Robinson and Manning, 2015). Acupuncture has been shown to modulate endorphin release at the level of the spinal cord, and as such, may reduce levels of chronic pain in horses (Dunkel et al., 2017). However, multiple studies have failed to prove the usefulness of this modality for horses with chronic lameness caused by caudal heel pain (Robinson and Manning, 2015; Schoonover et al., 2005; Steiss et al., 1989).

2.4.9 Experimental treatments

Several experimental treatment options have been examined for use in horses with caudal heel pain. One group evaluated the response to intra-bursal injection of botulinum toxin type B in horses affected with caudal heel pain and found a decrease in lameness at 7 or 14 days after injection, although no horses became sound during the study period (Gutierrez-Nibeyro et al., 2014). A study performed in healthy horses investigated surgical core decompression of the navicular bone, and found that following drilling, intraosseous pressure was reduced in the navicular bone, and osseous remodeling and neovascularization was present adjacent to the surgical sites (Jenner and Kirker-Head, 2011). This may represent a promising treatment option, if similar results can be demonstrated in diseased horses.

2.5 Shock Wave Therapy

Extracorporeal shock wave therapy was initially developed for dissolution of urinary calculi in humans (Chung and Wiley, 2002). Osseous remodeling was noted in the pelvis of humans following treatment of the ureter for urolith dissolution (Graff et al., 1987). The therapy was then explored as a treatment for musculoskeletal disorders in humans such as non-union fractures and insertional desmopathies, and positive results stimulated the use of this therapy in other species (McClure and Dorfmueller, 2003).

It is suspected that ESWT is used with relative frequency in equine practice, although true prevalence of treatment use has not been determined. Anecdotally, the therapy is widely used to treat tendon and ligament injuries, epaxial muscle pain, dorsal metacarpal disease, osteoarthritis, wounds, and caudal heel pain.

2.5.1 Physics and types

Shock waves are generated by a sudden release of energy, creating a pressure wave that can propagate rapidly through body tissues (Chung and Wiley, 2002). A quick rising positive pressure wave is followed by a longer decrease to normal pressure and a negative pressure wave. The pressure difference causes tensile stress and can create cavitations within the tissue (McClure and Dorfmueller, 2003). The greatest release of energy at the tissue level occurs when the density of two tissues is different, such as at a bone-tendon interface (Leeman et al., 2016).

Shock waves require a fluid medium or tissue through which to propagate, and are reflected by air-containing surfaces such as the pleural or intestinal surface (McClure and Dorfmueller, 2003). The energy contained in a shock wave is measured in millijoules (mJ). The energy supplied to the target tissue can vary. Energy flux density (EFD) is a good way to describe the dose of energy applied to a focal point within tissue. This is the amount of energy applied in millijoules to one square millimetre (mJ/mm^2) (McClure and Dorfmueller, 2003). Research typically uses EFD to describe dose used. In human and laboratory animal research, high EFD is more than $0.6 \text{ mJ}/\text{mm}^2$, medium EFD between 0.08 and $0.28 \text{ mJ}/\text{mm}^2$, and low EFD is less than $0.08 \text{ mJ}/\text{mm}^2$ (Rompe et al., 1998). This is important to consider when evaluating research on ESWT, as a dose-dependent effect has been noted in some tissues and species (F. S. Wang et al., 2002).

Shock waves are generated by one of four methods: electrohydraulic, electromagnetic, piezoelectric, and pneumatic/ballistic (McClure and Dorfmueller, 2003). The first three methods produce a very focused shock wave by converting electricity into rapid physical movement. These shock waves converge on a small focus point, do not expose the surrounding non-target tissues to the therapy, and are able to penetrate tissue to a deeper point. Only the ballistic method produces non-focused (or radial) shock waves, which are generated by a projectile moving at high speeds. Radial shock waves concuss all tissues, including surrounding non-target tissues, uniformly and are not as penetrating as focused shock waves (Chung and Wiley, 2002).

2.5.2 Proposed mechanisms of action

Within tissues, shock waves undergo absorption, refraction, reflection and transmission of the energy (Ogden et al., 2001). In many body tissues, the tensile stress created by the shock wave can cause cell displacement without heating, can transiently alter cell membrane permeability and stimulate cytoplasmic organelles and the nucleus (Chung and Wiley, 2002; Romeo et al., 2013). This may result in nitric oxide and growth factor production, resulting in activation of further biologic processes, depending on the type of cell stimulated (Romeo et al., 2013; C. J. Wang et al., 2002; Wang et al., 2009). Nitric oxide can have an anti-inflammatory effect, which may contribute to pain reduction (van den Boom et al., 2005). However, ESWT may stimulate local inflammation in the treated tissues as well. Wang et al. (2002) determined that high-energy ESWT caused hemorrhage and inflammation when the femoral artery and nerve

were treated in dogs. The pattern and timeline of anti-inflammatory and inflammatory effects has not yet been completely determined through research. There may also be a dose-dependent effect on tissue response (Rompe et al., 1998; F. S. Wang et al., 2002), and it is possible that different tissue structures and types respond to the therapy in a different way. Structural alignment of tissues such as collagen may be reversibly disrupted (Cárcamo et al., 2012) and in this way, focused ESWT may improve healing of osseous and soft tissue structures (F. S. Wang et al., 2002). Mechanisms of action that may support improved healing at the tissue level include induction of neovascularization (Kersh et al., 2006; C. J. Wang et al., 2002), increased expression of growth factors such as transforming growth factor-beta-1 (TGF- β 1) (Caminoto et al., 2005), and increased cellular metabolism, glycosaminoglycan levels and protein synthesis (Bosch et al., 2007).

2.5.3 Effects on tissues

2.5.3.1 Effects on osseous tissues

The effects of ESWT on osseous tissues in horses and other species have been investigated at the cellular and macroscopic levels. Low energy ESWT induced a cyto-stimulatory response in human osteoprogenitor cell lines through increased production of nitric oxide, osteocalcin and TGF- β 1 (Martini et al., 2003). Induction of TGF- β 1 production was also noted in association with an enhanced formation of bone nodules in an in vitro study in rats (F. S. Wang et al., 2002). The osteogenic effect of ESWT may be dose dependent. In rabbits, a higher dose of shock waves applied to bone caused fractures and aseptic necrosis, but a lower dose stimulated osteogenesis with minimal cell damage (Haupt, 1997).

In horses, an increase in TGF- β 1 has not been investigated in osseous tissues following ESWT, although this effect has been noted in experimentally induced suspensory ligament desmitis treated with ESWT (Caminoto et al., 2005). Results in equine bone are somewhat contradictory, and it is suspected that ESWT induces osseous remodeling due to the formation of microcracks. One group has demonstrated osteogenic stimulation and an endosteal response following ESWT applied to the third metacarpus/metatarsus (McClure et al., 2004b). Another group determined that focused ESWT increased microfracture density in cortical bone, but ballistic/radial ESWT increased microfracture length (Da Costa Gómez et al., 2004). Yet another

study found that neither method of ESWT application caused microcracking in cortical bone (Pauwels et al., 2004). Histologic investigation following treatment of the proximal suspensory region (bone-ligament interface) in horses revealed no microfractures but increased density of osteoblasts in treated regions compared to control limbs (Bischofberger et al., 2006). These varied results may be due to a lack of consistency in treatment protocol or type of ESWT used, and in vivo versus in vitro studies.

Clinical studies in humans have shown a benefit of ESWT for delayed union and non-union fractures (Schaden et al., 2001). It is unknown if ESWT truly has a regenerative effect in horses, or what is an ideal treatment protocol for specific conditions. Ballistic/radial ESWT has been found to be an effective adjunctive treatment for dorsal metacarpal disease (stress fractures) that allows Thoroughbred horses to return to speed work and racing sooner than other treatment modalities, however, this was investigated without the use of a control group (Palmer, 2002). To the author's knowledge, no further research into the osseous effects of ESWT in horses have been published.

2.5.3.2 Effects on tendons and ligaments

Effects of ESWT on equine tendons and ligaments have been investigated in multiple research studies. When applied to normal equine tendons, focused ESWT has been shown to cause disorganization of tendon structure (Bosch et al., 2009). Disruption of tissue structure may stimulate healing in cases of injury, but caution should be exercised to avoid targeting normal tissues. The response of experimentally induced lesions to ESWT has been evaluated. Caminoto et al. (2005) determined that expression of TGF- β 1 is increased following ESWT applied to collagen-induced suspensory ligament desmitis. Additionally, treated limbs had an increased number of small, newly formed collagen fibrils and increased numbers of mitochondria present compared to control limbs, indicating an increased rate of tissue repair. A similar study showed an increased rate of ultrasonographically apparent healing in treated suspensory ligaments versus controls (McClure et al., 2004c). Increased neovascularization was noted on histology following treatment with ESWT in collagen-induced superficial digital flexor tendon lesions, when compared to control limbs (Kersh et al., 2006). Contrarily, collagen induced lesions of the accessory ligament of the deep digital flexor tendon did not respond favourably to treatment with ESWT, and no significant differences were found in lesion size, echogenicity, or fiber pattern on

ultrasound examination, nor on histological examination between treatment and control groups (Waguespack et al., 2011).

Shock wave therapy may decrease lameness and improve outcomes in horses with naturally occurring tendinopathy and desmopathy. Crowe et al. (2004) evaluated the effects of radial/ballistic ESWT on horses with suspensory ligament desmitis, and found that more horses were able to return to work when compared to previous retrospective studies evaluating controlled exercise alone. Further work is required to determine the effects of focused ESWT on naturally occurring tendon and ligament injuries.

2.5.3.3 Effects on joints and synovial structures

ESWT has been investigated as a treatment modality for osteoarthritis. Seventy-four horses with naturally occurring tarsal osteoarthritis were treated with ESWT resulting in an 80% improvement in lameness 90 days after treatment, although no change was noted on post-treatment radiographs, and control horses were not used in the study (McCarroll and McClure, 2000). Frisbie et al. (2009) determined that focused ESWT improved lameness scores when compared to controls in an experimental carpal osteoarthritis model, but could not identify any disease-modifying effects in synovial fluid, membranes, or cartilage. Kawcak et al. (2011) further evaluated the effect of ESWT on subchondral bone and serum biomarkers in the same carpal osteoarthritis model. No change was noted in subchondral bone, but serum osteocalcin concentration increased in treated horses, indicating induction of bone remodeling. In a knee osteoarthritis model in rats, ESWT application to the medial tibial condyle resulted in a regression of osteoarthritis radiographically and histologically, as well as an improvement in bone strength in comparison to the control group (Wang et al., 2013). A clinical trial performed in humans demonstrated that ESWT using an EFD of 0.093 mJ/mm² resulted in significantly greater improvement in pain scores and functional outcomes when compared to patients receiving ESWT at a lower EFD of 0.040 mJ/mm² (Kim et al., 2015).

2.5.3.4 Analgesic effects

Focused ESWT has been shown to cause analgesia in equine musculoskeletal tissues (Dahlberg et al., 2006; Frisbie et al., 2009; McCarroll and McClure, 2000; Palmer, 2002), but the mechanism of action is somewhat undetermined. Sensory nerve conduction velocity in the

palmar digital nerves of equine forelimbs was shown to be decreased following treatment with radial/ballistic ESWT due to disruption of the myelin sheath in medium to large diameter myelinated axons (Bolt et al., 2004b). However, a study performed in horses has established no analgesia of the sensory region after treating the palmar digital nerve with focused ESWT (McClure et al., 2005). In the same study, a short-lived local cutaneous analgesic effect was identified, unrelated to the sensory region supplied by the nerve. This group established that perineural inflammation occurred after treatment using histology, but nerve integrity and neuropeptide concentrations did not change. High energy shock waves applied to the femoral nerve of dogs caused nerve fiber swelling and damage to the perineural tissues, although no evidence of nerve bundle disruption or change in cellular distribution within the nerve was noted (C. J. Wang et al., 2002). Damage to the nerve does not equate to an analgesic effect, and this canine study did not evaluate nociception. Abed et al. (2007) found that neither focused nor radial/ballistic ESWT depleted the neuropeptides substance P or calcitonin gene-related peptide in the skin or periosteum of sheep. Additionally, when low-energy ESWT was applied to the spinal cord of rats, the expression of substance P and calcitonin gene-related peptide did not change, indicating that ESWT likely does not stimulate the endogenous pain control system through hyperstimulation (Haake et al., 2002). The anti-nociceptive or analgesic effect of ESWT remains speculative.

2.5.4 Use and efficacy for caudal heel pain

A definitive but transient analgesic effect was noted by Dahlberg et al. (2006) when focused ESWT was used to treat horses with caudal heel pain, and McClure et al. (2004a) identified an analgesic effect in 81% of horses with caudal heel pain six months following treatment with focused ESWT. A similar analgesic effect resulting in a reduction in lameness has been identified by Blum (2004) and Bår et al. (2001). However, all of these studies were performed without control groups or blinding of the investigators, and an effect of the therapy was not noted radiographically (McClure et al., 2004a). MRI was not used for diagnosis or monitoring in any of these studies. Radial ESWT has not been shown to provide analgesia nor have any effect on nuclear scintigraphy results for horses with navicular syndrome (Brown et al., 2005; Byron et al., 2009). To the author's knowledge, disease modifying effects of ESWT have not been identified for caudal heel pain in horses.

2.5.5 Adverse effects

Adverse effects of ESWT depend on the tissues targeted and the energy dosage used. Subperiosteal and endosteal hemorrhage has been identified in equine bone (McClure et al., 2004b). At high energy levels, cell death may occur (Martini et al., 2003), and local hemorrhage and inflammation was noted in blood vessels (C. J. Wang et al., 2002). Further adverse effects may include pain during and/or intolerance of treatment administration, increase in lameness following treatment, or microcracking of bone (Da Costa Gómez et al., 2004; Revenaugh, 2005).

3. SPECIFIC AIMS

The specific aims of this thesis are:

To characterize the use of ESWT among equine practitioners in North America (Chapter 4).

To determine the analgesic efficacy (via measurement of lameness and kinematic gait analysis) of focused ESWT on horses with naturally occurring caudal heel pain (Chapter 5).

To determine the effect of focused ESWT on the appearance of lesions diagnosed by MRI in horses with naturally occurring caudal heel pain (Chapter 5).

CHAPTER FOUR

CHARACTERIZATION OF THE USE OF SHOCK WAVE THERAPY AMONG EQUINE PRACTITIONERS

CHAPTER 4

Transition Page

Characterization of the use of shock wave therapy among equine practitioners

This chapter utilized an online survey to determine the frequency and type of ESWT use among equine practitioners registered with the AAEP.

Copyright statement: Submission of Chapter 4 for publication is impending. The copyright of this Chapter will belong to the journal in which it is published. The full citation will be available upon publication.

Author Contribution: MacKay and Robinson were responsible for the experimental design. MacKay, McOnie, and Riddell were responsible for data collection and organization. MacKay was responsible for data analysis. MacKay, McOnie, Riddell, and Robinson wrote the manuscript.

4. Characterization of the use of shock wave therapy among equine practitioners

Angela V. MacKay, Rebecca C. McOnie, Lea P. Riddell, Katherine A. Robinson

4.1 Abstract

The use of extracorporeal shock wave therapy (ESWT) has increased in both veterinary and human medicine. Research to date has prioritized mechanism of action and efficacy of the therapy; data regarding clinical use patterns is not available. The objective of this survey was to characterize the use of ESWT by equine practitioners specifically regarding rate of use, indications for use, and opinion of efficacy and tolerability. A 21-question survey was offered using an online survey engine to all 7787 members of the American Association of Equine Practitioners (AAEP) between April 25 and June 6, 2016. One-hundred-and-forty-four responses were obtained. ESWT was used frequently by 65/144 (45.1%) respondents, infrequently by 61/144 (42.4%) respondents, and never by 18/144 (12.5%) respondents. The most common reason for use was to treat ligamentous injuries. Overall, the therapy was rated as a moderately effective option for various musculoskeletal conditions of the horse. Respondents who do not use the therapy indicate a lack of scientific evidence supporting its use and a lack of access to the technology as contributing factors. The information gained from this survey will help direct further research and development, and may guide practitioners' use of ESWT.

4.2 Introduction

Shock wave therapy (extracorporeal shock wave therapy, ESWT) has become increasingly common in human and veterinary medicine. Originally developed for dissolution of urinary calculi in humans, ESWT has evolved into a treatment modality for musculoskeletal injuries in animals and humans. Research has concentrated on the mechanism of action of ESWT and treatment efficacy for both experimentally induced and naturally occurring musculoskeletal disease processes in rats, sheep, dogs, horses and humans (Chung and Wiley, 2002; Leeman et al., 2016; McClure et al., 2005; Wang et al., 2013).

Types of ESWT generators, treatment protocols, indications for use, and evidence and definition of efficacy vary in the scientific literature (Chung and Wiley, 2002; McClure and Dorfmueller, 2003). Data regarding the use of ESWT in equine veterinary clinical practice has not been available. The goal of this study was to characterize the use of ESWT among equine

veterinary practitioners regarding: rate of therapy use, diseases treated, and clinical opinion of treatment efficacy and tolerability. We hypothesized that ESWT was commonly used by equine veterinary practitioners, and that clinicians would rate ESWT as a well-tolerated and effective treatment for a variety of musculoskeletal conditions in the horse.

4.3 Materials and Methods

4.3.1 Sample and survey

A 21-question survey was offered to the 7787 members of the American Association of Equine Practitioners (AAEP). Contact was initiated electronically via email; a link for a web-based^a survey was sent. The survey was available for a 6-week period between April 25 and June 6, 2016, and email reminders were circulated 1 and 3 weeks after survey release. Respondents could choose to remain anonymous when completing the survey, and could exit the survey at any time. A reward was not offered for survey participation. Question type included multiple choice, multiple answer, rating scales, and short answer (Appendix A). Frequency of shock wave use, machine type, conditions treated, combinations with other therapies, clinical opinion of the therapy, use of sedation, opinion of therapy tolerance, and practice demographics were evaluated. Demographic information evaluated included: type of practice worked in, percentage of equine work performed by the practice, any complementary therapies offered by the practice, and types of horses worked on grouped by discipline.

4.3.2 Statistical analysis

All surveys were reviewed for completion and errors once received. All available responses for each question were included in the analysis. Numerical data was tested for normality of distribution using Shapiro-Wilks test for normality. Responses were summarized, and percentages were calculated for all questions. Data were examined for number of responses per question option, and then re-categorized based on response distribution if indicated to facilitate statistical analysis. For questions regarding self-reported rate of use, the responses were grouped into categorical ranges if not normally distributed: rarely or never (0-20%), seldom (21-40%), about half the time (41-60%), often (61-80%), and almost always or always (81-100%). Reporting the percentage of horse work in the veterinary practice was exempted from the above

categorization; responses to this question were grouped into one of 2 categories: 100% equine work (equine-only), or all other responses (not equine-only).

Associations were assessed using Fisher's Exact test for binary outcome variables and Kruskal-Wallis test for continuous and categorical scale outcome variables. A Bonferroni correction was used to control overall experimental error for multiple pairwise comparisons. Predictors included practice type, amount of equine work, and if complementary therapies were offered by the practice. The outcome variable examined included frequency of ESWT use. Further associations were examined between frequency of ESWT use and opinion of efficacy, as well as use of sedation and opinion of tolerance. Statistical analysis was performed using statistical software^b. Significance was set at $p < 0.05$.

4.4 Results

One-hundred-and-forty-four (144/7787) survey responses were collected (1.8% response rate). Thirteen surveys were incomplete; available responses for individual questions from incomplete surveys were included in the analysis. The data were not normally distributed.

4.4.1 Demographic information

Most respondents indicated that their practice was equine-only (108/131; 82.4%). Twenty-three of 131 respondents (17.6%) indicated that their practice was not equine-only. Respondents were asked what type of practice they worked in, such as ambulatory equine, mixed practice, racetrack and horse-show practice, or other. Based on distribution, responses were re-categorized into 4 distinct types of practice. Sixty of 131 (45.8%) respondents were in a general or ambulatory equine practice. Twenty-two of 131 (16.8%) were part of a specialist or referral equine practice, including surgery, radiology, or sports medicine. Forty of 131 (30.5%) respondents were part of a racetrack (flat or harness) or show horse-based practice. Nine of 131 respondents worked in a mixed practice (6.9%). Types of horses seen were divided by generic discipline, and respondents could select all that applied. English performance horses were the most common type of horses seen (103/131, 78.63%), followed by companion or pleasure horses (86/131, 65.65%) and Western performance horses (77/131, 58.78%). Complementary therapy offerings were investigated; 39/131 (29.8%) respondents did not offer complementary therapies to their clients. Many respondents offered more than one type of complementary therapy, with

the most common types being acupuncture (69/131, 52.67%), chiropractic (53/131, 40.46%), and therapeutic laser (42/131, 32.06%).

4.4.2 Frequency of shock wave therapy use

To determine the rate of use of ESWT, respondents were given five descriptive options including: daily, at least once per week, at least once per month, less than once per month, and never. Based on response distribution, these data were re-categorized for analysis into frequently (daily, once per week), infrequently (once per month, less than once per month), and never. Sixty-five of 144 (45.1%) respondents indicated that they use ESWT frequently in their practice. Sixty-one of 144 (42.4%) respondents indicated that they use ESWT infrequently. Only 18/144 (12.5%) respondents indicated that ESWT was a modality that they never use in their practice. Respondents who do not use ESWT indicated that a lack of scientific evidence supporting its use and a lack of access to the technology were their primary reasons. ESWT was more likely to be used if the practice was 100% equine ($p = 0.018$) and if complementary therapies were also offered by the veterinarian ($p = 0.02$). The rate of ESWT use was different (Kruskal-Wallis test, $X^2(3) = 22.282$, $p = 0.0001$) between mixed practice ($n=9$), general and ambulatory equine ($n=60$), referral equine ($n=22$), and sport horse/racetrack practice ($n=40$). Referral equine had a higher rate of use than mixed practice ($p = 0.0029$) and general equine practice ($p = 0.0073$). Sport horse/racetrack practice had a higher rate of use than both mixed practice ($p = 0.0004$) and general equine practice ($p=0.0005$). Referral equine and sport horse practice did not differ ($p = 0.95$); nor did mixed practice or general equine practice ($p = 0.0576$). A Bonferroni correction was used to control overall experimental error for multiple pairwise comparisons; comparisons following the correction were considered significant at $p < 0.008$.

Respondents were asked how often they chose ESWT as a single treatment modality. Forty-one of 120 (34.2%) respondents rarely or never used the therapy as the single treatment for an injury (Table 4.1). Only 9/120 (7.5%) respondents almost always or always used ESWT as the single treatment modality. In a separate but related question, respondents were asked how often they used ESWT as part of a multi-modal treatment plan, or in conjunction with other treatments for an injury. Twenty of 120 (16.7%) respondents almost always or always use the therapy in conjunction with other treatment options for an injury (Table 4.1). Twenty-seven out of 120 (22.5%) respondents rarely or never use ESWT in conjunction with other treatment options.

Thirty-three out of 120 (27.5%) respondents to both questions regarding rate of use did not sum their responses to ensure equal but opposite responses. Characterization of multi-modal use of the therapy was requested. Most respondents (110/118, 93.2%) indicated that they prefer to use ESWT in conjunction with other medically appropriate therapies, depending on the injury. Twenty-one of 118 (17.8%) respondents indicated that ESWT was preferred in situations where more advanced therapies would not be financially feasible.

Table 4.1 Number and percent of respondents who reported using ESWT as a single treatment and as part of a multi-modal treatment approach for musculoskeletal injuries (120 respondents for each question).

	Single Treatment Approach # (%)	Multi-Modal Approach # (%)
Rarely or Never	41 (34.2)	27 (22.5)
Seldom	17 (14.2)	21 (17.5)
About Half the Time	27 (22.5)	29 (24.2)
Often	26 (21.6)	23 (19.2)
Almost Always or Always	9 (7.5)	20 (16.6)

4.4.3 Method of shock wave therapy use

Respondents were asked what brand(s) of shock wave machine(s) they used in practice to determine which types of shock wave generators were being used. The brands of shock wave machines were re-categorized into focused, radial, or dual (focused and radial) machines based on information freely available from the manufacturers. Ninety-two of 125 (73.6%) respondents used a focused-type machine, including but not limited to the Versatron® (Pulse Veterinary Technologies, LLC, Alpharetta, Georgia), VetGold® (Tissue Regeneration Technologies, LLC, Woodstock, Georgia), and NeoVet® (Nucleus Regenerative Therapies, Kennesaw, Georgia). Seventeen out of 125 (13.6%) respondents used a radial-type machine, including but not limited to Storz Masterpuls MP200 (Storz Medical AG, Tägerwil, Switzerland). Six of 125 (4.8%) respondents used both types of machines, or a dual machine such as the Storz Duolith (Storz Medical AG, Tägerwil, Switzerland).

The condition that was most commonly treated with ESWT was desmitis, treated by 118/125 (94.4%) respondents. Tendon injuries were treated using the therapy by 96/125 (76.8%) respondents, muscle pain was treated by 79/125 (63.2%), osteoarthritis was treated by 64/125 (51.2%), and navicular syndrome was treated by 34/125 (27.2%) respondents. Other responses for indications for ESWT use included: wounds, proximal sesamoiditis, non-healing fractures, periostitis of the third metacarpal bone, sacroiliac pain, generalized back pain, sclerosis of the third carpal bone, cervical vertebral pain, injury to the second and fourth metacarpal or tarsal bones, and digital cushion pain.

Sedation was always used to administer ESWT to horses by 50% (59/118) of respondents. Of the 50% that do not always use sedation for ESWT administration, 16/59 (27%) rarely or never used sedation to administer ESWT; of those 16 respondents, 3 respondents indicated that they never used sedation to administer the therapy.

Protocols for use may be included with the specific ESWT machine. When provided by the manufacturer, these given protocols were followed about half of the time by 24/118 (20.34%) respondents, often followed by 33/118 (27.97%) respondents, and almost always or always followed by 28/118 (23.73%) respondents. However, the protocols were rarely or never followed by 27/118 (22.88%) of respondents.

Respondents were asked to rate their clinical opinion of how well equine patients tolerate application of ESWT to various body regions on a scale of 1-4, with 1 being intolerable and 4

being completely tolerable. Most respondents indicated that equine patients were moderately to completely tolerable of ESWT, regardless of the body region (Table 4.2). Opinion of tolerance was not associated with the use of sedation to administer the therapy to the joints of the distal limb ($p = 0.3$), the flexor tendons ($p = 0.4$), the foot and heel region ($p = 0.3$), the hock joints ($p = 0.3$), or the epaxial muscles ($p = 0.1$).

Table 4.2 Respondents' clinical opinion of patient tolerance for ESWT applied to specified body regions. Results are shown as number and percent of respondents per rating category (131 respondents for the question).

	Intolerable # (%)	Moderately Intolerable # (%)	Moderately Tolerable # (%)	Complete Tolerance # (%)	Not Applicable # (%)
Distal limb joints	5 (3.8)	33 (25.2)	44 (33.6)	32 (24.4)	17 (13.0)
Flexor tendons	0 (0)	11 (8.4)	59 (45.1)	51 (38.9)	10 (7.6)
Foot/heels	0 (0)	18 (13.7)	45 (34.3)	34 (26.0)	34 (26.0)
Hocks	5 (3.8)	32 (24.4)	36 (27.5)	27 (20.6)	31 (23.7)
Epaxial muscles	1 (0.8)	7 (5.3)	38 (29.0)	69 (52.7)	16 (12.2)

To rate their opinion of the efficacy of ESWT as a single treatment option for various musculoskeletal disorders, respondents were given a scale of 1-5, with 1 being completely ineffective and 5 being highly effective. Based on a clustered response distribution, this scale was condensed into a 3 point descriptive scale for analysis: ineffective (ratings 1 and 2), somewhat effective (rating 3), and highly effective (ratings 4 and 5). ESWT was viewed as a highly effective treatment option for ligament injuries and muscle pain management; a somewhat effective treatment option for tendon injuries; and an ineffective treatment option for osteoarthritis pain management and navicular syndrome (Table 4.3). There was no association between frequency of ESWT use and opinion of efficacy for osteoarthritis pain management ($p = 0.617$), flexor tendinitis ($p = 0.178$), desmitis ($p = 0.086$), navicular syndrome ($p = 0.65$), or muscle pain management ($p = 0.087$).

Table 4.3 Respondents' clinical opinion of ESWT efficacy for specified musculoskeletal disorders. Results are shown as number and percent of respondents per rating category (133 respondents for the question).

	Ineffective # (%)	Somewhat Effective # (%)	Completely Effective # (%)
OA Pain Management	63 (47.4)	43 (32.3)	27 (20.3)
Tendon Injuries	38 (28.6)	44 (33.1)	51 (38.3)
Ligament Injuries	20 (15.0)	36 (27.1)	77 (57.9)
Navicular Syndrome	78 (58.6)	36 (27.1)	19 (14.3)
Muscle Pain Management	32 (24.1)	39 (29.3)	62 (46.6)

4.5 Discussion

Objective information regarding ESWT use among equine practitioners was previously not available. This survey outlines the use and perceived effectiveness of ESWT in the equine veterinary field.

Although commonly used in equine veterinary practice, there is conflicting evidence supporting the use of ESWT. Multiple studies have shown that treatment with ESWT alleviated pain and lameness in horses, regardless of the disease process (Dahlberg et al., 2006; Frisbie et al., 2009; McCarroll and McClure, 2000; Palmer, 2002). In vivo work in horses has demonstrated changes to sensory nerve conduction following ESWT that could explain an analgesic effect (Bolt et al., 2004b). As such, regulations have been established in some equine competitive jurisdictions to prevent ESWT use immediately prior to competition. However, work performed in horses with chronic forelimb lameness shows no change in force plate analysis of gait immediately following treatment with radial ESWT (Brown et al., 2005). A separate study performed in horses established that there was no analgesia of the cutaneous nerve field when the palmar digital nerve was treated with ESWT, but a local cutaneous analgesic effect was produced (McClure et al., 2005). The same group evaluated histological changes after ESWT was applied to a subcutaneous nerve in sheep, and demonstrated perineural inflammation but no changes in nerve integrity or neuropeptide concentrations (McClure et al., 2005). The effects of ESWT on bone, tendon, and ligaments have been examined. A positive effect of ESWT at the tissue level has been noted in multiple species, including an anti-inflammatory effect (Mariotto et al., 2009), induction of neovascularization (Kersh et al., 2006; C. J. Wang et al., 2002), increased expression of transforming growth factor - beta 1 (TGF- β 1) (Caminoto et al., 2005), and transient increased cellular metabolism, glycosaminoglycan levels and protein synthesis (Bosch et al., 2007) when compared to controls, indicating possible mechanisms for improved healing in osseous and connective tissue structures. It has been shown that the effects on osseous structures are dose-dependent, with lower energy doses stimulating osteogenesis and high energy doses causing microfractures, aseptic necrosis and damaged osteocytes (F. S. Wang et al., 2002). Despite this information, optimal dosage ranges for specific injuries in horses have not been established. In addition, a study reporting decreased lameness was not able to demonstrate any disease modifying effects when ESWT was used to treat experimentally induced osteoarthritis (Frisbie et al., 2009), and another group has reported a lack of improved healing when ESWT was used to

treat experimentally induced desmitis (Waguespack et al., 2011). Difficulties exist in interpretation of the current literature and are beyond the scope of this paper, in part because the studies are widely varied in terms of design, use of appropriate blinding and negative controls, and sample size. The available evidence has not yet provided a long-term assessment of the effects of ESWT in horses, so it is not known if the treatment improves the final outcome for musculoskeletal injuries compared to negative controls or other available treatments.

Rate of ESWT use as either a single therapy or as part of a multi-modal treatment plan was self-reported by respondents in percentage format. These questions were asked in conjunction, but respondents were not explicitly directed to ensure logical summation of their responses (to 100%). As stated above, 27.5% of respondents did not provide equal and opposite responses. Categorization of the percentage data resulted in apparent illogical responses, as represented in Table 4.1. It is possible that some respondents did not consider that a single therapy plan is the opposite of a multi-modal therapy plan. The lack of explicit direction was intended to allow respondents to convey their own opinions and uses of ESWT. However, this created discordant results and represents a weakness of the survey design.

The current survey established that veterinary practitioners have a moderately positive view regarding the efficacy of ESWT for treating various injuries in horses. However, respondents were simply asked to provide a rating; a definition of efficacy was not provided or allowed to be stated by the respondent. Efficacy could have been interpreted by respondents in multiple ways. For example, one practitioner could have deemed ESWT to be efficacious in treating osteoarthritis if the patient's lameness was alleviated with no change in radiographic evidence of disease. Another practitioner could conclude that ESWT was efficacious in treating a tendinopathy based on improvement in ultrasonographic appearance on recheck examination regardless of the degree of lameness improvement. In this way, the survey was a tool to examine practitioner use and opinion of ESWT and provides a starting point for more precise investigations. However, this lack of a definition of efficacy as used in this survey may not have allowed for an accurate evaluation of respondents' opinions; it simply provided an estimate. This highlights the need to provide defined, concrete end-points in both surveys and in equine scientific literature.

The current survey also established that veterinary practitioners consider ESWT a moderately to completely tolerable therapy for their equine patients, based on a rating scale. This

question was not asked in relation to the use of sedation to administer ESWT, and a definition of tolerable was not provided nor allowed to be stated by the respondent. As discussed for efficacy, tolerable could have different meaning for each respondent. Again, this lack of a definition did not allow an accurate or complete evaluation of respondents' opinions. This possibility for widespread interpretation represents a limitation of the current study.

The poor survey response rate (1.8%) and undetermined possible biases were important limitations of this study. A previous survey of a similar population elicited 831 responses, or a 7.6% response rate (Ferris et al., 2011). The pool of respondents was limited to those with access to email and internet. In addition, voluntary surveys can produce non-response bias, which poses a significant risk to the accuracy of the results, given the possibility that the responses of the respondents could differ from those that would be provided by non-respondents (Dargatz and Hill, 1996). In this survey, ESWT users may have been more likely to voluntarily complete the survey. However, based on demographic responses, our population was similar to that of a previous survey investigating intra-articular injection practices of equine veterinarians. Ferris *et al.* (2011) reported that 80.3% of their respondents worked in a practice that saw 100% equine cases. This is similar to our result of 82.4%. This indicates that our population of respondents may be representative of the entire population sampled. However, the AAEP published demographic information for the year the survey was available stating that 45.4% of their 7787 members worked in a practice that saw 100% equine cases¹, indicating that non-response bias could be present. It is possible that non-response bias existed both due to the conflicting scientific evidence supporting ESWT, and due to the interests of equine-only practitioners. Both the subject of the current survey and the previous survey of the same population were more likely to be of interest to veterinarians who were equine-only practitioners.

The current survey attempted to gather a large volume of information regarding ESWT use and had a small number of respondents. Further work on this topic should attempt to improve response rate and decrease potential non-response bias. Methods to achieve this include mailing out surveys, conducting phone surveys, offering a small reward for survey completion, decreasing the length of the survey, increasing the duration that the survey is available, or establishing the statistical difference between responses of early and late respondents to estimate the amount of sampling bias (Hutchison et al., 1987; Sax et al., 2003). Information that would improve the available body of literature regarding ESWT include therapy protocols used for

defined injuries (including frequency, dose and duration of therapy), type of ESWT generator used, and specific outcome measures being used to indicate treatment success. Expanding the survey population to a wider range of veterinarians may improve response rate. Widening the survey topic to include other species may result in a more accurate assessment of ESWT use by the entire veterinary population.

In conclusion, shock wave therapy was commonly used by the equine practitioners who participated in this survey. The therapy was used to treat a diverse range of injuries in the horse. Clinical opinion of the efficacy of the therapy was variable and depended on the condition being treated. Practitioners indicated that they considered ESWT to be moderately well to completely tolerated by their patients. Practitioners who have an equine-only practice were more likely to use ESWT than those who worked in mixed practice. Non-response bias likely affected the results of this survey. Further work should include efforts to reduce non-response bias or to select a representative sample. Future surveys of practitioners regarding shock wave therapy should focus on the clinical use of the technology.

4.6 Footnotes

1. American Association of Equine Practitioners Annual Report 2016 (2017). aaep.org Accessed November 2017.

a. Survey Monkey; surveymonkey.com, Portland, OR

b. Stata®, StataCorp LP, College Station, TX.

CHAPTER FIVE

A NOVEL APPROACH TO THE TREATMENT OF CAUDAL HEEL PAIN IN HORSES USING EXTRACORPOREAL SHOCK WAVE THERAPY

CHAPTER 5

Transition Page

A novel approach to the treatment of caudal heel pain in horses using extracorporeal shock wave therapy

This chapter evaluated the effects of ESWT for treatment of naturally occurring caudal heel pain via subjective lameness evaluation, kinematic gait analysis, and magnetic resonance imaging.

Copyright statement: Submission of Chapter 5 for publication is impending. The copyright of this Chapter will belong to the journal in which it is published. The full citation will be available upon publication.

Author Contribution: MacKay, Robinson, and Manning were responsible for the experimental design. MacKay, Robinson, Manning, McOnie, and Riddell were responsible for data collection. McOnie and Riddell were responsible for data management. Werpy was responsible for interpretation of magnetic resonance imaging. MacKay was responsible for data analysis. MacKay and Robinson wrote the manuscript with Manning, Riddell, Werpy, and McOnie providing editorial assistance.

5. A novel approach to the treatment of caudal heel pain in horses using extracorporeal shock wave therapy

MacKay, AV; Manning, ST; McOnie, RC; Riddell, LP; Werpy, NM; Robinson, KA

5.1 Abstract

Caudal heel pain is a common cause of forelimb lameness in the horse (Sampson et al., 2009). Multiple treatment options are available, including: therapeutic farrier work, systemic anti-inflammatories, intra-articular or intra-bursal medication, systemic bisphosphonates, and vasoactive medications (Barrett et al., 2017; Bell et al., 2009; Denoix et al., 2003; Schoonover et al., 2005), but none have demonstrated a clear disease-modifying effect or have been evaluated using magnetic resonance imaging (MRI). Extracorporeal shock wave therapy (ESWT) has been shown to reduce pain and lameness associated with caudal heel pain (Dahlberg et al., 2006; McClure et al., 2004a). The current study evaluated the effects of focused ESWT on the degree of lameness using subjective assessment and kinematic gait analysis, as well as the change in lesions over time as diagnosed by MRI in horses with naturally occurring caudal heel pain. This was a randomized, double-blind, controlled trial in horses with naturally occurring caudal heel pain undertaken between June 2015 and August 2017. Thirty adult horses underwent a lameness exam, diagnostic analgesia of the lame limb(s), kinematic gait analysis, radiographs, and MRI of both front feet to diagnose caudal heel pain and determine inclusion at day -16. Horses were randomized into the treatment group (n=15) or the control group (n=15). Focused ESWT (1,500 shock waves, energy flux density of 0.28 mJ/mm² at 360 Hz, penetration depth of 35 mm) was applied to the heel bulb region of affected limbs with standing sedation on days 0, 14, and 28 to horses in the treatment group; standing sedation but no ESWT was administered to the control group on days 0, 14, and 28. A lameness exam and kinematic gait analysis was performed at each treatment point before sedation. At day 128, the inclusion procedures as listed above were repeated. Outcome measures included: change in subjective lameness grade (0-5/5) of each limb, total subjective lameness score (0-10/10) of each horse, absolute change in kinematic gait analysis measures, and change in MRI grades for each included limb from day -16 to day 128. Forty-nine limbs (11 unilateral, 19 bilateral; 30 horses total) were evaluated. The median decrease in lameness grade per limb was 1 grade between day -16 and day 128; groups were not significantly different. The median total lameness score per horse at baseline was 5/10 units. The

median change in total horse lameness score was -1 unit (interquartile range, IQR: -2 to 0 units) for the control group and -2 units (IQR: -3 to -1 units) for the treatment group ($p=0.15$). If only unilaterally lame horses ($n = 11$) were considered, the control group ($n=7$) experienced no change in total lameness score (a median change of 0 lameness units; IQR: -1 to 1 units) and the treatment group ($n=4$) experienced a significantly different median decrease of 1 lameness units (IQR: -2 to -1 units) ($p=0.049$). Kinematic gait analysis results were not validated for use with bilaterally lame horses, so only results from unilaterally lame horses were reported. Horses in the treatment group had a larger degree of decrease in some kinematic parameters than those in the control group following treatment, although no statistically significant differences were found. When change in MRI grades were compared between groups, the control group exhibited improved navicular bursitis and the treatment group exhibited worsened navicular bursitis ($p=0.027$). No other significant differences were found. Focused ESWT may decrease subjectively assessed pain in horses with unilateral caudal heel pain for at least 128 days. However, the therapy may lead to worsening of navicular bursitis. Further work is needed to determine the mechanism of action of focused ESWT for both pain control and effect on tissues. In addition, validation of kinematic gait analysis for use in cases of bilateral forelimb lameness would increase the utility of this assessment tool, both clinically and in research settings.

5.2 Introduction

Caudal heel pain is a commonly diagnosed cause of forelimb lameness in the horse (Sampson et al., 2009; Turner, 1989). With the advent of magnetic resonance imaging (MRI), accurate identification of abnormalities of structures in the caudal heel region has improved (Dyson et al., 2012, 2011a; Murray et al., 2006b; Parkes et al., 2015). The structures of the podotrochlear apparatus (PTA) include: the navicular bone, the collateral sesamoidean ligaments (CSL), the distal sesamoidean impar ligament (DSIL), the navicular bursa, and the distal portion of the deep digital flexor tendon (DDFT) (Busoni and Denoix, 2001; Dyson, 2011b). It is recognized that one or any combination of these structures can be affected in cases of caudal heel pain, although primary injury of the DDFT in the foot is now considered to be a separate clinical syndrome that may have similar clinical signs (Dyson et al., 2012; Lutter et al., 2015; Parkes et al., 2015). Abnormalities in the foot of horses affected with caudal heel pain often involve the flexor surface of the navicular bone in combination with the dorsal aspect of the DDFT (Blunden

et al., 2006a; Wright et al., 1998). Other notable abnormalities include: navicular bone edema, desmitis of the CSL and/or DSIL, navicular bursitis, and distal border fragmentation of the navicular bone (Biggi and Dyson, 2012; Dyson et al., 2012; Murray et al., 2006b; Sampson et al., 2009). The etiology of caudal heel pain has not been proven, but the degenerative disease is similar to osteoarthritis in other anatomical locations (Dyson et al., 2011a; Gabriel et al., 1998; Wright et al., 1998). A failure of biomechanics followed by chronic mechanical overload is supported by current research (Rijkenhuizen, 2006; Wilson et al., 2001; Wright et al., 1998).

Multiple treatment or management options have been used in cases of caudal heel pain with varying degrees of success. Success is often defined as a return to work or resolution of lameness for a period of time (Bell et al., 2009; Denoix et al., 2003; Gutierrez-Nibeyro et al., 2010; Schoonover et al., 2005). Modulation of the disease process in an attempt to slow progression or induce healing is difficult when etiology is not fully understood. The focus of management in clinical cases is on control of symptoms clinical signs versus disease modification, and previous research has not investigated effect of treatment on MRI-diagnosed abnormalities. The mainstay of management is corrective trimming and shoeing techniques (Barrett et al., 2017; Schoonover et al., 2005). Other treatments include: intra-synovial medication with anti-inflammatories, systemic hemo-rheologics, systemic bisphosphonates, and various surgical methods (Baxter et al., 2011; Dabareiner and Carter, 2003). Medication of the navicular bursa with corticosteroids has been shown to reduce or resolve lameness for 2-16 months (Bell et al., 2009; Dabareiner et al., 2003; Marsh et al., 2012; Verschooten et al., 1990). Bisphosphonate drugs such as tiludronate or clodronate reduce lameness associated with caudal heel pain, but do not alter disease progression on the basis of radiographic examination (Denoix et al., 2003; Frevel et al., 2014). Focused extracorporeal shock wave therapy (ESWT) has been used to alleviate lameness associated with caudal heel pain for a variable period of time (Dahlberg et al., 2006; McClure et al., 2004).

Focused ESWT is a pressure wave that can penetrate the tissues and cause cavitation. Initially developed for lithotripsy in human medicine, this therapy is now used in human and veterinary sports medicine as a general modality to decrease pain and improve healing for multiple musculoskeletal injuries, including tendonitis, desmitis, and osteoarthritis (Chung and Wiley, 2002; McClure and Dorfmueller, 2003). Purported mechanisms of action include: modulation of nerve conduction, increased blood flow through angiogenesis and

neovascularization, alteration of inflammation through induction and/or reduction of nitric oxide and growth factors, and induction of osteogenesis and bone remodeling (Caminoto et al., 2005; Cárcamo et al., 2012; Gotte et al., 2002; Kersh et al., 2006; Maier et al., 2003; Romeo et al., 2013; Wang et al., 2009; F. S. Wang et al., 2002; Zhao et al., 2012). Doses of ESWT are typically reported using energy flux density (EFD), which is the amount of energy administered in millijoules (mJ) to one square millimetre (mm²) (McClure and Dorfmueller, 2003). Both focused and radial ESWT have previously been examined as a therapy for caudal heel pain with mixed results. Some studies have demonstrated that focused ESWT decreases pain and lameness associated with caudal heel pain (Bär et al., 2001; Blum, 2004; Dahlberg et al., 2006; McClure et al., 2004), although the duration of lameness improvement varied and no radiographic change over time was observed. Others have shown that radial ESWT affects neither lameness nor radiographs and scintigraphic results (Brown et al., 2005; Byron et al., 2009). Treatment protocols varied in these studies, and control groups were not used. The effect of ESWT on lesions in the foot as diagnosed by MRI in horses has not been investigated. Additionally, the effects of ESWT on lameness caused by naturally occurring caudal heel pain in comparison to a control group have not been shown.

The null hypothesis of this study was that treatment with focused ESWT would not change subjective lameness scores, kinematic gait analysis parameters, or lesions identified on MRI associated with caudal heel pain in horses, when compared to controls. The objectives of this study were to determine the analgesic efficacy of focused ESWT on horses with naturally occurring caudal heel pain through subjective lameness assessment and kinematic gait analysis; and to determine the effect of this therapy on the appearance of lesions associated with caudal heel pain as diagnosed by MRI.

5.3 Materials and Methods

5.3.1 Animals

Client-owned horses (n=30) referred with a known or tentative diagnosis of caudal heel pain were recruited for this study. Recruitment occurred between June 2015 and August 2017. Study inclusion was based on a complete lameness examination performed by the authors (AVM, KAR) prior to enrolment, including a movement exam, diagnostic anesthesia, and radiography.

Inclusion criteria were: 1) lameness of >3 weeks duration, 2) unilateral or bilateral forelimb lameness notable at a trot in hand, 3) subjective improvement in lameness by more than 80% following a palmar digital nerve block of the affected limb(s), and 4) magnetic resonance imaging findings consistent with caudal heel pain as the primary cause of lameness. Exclusion criteria included 1) forelimb lameness not localized to the palmar heel region, 2) any bursal or articular injections to the palmar heel region within the prior 6 months, 3) any treatment with shock wave therapy or bisphosphonates in the prior 6 months, or 4) radiographic evidence of laminitis of the fore feet or osteoarthritis of the distal interphalangeal joint. Radiographic evidence of navicular region pathology was not required for study inclusion.

Horses were housed on their respective farms in pasture or paddock turnout based on owner preference. Housing and exercise of the horses was not restricted during the study period unless chosen by the owner. General recommendations for trimming of the front feet to increase heel mass and improve break over were given on an individual basis for each horse. The owner's regular farrier maintained foot care during the study period. Horses could not wear shoes for the duration of the trial. The use of analgesic and anti-inflammatory medications and supplements for the management of lameness was restricted for the study duration.

This protocol was approved by the University Animal Care Committee at the University of Saskatchewan, and owners provided written consent for the use of their horse.

5.3.2 Design

Horses were randomly assigned to one of two groups: control (n = 15) or treatment (n = 15). Forelimbs were included only if all inclusion criteria were met. Data were collected at 5 time points within the study period (Table 5.1). Baseline for subjective lameness evaluation was established as day -16 (median, interquartile range (IQR): -28 to -13 days) to establish true lameness of each limb following diagnostic anesthesia at the inclusion examination. Baseline for kinematic gait analysis was on day 0, immediately prior to the first treatment. Baseline for MRI was on day -16. The times of the inclusion and final exams are stated as a median with the interquartile range to account for scheduling variability.

Table 5.1 Data collection time points for the study.

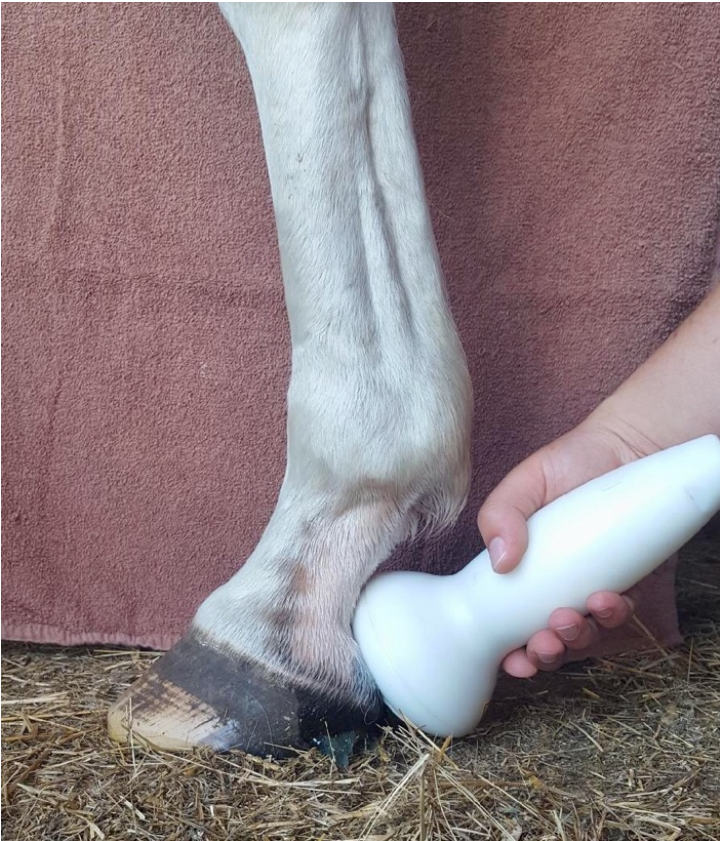Time Point	Type of Data Collection or Monitoring
Day -16 (median, IQR: -28 to -13 days)	Complete Subjective Lameness Evaluation (inclusion exam)
	MRI
Day 0	Kinematic Gait Analysis
	Subjective Lameness Evaluation (no diagnostic anesthesia performed)
Day 14	Kinematic Gait Analysis
	Subjective Lameness Evaluation (no diagnostic anesthesia performed)
Day 28	Kinematic Gait Analysis
	Subjective Lameness Evaluation (no diagnostic anesthesia performed)
Day 128 (median, IQR: 123-138 days)	Kinematic Gait Analysis
	Complete Subjective Lameness Evaluation (diagnostic anesthesia included)
	MRI

MRI, magnetic resonance imaging

5.3.3 ESWT

The protocol used in this study was based on a combination of prior research (Bär et al., 2001; Blum, 2004; Dahlberg et al., 2006; McClure et al., 2004a), manufacturer directions^a and anecdotal experience. Horses enrolled in the treatment group were administered ESWT to all included limbs three times at two-week intervals on days 0, 14, and 28. ESWT was performed with the horse standing, sedated by intravenous (IV) administration of xylazine^b (0.2-0.3 mg/kg) or detomidine^c (4-6 µg/kg) combined with butorphanol^d (4-6 µg/kg). The heel bulb region of each included forelimb was cleansed with chlorhexidine soap^e and isopropyl alcohol^f prior to treatment, and coupling gel^g was generously applied. An electrohydraulic shock wave generator^h was used. Shock waves (1,500 shocks) with an EFD of 0.28 mJ/mm² at a frequency of 360 Hertz were applied to the heel bulb region with the limb weight bearing by authors (LER, KAR, STM) blinded to the lameness status of the horse. A trode with a penetration depth of 35 millimetres (mm) was used (35-mm trodeⁱ). The shock wave trode was moved continuously throughout the treatment and was directed at an angle towards the PTA (Figure 5.1). Horses in the control group were administered xylazine (0.2-0.3 mg/kg) or detomidine (4-6 µg/kg) combined with butorphanol (4-6 µg/kg) IV and had the heel region of the included forelimbs cleansed as if going to receive treatment, but ESWT was not applied on days 0, 14, and 28.

Figure 5.1 Angle of ESWT trode application to the heel region of the fore foot.



5.3.4 Subjective lameness evaluation

Horses were completely evaluated for lameness during the inclusion exam (median: day -16; IQR: -28 to -13 days) and at day 128 (median; IQR: 123 to 138 days), including hoof tester exam, flexion tests and diagnostic anesthesia. A brief subjective lameness assessment consisting only of a movement exam was also performed at days 0, 14 and 28 prior to the administration of any sedation. At these time points, horses were observed at a walk and trot in a straight line and on circles in both directions. Lameness was graded for each limb on a scale from 0 to 5, with 0 representing a normal gait and 5 representing non-weight bearing (severe) lameness using the scale recommended by the American Association of Equine Practitioners (AAEP) (Swanson, 1984), as outlined in section 2.3.2.1. On days -16 and 128, the lamest limb was assigned a lameness grade prior to diagnostic anesthesia, and the less lame limb, if applicable, was assigned a lameness grade after the lamest limb was blocked. Subjective lameness grades for each limb from days -16 and 128 were combined to create a total lameness score representing total number of lameness units (0-10/10) per horse. Lameness evaluations were performed by the same veterinarian (AVM) who was blinded to group assignment.

5.3.5 Kinematic gait analysis

Kinematic gait analysis was performed using a commercially available inertial sensor system (Lameness Locator®^j) with three inertial sensors applied to the horse; one each on dorsal midline at the poll and tuber sacrale and one on the dorsal aspect of the right front pastern, as outlined by the user manual^k. Variables obtained to reflect head movement asymmetry and therefore forelimb lameness measurements included: the mean difference in minimum and maximum head height (Hmin and Hmax, respectively) between right and left halves of the trot stride, standard deviation of Hmin and Hmax, and the vector sum (VS) of Hmin and Hmax in a straight line and on the circle in both directions, as previously described (Keegan et al., 2012). The VS is calculated from the Hmin and Hmax, and represents the overall measurement of head movement asymmetry in the vertical plane. Data were collected by the accompanying software^l as described elsewhere (Keegan et al., 2013, 2011). Values for each trial were taken from a data output sheet generated by the software.

5.3.6 Magnetic resonance imaging

Magnetic resonance imaging was performed at days -16 and 128 for all horses using a 0.27-Tesla standing equine MRI unit^m and a specific equine foot radiofrequency coilⁿ. Horses were sedated with acepromazine^o (0.06 mg/kg administered intramuscularly), detomidine (4-6 µg/kg IV), butorphanol (4-6 µg/kg IV) and maintained under light standing sedation using detomidine (1-2 µg/kg) or xylazine (0.1-0.15 mg/kg) via IV bolus as needed. Images were obtained of each front foot in a standing position using the following pulse sequences: T1- and T2*- weighted 3-dimensional (3D) gradient echo (GE), T2-weighted fast spin echo (FSE), proton density (PD) weighted FSE, and short tau inversion recovery (STIR) FSE with number of slices ranging from 4-26. T1-weighted 3D gradient echo and STIR FSE images were obtained in dorsal, sagittal and transverse planes. T2-weighted FSE images were obtained in dorsal and transverse planes. T2*-weighted 3D GE images were obtained in the sagittal plane. PD-weighted FSE images were obtained in a transverse plane. A T1-weighted 3D isotropic pulse sequence comprised of 112 slices in the dorsal plane was added to the imaging protocol in January 2017; all MRI examinations completed before this date did not include this pulse sequence. Images were centered at the navicular bone. MRI images were interpreted by a single board-certified radiologist (NMW). Abnormalities were reported as mild, moderate or severe for each structure. Following interpretation, reported signal abnormalities were translated into grades by the author (AVM) with radiologist assistance (NMW) on a scale from 0-3, as per the grading system used by Murray et al. (2006b) and Biggi and Dyson (2011) (0: normal; 1: mild abnormalities; 2: moderate abnormalities; 3: severe abnormalities). An overall grade for the navicular bone was determined based on the sum of grades for each aspect of the bone, as per the grading system used by Biggi and Dyson (2011). An overall grade for the DDFT was determined based on the grading system published by Lutter et al. (2015). The radiologist was blinded to group assignment at all times and to degree of lameness at day 128. The author performing the grading was blinded to horse identity and group assignment.

5.3.7 Statistical analysis

Descriptive statistical analysis was performed for all data, and data were analyzed for both individual horse and individual leg. Kinematic gait analysis data was checked for normality of distribution (Shapiro-Wilks, $P > 0.05$) prior to using non-parametric statistical tests. The Fisher

exact and Wilcoxon rank sum tests were used to assess the difference in change in subjective lameness grade by leg (AAEP lameness scale, 0-5) and by horse (total lameness score, 0-10) between groups, between demographic subtypes, between each time point and over the entire study period. The Fisher exact and Kruskal-Wallis tests were used to compare the change in MRI grades between groups. Groups were evaluated for improvement versus worsening for both subjective lameness scores and MRI scores. Kinematic gait analysis data were transformed into the absolute values to represent the asymmetry of the horse regardless of the lame leg, and a leg variable was included. Groups were compared using a Wilcoxon rank sum test for all kinematic gait analysis variables. Analysis of all variables was repeated with all bilaterally lame horses removed, and then all unilaterally lame horses removed. A 2-way analysis of variance was used to test for associations between MRI grades and change in kinematic gait variables, despite lack of normality. Values of $P < 0.05$ were considered significant. An initial power calculation indicated that a study population of 32 horses (16 per group) would be appropriate to determine if a difference of one lameness grade existed. A post-hoc power calculation was performed to determine if the change in horse number for the lameness data affected the statistical power when only unilateral horses were considered. Statistical software^p was used to analyze the data.

5.4 Results

Eighty-three horses were evaluated for inclusion, and 30 horses were enrolled in the study with 4 left forelimbs only, 7 right forelimbs only and 19 bilateral forelimbs for a total of 49 limbs. The mean age was 11 years old (range: 6-18 years). Demographic and historical data was tabulated and was not significantly different between groups (see Table 5.2). Twenty-four horses completed the study within the designated time period; 5 had delays of study completion due to owner related factors and 1 horse developed an unrelated non-degenerative lameness that delayed study completion. Basic supportive treatment was provided for this horse until the complication resolved prior to completing the study period. The median day for inclusion exam procedures was day -16 (IQR: -28 to -13 days); for the control group this was day -16 (IQR: -23 to -13 days) and for the treatment group this was day -14 (IQR: -31 to -9 days). The median day for final exam procedures (from day 0 to final MRI) was day 128 (IQR: 123 to 138 days); for the control group this was day 125 (IQR: 118 to 133 days) and for the treatment group this was day 133

(IQR: 126 to 141 days). Groups were not significantly different in time frame required to complete study procedures ($p>0.05$).

Table 5.2 Demographic information for the 30 horses enrolled in the study. No significant differences were noted between groups.

Demographic Characteristics										
		Sex		Breed			Lameness Duration		Forelimb Lameness	
Group		Mare	Gelding	QH	Paint	Other	<1 Yr	>1 Yr	Unilat	Bilat
Treatment	#	8	7	11	4	0	6	9	4	11
	%	53	47	73	27	0	40	60	27	73
Control	#	3	12	10	4	1	3	12	7	8
	%	20	80	67	27	6	20	80	47	53
Total	#	11	19	21	8	1	9	21	11	19
	%	37	63	70	27	3	30	70	37	63

QH, Quarter Horse; Unilat, unilateral; Bilat, bilateral; Yr, year

5.4.1 Subjective lameness evaluation

The lameness grade per limb (n=49) at day -16 and day 128 are shown in Figures 5.2 and 5.3. There were no significant differences between groups at either time point. There was a mean decrease in 1 lameness grade per leg from day -16 to day 128 in both groups (range: decrease by 3 grades to increase by 1 grade); groups were not significantly different ($p>0.05$).

The median total lameness score per horse at baseline (day -16) was 5/10 units (IQR: 3-6/10 units); groups were not significantly different. The median total lameness score at day 128 per horse was 3/10 units (IQR: 2-4/10 units); median for the control group was 3/10 units (IQR: 2-4/10 units) and the treatment group was 2/10 units (IQR: 1-5/10 units). The median change in total horse lameness score was -1 units (IQR: -2 to 0 units) for the control group and -2 units (IQR: -3 to -1 units) for the treatment group ($p=0.15$). If only unilaterally lame horses (n = 11) were considered, the control group (n=7) experienced no change in total lameness score (a median change of 0 lameness units; IQR: -1 to 1 units) and the treatment group (n=4) experienced a significantly different median decrease of 1 lameness units (IQR: -2 to -1 units), as shown in Figure 5.4 (Wilcoxon Rank Sum, $p=0.049$). There was no significant effect of MRI grade on subjective lameness assessment outcomes ($p>0.05$).

Figure 5.2 Baseline grade of lameness, by leg, separated by group (percent of legs per grade).

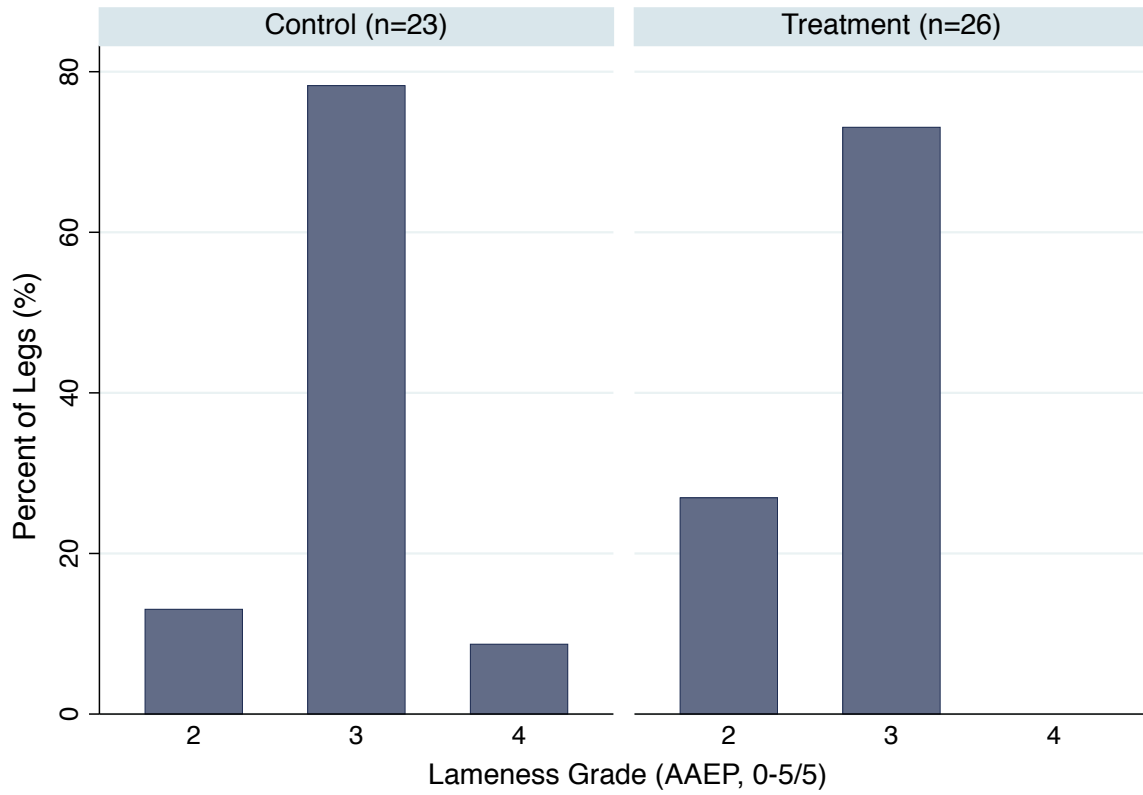


Figure 5.3 Final grade of lameness, by leg, separated by group (percent of legs per grade).

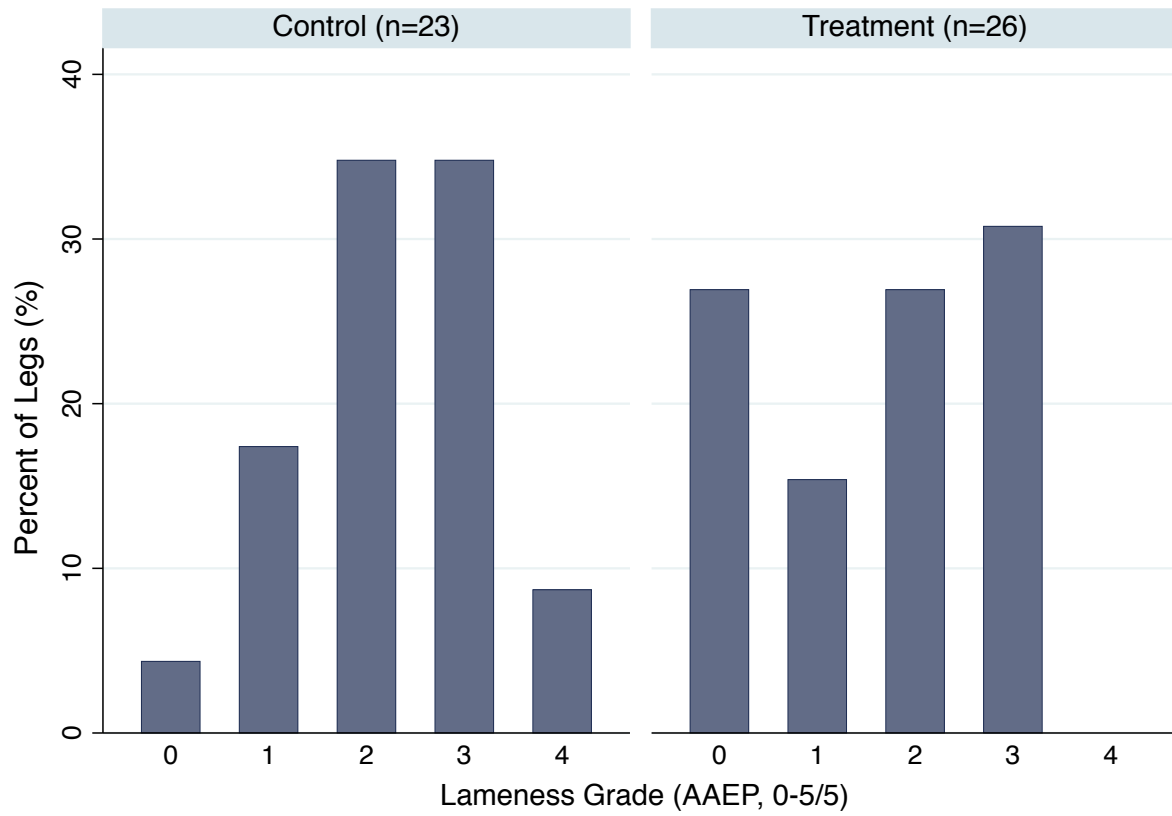
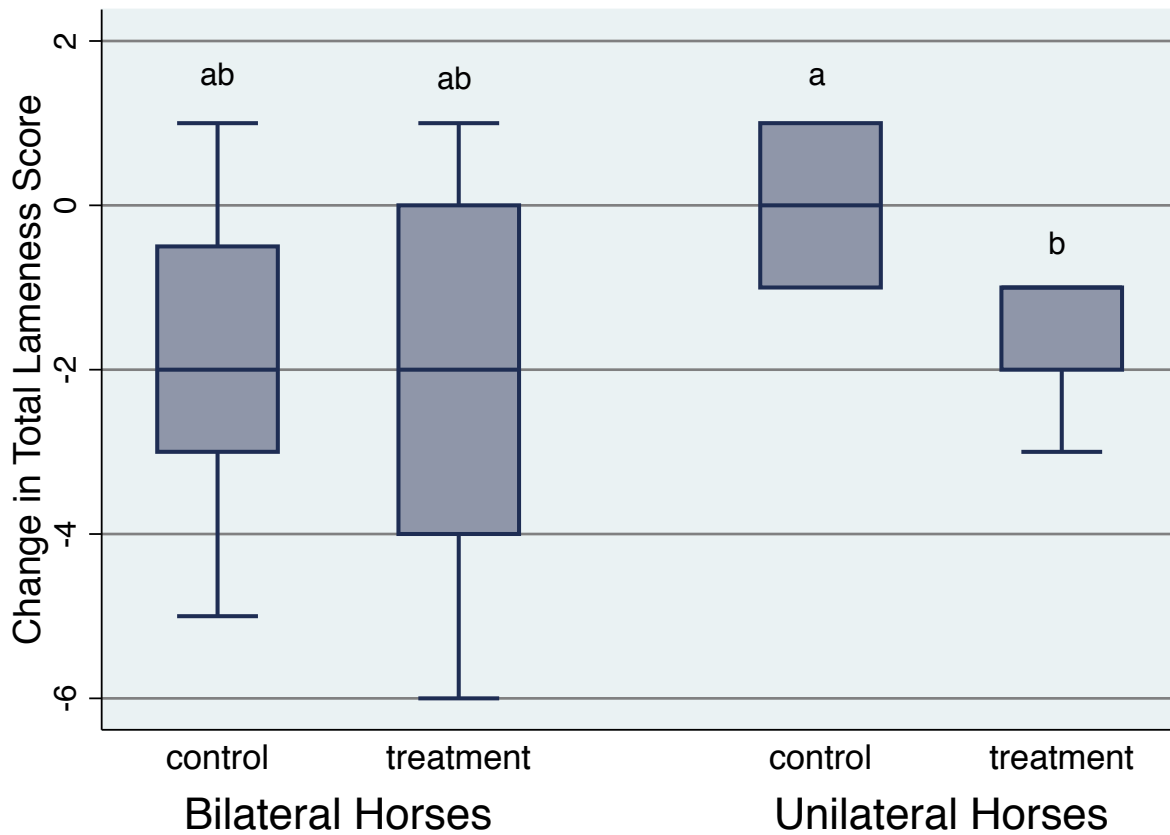


Figure 5.4 Change in total lameness score (0-10/10) per horse between day -16 and day 128 separated by group and by bilateral or unilateral lameness. Median values that are significantly different ($p < 0.05$) are indicated by different letters.



5.4.2 Kinematic gait analysis

Absolute values of all kinematic gait analysis data are reported here, as described in section 5.3.7. Kinematic gait analysis is not validated for use with bilaterally lame horses due to muting of measurable asymmetry. Muting of asymmetry was present in this population of horses that had bilateral forelimb lameness. The median straight line vector sum for unilaterally included horses at day 0 was 22.3 mm (IQR: 10.9 to 24.4 mm); the median straight line vector sum for bilaterally included horses at day 0 was 17.3 mm (IQR: 10.8 to 21.6 mm); no significant difference was present ($p>0.05$). Despite the lack of statistical significance, decreased measurable asymmetry in bilaterally lame horses represents an important biological consideration with clinical relevance to the analyzed data. With this in mind, only data for horses enrolled with a unilateral forelimb lameness is presented. There were no significant differences in outcomes when all horses were included in the analysis.

The median straight line absolute value vector sum at baseline of 22.3 mm in unilaterally lame horses is over the established threshold for lameness^k of 8.5 mm and is consistent with the subjective lameness evaluation results. The median right circle absolute value vector sum at baseline was 22.6 mm (IQR: 11.8 to 31.0 mm). The median left circle absolute value vector sum at baseline was 16.6 mm (IQR: 8.5 to 33.4 mm). Groups were not significantly different at baseline for all variables. The distribution of the absolute values of vector sum, Hmin and Hmax over time for the straight line, left circle and right circle are shown in Appendix B. The change in absolute value of vector sum, Hmin and Hmax for each trial type (straight line, left circle, right circle) between day 0 and day 128 were calculated and compared between groups; the distribution of change between groups is shown in Figures 5.5-7. A decrease in absolute value represents a decrease in asymmetry and therefore improvement in lameness as measured by the inertial sensor system. No significant differences were noted between groups for change in variables, but there was a trend for the treatment group to have a larger degree of decrease in some kinematic parameters than the control group, as shown in Figures 5.5-7. A decrease in kinematic parameters in unilaterally lame horses indicates a decrease in asymmetry and therefore a decrease in lameness^k.

Figure 5.5 Change in kinematic gait analysis variables (VS, Hmin, Hmax) from day 0 to day 128 in a straight line (unilateral horses only), separated by group.

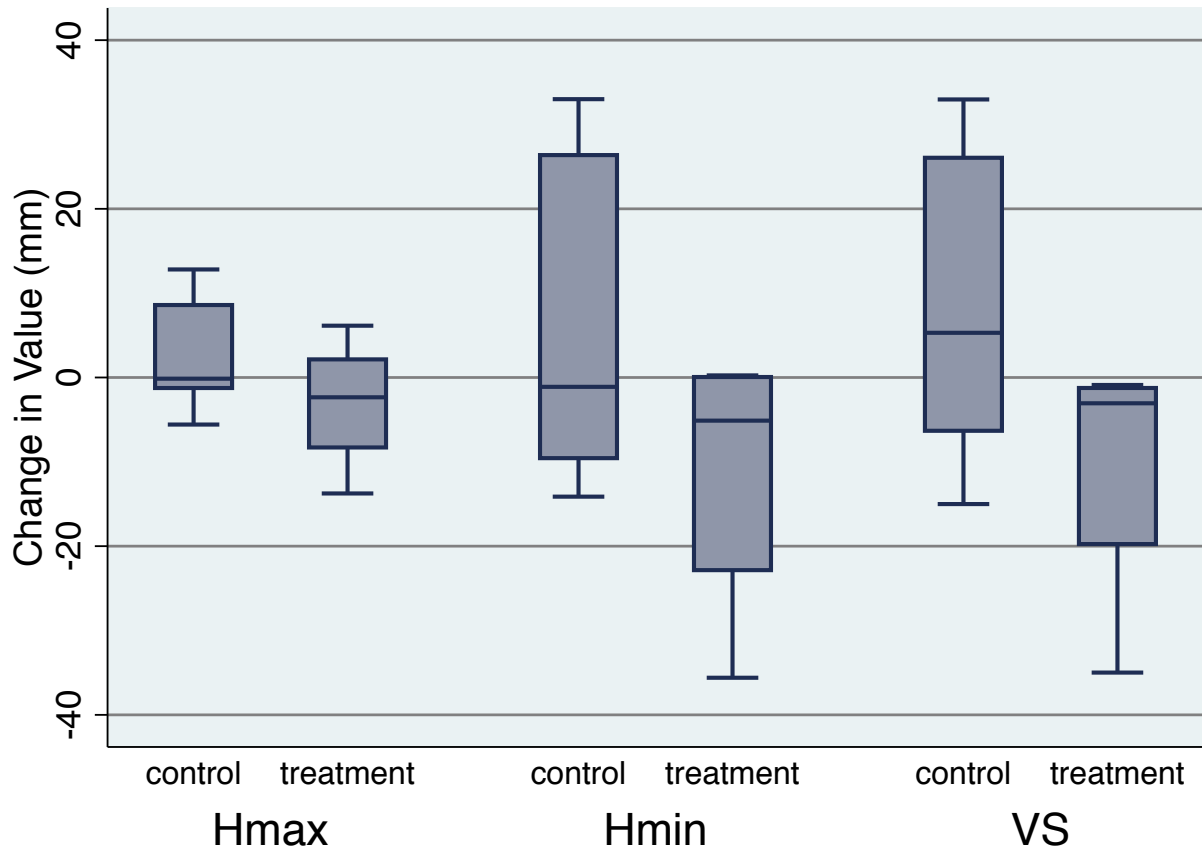


Figure 5.6 Change in kinematic gait analysis variables (VS, Hmin, Hmax) from day 0 to day 128 in a left circle (unilateral horses only), separated by group.

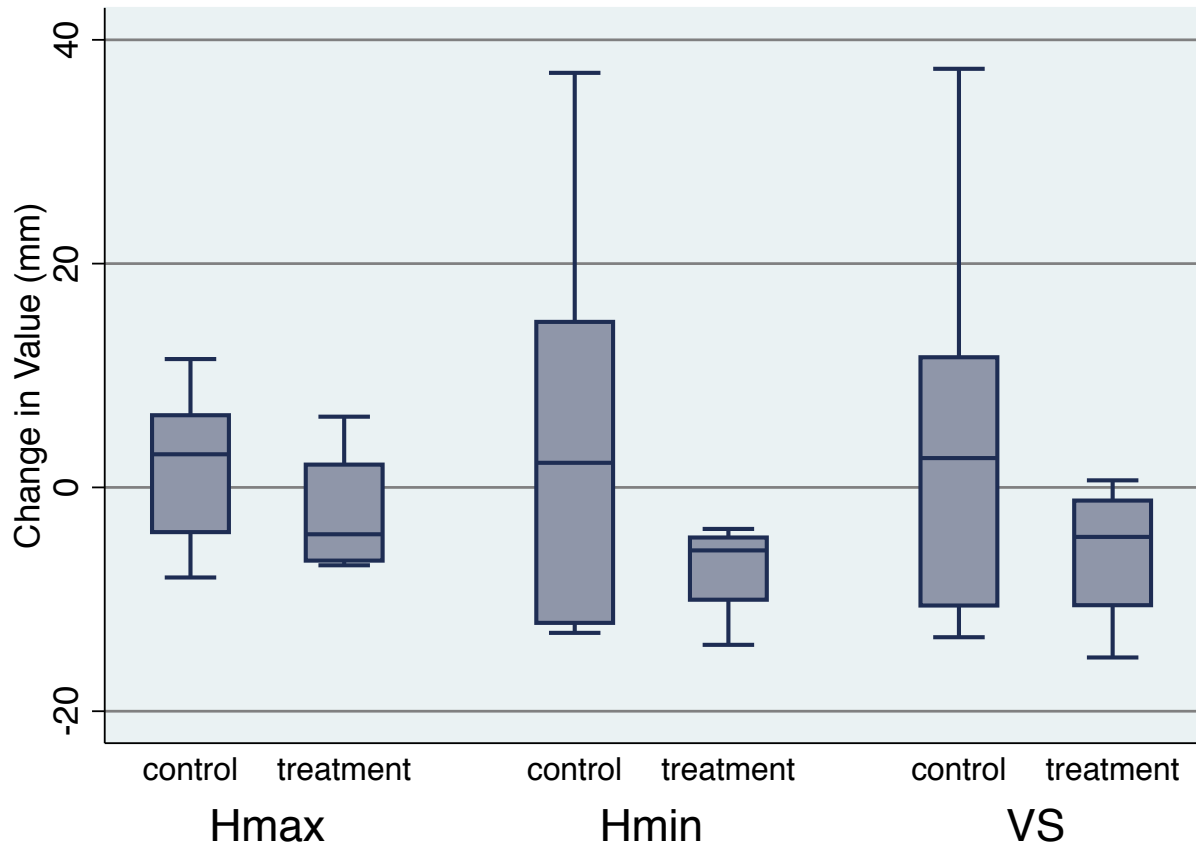
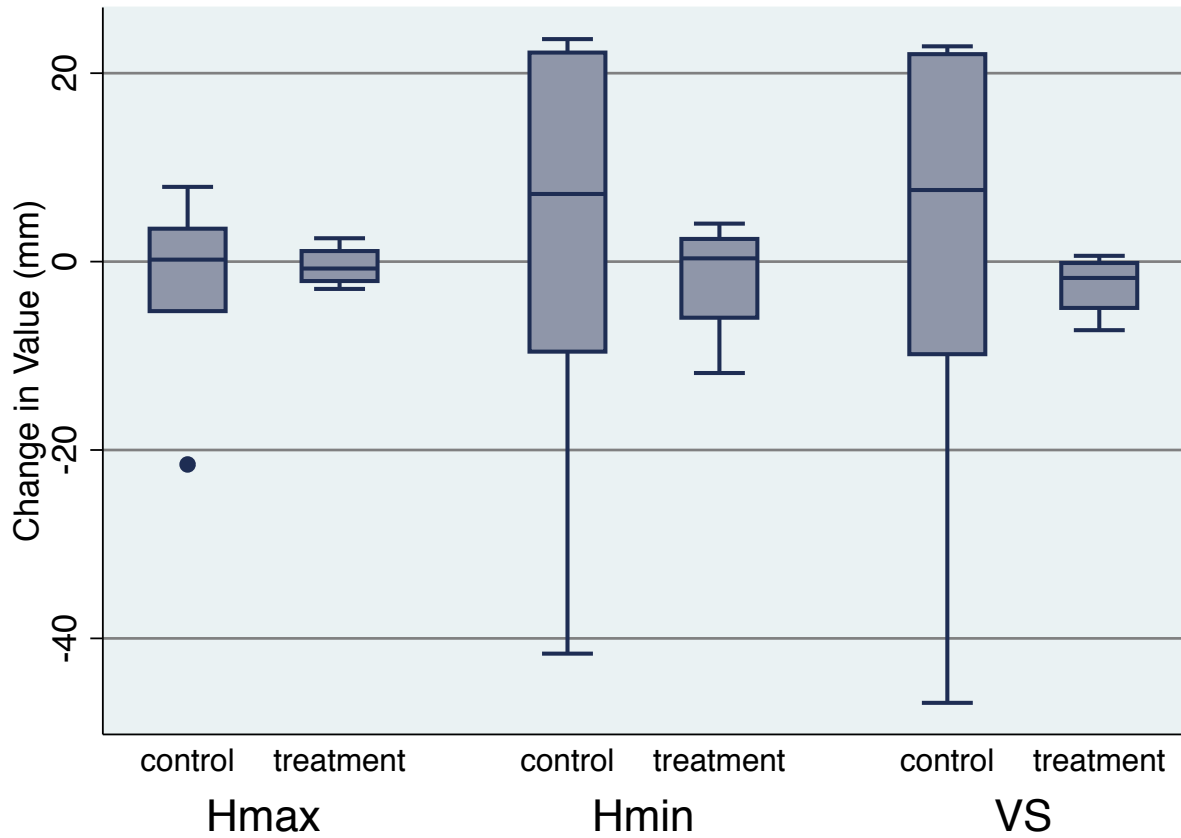


Figure 5.7 Change in kinematic gait analysis variables (VS, Hmin, Hmax) from day 0 to day 128 in a right circle (unilateral horses only), separated by group.



5.4.3 MRI

Lesion grades on MRI at day -16 (by limb, n=49) are shown in Table 5.3. The control group had 23 limbs and the treatment group had 26 limbs included in the study. Groups were not significantly different at baseline. Adhesions involving the DDFT were identified in 43% of limbs (21 limbs; 8 limbs (35%) in the control group and 13 limbs (50%) in the treatment group). Lesion grades on MRI at day 128 (by leg, n=49) are shown in Table 5.4. At day 128, an additional 4 limbs had developed identifiable adhesions involving the DDFT, 3 in the control group and 1 in the treatment group. This change was not statistically significant ($p>0.05$). Degree of change (worse, no change, better) in lesion grades from day -16 to day 128 was compared between groups and is shown in Table 5.5. More limbs in the treatment group had a worsening of navicular bursitis, and more limbs in the control group had an improvement in navicular bursitis ($p=0.027$). A similar but insignificant trend was noted with navicular bone fluid ($p=0.12$) and navicular bone overall grade ($p=0.18$). Limbs in the treatment group with an increase or worsening of navicular bursa grade (n=7) showed an overall improvement in lameness grade; only a single limb worsened by 1 lameness grade; although this was not statistically significant ($p>0.05$). Degree of change in MRI grades was evaluated with bilaterally lame horses removed; no significant differences between groups were noted. Degree of change in MRI grades was evaluated with unilaterally lame horses removed (bilaterally lame horses, n= 19, # of limbs = 38). Bilaterally lame horses enrolled in the control group (n=8) had significantly more improvement in navicular bursitis ($p=0.008$) and a trend for more improvement in navicular bone fluid ($p=0.072$) than bilaterally lame horses enrolled in the treatment group (n=11).

Table 5.3 Number and proportion (%) of limbs graded 0 (normal) to 3 (severe abnormality) for lesions or signal abnormalities in podotrochlear structures on MRI at day -16 in horses from the treatment (15 horses, 26 limbs) and control (15 horses, 23 limbs) groups.

Structure	Grade 0		Grade 1		Grade 2		Grade 3	
	Control # (%)	Treatment # (%)	Control # (%)	Treatment # (%)	Control # (%)	Treatment # (%)	Control # (%)	Treatment # (%)
Navicular Bone								
Flexor Surface	14 (61)	18 (69)	1 (4)	0 (0)	1 (4)	1 (4)	7 (31)	7 (27)
Synovial Invaginations	10 (44)	10 (38)	6 (26)	9 (35)	7 (30)	6 (23)	0 (0)	1 (4)
Distal Border	11 (48)	8 (31)	7 (30)	11 (42)	5 (22)	5 (19)	0 (0)	2 (8)
Medulla (Fluid)	1 (4)	0 (0)	11 (48)	16 (62)	9 (39)	5 (19)	2 (9)	5 (19)
Proximal Border	20 (87)	22 (85)	0 (0)	1 (4)	3 (13)	3 (12)	0 (0)	0 (0)
Max Grade	0 (0)	0 (0)	8 (35)	12 (46)	8 (35)	6 (23)	7 (30)	8 (31)
Overall Grade	0 (0)	0 (0)	16 (70)	16 (61)	6 (26)	8 (31)	1 (4)	2 (8)
DSIL	7 (30)	17 (65)	13 (57)	8 (31)	3 (13)	1 (4)	0 (0)	0 (0)
P3 (Fluid)	13 (57)	21 (81)	7 (30)	4 (15)	3 (13)	1 (4)	0 (0)	0 (0)
CSL	5 (22)	6 (23)	8 (35)	16 (62)	10 (43)	4 (15)	0 (0)	0 (0)
DDFT Overall Grade	2 (9)	1 (4)	7 (30)	14 (54)	14 (61)	11 (42)	0 (0)	0 (0)
Navicular Bursa (Bursitis)	2 (9)	5 (19)	9 (39)	11 (42)	9 (39)	10 (38)	3 (13)	0 (0)

DSIL, distal sesamoidean impar ligament; P3, third phalanx; CSL, collateral sesamoidean ligaments; DDFT, deep digital flexor tendon

Table 5.4 Number and proportion (%) of limbs graded 0 (normal) to 3 (severe abnormality) for lesions or signal abnormalities in podotrochlear structures on MRI at day 128 in horses from the treatment (15 horses, 26 limbs) and control (15 horses, 23 limbs) groups.

Structure	Grade 0		Grade 1		Grade 2		Grade 3	
	Control # (%)	Treatment # (%)	Control # (%)	Treatment # (%)	Control # (%)	Treatment # (%)	Control # (%)	Treatment # (%)
Navicular Bone								
Flexor Surface	12 (52)	18 (69)	1 (4)	1 (4)	1 (4)	0 (0)	9 (39)	7 (27)
Synovial Invaginations	10 (44)	9 (35)	6 (26)	9 (35)	7 (30)	7 (27)	0 (0)	1 (4)
Distal Border	9 (39)	8 (31)	7 (30)	7 (27)	6 (26)	10 (38)	1 (4)	1 (4)
Medulla (Fluid)	2 (9)	0 (0)	14 (61)	14 (54)	6 (26)	7 (27)	1 (4)	5 (19)
Proximal Border	20 (87)	22 (85)	0 (0)	0 (0)	3 (13)	4 (15)	0 (0)	0 (0)
Max Grade	1 (4)	0 (0)	8 (35)	10 (38)	5 (22)	8 (31)	9 (39)	8 (31)
Overall Grade	1 (4)	0 (0)	13 (57)	16 (62)	8 (35)	9 (35)	1 (4)	1 (4)
DSIL	12 (52)	14 (54)	8 (35)	12 (46)	2 (9)	0 (0)	1 (4)	0 (0)
P3 (Fluid)	16 (70)	22 (85)	6 (26)	4 (15)	1 (4)	0 (0)	0 (0)	0 (0)
CSL	2 (9)	4 (15)	8 (35)	17 (65)	13 (57)	5 (9)	0 (0)	0 (0)
DDFT Overall Grade	2 (9)	0 (0)	7 (30)	15 (58)	13 (57)	11 (42)	1 (4)	0 (0)
Navicular Bursa (Bursitis)	4 (17)	1 (4)	11 (48)	13 (50)	6 (26)	12 (46)	2 (9)	0 (0)

DSIL, distal sesamoidean impar ligament; P3, third phalanx; CSL, collateral sesamoidean ligaments; DDFT, deep digital flexor tendon

Table 5.5 Number and proportion (%) of limbs with a change in lesion grade on MRI between day -16 and day 128 by identified lesions and signal abnormalities in podotrochlear structures in horses from the treatment (15 horses, 26 limbs) and control (15 horses, 23 limbs) groups; P value indicates comparison between groups.

Structure	Worse		No Change		Better		P value
	Control	Treatment	Control	Treatment	Control	Treatment	
	# (%)	# (%)	# (%)	# (%)	# (%)	# (%)	
Navicular Bone							
Flexor Surface	3 (13)	1 (4)	20 (87)	24 (92)	0 (0)	1 (4)	0.33
Synovial Invaginations	0 (0)	1 (4)	23 (100)	25 (96)	0 (0)	0 (0)	0.53
Distal Border	5 (22)	4 (15)	18 (78)	21 (81)	0 (0)	1 (4)	0.85
Medulla (Fluid)	2 (9)	4 (15)	14 (61)	20 (77)	7 (30)	2 (8)	0.12
Proximal Border	0 (0)	1 (4)	23 (100)	25 (96)	0 (0)	0 (0)	0.53
Max Grade	2 (9)	3 (12)	19 (83)	22 (85)	2 (9)	1 (4)	0.86
Overall Grade	8 (35)	6 (23)	8 (35)	16 (62)	7 (30)	4 (15)	0.18
DSIL	3 (13)	4 (15)	14 (61)	20 (77)	6 (26)	2 (8)	0.27
P3 (Fluid)	1 (4)	2 (8)	17 (74)	20 (77)	5 (22)	4 (15)	0.89
CSL	4 (17)	2 (8)	19 (83)	24 (92)	0 (0)	0 (0)	0.28
DDFT Overall Grade	3 (13)	1 (4)	18 (78)	24 (92)	2 (9)	1 (4)	0.4
Navicular Bursa (Bursitis)	1 (4)	7 (27)	15 (65)	17 (65)	7 (30)	2 (8)	0.027

DSIL, distal sesamoidean impar ligament; P3, third phalanx; CSL, collateral sesamoidean ligaments; DDFT, deep digital flexor tendon

5.4.4 Adverse effects

Minimal adverse effects of ESWT were noted in the treatment group. One owner reported moderately increased lameness for 1-2 days immediately following each treatment that resolved without additional care.

5.5 Discussion

The results of this research suggest that focused ESWT provides incomplete pain relief in horses with naturally occurring unilateral caudal heel pain for at least 128 days when compared to a control group. This was supported by statistically significant differences in subjective lameness evaluation between groups, and non-statistically significant trends in the kinematic gait evaluation data. Previous research indicated that focused ESWT alleviated lameness associated with caudal heel pain for a variable period of time of 2 days to 12 months following treatment (Bär et al., 2001; Blum, 2004; Dahlberg et al., 2006; McClure et al., 2004), however all previous work on this topic was performed in an uncontrolled manner. A lack of a control group in these studies introduces significant bias and decreases the strength of the results. The results presented in the current study show a mild reduction in subjective lameness grade over a period of 128 days (on average) regardless of group assignment, so it is possible that the reduction of lameness reported in other studies is due to the fluctuating nature of lameness associated with caudal heel pain (Parkes et al., 2015). The sample size (n=30) in the current study was close to the estimate provided by the power calculation and should have allowed for an obvious difference to be seen between groups, should one exist. However, only unilaterally lame horses showed statistically significant improvement over the control group. When only unilaterally lame horses were included in the analysis, the sample size was dramatically reduced to 11 horses.

The current study used 1,500 shocks at an EFD of 0.28 mJ/mm². It is possible that this ESWT dosing protocol was not the required dose to induce positive change in the injured tissues. It has been shown that there is a dose-dependent response in tissues following treatment with ESWT, with lower EFD stimulating positive biochemical responses and higher EFD (more than 0.5 - 0.6 mJ/mm²) causing detrimental tissue disruption in laboratory animals (Maier et al., 2002; Orhan et al., 2004; Rompe et al., 1998). Multiple studies of ESWT use in horses, including for caudal heel pain, have evaluated a dose of approximately 0.15 mJ/mm² (Blum, 2004; Caminoto et al., 2005; Frisbie et al., 2009; Kawcak et al., 2011), although another group saw a reduction in

lameness using a dose of 0.89 mJ/mm² in horses with caudal heel pain (McClure et al., 2004). However, it has not been shown in horses what a reasonable or productive EFD is, and the protocol used in this study was based on a combination of these prior references, recommendations provided by the manufacturer^a and previous personal experience with the therapy by multiple authors (KAT, AVM). The use of a 35-mm hand-piece was deemed appropriate based on the approximate distance between the skin of the heel bulbs and the navicular bone (Blum, 2004). Also, Blum (2004) determined that the outcome was improved if ESWT was applied between the heel bulbs with the horse weight bearing instead of through the palmar aspect of the frog. This method was used in the current study, with less appreciable improvement in lameness when compared to a control group.

The inability of kinematic gait analysis to accurately quantify bilateral forelimb lameness represents a significant and unforeseen limitation of this research. Kinematic gait analysis with inertial sensors relies on asymmetry between halves of the trot stride to detect the presence and amplitude of a lameness (Keegan et al., 2013). In cases of forelimb lameness, the sensors detect the abnormal acceleration of the head as the horse attempts to offload the lame limb at the trot. Horses with bilateral forelimb lameness may mute this head movement as they attempt to offload both lame limbs (Keegan et al., 2012), rendering the measured asymmetry between stride halves a smaller value when lameness is not isolated to a single limb, as demonstrated in the current study. This biologically important effect may reduce the validity and repeatability of the data, limiting comparisons over time for a given animal. Given this lack of validation, the kinematic gait analysis data for the bilateral horses could not be included in the final analysis, reducing the power of this study. The kinematic gait analysis results with the bilateral horses included versus excluded were not statistically significantly different, although it was determined that bilaterally lame horses do not experience the same improvement in subjectively evaluated lameness as unilaterally lame horses do following treatment with ESWT. Prior research has used both unilaterally and bilaterally lame horses to note an effect of ESWT in cases of caudal heel pain via subjective gait assessment (Bär et al., 2001; Blum, 2004; McClure et al., 2004a). However, even subjective lameness grading methods have difficulty in accurately identifying the severity of or improvement in bilateral forelimb lameness without eliminating one of the lame limbs through diagnostic anesthesia (Dyson, 2011a). Finally, the change in subjective lameness grade in both groups was only a decrease in one lameness grade, which could be a reflection of intra-observer

variability (Dyson, 2011a), or due to the known fluctuation in lameness that occurs in horses with caudal heel pain (Parkes et al., 2015).

Previous research showed no evidence of lesion change on radiographs or nuclear scintigraphy in horses with caudal heel pain following treatment with focused or radial ESWT (Bär et al., 2001; Byron et al., 2009). The current study used MRI to determine an effect of therapy on lesion appearance. The increase in inflammation within the navicular bursa in treated horses does not agree with the reported anti-inflammatory and potential disease-modifying effect of ESWT in other species (Chamberlain and Colborne, 2016; Mariotto et al., 2009), and was a surprising finding. The true mechanism by which focused ESWT stimulates healing and regeneration in musculoskeletal tissue in horses is incompletely determined. It has been shown in other species that the therapy stimulates a partial inflammatory response in osseous tissues through immediate increased substance P expression (Maier et al., 2003), yet stimulates an anti-inflammatory response in connective tissues via increased nitric oxide expression (Gotte et al., 2002; Wang et al., 2009, 2011b). However, another group determined that ESWT caused decreased nitric oxide expression, resulting in disease-modifying effects at the cartilage level (Zhao et al., 2012). In laboratory animals and humans, the therapy may promote bone healing in non-union fractures through increasing transforming growth factor-beta-1 (TGF- β 1) (Wang et al., 2009), and may enhance angiogenesis and neovascularization through increasing vascular endothelial growth factor release (Wang et al., 2011a, 2008). Vascular endothelial growth factor and TGF- β 1 is known to improve neovascularization of injured connective tissues in horses, which could result in more effective healing (Bosch et al., 2011; Dahlgren et al., 2005). Low dose ESWT failed to induce an increase in vascular endothelial growth factor, TGF- β 1, and insulin like growth factor 1 in experimentally induced skin wounds in horses (Morgan et al., 2009). Contrarily, low dose ESWT applied to induced suspensory ligament desmitis in horses resulted in an increase in TGF- β 1 (Caminoto et al., 2005). The specific role of these biomolecules in caudal heel pain in the horse is unknown, and the effects of potentially increased growth factors on lesion progression on MRI has not been determined. When focused ESWT was used to treat experimentally induced osteoarthritis in horses, an increase in serum biomarkers indicating bone remodeling was determined, but no histological effects were noted within the subchondral bone (Kawcak et al., 2011). In a similar osteoarthritis model, no disease modifying effects were found following treatment with focused ESWT, although there was a decrease in synovitis in treated

joints due to a statistically insignificant decrease in synovial fluid protein concentration (Frisbie et al., 2009); this finding was not supported by our results.

Navicular bursitis is characterized by an increase in fluid volume and the presence of synovial proliferation (hyperplasia) on MRI (Bell et al., 2009; Murray et al., 2006b). The results reported in the current study suggest that inflammation within the navicular bursa increased despite a mild decrease in lameness in horses treated with focused ESWT. This result is unexpected, and contrary to widespread accepted understanding of caudal heel pain. Inflammation and distension of the navicular bursa created experimentally in normal horses causes lameness (Pleasant et al., 1997). It is thought that naturally occurring navicular bursitis contributes to lameness in cases of caudal heel pain (Blunden et al., 2006a; Dyson et al., 2005; Murray et al., 2006b) but it is difficult to discern which lesion in the foot causes the most pain in horses with multiple lesions, given the closely related structures in the distal limb and lack of specificity of intra-synovial diagnostic anesthetic techniques in the foot (Parkes et al., 2015; Schumacher et al., 2001b, 2003). Intra-synovial administration of local anesthetic into the navicular bursa improves lameness associated with caudal heel pain, including navicular bursitis and other lesions of the PTA (Bell et al., 2009; Dyson and Kidd, 2003; Parkes et al., 2015), but anesthesia of the navicular bursa may also desensitize the sole and the distal interphalangeal joint (Schumacher et al., 2001b, 2003). With this in mind, perhaps navicular bursitis does not contribute to lameness as much as previously thought, especially in cases of advanced caudal heel pain with multiple abnormalities present. It is also possible that treatment with focused ESWT resulted in a partial decrease in pain sensation, allowing potential overuse and exacerbation of bursitis. It has been shown that ESWT can decrease local skin sensation in a treated region in horses, but that analgesia of the entire treated nerve field is not produced (McClure et al., 2005). In addition, inflammation is noted in treated nerves in sheep (McClure et al., 2005), but there is no change in substance P concentrations or other neuropeptides to explain any analgesic effect (Abed et al., 2007). Treatment of equine peripheral nerves with radial ESWT resulted in decreased sensory nerve conduction velocity, but cutaneous analgesia was not evaluated (Bolt et al., 2004a). The presence of worsened navicular bursitis in the current study may indicate that treatment with focused ESWT caused an inflammatory reaction. The effects of ESWT in equine tissues beyond 105 days (McClure et al., 2004c) have not previously been determined, so it is

possible that the sequence of inflammatory and anti-inflammatory events varies between tissue types, and that analgesia may be unrelated to the effects of the therapy on cells and tissues.

There was an overwhelming lack of change in MRI lesion grades despite group assignment. While not statistically significant, the trend of increasing navicular bone medulla fluid signal grade in treated horses could be due to angiogenesis within the navicular bone medulla. Increased fluid signal within the navicular bone on fat suppressed sequences can indicate edema, contusion, angiogenesis, osteonecrosis or degeneration, fibrosis, or inflammatory infiltrate (Murray et al., 2006a; Werpy, 2012). The cause of navicular bone fluid can only be determined by histopathology, which was not performed in the current study. It is possible that the overall severity of lesions in this particular group of horses limited the possible effects of the therapy, or that the lack of change on MRI indicated that the lesions noted were static and permanent (Werpy, 2012). Permanent navicular bone fluid could indicate more substantial osseous injury and degeneration that may not respond to treatment with focused ESWT. It is also possible that the timeline used to assess lesion change in this study was inappropriate to detect an effect of treatment. Prior research using ESWT has evaluated lesion change as early as 3 hours (Bosch et al., 2009) and as long as 105 days following treatment (McClure et al., 2004c). The time point used in this study (128 days, approximately 4.25 months) reflects the recommendations for recheck imaging as reported by Werpy (2012). It is possible that results would have differed if MRI was performed on a different timeline, for example immediately after the third treatment. It has been recommended that osseous fluid should be rechecked in 2-4 months, 6 if severe, and DDFT lesions should be rechecked in 5-7 months on average (Werpy, 2012). All horses in this study had some degree of osseous fluid within the navicular bone and at least one soft tissue structure affected, rendering an appropriate recheck time period somewhere between 2-7 months. It is unknown why a greater difference was noted in MRI grade change between groups when only bilaterally lame horses were considered.

Caudal heel pain is a difficult disease to maintain as a constant measured lameness, given the intermittent worsening and improvement of clinical signs that is often noted and the variation in possible lesions (Parkes et al., 2015). This naturally occurring disease state represents a limitation of this study, because it is impossible to control for all of the factors that may contribute to lameness and disease progression. All horses had some degree of navicular bone abnormalities in conjunction with soft tissue injury that were localized with diagnostic

anesthesia, and differences were not statistically different between groups. Further work should focus on the appearance and progression of types of lesions associated with caudal heel pain on MRI, and response to available therapies.

This study attempted to mimic the circumstances encountered in clinical practice, but the use of client-owned animals was also a limitation of this study. It was specified that clients could choose turnout and exercise for their horse, although most horses were given a period of rest during the study period at owner discretion and all were maintained on large paddock or pasture turnout. Relying on client compliance with recommendations is paramount for horse outcomes in cases of musculoskeletal injury.

Results of the current study were unable to provide an explanation for the mild improvement in lameness that was observed in the unilaterally lame horses in the treatment group. It cannot be determined from the results of the current study if focused ESWT is truly disease-modifying in cases of caudal heel pain, or if there is simply a reduction in lameness due to disrupted nerve conduction. However, it appears that treatment with focused ESWT does not result in any significant lesion resolution or improvement based on MRI when evaluated at this interval, and may result in worsening of navicular bursitis and increased STIR intensity within the navicular bone.

In conclusion, this study indicated that treatment with focused ESWT caused a mild decrease in subjectively assessed lameness in unilaterally lame horses when compared to a control group, but not in all horses included in the study. Despite this, navicular bursitis worsened in the treatment group but improved in the control group. Kinematic gait analysis was not useful for objective assessment of lameness in bilaterally lame horses due to muting of measured asymmetry, and no significant differences were present between groups if only unilateral horses were evaluated. To address limitations of this study, further research should focus on validation of kinematic gait analysis in bilaterally lame horses, elucidation of the concentration of growth factors and other biomolecules present in cases of caudal heel pain, determination of the true mechanism of action of ESWT on equine tissues over time, and the use of ESWT as a possible concurrent treatment method for caudal heel pain in combination with other therapies.

5.6 Footnotes

- a. VersaTron® Treatment Protocols, Pulse Veterinary Technologies LLC, Alpharetta, GA, USA
- b. Xylazine hydrochloride, Rompun 100 mg/mL Injectable, Bayer, Mississauga, ON, Canada
- c. Detomidine hydrochloride, Dormosedan, Pfizer Animal Health, Kirkland, QC, Canada
- d. Butorphanol tartrate, Torbugesic, Zoetis, Kirkland, QC, Canada
- e. Chlorhexidine gluconate solution 4%, Stanhexidine, Omega Laboratories Ltd, Montreal, QC, Canada
- f. Isopropyl alcohol 70%, RW Packaging Ltd, Winnipeg, MB, Canada
- g. Aquasonic® Ultrasound Transmission Gel, Parker Laboratories Inc., Fairfield, NJ, USA
- h. VersaTron®, Pulse Veterinary Technologies LLC, Alpharetta, GA, USA
- i. 35 mm trode, VersaTron®, Pulse Veterinary Technologies LLC, Alpharetta, GA, USA
- j. Lameness Locator®, Equinosis LLC, Columbia, MO, USA
- k. The Equinosis Q with Lameness Locator® User Manual 2017, Equinosis LLC, Columbia, MO, USA
- l. The Equinosis Q 2027 v1.1, Equinosis LLC, Columbia, MO, USA
- m. 0.27-Tesla Standing Equine MRI, Hallmarq Veterinary Imaging Inc., Acton, MA, USA
- n. Equine hoof receiver coil, Hallmarq Veterinary Imaging Inc., Acton, MA, USA
- o. Acepromazine, Acevet 25 Injectable, Vetoquinol, Lavaltrie, QC, Canada
- p. Stata®, StataCorp LP, College Station, TX.

CHAPTER SIX

GENERAL DISCUSSION

6.1 Introduction

Extracorporeal shock wave therapy (ESWT) was anecdotally thought to be a widely used treatment modality in equine practice, primarily for musculoskeletal injuries. The therapy has been shown to provide analgesia in some horses affected by caudal heel pain, but not all research in this regard has used proper controls or blinding (Bär et al., 2001; Blum, 2004; Dahlberg et al., 2006; McClure et al., 2004a). While analgesia is one aspect of a desirable treatment for caudal heel pain, the effect of the therapy on disease progression is important to guide clinical decision making. Caudal heel pain of the forelimbs in horses is accurately diagnosed with MRI (Parkes et al., 2015; Sampson et al., 2009), making MRI a useful tool to evaluate treatment effect (Werpy, 2012).

6.2 General Results and Future Studies

The goal of this research was to characterize the use of ESWT among equine practitioners in North America, and to determine the effect of ESWT on both the degree of lameness and the appearance of lesions diagnosed by MRI in horses with naturally occurring caudal heel pain.

The first specific aim, to characterize the use of ESWT in regard to frequency of use, diseases treated, and clinical opinion of therapy efficacy was determined by surveying a population of equine practitioners (n=144) (Chapter 4). Data showed that 45.1% of respondents used ESWT frequently, 42.4% of respondents use the therapy infrequently, and only 12.5% never used the modality in their practice. Use of ESWT was positively associated with the amount of equine work in the respondent's veterinary practice. Most respondents (94.4%) used ESWT to treat ligament injuries. Other types of injuries frequently treated with ESWT included tendon injuries (76.8% of respondents), muscle pain (63.2% of respondents), and osteoarthritis (51.2%). Caudal heel pain was treated by 27.2% of respondents. ESWT was viewed by respondents as a highly effective treatment option for ligament injuries and muscle pain management, but an ineffective treatment option for osteoarthritis and navicular syndrome. Non-response bias likely had an effect on the results of the survey. A low number of respondents was a factor in this limitation.

The second specific aim of this thesis was to determine the analgesic efficacy of focused ESWT as a treatment for horses with caudal heel pain (Chapter 5). The third specific aim of this thesis was to determine the effect of focused ESWT on the appearance of lesions diagnosed by

MRI in horses with naturally occurring caudal heel pain (Chapter 5). Analgesic efficacy was evaluated by change in subjectively evaluated lameness and change in kinematic gait analysis parameters. Effect on lesions was evaluated by change in lesion appearance on repeat MRI. ESWT was applied to the heel region of the horses in the treatment group at a dose of 1,500 shocks with an EFD of 0.28 mJ/mm² for 3 treatments. Data showed that unilaterally lame horses had improvement in subjectively evaluated lameness following treatment with ESWT, compared to the control group. Kinematic gait analysis was not useful for evaluating bilaterally lame horses, which limited the power of this portion of the analysis. Horses in the control group had improvement in navicular bursitis, while horses in the treatment group worsened.

The use of a naturally occurring disease was a factor in the limitations of Chapter 5. Inherent variability in degree of lameness and natural progression of the disease was impossible to control for in the study design. This, combined with intra-observer variability, affects the usefulness of repeated subjective lameness evaluation over time. Kinematic gait analysis was used to provide objective data regarding lameness improvement, but the unforeseen muting of asymmetry in bilaterally lame horses lead to a significant reduction in sample size and therefore, statistical power of the experiment.

Future studies using a larger sample size of unilaterally lame horses need to be conducted prior to recommending ESWT as a treatment option for all horses affected with caudal heel pain. Additionally, it would be useful to validate kinematic gait analysis as an objective lameness measurement tool for bilaterally lame horses. Investigation into the biochemical and molecular effects of ESWT in the caudal heel region may elucidate the mechanism of action of this therapy. Further surveys of equine practitioners regarding ESWT use should focus on specific doses used for different injuries to determine if practitioners are seeing a dose-dependent effect of the therapy. If results are informative, perhaps ESWT use could be optimized for caudal heel pain.

6.3 Conclusion

In conclusion, we have demonstrated that ESWT is used relatively commonly by equine practitioners, and that focused ESWT does not improve lesions associated with caudal heel pain when using an EFD of 0.28 mJ/mm², but may provide analgesia for some horses. Further research is required to evaluate alternative dosing protocols for ESWT and to determine the mechanism of action of ESWT.

REFERENCES

- Abed, J.M., McClure, S.R., Yaeger, M.J., Evans, R.B., 2007. P and calcitonin gene-related peptide in skin therapy and radial pressure wave therapy in sheep. *Am. J. Vet. Res.* 68, 323–328.
- Back, W., MacAllister, C.G., van Heel, M.C. V, Pollmeier, M., Hanson, P.D., 2009. The use of force plate measurements to titrate the dosage of a new COX-2 inhibitor in lame horses. *Equine Vet. J.* 41, 309–312.
- Bär, K., Weiler, M., Bodamer, J., Rupprecht, H., Schramm, M., Carbon, R., 2001. Extrakorporale Stoßwellentherapie (ESWT) eine Möglichkeit zur Therapie der Podotrochlose. *Tierärztl. Prax. Ausgabe G Grosstiere - Nutztiere* 29, 163–167.
- Barrett, M.F., Frisbie, D.D., King, M.R., Werpy, N.M., Kawcak, C.E., 2017. A review of how magnetic resonance imaging can aid in case management of common pathological conditions of the equine foot. *Equine Vet. Educ.* 29, 683–693.
- Baxter, G.M., Stashak, T.S., 2011a. History, Visual Exam, Palpation, and Manipulation, in: Baxter, G.M. (Ed.), *Adams and Stashak's Lameness in Horses*. Wiley-Blackwell, Chichester, West Sussex, UK, pp. 109–150.
- Baxter, G.M., Stashak, T.S., 2011b. Perineural and Intrasynovial Anesthesia, in: Baxter, G.M. (Ed.), *Adams and Stashak's Lameness in Horses*. Wiley-Blackwell, Chichester, West Sussex, UK, pp. 173–202.
- Baxter, G.M., Stashak, T.S., Belknap, J.K., Parks, A., 2011. The Foot, in: Baxter, G.M. (Ed.), *Adams and Stashak's Lameness in Horses*. Wiley-Blackwell, Chichester, West Sussex, UK, pp. 475–558.
- Bell, C.D., Howard, R.D., Taylor, D.S., Voss, E.D., Werpy, N.M., 2009. Outcomes of podotrochlear (navicular) bursa injections for signs of foot pain in horses evaluated via magnetic resonance imaging: 23 cases (2005–2007). *J. Am. Vet. Med. Assoc.* 234, 920–925.
- Biggi, M., Dyson, S., 2012. Distal border fragments and shape of the navicular bone: Radiological evaluation in lame horses and horses free from lameness. *Equine Vet. J.* 44, 325–331.
- Biggi, M., Dyson, S., 2011. High-field magnetic resonance imaging investigation of distal border fragments of the navicular bone in horses with foot pain. *Equine Vet. J.* 43, 302–308.

- Biggi, M., Dyson, S., 2010. Comparison between radiological and magnetic resonance imaging lesions in the distal border of the navicular bone with particular reference to distal border fragments and osseous cyst-like lesions. *Equine Vet. J.* 42, 707–712.
- Bischofberger, A.S., Ringer, S.K., Geyer, H., Imboden, I., Ueltschi, G., Lischer, C.J., 2006. Shock wave therapy of the fourth metatarsal in horses without lameness. *Am. J. Vet. Res.* 67, 577–582.
- Blum, N., 2004. Der Einsatz der Extrakorporalen Stoßwellentherapie (ESWT) zur Behandlung des Podotrochlose-Syndroms - Eine Untersuchung zur Wirksamkeit einer neuen Therapiemethode bei der Hufrollenerkrankung des Pferdes. Justus-Liebig-Universität Giessen Dekan:
- Blunden, A., Dyson, S., Murray, R., Schramme, M., 2006a. Histopathology in horses with chronic palmar foot pain and age-matched controls. Part 1: Navicular bone and related structures. *Equine Vet. J.* 38, 15–22.
- Blunden, A., Dyson, S., Murray, R., Schramme, M., 2006b. Histopathology in horses with chronic palmar foot pain and age-matched controls. Part 2: The deep digital flexor tendon. *Equine Vet. J.* 38, 23–27.
- Blunden, A., Murray, R., Dyson, S., 2009. Lesions of the deep digital flexor tendon in the digit: A correlative MRI and post mortem study in control and lame horses. *Equine Vet. J.* 41, 25–33.
- Bolen, G., Busoni, V., Jacqmot, O., Snaps, F., 2007. Sonographic anatomy of the palmarodistal aspect of the equine digit. *Vet. Radiol. Ultrasound* 48, 270–275.
- Bolt, D.M., Burba, D.J., Hubert, J.D., Pettifer, G.R., Hosgood, G.L., 2004a. Evaluation of cutaneous analgesia after non-focused extracorporeal shock wave application over the 3rd metacarpal bone in horses. *Can. J. Vet. Res.* 68, 288–292.
- Bolt, D.M., Burba, D.J., Hubert, J.D., Strain, G.M., Hosgood, G.L., Henk, W.G., Cho, D.Y., 2004b. Determination of functional and morphologic changes in palmar digital nerves after nonfocused extracorporeal shock wave treatment in horses. *Am. J. Vet. Res.* 65, 1714–1718.
- Bos, H., van der Meij, G.J., Dik, K.J., 1986. Heredity of navicular disease. *Vet. Q.* 8, 68–72.
- Bosch, G., de Mos, M., van Binsbergen, R. V., van Schie, H.T.M., van de Lest, C.H.A., van Weeren, P.R., 2009. The effect of focused extracorporeal shock wave therapy on collagen matrix and gene expression in normal tendons and ligaments. *Equine Vet. J.* 41, 335–341.

- Bosch, G., Lin, Y.L., Van Schie, H.T.M., Van De Lest, C.H.A., Barneveld, A., Van Weeren, P.R., 2007. Effect of extracorporeal shock wave therapy on the biochemical composition and metabolic activity of tenocytes in normal tendinous structures in ponies. *Equine Vet. J.* 39, 226–231.
- Bosch, G., Moleman, M., Barneveld, A., van Weeren, P.R., van Schie, H.T.M., 2011. The effect of platelet-rich plasma on the neovascularization of surgically created equine superficial digital flexor tendon lesions. *Scand. J. Med. Sci. Sport.* 21, 554–561.
- Bowker, R.M., 2003. Contrasting structural morphologies of “good” and “bad” footed horses. *AAEP Proc.* 49, 186–209.
- Bowker, R.M., Atkinson, P.J., Atkinson, T.S., Haut, R.C., 2001. Effect of contact stress in bones of the distal interphalangeal joint on microscopic changes in articular cartilage and ligaments. *Am. J. Vet. Res.* 62, 414–424.
- Bowker, R.M., Linder, K., Van Wulfen, K.K., Sonea, I.M., 1997. Anatomy of the distal interphalangeal joint of the mature horse: Relationships with navicular suspensory ligaments, sensory nerves and neurovascular bundle. *Equine Vet. J.* 29, 126–135.
- Bowker, R.M., Wulfen, K.K. Van, Springer, S.E., Linder, K.E., 1998. Functional anatomy of the cartilage of the distal phalanx and digital cushion in the equine foot and a hemodynamic flow hypothesis of energy dissipation. *Am. J. Vet. Res.* 961–968.
- Brown, K.E., Nickels, F.A., Caron, J.P., Mullineaux, D.R., Clayton, H.M., 2005. Investigation of the immediate analgesic effects of extracorporeal shock wave therapy for treatment of navicular disease in horses. *Vet. Surg.* 34, 554–558.
- Busoni, V., Denoix, J., 2001. Ultrasonography of the podotrochlear apparatus in the horse using a transcuneal approach: Technique and reference images. *Vet. Radiol. Ultrasound* 42, 534–540.
- Busoni, V., Heimann, M., Trenteseaux, J., Snaps, F., Dondelinger, R.F., 2005. Magnetic resonance imaging findings in the equine deep digital flexor tendon and distal sesamoid bone in advanced navicular disease - An ex vivo study. *Vet. Radiol. Ultrasound* 46, 279–286.
- Byron, C., Stewart, A., Benson, B., Tennent-Brown, B., Foreman, J., 2009. Effects of radial extracorporeal shock wave therapy on radiographic and scintigraphic outcomes in horses with palmar heel pain. *Vet. Comp. Orthop. Traumatol.* 22, 113–118.

- Caminoto, E.H., Alves, A.L.G., Amorim, R.L., Thomassian, A., Hussni, C.A., Nicoletti, J.L.M., 2005. Ultrastructural and immunocytochemical evaluation of the effects of extracorporeal shock wave treatment in the hind limbs of horses with experimentally induced suspensory ligament desmitis. *Am. J. Vet. Res.* 66, 892–896.
- Cárcamo, J.J., Aliaga, A.E., Clavijo, R.E., Brañes, M.R., Campos-Vallette, M.M., 2012. Raman study of the shockwave effect on collagens. *Spectrochim. Acta - Part A Mol. Biomol. Spectrosc.* 86, 360–365.
- Chamberlain, G. A, Colborne, G.R., 2016. A review of the cellular and molecular effects of extracorporeal shockwave therapy. *Vet. Comp. Orthop. Traumatol.* 29, 99–107.
- Chen, T.W., Lin, C.W., Lee, C.L., Chen, C.H., Chen, Y.J., Lin, T.Y., Huang, M.H., 2014. The efficacy of shock wave therapy in patients with knee osteoarthritis and popliteal cyamella. *Kaohsiung J. Med. Sci.* 30, 362–370.
- Chow, I.H.W., Cheing, G.L.Y., 2007. Comparison of different energy densities of extracorporeal shock wave therapy (ESWT) for the management of chronic heel pain. *Clin. Rehabil.* 21, 131–141.
- Chung, B., Wiley, J.P., 2002. Extracorporeal shockwave therapy: A review. *Sport. Med* 32, 851–865.
- Cillán-García, E., Milner, P.I., Talbot, A., Tucker, R., Hendey, F., Boswell, J., Reardon, R.J.M., Taylor, S.E., 2013. Deep digital flexor tendon injury within the hoof capsule; does lesion type or location predict prognosis? *Vet. Rec.* 173, 70–70.
- Claerhoudt, S., Bergman, E.H.J., Van Der Veen, H., Vanderperren, K., Raes, E. V., Saunders, J.H., 2011. Computed tomographic morphology of the synovial invaginations of the distal sesamoid bone of the horse. *J. Vet. Med. Ser. C Anat. Histol. Embryol.* 40, 55–60.
- Colles, C.M., Hickman, J., 1977. The arterial supply of the navicular bone and its variations in navicular disease. *Equine Vet. J.* 9, 150–154.
- Crowe, O.M., Dyson, S.J., Wright, I.M., Schramme, M.C., Smith, R.K.W., 2004. Treatment of chronic or recurrent proximal suspensory desmitis using radial pressure wave therapy in the horse. *Equine Vet. J.* 36, 313–316.
- Da Costa Gómez, T.M., Radtke, C.L., Kalscheur, V.L., Swain, C.A., Scollay, M.C., Edwards, R.B., Santschi, E.M., Markel, M.D., Muir, P., 2004. Effect of focused and radial extracorporeal shock wave therapy on equine bone microdamage. *Vet. Surg.* 33, 49–55.

- Dabareiner, R.M., Carter, G.K., 2003. Diagnosis, treatment, and farriery for horses with chronic heel pain. *Vet. Clin. North Am. - Equine Pract.* 19, 417–441.
- Dabareiner, R.M., Carter, G.K., Honnas, C.M., 2003. Injection of corticosteroids, hyaluronate, and amikacin into the navicular bursa in horses with signs of navicular area pain unresponsive to other treatments: 25 cases (1999-2002). *J. Am. Vet. Med. Assoc.* 223, 1469–1474.
- Dahlberg, J.A., McClure, S.R., Evans, R.B., Reinertson, E.L., 2006. Force platform evaluation of lameness severity following extracorporeal shock wave therapy in horses with unilateral forelimb lameness. *J. Am. Vet. Med. Assoc.* 229, 100–103.
- Dahlgren, L.A., Mohammed, H.O., Nixon, A.J., 2005. Temporal expression of growth factors and matrix molecules in healing tendon lesions. *J. Orthop. Res.* 23, 84–92.
- Daniel, A.J., Goodrich, L.R., Barrett, M.F., Werpy, N.M., Morley, P.S., McIlwraith, C.W., 2016. An optimised injection technique for the navicular bursa that avoids the deep digital flexor tendon. *Equine Vet. J.* 48, 159–164.
- Dargatz, D.A., Hill, G.W., 1996. Analysis of survey data. *Prev. Vet. Med.* 28, 225–237.
- de Grauw, J.C. d., Visser-Meijer, M.C., Lashley, F., Meeus, P., van Weeren, P.R., 2016. Intra-articular treatment with triamcinolone compared with triamcinolone with hyaluronate: A randomised open-label multicentre clinical trial in 80 lame horses. *Equine Vet. J.* 48, 152–158.
- de Grauw, J.C., van Loon, J.P.A.M., 2016. Systematic pain assessment in horses. *Vet. J.* 209, 14–22.
- Denoix, J., Thibaud, D., Riccio, B., 2003. Tiludronate as a new therapeutic agent in the treatment of navicular disease : a double-blind placebo-controlled clinical trial. *Equine Vet. J.* 35, 407–413.
- Dik, K.J., van den Belt, a J., van den Broek, J., 2001a. Relationships of age and shape of the navicular bone to the development of navicular disease: a radiological study. *Equine Vet. J.* 33, 172–5.
- Dik, K.J., van den Belt, A.J.M., Enzerink, E., van Weeren, P.R., 2001b. The radiographic development of the distal and proximal double contours of the equine navicular bone on dorsoproximal-palmarodistal oblique (upright pedal) radiographs, from age 1 to 11 months. *Equine Vet. J.* 33, 70–74.

- Dik, K.J., van den Broek, J., 1995. Role of navicular bone shape in the pathogenesis of navicular disease: a radiological study. *Equine Vet. J.* 27, 390–393.
- Donnell, J.R., Frisbie, D.D., King, M.R., Goodrich, L.R., Haussler, K.K., 2015. Comparison of subjective lameness evaluation, force platforms and an inertial-sensor system to identify mild lameness in an equine osteoarthritis model. *Vet. J.* 206, 136–142.
- Dowling, B.A., Dart, A.J., Hodgson, D.R., Smith, R.K.W., 2000. Superficial digital flexor tendonitis in the horse. *Equine Vet. J.* 32, 369–378.
- Dunkel, B., Pfau, T., Fiske-Jackson, A., Veres-Nyeki, K.O., Fairhurst, H., Jackson, K., Chang, Y.M., Bolt, D.M., 2017. A pilot study of the effects of acupuncture treatment on objective and subjective gait parameters in horses. *Vet. Anaesth. Analg.* 44, 154–162.
- Dyson, S.J., 2011a. Can lameness be graded reliably? *Equine Vet. J.* 43, 379–382.
- Dyson, S.J., 2011b. Radiological interpretation of the navicular bone. *Equine Vet. Educ.* 23, 73–87.
- Dyson, S.J., 2008. Radiological interpretation of the navicular bone. *Equine Vet. Educ.* 20, 268–280.
- Dyson, S.J., 2002. Subjective and quantitative scintigraphic assessment of the equine foot and its relationship with foot pain. *Equine Vet. J.* 34, 164–170.
- Dyson, S.J., Blunden, T., Murray, R., 2012. Comparison between magnetic resonance imaging and histological findings in the navicular bone of horses with foot pain. *Equine Vet. J.* 44, 692–698.
- Dyson, S.J., Kidd, L., 2003. A comparison of responses to analgesia of the navicular bursa and intra-articular analgesia of the distal interphalangeal joint in 59 horses. *Equine Vet. J.* 25, 93–98.
- Dyson, S.J., Murray, R., 2007a. Magnetic resonance imaging evaluation of 264 horses with foot pain: The podotrochlear apparatus, deep digital flexor tendon and collateral ligaments of the distal interphalangeal joint. *Equine Vet. J.* 39, 340–343.
- Dyson, S.J., Murray, R., 2007b. Verification of scintigraphic imaging for injury diagnosis in 264 horses with foot pain. *Equine Vet. J.* 39, 350–355.
- Dyson, S.J., Murray, R., 2007c. Use of concurrent scintigraphic and magnetic resonance imaging evaluation to improve understanding of the pathogenesis of injury of the podotrochlear apparatus. *Equine Vet. J.* 39, 365–369.

- Dyson, S.J., Murray, R., Schramme, M., Branch, M., 2003. Lameness in 46 horses associated with deep digital flexor tendonitis in the digit: diagnosis confirmed with magnetic resonance imaging. *Equine Vet. J.* 35, 681–690.
- Dyson, S.J., Murray, R., Schramme, M.C., 2005. Lameness associated with foot pain: results of magnetic resonance imaging in 199 horses (January 2001-December 2003) and response to treatment. *Equine Vet. J.* 37, 113–121.
- Dyson, S.J., Murray, R.C., Schramme, M., Blunden, T., 2011a. Current concepts of navicular disease. *Equine Vet. Educ.* 23, 27–39.
- Dyson, S.J., Tranquille, C.A., Collins, S.N., Parkin, T.D.H., Murray, R.C., 2011b. An investigation of the relationships between angles and shapes of the hoof capsule and the distal phalanx. *Equine Vet. J.* 43, 295–301.
- Eggleston, R.B., 2012. Equine imaging: The framework for applying therapeutic farriery. *Vet. Clin. North Am. - Equine Pract.* 28, 293–312.
- Eliashar, E., 2007. An evidence-based assessment of the biomechanical effects of the common shoeing and farriery techniques. *Vet. Clin. North Am. - Equine Pract.* 23, 425–442.
- Eliashar, E., McGuigan, M.P., Rogers, K. A., Wilson, A. M., 2002. A comparison of three horseshoeing styles on the kinetics of breakover in sound horses. *Equine Vet. J.* 34, 184–190.
- Eliashar, E., McGuigan, M.P., Wilson, A. M., 2004. Relationship of foot conformation and force applied to the navicular bone of sound horses at the trot. *Equine Vet. J.* 36, 431–435.
- Erkert, R.S., MacAllister, C.G., 2002. Isoxsuprine hydrochloride in the horse: A review. *J. Vet. Pharmacol. Ther.* 25, 81–87.
- Erkert, R.S., MacAllister, C.G., Payton, M.E., Clarke, C.R., 2005. Use of force plate analysis to compare the analgesic effects of intravenous administration of phenylbutazone and flunixin meglumine in horses with navicular syndrome. *Am. J. Vet. Res.* 66, 284–288.
- Ferris, D.J., Frisbie, D.D., McIlwraith, C.W., Kawcak, C.E., 2011. Current joint therapy usage in equine practice: A survey of veterinarians 2009. *Equine Vet. J.* 43, 530–535.
- Frevel, M., King, B., Kolb, D., Boswell, R., Shoemaker, R.S., Janicek, J., Cole, R., Poole, M., Longhofer, S., 2014. Multi-centre field trial to evaluate the effectiveness of clodronic acid for navicular syndrome. *Equine Vet. J.* 46, 5–6.
- Fricker, C., Riek, W., Hugleshofer, J., 1982. Occlusion of the digital arteries - A model for

- pathogenesis of navicular disease. *Equine Vet. J.* 14, 203–207.
- Frisbie, D.D., Kawcak, C.E., McIlwraith, C.W., 2009. Evaluation of the effect of extracorporeal shock wave treatment on experimentally induced osteoarthritis in middle carpal joints of horses. *Am. J. Vet. Res.* 70, 449–454.
- Frisbie, D.D., Kawcak, C.E., Trotter, G.W., Powers, B.E., Walton, R.M., McIlwraith, C.W., 1997. Effects of triamcinolone acetonide on an in vivo equine osteochondral fragment exercise model. *Equine Vet. J.* 29, 349–359.
- Fuller, C.J., Bladon, B.M., Driver, A.J., Barr, A.R.S., 2006. The intra- and inter-assessor reliability of measurement of functional outcome by lameness scoring in horses. *Vet. J.* 171, 281–286.
- Gabriel, A., Jolly, S., Detilleux, J., Dessy-Doize, C., Collin, B., Reginster, J.-Y., 1998. Morphometric study of the equine navicular bone : variations with breeds and types of horse and influence of exercise. *J. Anat.* 193, 535–549.
- Gotte, G., Amelio, E., Russo, S., Marlinghaus, E., Musci, G., Suzuki, H., 2002. Short-time non-enzymatic nitric oxide synthesis from L-arginine and hydrogen peroxide induced by shock waves treatment. *FEBS Lett.* 520, 153–155.
- Graff, J., Pastor, J., Senge, T., Richter, K.D., Runke, W., 1987. The effect of high energy shock waves on bony tissue - An experimental study. *J. Urol.* 137, 278A.
- Groth, A.M., May, S.A., Weaver, M.P., Weller, R., 2009. Intra- and interobserver agreement in the interpretation of navicular bones on radiographs and computed tomography scans. *Equine Vet. J.* 41, 124–129.
- Gunkelman, M.A., Hammer, C.J., 2017. A Preliminary Study Examining the Digital Cushion in Horses. *J. Equine Vet. Sci.* 56, 6–8.
- Gutierrez-Nibeyro, S., Werpy, N., White, N., 2012. Standing low-field magnetic resonance imaging in horses with chronic foot pain. *Aust. Vet. J.* 90, 75–83.
- Gutierrez-Nibeyro, S.D., Santos, M.P., White, N.A., Brown, J.A., Adams, M.N., McKnight, A.L., Schaeffer, D.J., 2014. Effects of intrabursal administration of botulinum toxin type B on lameness in horses with degenerative injury to the podotrochlear apparatus. *Am. J. Vet. Res.* 75, 282–289.
- Gutierrez-Nibeyro, S.D., Werpy, N.M., White, N.A., Mitchell, M.A., Edwards, R.B., Mitchell, R.D., Gold, S.J., Allen, A.K., 2015. Outcome of palmar/plantar digital neurectomy in horses

- with foot pain evaluated with magnetic resonance imaging: 50 cases (2005-2011). *Equine Vet. J.* 47, 160–164.
- Gutierrez-Nibeyro, S.D., White, N.A., Werpy, N.M., 2010. Outcome of medical treatment for horses with foot pain: 56 cases. *Equine Vet. J.* 42, 680–685.
- Haake, M., Thon, A., Bette, M., 2002. No influence of low-energy extracorporeal shock wave therapy (ESWT) on spinal nociceptive systems. *J. Orthop. Sci.* 7, 97–101.
- Haupt, G., 1997. Use of Extracorporeal Shock Waves in the Treatment of Pseudarthrosis, Tendinopathy and Other Orthopedic Diseases. *J. Urol.* 158, 4–11.
- Hewetson, M., Christley, R.M., Hunt, I.D., Voute, L.C., 2006. Investigations of the reliability of observational gait analysis for the assessment of lameness in horses. *Vet. Rec.* 158, 852–858.
- Hutchison, J., Tollefson, N., Wigington, H., 1987. Response bias in college freshmen's responses to mail surveys. *Res. High. Educ.* 26, 99–106.
- Ingle-Fehr, J.E., Baxter, G.M., 1999. The effect of oral isoxsuprine and pentoxifylline on digital and laminar blood flow in healthy horses. *Vet. Surg.* 28, 154–160.
- Jackman, B.R., Baxter, G.M., Doran, R.E., Allen, D., Parks, A.H., 1993. Palmar digital neurectomy in horses 57 Cases (1984-1990). *Vet. Surg.* 22, 285–288.
- Jenner, F., Kirker-Head, C., 2011. Core decompression of the equine navicular bone: An in vitro biomechanical study. *Vet. Surg.* 40, 163–170.
- Kainer, R.A., Fails, A.D., 2011. Functional Anatomy of the Equine Musculoskeletal System, in: Baxter, G.M. (Ed.), *Adams and Stashak's Lameness in Horses*. Wiley-Blackwell, Chichester, West Sussex, UK, pp. 3–72.
- Kawcak, C.E., Frisbie, D.D., McIlwraith, C.W., 2011. Effects of extracorporeal shock wave therapy and polysulfated glycosaminoglycan treatment on subchondral bone, serum biomarkers, and synovial fluid biomarkers in horses with induced osteoarthritis. *Am. J. Vet. Res.* 72, 772–779.
- Keegan, K.G., 2011. Objective Assessment of Lameness, in: Baxter, G.M. (Ed.), *Adams and Stashak's Lameness in Horses*. Wiley-Blackwell, Chichester, West Sussex, UK, pp. 154–164.
- Keegan, K.G., Dent, E. V., Wilson, D.A., Janicek, J., Kramer, J., Lacarrubba, A., Walsh, D.M., Cassells, M.W., Esther, T.M., Schiltz, P., Frees, K.E., Wilhite, C.L., Clark, J.M., Pollitt,

- C.C., Shaw, R., Norris, T., 2010. Repeatability of subjective evaluation of lameness in horses. *Equine Vet. J.* 42, 92–97.
- Keegan, K.G., Kramer, J., Yonezawa, Y., Maki, H., Pai, P.F., Dent, E. V, Kellerman, T.E., Wilson, D.A., Reed, S.K., 2011. Assessment of repeatability of a wireless, inertial sensor-based lameness evaluation system for horses. *Am. J. Vet. Res.* 72, 1156–1163.
- Keegan, K.G., MacAllister, C.G., Wilson, D.A., Gedon, C.A., Kramer, J., Yonezawa, Y., Maki, H., Frank Pai, P., 2012. Comparison of an inertial sensor system with a stationary force plate for evaluation of horses with bilateral forelimb lameness. *Am. J. Vet. Res.* 73, 368–374.
- Keegan, K.G., Wilson, D.A., Kramer, J., Reed, S.K., Yonezawa, Y., Maki, H., Pai, P.F., Lopes, M.A.F., 2013. Comparison of a body-mounted inertial sensor system-based method with subjective evaluation for detection of lameness in horses. *Am. J. Vet. Res.* 74, 17–24.
- Kersh, K.D., McClure, S., Evans, R.B., Moran, L., 2006. The evaluation of extracorporeal shock wave therapy on collagenase-induced superficial digital flexor tendonitis. *Vet. Comp. Orthop. Traumatol.* 19, 99–105.
- Kim, J.H., Kim, J.Y., Choi, C.M., Lee, J.K., Kee, H.S., Jung, K.I., Yoon, S.R., 2015. The dose-related effects of extracorporeal shock wave therapy for knee osteoarthritis. *Ann. Rehabil. Med.* 39, 616–623.
- Leeman, J.J., Shaw, K.K., Mison, M.B., Perry, J.A., Carr, A., Shultz, R., 2016. Extracorporeal shockwave therapy and therapeutic exercise for supraspinatus and biceps tendinopathies in 29 dogs. *Vet. Rec.* 179.
- Lutter, J.D., Schneider, R.K., Sampson, S.N., Cary, J.A., Roberts, G.D., Vahl, C.I., 2015. Medical treatment of horses with deep digital flexor tendon injuries diagnosed with high-field-strength magnetic resonance imaging: 118 cases (2000–2010). *J. Am. Vet. Med. Assoc.* 247, 1309–1318.
- Macgregor, C.M., 1984. Studies on the pathology and treatment of equine navicular disease. Royal (Dick) School of Veterinary Studies, University of Edinburg.
- Maher, M.C., Werpy, N.M., Goodrich, L.R., McIlwraith, C.W., 2011. Positive contrast magnetic resonance bursography for assessment of the navicular bursa and surrounding soft tissues. *Vet. Radiol. Ultrasound* 52, 385–393.
- Maher, O., Davis, D.M., Drake, C., Myhre, G.D., Labbe, K.M., Han, J.H., Lejeune, S.S., 2008. Pull-through technique for palmar digital neurectomy: Forty-one horses (1998-2004). *Vet.*

- Surg. 37, 87–93.
- Mählmann, K., Koch, C., Bodó, G., 2015. Diagnostic endoscopy of the navicular bursa using a needle endoscope by direct or transthecal approach: A comparative cadaver study. *Vet. Surg.* 44, 816–824.
- Maier, M., Averbek, B., Milz, S., Refior, H., Schmitz, C., 2003. Substance P and Prostaglandin E2 release after shock wave application to the rabbit femure. *Clin. Orthop. Relat. Res.* 237–245.
- Maier, M., Tischer, T., Milz, S., Weiler, C., Nerlich, A., Pellengahr, C., Schmitz, C., Refior, H.J., 2002. Dose-related effects of extracorporeal shock waves on rabbit quadriceps tendon integrity. *Arch. Orthop. Trauma Surg.* 122, 436–441.
- Mani-Babu, S., Morrissey, D., Waugh, C., Screen, H., Barton, C., 2015. The effectiveness of extracorporeal shock wave therapy in lower limb tendinopathy: A systematic review. *Am. J. Sports Med.*
- Mariotto, S., de Prati, A.C., Cavalieri, E., Amelio, E., Marlinghaus, E., Suzuki, H., 2009. Extracorporeal shock wave therapy in inflammatory diseases: molecular mechanism that triggers anti-inflammatory action. *Curr. Med. Chem.* 16, 2366–2372.
- Marsh, C.A., Schneider, R.K., Sampson, S.N., Roberts, G.D., 2012. Response to injection of the navicular bursa with corticosteroid and hyaluronan following high-field magnetic resonance imaging in horses with signs of navicular syndrome: 101 Cases (2000-2008). *J. Am. Vet. Med. Assoc.* 241, 1353–1364.
- Martini, L., Giavaresi, G., Fini, M., Torricelli, P., de Pretto, M., Schaden, W., Giardino, R., 2003. Effect of extracorporeal shock wave therapy on osteoblastlike cells. *Clin. Orthop. Relat. Res.* 413, 269–280.
- McCarroll, G.D., McClure, S.R., 2000. Extracorporeal shock wave therapy for treatment of osteoarthritis of the tarsometatarsal and distal intertarsal joints of the horse, in: *Proceedings of the American Association of Equine Practitioners.* pp. 200–202.
- McClure, S.R., Dorfmueller, C., 2003. Extracorporeal shock wave therapy: Theory and equipment. *Clin. Tech. Equine Pract.* 2, 348–357.
- McClure, S.R., Evans, R.B., Miles, K.G., Reinertson, E.L., Hawkins, J.F., Honnas, C.M., 2004a. Extracorporeal shock wave therapy for treatment of navicular syndrome, in: *Proceedings of the American Association of Equine Practitioners.* pp. 316–319.

- McClure, S.R., Sonea, I.M., Evans, R.B., Yaeger, M.J., 2005. Evaluation of analgesia resulting from extracorporeal shock wave therapy and radial pressure wave therapy in the limbs of horses and sheep. *Am. J. Vet. Res.* 66.
- McClure, S.R., Van Sickle, D., White, M.R., 2004b. Effects of extracorporeal shock wave therapy on bone. *Vet. Surg.* 33, 40–48.
- McClure, S.R., VanSickle, D., Evans, R., Reinertson, E.L., Moran, L., 2004c. The effects of extracorporeal shock-wave therapy on the ultrasonographic and histologic appearance of collagenase-induced equine forelimb suspensory ligament desmitis. *Ultrasound Med. Biol.* 30, 461–467.
- McCracken, M.J., Kramer, J., Keegan, K.G., Lopes, M., Wilson, D.A., Reed, S.K., Lacarrubba, A., Rasch, M., 2012. Comparison of an inertial sensor system of lameness quantification with subjective lameness evaluation. *Equine Vet. J.* 44, 652–656.
- McGuigan, M.P., Wilson, A.M., 2001. The effect of bilateral palmar digital nerve analgesia on the compressive force experienced by the navicular bone in horses with navicular disease. *Equine Vet. J.* 33, 166–71.
- McIlwraith, C.W., 2010. The use of intra-articular corticosteroids in the horse: What is known on a scientific basis? *Equine Vet. J.* 42, 563–571.
- McLellan, J., 2017. Bisphosphonate use in the racehorse: Safe or unsafe? *Equine Vet. J.* 49, 404–407.
- Mitchell, J.S., 2012. Lameness and performance evaluation in ambulatory practice. *Vet. Clin. North Am. - Equine Pract.* 28, 101–115.
- Moleman, M., van Heel, M.C.V., van Weeren, P.R., Back, W., 2006. Hoof growth between two shoeing sessions leads to a substantial increase of the moment about the distal, but not the proximal, interphalangeal joint. *Equine Vet. J.* 38, 170–174.
- Moorman, V.J., Frisbie, D.D., Kawcak, C.E., McIlwraith, C.W., 2017. Effects of sensor position on kinematic data obtained with an inertial sensor system during gait analysis of trotting horses. *J. Am. Vet. Med. Assoc.* 250, 548–553.
- Morgan, D.D., McClure, S., Yaeger, M.J., Schumacher, J., Evans, R.B., 2009. Effects of extracorporeal shock wave therapy on wounds of the distal portion of the limbs in horses. *J. Am. Vet. Med. Assoc.* 234, 1154–1161.
- Moses, V.S., Bertone, Alicia, L., 2002. Nonsteroidal anti-inflammatory drugs. *Vet. Clin. North*

- Am. - Equine Pract. 18, 21–37.
- Murray, R.C., Blunden, T.S., Schramme, M.C., Dyson, S.J., 2006a. How does magnetic resonance imaging represent histologic findings in the equine digit? *Vet. Radiol. Ultrasound* 47, 17–31.
- Murray, R.C., Schramme, M.C., Dyson, S.J., Branch, M. V., Blunden, T.S., 2006b. Magnetic resonance imaging characteristics of the foot in horses with palmar foot pain and control horses. *Vet. Radiol. Ultrasound* 47, 1–16.
- Ogden, J.A., Tóth-kischkat, A., Schultheiss, R., 2001. Principles of shockwave therapy. *Clin. Orthop. Relat. Res.* 8–17.
- Olive, J., Videau, M., 2017. Distal border synovial invaginations of the equine distal sesamoid bone communicate with the distal interphalangeal joint. *Vet. Comp. Orthop. Traumatol.* 30, 107–110.
- Orhan, Z., Cam, K., Alper, M., Ozturan, K., 2004. The effects of extracorporeal shock waves on the rat Achilles tendon: Is there a critical dose for tissue injury? *Arch. Orthop. Trauma Surg.* 124, 631–635.
- Østblom, L., Lund, C., Melsen, F., 1982. Histological study of navicular bone disease. *Equine Vet. J.* 14, 199–202.
- Palmer, S.E., 2002. Treatment of dorsal metacarpal disease in the Thoroughbred racehorse with radial extracorporeal shock wave therapy, in: *Proceedings of the American Association of Equine Practitioners.* pp. 318–321.
- Parkes, R.S., Newton, R., Dyson, S.J., 2015. Is there an association between clinical features, response to diagnostic analgesia and radiological findings in horses with a magnetic resonance imaging diagnosis of navicular disease or other injuries of the podotrochlear apparatus? *Vet. J.* 204, 40–46.
- Pauwels, F.E.T., McClure, S.R., Amin, V., Van Sickle, D., Evans, R.B., 2004. Effects of extracorporeal shock wave therapy and radial pressure wave therapy on elasticity and microstructure of equine cortical bone. *Am. J. Vet. Res.* 65, 207–212.
- Pilsworth, R., Dyson, S.J., 2015. Where does it hurt? Problems with interpretation of regional and intra-synovial diagnostic analgesia. *Equine Vet. Educ.* 27, 595–603.
- Pleasant, R.S., Baker, G.J., Foreman, J.H., Eurell, J.A.C., Losonsky, J.M., 1993. Intraosseous pressure and pathologic changes in horses with navicular disease. *Am. J. Vet. Res.* 54, 7–12.

- Pleasant, S., Moll, H.D., Ley, W., Lessard, P., Warnick, L., 1997. Intra-articular anesthesia of the distal interphalangeal joint alleviates lameness associated with the navicular bursa in horses. *Vet. Surg.* 26, 137–140.
- Pool, R.R., Meagher, D.M., Stover, S.M., 1989. Pathophysiology of navicular syndrome. *Vet. Clin. North Am. Equine Pract.* 5, 109–129.
- Redden, R.F., 2003. Radiographic imaging of the equine foot. *Vet. Clin. North Am. - Equine Pract.*
- Revenaugh, M.S., 2005. Extracorporeal shock wave therapy for treatment of osteoarthritis in the horse: Clinical applications. *Vet. Clin. North Am. - Equine Pract.* 21, 609–625.
- Rijkenhuizen, A., 2006. Navicular disease: A review of what's new. *Equine Vet. J.* 38, 00–00.
- Rijkenhuizen, A., Nemeth, F., Dik, K.J., Goedegebuure, S.A., 1989a. The arterial supply of the navicular bone in the normal horse. *Equine Vet. J.* 21, 399–404.
- Rijkenhuizen, A., Nemeth, F., Dik, K.J., Goedegebuure, S.A., 1989b. The arterial supply of the navicular bone in adult horses with navicular disease. *Equine Vet. J.* 21, 418–424.
- Rijkenhuizen, A., Nemeth, F., Dik, K.J., Goedegebuure, S.A., Van Den Brom, W.E., 1989c. The effect of unilateral resection of segments of both palmar digital arteries on the navicular bone in ponies: An experimental study. *Equine Vet. J.* 21, 413–417.
- Robinson, K.A., Manning, S.T., 2015. Efficacy of a single-formula acupuncture treatment for horses with palmar heel pain. *Can. Vet. J.* 56, 1257–1260.
- Romeo, P., Lavanga, V., Pagani, D., Sansone, V., 2013. Extracorporeal shock wave therapy in musculoskeletal disorders: A review. *Med. Princ. Pract.*
- Rompe, J.D., Kirkpatrick, C.J., Küllmer, K., Schwitalle, M., Krischek, O., 1998. Dose-related effects of shock waves on rabbit tendo Achillis: A sonographic and histological study. *J. Bone Jt. Surg.* 80, 546–552.
- Sampson, S.N., Schneider, R.K., Gavin, P.R., 2008. Magnetic resonance imaging findings in horses with recent and chronic bilateral forelimb lameness diagnosed as navicular syndrome. *Proc. Am. Assoc. Equine Pract.* 54, 419–434.
- Sampson, S.N., Schneider, R.K., Gavin, P.R., Baszler, T. V., Mealey, R.H., Zubrod, C.J., Marsh, C.A., 2010. Evaluation of an arthroscopic approach for transection of the equine collateral sesamoidean ligament. *Vet. Surg.* 39, 1011–1020.
- Sampson, S.N., Schneider, R.K., Gavin, P.R., Ho, C.P., Tucker, R.L., Charles, E.M., 2009.

- Magnetic resonance imaging findings in horses with recent onset navicular syndrome but without radiographic abnormalities. *Vet. Radiol. Ultrasound* 50, 339–346.
- Sax, L.J., Gilmartin, S.K., Bryant, A.N., 2003. Assessing response rate and nonresponse bias in web and paper surveys. *Res. High. Educ.* 44, 409–432.
- Schaden, W., Fischer, A., Sailer, A., 2001. Extracorporeal shock wave therapy of nonunion or delayed osseous union. *Clin. Orthop. Relat. Res.* 387, 90–94.
- Schoonover, M.J., Jann, H.W., Blaik, M.A., 2005. Quantitative comparison of three commonly used treatments for navicular syndrome in horses. *Am. J. Vet. Res.* 66, 1247–1251.
- Schramme, M.C., 2011. Deep digital flexor tendonopathy in the foot. *Equine Vet. Educ.* 23, 403–415.
- Schumacher, J., de Graves, F., Steiger, R., Schramme, M., Smith, R., Coker, M., 2001a. A comparison of the effects of two volumes of local analgesic solution in the distal interphalangeal joint of horses with lameness caused by solar toe or solar heel pain. *Equine Vet. J.* 33, 265–8.
- Schumacher, J., Schramme, M.C., Schumacher, J., Degraives, F.J., 2013. Diagnostic analgesia of the equine digit. *Equine Vet. Educ.* 25, 408–421.
- Schumacher, J., Schumacher, J., de Graves, F., Schramme, M., Smith, R., Coker, M., Steiger, R., 2001b. A comparison of the effects of two volumes of local analgesic solution in the navicular bursa of horses with lameness caused by solar toe or solar heel pain. *Equine Vet. J.* 33, 265–8.
- Schumacher, J., Schumacher, J., Gillette, R., DeGraves, F., Schramme, M., Smith, R., Perkins, J., Coker, M., 2003. The effects of local anaesthetic solution in the navicular bursa of horses with lameness caused by distal interphalangeal joint pain. *Equine Vet. J.* 35, 502–505.
- Sherlock, C., Mair, T., Blunden, T., 2008. Deep erosions of the palmar aspect of the navicular bone diagnosed by standing magnetic resonance imaging. *Equine Vet. J.* 40, 684–692.
- Smith, M.R.W., Wright, I.M., 2012. Endoscopic evaluation of the navicular bursa: Observations, treatment and outcome in 92 cases with identified pathology. *Equine Vet. J.* 44, 339–345.
- Smith, R.K.W., Zunino, L., Webbon, P.M., Heinegård, D., 1997. The distribution of cartilage oligomeric matrix protein (COMP) in tendon and its variation with tendon site, age and load. *Matrix Biol.* 16, 255–271.
- Soto, S.A., Chiappe Barabará, A., 2014. Bisphosphonates: Pharmacology and clinical approach to

- their use in equine osteoarticular diseases. *J. Equine Vet. Sci.* 34, 727–737.
- Steiss, J.E., White, N.A., Bowen, J.M., 1989. Electroacupuncture in the treatment of chronic lameness in horses and ponies: a controlled clinical trial. *Can. J. Vet. Res.* 53, 239–243.
- Svalastoga, E., Smith, M., 1983. Navicular disease in the horse The subchondral bone pressure. *Nord. Vet. Med.* 35, 31–37.
- Swanson, T.D., 1984. *Guide for Veterinary Service and Judging of Equestrian Events.*, 3rd ed. ed. American Association of Equine Practitioners, Golden, CO.
- Turner, T., 1998. Use of navicular bursography in 97 horses. *Proc. Am. Assoc. Equine Pract.* 44, 227–229.
- Turner, T.A., 1989. Diagnosis and treatment of the navicular syndrome in horses. *Vet. Clin. North Am. - Equine Pract.* 5, 131–144.
- Van den Boom, R., van de Lest, C.H.A., Bull, S., Brama, P.A., van Weeren, P.R., Barneveld, A., 2005. Influence of repeated arthrocentesis and exercise on synovial fluid concentrations of nitric oxide, prostaglandin E2 and glycosaminoglycans in healthy equine joints. *Equine Vet. J.* 37, 250–256.
- Van der Zaag, E.J., Weerts, E.A.W.S., van den Belt, A.J.M., Back, W., 2016. Clinicopathological findings in horses with a bi- or tripartite navicular bone. *BMC Vet. Res.* 12, 1–10.
- Van Wulfen, K.K., Bowker, R.M., 1997. Intersection of the DSIL and the DDFT and Its Relationship to Navicular Syndrome. 43rd Annu. Conv. Am. Assoc. Equine Pract. 43, 405–406.
- Verschooten, F., Desmet, P., Peremans, K., Picavet, T., 1990. Navicular disease in the horse: The effect of controlled intrabursal corticoid injection. *J. Equine Vet. Sci.* 10, 316–320.
- Waguespack, R.W., Burba, D.J., Hubert, J.D., Vidal, M.A., Lomax, L.G., Chirgwin, S.R., Lopez, M.J., 2011. Effects of extracorporeal shock wave therapy on desmitis of the accessory ligament of the deep digital flexor tendon in the horse. *Vet. Surg.* 40, 450–456.
- Wang, C.J., Hsu, S.L., Weng, L.H., Sun, Y.C., Wang, F.S., 2013. Extracorporeal shockwave therapy shows a number of treatment related chondroprotective effect in osteoarthritis of the knee in rats. *BMC Musculoskelet. Disord.* 14, 1–8.
- Wang, C.J., Huang, H.Y., Pai, C.H., 2002. Shock wave-enhanced neovascularization at the tendon-bone junction: An experiment in dogs. *J. Foot Ankle Surg.* 41, 16–22.
- Wang, C.J., Huang, H.Y., Yang, K., Wang, F.S., Wong, M., 2002. Pathomechanism of shock

- wave induced injuries on femoral artery, vein and nerve An experimental study in dogs. *Inj. Int. J. Care Inj.* 33, 439–446.
- Wang, C.J., Huang, K.E., Sun, Y.C., Yang, Y.J., Ko, J.Y., Weng, L.H., Wang, F.S., 2011a. VEGF modulates angiogenesis and osteogenesis in shockwave-promoted fracture healing in rabbits. *J. Surg. Res.* 171, 114–119.
- Wang, C.J., Wang, F.S., Yang, K.D., 2008. Biological effects of extracorporeal shockwave in bone healing: A study in rabbits. *Arch. Orthop. Trauma Surg.* 128, 879–884.
- Wang, C.J., Yang, K.D., Ko, J.Y., Huang, C.C., Huang, H.Y., Wang, F.S., 2009. The effects of shockwave on bone healing and systemic concentrations of nitric oxide (NO), TGF- β 1, VEGF and BMP-2 in long bone non-unions. *Nitric Oxide - Biol. Chem.* 20, 298–303.
- Wang, C.J., Yang, Y.J., Huang, C.C., 2011b. The effects of shockwave on systemic concentrations of nitric oxide level, angiogenesis and osteogenesis factors in hip necrosis. *Rheumatol. Int.* 31, 871–877.
- Wang, F.S., Yang, K.D., Chen, R.F., Wang, C.J., Sheen-Chen, S.M., 2002. Extracorporeal shock wave promotes growth and differentiation of bone-marrow stromal cells towards osteoprogenitors associated with induction of TGF-beta1. *J. Bone Joint Surg. Br.* 84, 457–61.
- Werpy, N.M., 2012. Recheck magnetic resonance imaging examinations for evaluation of musculoskeletal injury. *Vet. Clin. North Am. - Equine Pract.* 28, 659–680.
- Werpy, N.M., 2007. Magnetic resonance imaging of the equine patient: A comparison of high- and low-field systems. *Clin. Tech. Equine Pract.* 6, 37–45.
- Whitfield, C.T., Schoonover, M.J., Holbrook, T.C., Payton, M.E., Sippel, K.M., 2016. Quantitative assessment of two methods of tiludronate administration for the treatment of lameness caused by navicular syndrome in horses. *Am. J. Vet. Res.* 77, 167–173.
- Widmer, W.R., Buckwalter, K.A., Fessler, J.F., Hill, M.A., VanSickle, D.C., Ivancevich, S., 2000. Use of radiography, computed tomography and magnetic resonance imaging for evaluation of navicular syndrome in the horse. *Vet. Radiol. Ultrasound* 41, 108–116.
- Willemen, M.A., Savelberg, H.H.C.M., Barneveld, A., 1999. The effect of orthopaedic shoeing on the force exerted by the deep digital flexor tendon on the navicular bone in horses. *Equine Vet. J.* 31, 25–30.
- Wilson, A.M., McGuigan, M.P., Fouracre, L., MacMahon, L., 2001. The force and contact stress

on the navicular bone during trot locomotion in sound horses and horses with navicular disease. *Equine Vet. J.* 33, 159–165.

Wright, I.M., Kidd, L., Thorp, B.H., 1998. Gross, histological and histomorphometric features of the navicular bone and related structures in the horse. *Equine Vet. J.* 30, 220–234.

Zhao, Z., Ji, H., Jing, R., Liu, C., Wang, M., Zhai, L., Bai, X., Xing, G., 2012. Extracorporeal shock-wave therapy reduces progression of knee osteoarthritis in rabbits by reducing nitric oxide level and chondrocyte apoptosis. *Arch. Orthop. Trauma Surg.* 132, 1547–1553.

APPENDIX A

The introductory letter for the survey and survey questions used for Chapter 4 are provided as supplementary information, shown in the format used in the survey engine. If the respondent indicated that they never used ESWT, questions 3 to 15 regarding clinical use of the therapy were automatically skipped by the survey engine. An asterisk (*) indicates that the survey engine required a response.

Dear Colleague,

Extracorporeal and/or radial shockwave therapy has gained popularity as a treatment option in equine practice for multiple conditions. Initially developed to dissolve kidney stones in people, this treatment modality may have the potential to be a useful non-invasive option for musculoskeletal problems in horses.

The objective of this survey is to characterize the use of shockwave therapy among equine practitioners. All questions are multiple choice, rating scale or a brief answer box, although comments are welcome. This survey will take no more than 15 minutes of your time to complete. Please continue with the survey even if you do not use shockwave therapy.

Your participation in completing this survey is appreciated, and will help to define the perceived clinical value of shockwave therapy in treating varied musculoskeletal issues in horses. This survey will, in part, satisfy the requirements for my Master of Science degree. The results of this study will be circulated to all participants later this year. Identifying information will remain confidential; however if you wish to remain anonymous, feel free to leave the personal information fields blank.

If you have any questions, please contact Angela MacKay at the email address or phone number below. Thank you for volunteering your time for this survey.

**Angela MacKay, DVM
Resident, Equine Field
Service
Western College of Veterinary
Medicine University of
Saskatchewan
(306) 966-7178
angela.mackay@usask.ca**

* 1. How often do you use shockwave therapy on horses in your practice?

- Daily
- At least 1x per week
- At least 1x per month
- Less than 1x per month
- Never

* 2. What are your reasons for NOT using shockwave therapy on horses in your practice? (Select all that apply.)

- My clients do not have the financial resources for shockwave therapy
- I do not have enough equine business to support technology such as shockwave
- There is a lack of scientific evidence showing the efficacy of shockwave
- My clinical experience is that there is a lack of treatment efficacy
- I believe the risks of the therapy outweigh the benefits
- I am not comfortable using the technology
- I do not know enough about the technology and therapy to recommend it as a treatment
- I do not have access to the technology
- I do not think this technology is useful in veterinary medicine
- Other (please specify)

* 3. Which type of shockwave therapy do you use in your practice? (Select all that apply.)

- VersaTron® by PulseVet®
- Shockvet® Shockwave Systems
- NEOvet®
- Storz Duolith® Vet
- Storz Masterpuls® MP50 Elite
- Storz Masterpuls® MP100 Elite
- Storz Masterpuls® MP200 Elite
- Storz D-Actor
- PeizoVet 100 by Wolf
- EMS Dolorclast®
- Unsure of brand of machine
- Other (please specify)

* 4. What type of problems do you typically treat using shockwave therapy? (Select all that apply.)

- Osteoarthritis; for example, in the distal hock joints
- Tendon injuries; for example, a bowed superficial digital flexor tendon
- Ligamentous injuries; for example, proximal suspensory desmitis in a forelimb
- Navicular syndrome
- Muscle pain; for example, lumbar epaxial muscle pain
- I only use shockwave therapy on client request (for various conditions)
- Other (please specify)

* 5. What percent (%) of time do you use shockwave therapy as a stand alone treatment? E.g.; using shockwave therapy only for tendon injuries, instead of combining the treatment with platelet rich plasma. (Enter a % out of 100.)

* 6. What percent (%) of the time do you use shockwave therapy as part of a multi-modal approach? E.g.; combining locally-applied shockwave therapy with systemic hyaluronic acid treatment for osteoarthritis. (Enter a % out of 100.)

The following five questions will characterize your use of shockwave therapy as part of a multi-modal approach when treating various conditions in a horse. Please select all answers that apply.

* 7. When treating osteoarthritis, I generally combine shockwave therapy with these other treatments: (select all that apply)

- Intra-articular steroids
- Intra-articular hyaluronic acid
- Systemic hyaluronic acid
- Systemic anti-inflammatories
- I do not generally treat osteoarthritis with shockwave therapy
- Other (please specify)

* 8. When treating tendon or ligament injuries, I generally combine shockwave therapy with these other treatments: (select all that apply)

- Stall rest, hydrotherapy, and hand walking
- Intra-lesional PRP
- Intra-lesional stem cell therapy
- Blistering
- I do not generally treat tendon or ligament injuries with shockwave therapy
- Other (please specify)

* 9. When treating navicular syndrome, I generally combine shockwave therapy with these other treatments:
(select all that apply)

- Therapeutic farrier work
- Intra-articular steroids
- Bisphosphonates (Tildren, OsPhos)
- Systemic anti-inflammatories
- I do not generally treat navicular syndrome with shockwave therapy
- Other (please specify)

* 10. When treating muscle pain, I generally combine shockwave therapy with these other treatments: (select all that apply)

- Muscle relaxants such as methocarbamol
- Systemic anti-inflammatories
- Massage therapy
- Acupuncture or other complementary practices
- Heat
- Specific training or physical therapy recommendations
- I do not generally treat muscle pain with shockwave therapy
- Other (please specify)

* 11. Which further characterizes your use of shockwave therapy as part of a multi-modal treatment approach? (Select all that apply.)

- I prefer to use shockwave therapy in conjunction with other medically appropriate therapies, depending on the injury
- Shockwave therapy is never my first treatment recommendation
- I prefer to use shockwave therapy in situations where more advanced therapies are not financially possible
- I prefer to use shockwave therapy after other treatments have been pursued, i.e.: in a rehabilitation setting

* 12. Do you sedate every horse on which you perform shockwave therapy?

Yes

No

* 13. What percent (%) of horses do you perform shockwave therapy on WITHOUT sedation? (Enter a % out of 100.)

* 14. When using shockwave therapy, what percent (%) of time do you follow the protocols that were provided from the manufacturer of the machine? (Enter a % out of 100.)

* 15. When using shockwave therapy to treat navicular syndrome, how do you apply the trode? (Select only one answer.)

- Always at the bottom of the foot, i.e.: through the frog with the foot picked up
- Always at the caudal aspect of the foot, i.e.: through the heel bulbs while the horse is weight-bearing
- My method of trode application varies depending on the particular case
- I do not use shockwave therapy to treat navicular syndrome

The following two questions focus on your opinion of the efficacy and tolerability of shockwave therapy.

* 16. On a scale of **1 - 5** (*1 = completely ineffective and 5 = highly effective*), how effective is shockwave as a stand alone treatment modality for:

	1 (completely ineffective)	2	3	4	5 (highly effective)
Osteoarthritis pain management	<input type="radio"/>	<input type="radio"/>	<input type="radio"/>	<input type="radio"/>	<input type="radio"/>
Tendon injuries	<input type="radio"/>	<input type="radio"/>	<input type="radio"/>	<input type="radio"/>	<input type="radio"/>
Ligament injuries	<input type="radio"/>	<input type="radio"/>	<input type="radio"/>	<input type="radio"/>	<input type="radio"/>
Navicular syndrome	<input type="radio"/>	<input type="radio"/>	<input type="radio"/>	<input type="radio"/>	<input type="radio"/>
Muscle pain management	<input type="radio"/>	<input type="radio"/>	<input type="radio"/>	<input type="radio"/>	<input type="radio"/>

* 17. On a scale of 1 - 4 (1 = intolerable and 4 = complete tolerance; N/A if no experience), on average how tolerant of the therapy are patients who receive shockwave to these body regions:

	1 (intolerable)	2	3	4 (complete tolerance)	N/A
Joints of the distal limb (pastern, fetlock etc.)	<input type="radio"/>	<input type="radio"/>	<input type="radio"/>	<input type="radio"/>	<input type="radio"/>
Flexor tendons	<input type="radio"/>	<input type="radio"/>	<input type="radio"/>	<input type="radio"/>	<input type="radio"/>
Foot/heels	<input type="radio"/>	<input type="radio"/>	<input type="radio"/>	<input type="radio"/>	<input type="radio"/>
Hocks	<input type="radio"/>	<input type="radio"/>	<input type="radio"/>	<input type="radio"/>	<input type="radio"/>
Epaxial muscles	<input type="radio"/>	<input type="radio"/>	<input type="radio"/>	<input type="radio"/>	<input type="radio"/>

Other (please specify)

The following four questions focus on the type of practice that you work in.

* 18. What percent (%) of your practice is devoted to horses? (Enter a % out of 100.)

* 19. What type of practice do you work in? (Select only one option.)

- Mixed practice
- Ambulatory practice - equine only
- Referral practice - equine only
- Referral practice - radiology
- Racetrack/horse show practice - equine only
- Reproductive focused practice
- Other (please specify)

* 20. What type of horses do you typically see in your practice? (Select all that apply.)

- All of the below
- English Performance
- Western Performance
- Rodeo horses
- Halter show horses
- Racehorses - Thoroughbred/QH
- Racehorses - Standardbred
- Companion/pleasure horses
- Breeding stock

* 21. What types of complementary or alternative veterinary medicine are offered at and used in your practice? (Select all that apply.)

My practice does not offer complementary or alternative veterinary medicine

Acupuncture

Massage therapy

Chiropractic

Prolo therapy

Therapeutic laser

Therapeutic ultrasound

Other (please specify)

* 22. Can I contact you with further questions after the survey is complete?

Yes

No

The following demographic questions are optional, and can be left blank. **All personal information will be kept confidential.** Please enter your contact information correctly if you do not mind being contacted with further questions.

23. Address

Name	<input type="text"/>
Company	<input type="text"/>
Address	<input type="text"/>
Address 2	<input type="text"/>
City/Town	<input type="text"/>
State/Province	<input type="text"/>
ZIP/Postal Code	<input type="text"/>
Country	<input type="text"/>
Email Address	<input type="text"/>
Phone Number	<input type="text"/>

24. Do you have any other comments you would like to make in regard to the use of shockwave therapy on horses in your practice?

25. Do you have any comments or suggestions in regard to the survey?

Thank you for your time and input on this survey!

Do not hesitate to contact Angela MacKay at angela.mackay@usask.ca if you have any questions or comments regarding this survey.

APPENDIX B

Graphical representation of kinematic gait analysis variables over time for unilateral horses only (Chapter 5).

Figure B.1 Straight line vector sum (VS) over time, separated by group (unilateral horses only)

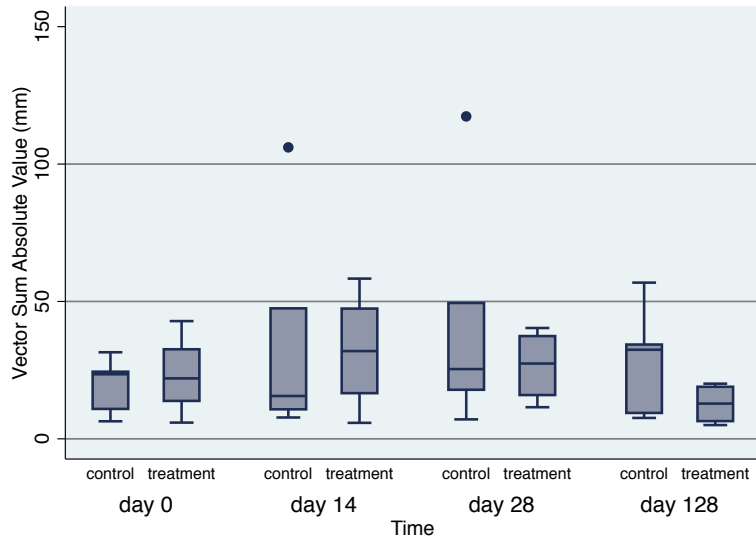


Figure B.2 Straight line Hmin over time, separated by group (unilateral horses only)

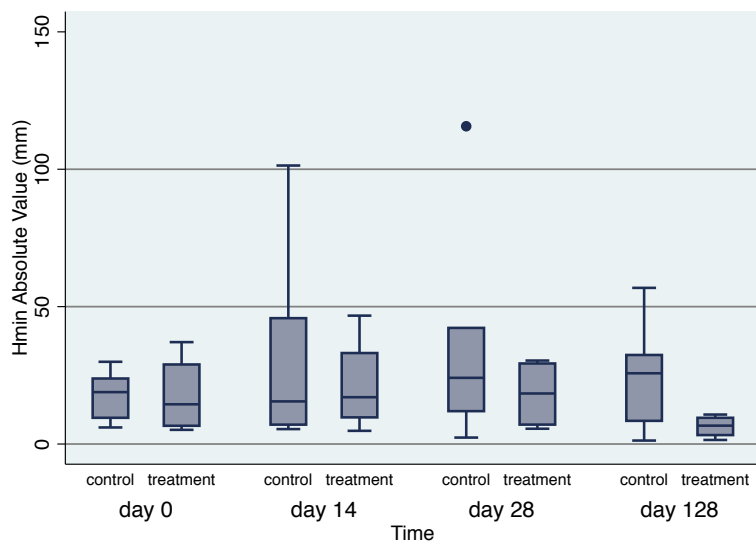


Figure B.3 Straight line Hmax over time, separated by group (unilateral horses only)

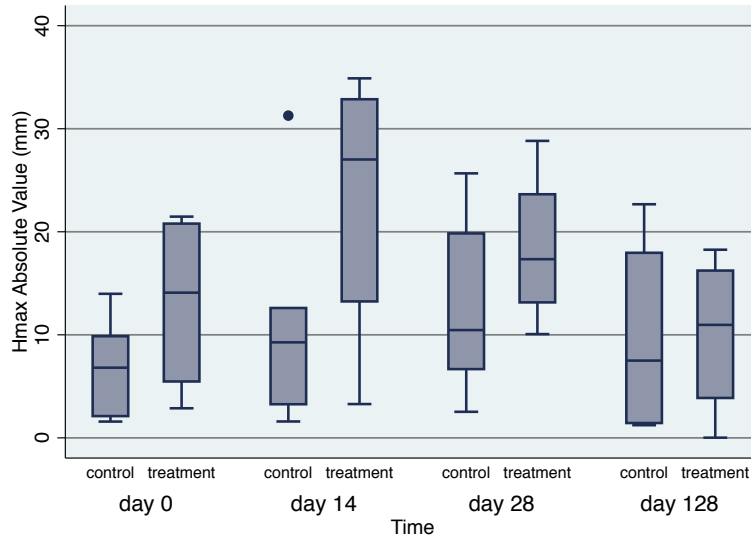


Figure B.4 Left circle VS over time, separated by group (unilateral horses only)

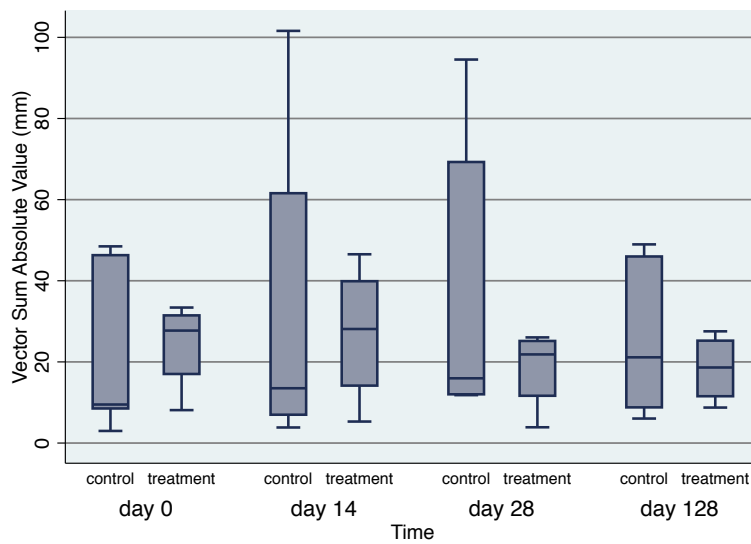


Figure B.5 Left circle Hmin over time, separated by group (unilateral horses only)

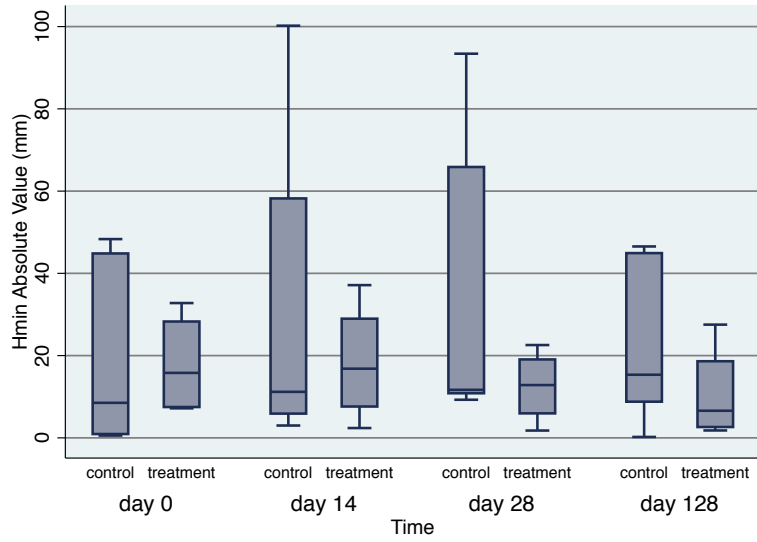


Figure B.6 Left circle Hmax over time, separated by group (unilateral horses only)

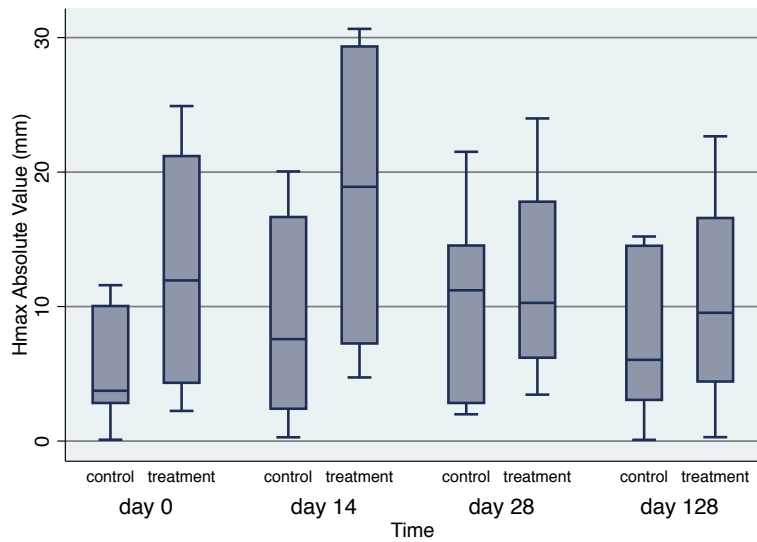


Figure B.7 Right circle VS over time, separated by group (unilateral horses only)

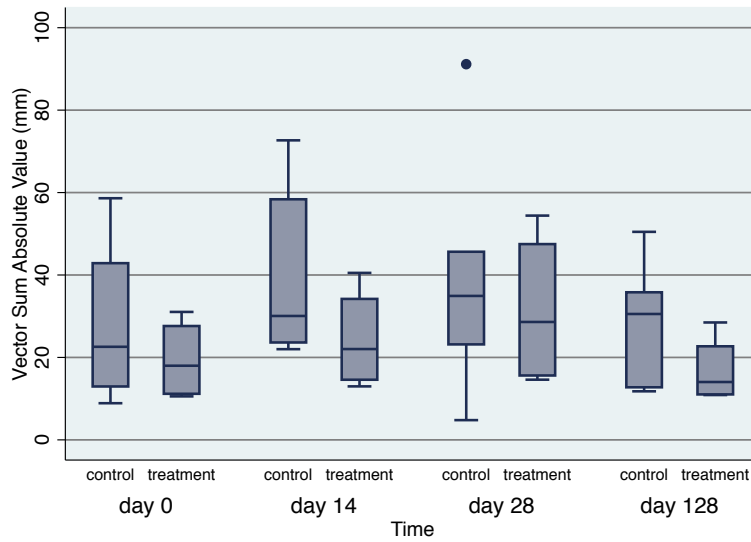


Figure B.8 Right circle Hmin over time, separated by group (unilateral horses only)

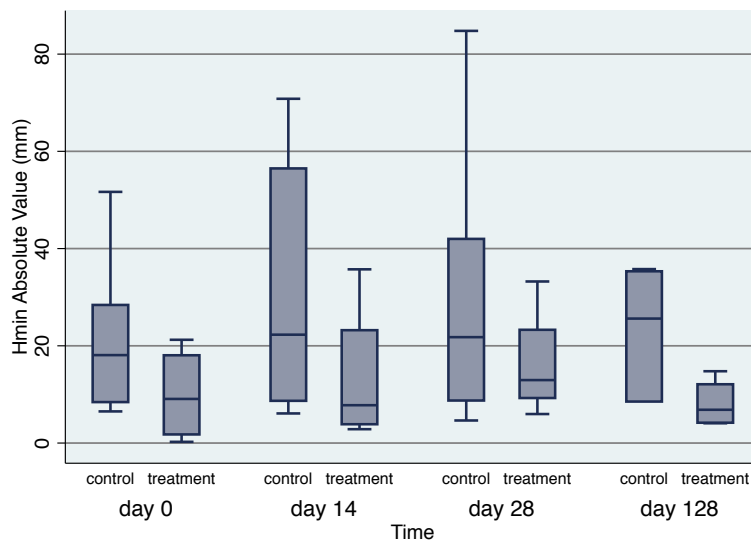


Figure B.9 Right circle Hmax over time, separated by group (unilateral horses only).

