

# Retroauricular Transmeatal Approach to Manage Mandibular Condylar Head Fractures

Arnaldo Benech, PhD, MD, PhD, Francesco Arcuri, MD, Nicola Baragiotta, MD, Matteo Nicolotti, MD, and Matteo Brucoli, MD

**Background:** There is a multitude of reported surgical approaches and technical variants with some unresolved technical problems to gain direct access to mandibular condylar head fractures; they can be divided into 2 groups: intraoral and extraoral. In 2005, Neff et al (*Mund Kiefer Gesichtschir* 2005;9:80), supported by a previous experimental work, reported a successful clinical study of condylar head fractures treated by a retroauricular approach; this article is in German, and the later English-language literature does not mention about this approach to open reduction and internal fixation of mandibular condylar fractures. The retroauricular transmeatal access, selected and performed by the senior author to treat 14 patients affected by highly located condylar head fracture, is illustrated in details.

**Methods:** We collected data of 14 consecutive adult patients who, after the discussion about all options, had consented to have 16 mandibular condylar head fractures treated with open reduction and internal fixation by miniplates and screws via a retroauricular transmeatal approach. We exposed the temporomandibular joint area easily and better by dissecting via a retroauricular route with identification, ligation, and transection of the retromandibular vein; because of the posterior access, the frontal branch of the facial nerve and the auriculotemporal nerve are located and protected within the substance of the anteriorly retracted flap, superficial to the retromandibular vein. The follow-up clinical examination showed temporary weakness of the frontal branch of the facial nerve in 1 case with a recovery to normal function of 1.6 months; no patients had permanent weakness of the facial nerve or injury of the auriculotemporal nerve. There was absence of any salivary fistula, sialocele, and Frey syndrome; hearing was preserved in all cases, without any auditory stenosis or aesthetic deformity, and there was absence of any infections, hematoma, or scarring.

**Conclusions:** Retroauricular approach provides good exposure of the temporomandibular joint and satisfactory protection from nerve injuries and vascular lesions, allowing an adequate osteosynthesis. The scar is hidden behind the ear, and the morbidity is low in terms of auditory stenosis, aesthetic deformity, and salivary fistulas.

**Key Words:** Condylar head fractures, retroauricular approach, transmeatal access, facial nerve

(*J Craniofac Surg* 2011;22: 641–647)

There is a multitude of reported surgical approaches and technical variants to gain direct access to mandibular condylar fractures, and they can be divided into 2 groups: intraoral and extraoral.<sup>1</sup>

The first group includes the endoscopic<sup>2</sup> and the endoscopically assisted approaches<sup>3</sup>; some authors prefer this method, stating that it is advantageous because it minimizes the risks of facial nerve injury and leaves a hidden scar. The disadvantages are that it necessitates specific instruments and an additional training of the surgeon.<sup>4</sup>

Moreover, an intraoral approach can be technically demanding when treating high and medially displaced fractures, and it can lead to unsatisfactory results in terms of anatomic reduction and functionality. Some authors have described for this technique a high percentage of complications such as myofascial pain, condylar head resorption, incorrect reduction, and malocclusions.<sup>5</sup>

The extraoral approaches are preauricular,<sup>6</sup> modified preauricular,<sup>7</sup> retromandibular,<sup>8</sup> miniretromandibular,<sup>9</sup> transmasseteric anteroparotid,<sup>10</sup> submandibular,<sup>11</sup> and facial rhytidectomy.<sup>12</sup>

Extraoral approaches simplify the management of condylar fractures, but they are associated with some unresolved technical problems such as facial nerve, vascular structures, skin incisions, and parotid gland; the preauricular approach is indicated to manage high condylar neck fractures but can have a disadvantage when treating lower fractures such as subcondylar. By contrast, the submandibular and retromandibular accesses allow for a comfortable management of lower fractures, but they become troublesome in treating higher fractures.<sup>13–18</sup>

In 2005, Neff et al,<sup>19</sup> supported by a previous experimental work,<sup>20</sup> reported a successful clinical study of condylar fractures treated by a retroauricular approach; this article is in German, and the later English-language literature does not mention about this approach to open reduction and internal fixation of mandibular condylar fractures.

In the Maxillofacial Unit at the Novara Major Hospital, we choose open treatment for 14 patients affected by highly located condylar head fracture using the retroauricular transmeatal approach.<sup>21,22</sup>

The retroauricular transmeatal access, selected and performed by the senior author to treat these cases, is introduced. This method is a relatively simple route to gain direct access to fractures of the mandibular condyle, allowing an easy anatomic reduction of the stumps and a proper osteosynthesis with miniplates and screws.

This approach permits an easy and fast management of highly located condylar fracture while minimizing the risks of facial nerve injuries and leaving a hidden scar in a barely noticeable region.

From the Department of Maxillo-Facial Surgery, Azienda Ospedaliera Maggiore della Carità, University of Piemonte Orientale “Amedeo Avogadro,” Novara, Italy.

Received September 2, 2010.

Accepted for publication September 24, 2010.

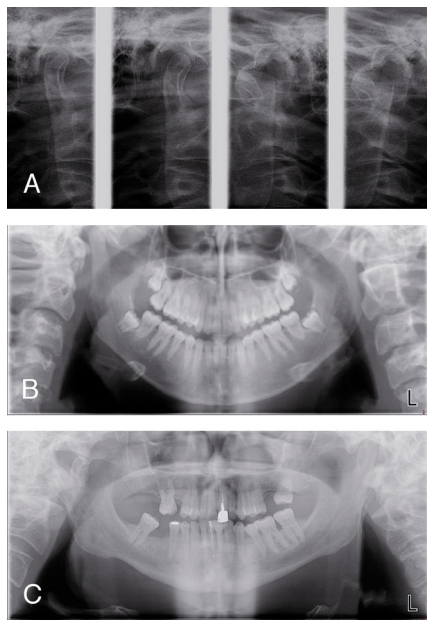
Address correspondence and reprint request to Francesco Arcuri, MD, SCU di Chirurgia Maxillo-Facciale, Ospedale Maggiore della Carità, Corso Mazzini 18, 28100 Novara, Italy; E-mail: fraarcuri@libero.it

The authors report no conflicts of interest.

Copyright © 2011 by Mutaz B. Habal, MD

ISSN: 1049-2275

DOI: 10.1097/SCS.0b013e318207f495



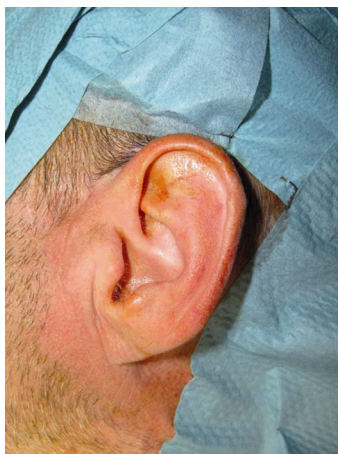**FIGURE 1.** A–C, Preoperative conventional radiographic examinations showing 3 cases of highly located condylar head fractures.

Most surgeons use only screws for fixation because the segments of the condylar fractures are small and difficult to reduce and fix<sup>23–26</sup>; we found this technique unstable for our patients, so our methods of fixation used to improve stability were miniplates and screws.

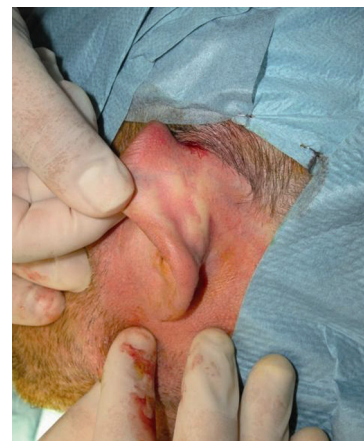We will not discuss which is the ideal surgical approach, which fractures should be managed with open reduction and internal fixation, or which type of osteosynthesis is most suitable biomechanically; these issues have already been addressed by other authors, and it is beyond the scope of this work<sup>27–31</sup>: we will entirely focus on the retroauricular transmeatal approach that is herein-after illustrated step by step.

### PATIENTS AND METHODS

We collected data of 14 consecutive adult patients (from January 2006 to December 2008; 7 white male and 2 North African



**FIGURE 2.** Surgical field at the beginning of the procedure.



**FIGURE 3.** Amount of infiltration in the retroauricular region.

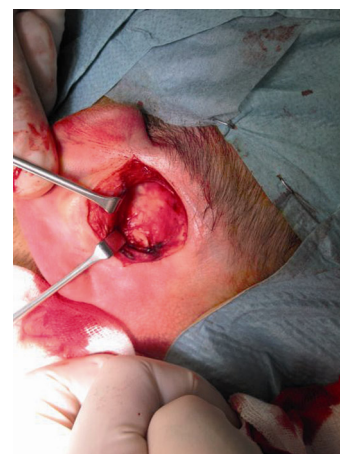male patients, 1 South American male patient, 3 white female patients, and 1 North African female patient; mean age, 33 years; age range, 17–64 years ) who underwent open reduction and internal fixation for 16 condylar head fractures.

Twelve patients presented with unilateral fractures and 2 with bilateral fractures; the 16 condylar fractures consisted of 11 intracapsular condylar fractures and 5 extracapsular highly located condylar head fractures (Fig. 1). A total of 5 patients presented with associated fractures of the facial bones (3 mandibular body and 2 panfacial). The average duration of surgery was 43 minutes (range, 29–67) for each surgical procedure.

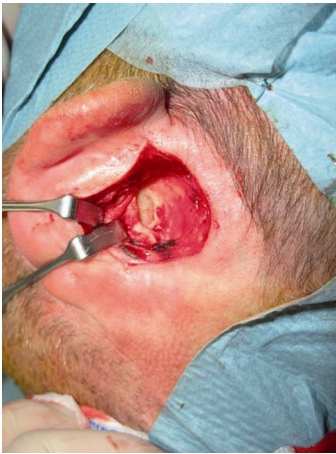The diagnosis was performed by clinical examination, conventional radiography, and computed tomography (CT) scanning; after the discussion about other surgical and nonsurgical alternative, all patients had consented to have the mandibular condylar fractures treated by osteosynthesis with miniplates and screws via a retroauricular transmeatal approach.

### SURGICAL TECHNIQUE

The operation is performed with the patient under general anesthesia with nasotracheal intubation; if other mandibular fractures are concomitant, these are treated first with a standard intraoral approach to recreate the continuity of the mandibular arch. Consequently, a new



**FIGURE 4.** Skin and soft-tissue flaps dissected with the direct exposure of the concha.



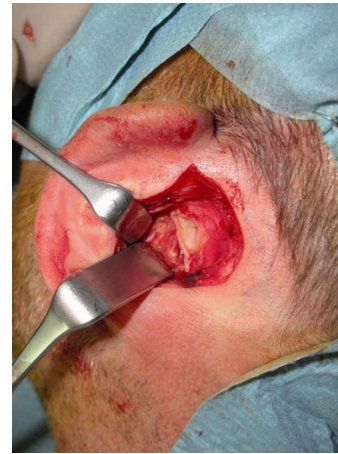**FIGURE 5.** The posterior aspect of the cartilaginous meatus transected.

sterile surgical field is made, and it is separated from the oral and nasal cavities using a sterile adhesive film to prevent bacterial contamination at the condylar site (Fig. 2).

Afterward, a preoperative drawing is made, marking the angle and the body of the mandible, the zygomatic arch, the glenoid fossa, and the fracture site. The ear, the lateral canthus of the eye, and the mandible are prepared and draped as pertinent landmarks of the face to properly expose the surgical field and to mentally visualize the fracture; placing a cotton soaked in the external auditory canal and shaving the preauricular hair are optional.

The retroauricular area is quite vascular, so it is preferable to inject a vasoconstrictor to decrease the amount of bleeding during the incision and the dissection. The posterior surface of the auricle and the occipital area are slowly infiltrated with 4 to 8 mL of 1% lidocaine with 1:100,000 epinephrine; although local anesthesia enhances hemostasis and demarcates the plane of dissection, it is preferable to inject a small amount of infiltration to avoid distortion of the tissues (Fig. 3).

A simple 25- to 30-mm vertical incision is made in the posterior occipital area, approximately 10 to 15 mm medial to the sulcus in a retroauricular crease, through skin and subcutaneous connective tissues. Normally, the edges of the incision are 0.5 to 10 mm cephalad to the radix of the auricular lobule and 0.5 to 10 mm caudal to the



**FIGURE 7.** The retromandibular space with the parotid gland.

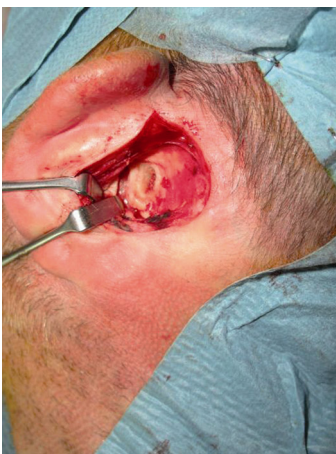insertion of the helix; any bleeding superficial vessels are cauterized before proceeding with deeper dissection.

The anterior and posterior edges of the skin and soft-tissue flaps are elevated to gain a direct exposure of the concha and the mastoid fascia. A clean surgical dissection is kept during the flap elevation; muscle fibers and fat can be cleanly excised off the perichondrium and the mastoid fascia (Fig. 4).

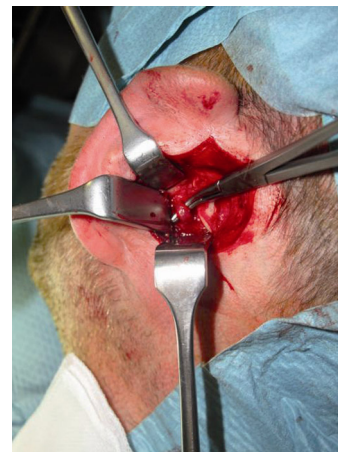Attention is now focused on the concha: the flap is retracted anteriorly, and a first incision with a scalpel is made through the posterior aspect of the cartilaginous meatus, sectioning the cartilage and the skin (Fig. 5); then a second incision is carried out through the anterior wall of the canal at a wide portion to prevent stenosis, transecting conclusively the external auditory meatus (Fig. 6).

At this depth, retraction of the external ear anteriorly permits the exposure of the retromandibular space with the parotid gland (Fig. 7), and blunt dissection commonly reveals the retromandibular vein that is ligated and transected (Fig. 8). Because of the posterior access, the frontal branch of the facial nerve and the auriculotemporal nerve are located and gently protected by a retractor within the substance of the anteriorly retracted flap, superficial to the retromandibular vein (Figs. 7 and 8).

At this point, the mandible is manipulated open and closed to help determine the location of the ramus and the condyle; when

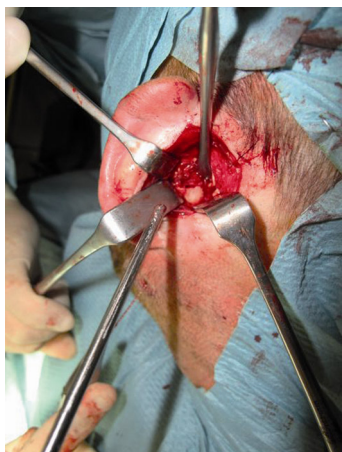


**FIGURE 6.** Incision of the anterior wall of the canal and consequently the entire external auditory canal transected.



**FIGURE 8.** The retromandibular vein isolated.





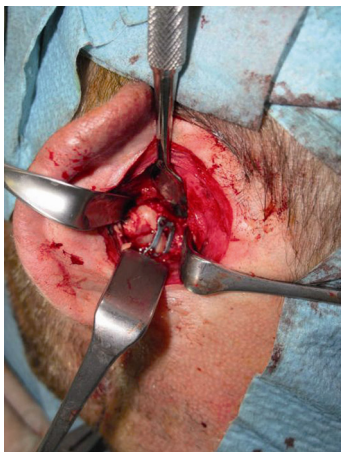
**FIGURE 9.** The anatomic reduction.

the bone surface is reached, the mandibular periosteum is incised, dissected, and elevated, revealing the fracture fragments.

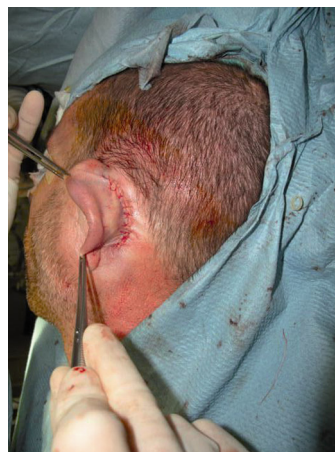The manipulation screw (386.902) and the handle for manipulation screw (386.903) of the endoscopic subcondylar/ramus fixation set (Synthes, West Chester, PA) are used similar to a “joystick” to facilitate the reduction of the condylar head; after a caudal distraction of the distal stump by intraoral pressure to the last mandibular molars with a finger, while taking great care to preserve sterility over the condylar surgical field by changing the surgical gloves, anatomic reduction has been completed (Fig. 9). Finally, after temporary maxillomandibular fixation, the osteosynthesis is performed with miniplates and screws (Fig. 10).

Attention is finally paid to close the access: the surgical site is generously irrigated with hydrogen peroxide, and any hemorrhage is meticulously controlled; afterward, the parotid capsule is closed tightly with running, slowly resorbing, horizontal mattress suture to prevent salivary fistula, and the auricular canal is reconstructed with interrupted, slowly resorbing suture to prevent stenosis. Subcutaneous and skin tissues are closed again with interrupted, slowly resorbing suture (Fig. 11).

A petrolatum gauze is inserted in the external auditory meatus, and it is left in place for 10 days; a compressive dressing is applied for 7 days (Fig. 12). In the postoperative period, the wound is kept moist twice a day for 1 week with hydrogen peroxide and



**FIGURE 10.** Rigid internal fixation.



**FIGURE 11.** Closure of the retroauricular skin with interrupted slowly resorbing suture.

antibiotic ointment; the ear is checked daily for hematoma and infection.

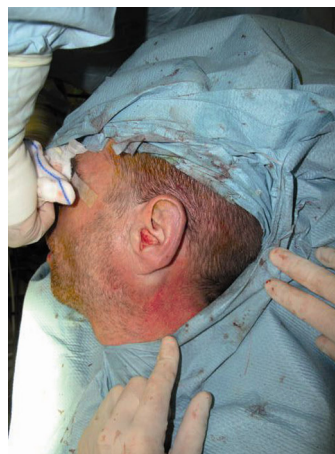## RESULTS

We have used 2 weeks of maxillomandibular fixation with elastics for all patients; postoperative conventional radiographic or CT scans were taken to check fracture osteosynthesis, and a soft diet was ordered for 1 month. After that, if a patient had mandibular hypomobility, mouth-opening exercises were taught: clinical follow-up was performed at 1 week; at 1, 3, and 6 months; and at 1 year; radiologic controls were scheduled in the immediate postoperative period, at 6 months, and at 1 year.

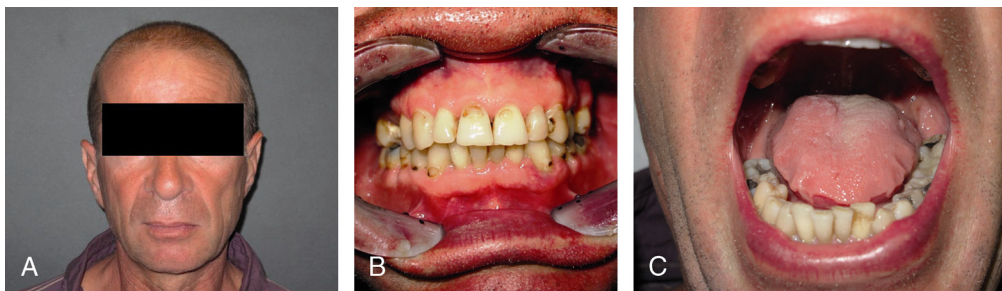
The follow-up clinical examination showed satisfactory results were achieved in all patients; temporary weakness of the frontal branch of the facial nerve was detected in 1 case, with a recovery to normal function after 1.6 months; no patients had permanent weakness of the facial nerve or injury of the auriculotemporal nerve.

There was absence of any salivary fistula, sialocele, and Frey syndrome; hearing was preserved in all cases without any auditory stenosis or aesthetic deformity, and there was absence of any infections, hematoma, or scarring.

The mean maximal interincisal mouth opening was 38 mm, and in every patient, good occlusion without dysfunctional



**FIGURE 12.** A petrolatum gauze is inserted in the external auditory meatus.



**FIGURE 13.** A–C, Postoperative clinical view (A), with a satisfactory occlusion (B) and a good articular function (C).

symptoms as well as facial morphology was restored (Fig. 13); examination on the basis of conventional radiography in 10 of the 14 patients and axial, coronal, and three-dimensional CT scanning in 4 of the 14 patients showed an acceptable osteosynthesis, except in 1 patient with a failure of fixation but with a satisfactory occlusion: no patient needed to return to the operating room for adjustment because of malocclusion (Fig. 14).

### DISCUSSION

Condylar fractures are very common in craniomaxillofacial traumas, and they account for 20% to 52% of all mandibular fractures<sup>32</sup>; properly managing condylar fractures is of priority importance because a mistake during the diagnosis or the treatment can lead to severe anatomic and functional impairment.<sup>33</sup>

These fractures can be classified in several ways; moreover, the patient's age, the fracture' site, and the degree of displacement seem to be of critical importance when deciding the indications for surgical management.<sup>34</sup>

Historically, highly located condylar fractures are treated closed because of 3 main reasons: the difficulty to reduce and fix the small segments of the fracture, the concern about any facial nerve injuries,

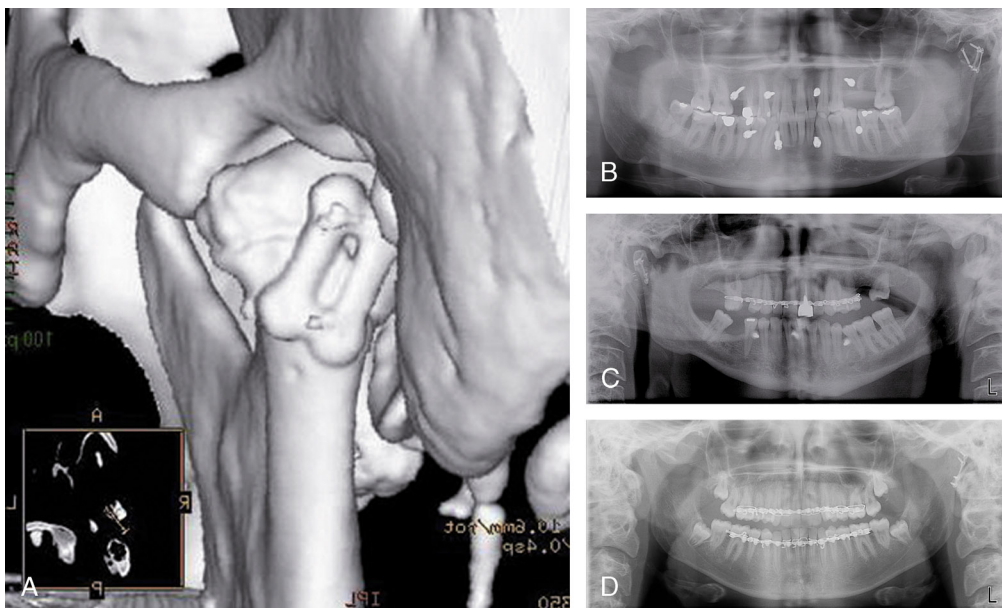
and the adequate satisfaction reported by most patients after conservative treatment during long-term follow-up.<sup>35</sup>

After the development of radiologic examinations, such as CT scanning and magnetic resonance imaging, surgeons analyzed the unsatisfactory results of the closed treatment and began to consider a more aggressive approach.<sup>36,37</sup>

One of the most important anatomic findings observed after the treatment of condylar fractures by functional therapy is the reduction of mandibular ramus height and severe functional impairment including poor occlusion, reduced opening, deviation, and limited lateral mandibular movement<sup>38</sup>; moreover, other possible complications such as temporomandibular joint (TMJ) ankylosis, TMJ dysfunction, and craniofacial pain need to be evaluated before considering a closed treatment.<sup>39</sup>

The surgical treatment of condylar fractures has been strongly debated, and various investigators have previously favored a non-operative approach<sup>40</sup>; a number of reports have now suggested that the treatment of condylar fractures by open reduction and rigid fixation leads to much better anatomic and functional results compared with closed and functional treatment.<sup>41–43</sup>

Nonoperative treatment is still indicated for some cases such as pediatric patients and comminuted intracapsular fractures;



**FIGURE 14.** A–D, Postoperative three-dimensional CT scanning (A) and conventional radiographic examination (B–D) of 3 cases of highly located condylar head fractures demonstrating successful anatomic mandibular reduction and adequate osteosynthesis.



nowadays, evidence with statistical significance strongly supports surgical treatment, and consequently, a more focused debate should start on the ideal method to approach condylar fractures.<sup>44-50</sup>

Surgical access to condylar fractures varies according to the literature; those commonly used, often in combination or modified, are preauricular retromandibular and submandibular. For high condylar fractures, a preauricular approach is commonly used, but the exposure of this area is very limited because of the frontal branch of the facial nerve, the auriculotemporal nerve, and the parotid gland. The submandibular and the retromandibular approaches allow good fracture treatment but require long skin incisions and present some risk for the facial nerve fibers and vascular lesions.<sup>6-12</sup>

Furthermore, these methods are not equivalent for treating all condylar fractures; the preauricular access is well indicated only for treating fractures at higher levels, whereas the standard submandibular and retromandibular approaches do not allow comfortable management of the same type of lesion.<sup>13-18</sup>

The authors exposed the condyle easily and better by dissecting via a retroauricular transmeatal route with identification, ligation, and transection of the retromandibular vein; because of the posterior access, the frontal branch of the facial nerve and the auriculotemporal nerve are located and protected within the substance of the anteriorly retracted flap, superficial to the retromandibular vein.

This approach is not technically demanding; it provides excellent access, allowing direct visualization of highly located condylar fracture, and it ensures that the plates can be well adapted, and the screws placed at 90 degrees to the bony surface, giving maximum mechanical advantage, which is not always possible with the more traditional preauricular, retromandibular, and submandibular accesses.

Moreover, once the flap is retracted anteriorly, the surgical field is always perpendicular to the fractured stumps; this simplifies the treatment of even difficult fractures (anteromedial luxation of the condylar head, delayed treatment) and their rigid fixation.

The ideal surgical approach should be the one that allows fracture management while minimizing the risk of potential pitfalls; we believe that the retroauricular transmeatal approach can be a valid alternative to the common transfacial accesses in selected highly located condylar head fracture such as (1) patients with intracapsular condylar head fractures; (2) overweight patients with redundant cheek soft tissues; (3) patients with a genetic predisposition to develop hypertrophic keloids; (4) patients who do not accept preoperatively any potential nerve injuries or noticeable facial scars; (5) patients who refer during the clinical examination previous surgical procedures in the preauricular area (facelift, parotid surgery).

## CONCLUSIONS

Retroauricular transmeatal access provides good exposure of condylar fractures permitting an adequate osteosynthesis; it is relatively easy and fast to perform; it presents an extremely low risk to injure the facial nerve, and it leaves a unnoticeable scar in a very hidden region behind the ear. The morbidity is extremely low in terms of auditory stenosis, aesthetic deformity, facial nerve lesions, vascular injuries, salivary fistulas, sialoceles, and Frey syndrome.

The TMJ area frequently requires exposure for a multitude of surgical procedures such as internal derangements, arthritis, trauma, developmental disorders, and neoplasia; several approaches have been proposed and used clinically; up to date, the ideal access has not yet been found.

We have successfully performed this approach for 14 trauma cases, and we suggest this access to selected patients owing to its ease, speed, versatility, and freedom from the complications that are common with other extraoral approaches.

We cannot draw statistically significant conclusions, and we think that further experimental studies and prospective clinical trials should be necessary to analyze, develop, and eventually modify this approach; we believe that there is not an ideal approach for a type of fracture, but each patient needs to be evaluated carefully preoperatively, and the more convenient approach needs to be selected for each clinical case.

It will be possible to better understand risks and benefits of this technique, comparing this route with other accesses and extending this surgical technique to other pathologic situations such as developmental disorders and neoplasia of the TMJ area.

## REFERENCES

1. Ellis E III, Moos K, El-Attar A. Ten years of mandibular fractures: an analysis of 2137 cases. *J Oral Surg* 1985;59:120
2. Kellman RM, Cienfuegos R. Endoscopic approaches to subcondylar fractures of the mandible [published online ahead of print February 10, 2009]. *Facial Plast Surg* 2009;25:23-28
3. Loukota RA. Endoscopically assisted reduction and fixation of condylar neck/base fractures The learning curve. *Br J Oral Maxillofac Surg* 2006;44:480
4. Jacobovitz J, Lee C, Trabulsky PP. Endoscopic repair of mandibular subcondylar fractures. *Plast Reconstr Surg* 1998;101:437
5. Jensen T, Jensen J, Norholt SE, et al. Open reduction and rigid internal fixation of mandibular condylar fractures by an intraoral approach: a long term follow up study of 15 patients. *J Oral Maxillofac Surg* 2006;64:1771
6. Kermer Ch, Undt G, Rasse M. Surgical reduction and fixation of intracapsular condylar fractures. A follow up study. *Int J Oral Maxillofac Surg* 1998;28:191
7. He D, Yang C, Chen M, et al. Modified preauricular approach and rigid internal fixation for intracapsular condyle fracture of the mandible. *J Oral Maxillofac Surg* 2010;68:1578-1584
8. Narayanan V, Kannan R, Sreekumar K. Retromandibular approach for reduction and fixation of mandibular condylar fractures: a clinical experience. *Int J Oral Maxillofac Surg* 2009;38:835-839
9. Biglioli F, Colletti G. Mini-retromandibular approach to condylar fractures [published online ahead of print July 2, 2008]. *J Craniomaxillofac Surg* 2008;36:378-383
10. Wilson AW, Ethunandan M, Brennan PA. Transmasseteric antero- parotid approach for open reduction and internal fixation of condylar fractures. *Br J Oral Maxillofac Surg* 2005;43:57
11. Malkin M, Kresberg H, Mandel I. Submandibular approach for open reduction of condylar fracture. *Oral Surg Oral med Oral Pathol* 1964;17:152-157
12. Anastassov GE, Rodriguez ED, Schwimmer AM, et al. Facial rhytidectomy approach for treatment of posterior mandibular fractures. *J Craniomaxillofac Surg* 1997;25:9-14
13. Tasanen A, Lamberg MA. Transosseous wiring in the treatment of condylar fractures of the mandible. *J Maxillofac Surg* 1976;4:200
14. Kallela I, Soderholm AL, Pauku P, et al. Lag screw osteosynthesis of mandibular condyle fractures: a clinical and radiological study. *J Oral Maxillofac Surg* 1995;53:1397
15. Ellis E III, McFadden D, Simon P, et al. Surgical complications with open treatment of mandibular condylar process fractures. *J Oral Maxillofac Surg* 2000;58:950
16. Manisali M, Amin M, Aghabeigi B, et al. Retromandibular approach to the mandibular condyle: a clinical and cadaveric study. *Int J Oral Maxillofac Surg* 2003;32:253
17. Vesnaver A, Gorjanc M, Eberlinc A, et al. The periauricular transparotid approach for open reduction and internal fixation of condylar fractures. *J Craniomaxillofac Surg* 2005;33:169
18. Blair VP. Operative treatment of ankylosis of the mandible. *South Surg Gynecol* 1913;26:436
19. Neff A, Kolk A, Meschke F, et al. Small fragment screws vs. plate osteosynthesis in condylar head fractures [in German]. *Mund Kiefer Gesichtschir* 2005;9:80

20. Neff A, Mühlberger G, Karoglan M, et al. Stability of osteosyntheses for condylar head fractures in the clinic and biomechanical simulation [in German] [published online ahead of print February 6, 2004]. *Mund Kiefer Gesichtschir* 2004;8:63–74
21. He DM, Ellis E, Zhang Y. Etiology of temporomandibular joint ankylosis secondary to condylar fractures: the role of concomitant mandibular fractures. *J Oral Maxillofac Surg* 2008;66:77
22. He DM, Yang C, Chen MJ, et al. Intracapsular condylar fracture of the mandible: our classification and open treatment experience. *J Oral Maxillofac Surg* 2009;67:1672
23. Pilling E, Schneider M, Mai R, et al. Minimally invasive fracture treatment with cannulated lag screws in intracapsular fractures of the condyle. *J Oral Maxillofac Surg* 2006;64:868
24. Vesnaver A. Open reduction and internal fixation of intraarticular fractures of the mandibular condyle: our first experiences. *J Oral Maxillofac Surg* 2008;66:2123
25. Loukota RA. Short communication. Fixation of decapitular fractures of the mandibular condyle with a headless bone screw. *Br J Oral Maxillofac Surg* 2007;45:399
26. Bos RR, Ward Booth RP, de Bont LG. Mandibular condyle fractures: a consensus. *Br J Oral Maxillofac Surg* 1999;37:87
27. Eckelt U, Rasse M. Clinical, radiographic and axiographic control after traction-screw osteosynthesis of fractures of the mandibular condyle region. *Rev Stomatol Chir Maxillofac* 1995;96:158–165
28. Ellis E III, Dean J. Rigid fixation of mandibular condyle fractures. *Oral Surg Oral Med Oral Pathol* 1993;76:6–15
29. Ziccardi VB, Schneider RE, Kummer FJ. Wurzburg lag screw plate versus four-hole miniplate for the treatment of condylar process fractures. *J Oral Maxillofac Surg* 1997;55:602–609
30. Schoen R, Fakler O, Metzger MC, et al. Preliminary functional results of endoscope-assisted transoral treatment of displaced bilateral condylar mandible fractures. *Int J Oral Maxillofac Surg* 2008;37:111–116
31. Martin M, Lee C. Endoscopic mandibular condyle fracture repair. *Atlas Oral Maxillofac Surg Clin North Am* 2003;11:169–178
32. Haug R, Prather J, Indresano A. An epidemiologic survey of facial fractures and concomitant injuries. *J Oral Maxillofac Surg* 1990;48:926
33. Silvennoinen U, Iizuka T, Lindqvist C, et al. Different patterns of condylar fractures: an analysis of 382 patients in a 3-year period. *J Oral Maxillofac Surg* 1992;50:1032
34. Eulert S, Proff P, Bokan I, et al. Study on treatment of condylar process fracture of the mandible. *Ann Anat* 2007;189:377
35. Ellis E. Condylar process fractures of the mandible. *Facial Plast Surg* 2000;16:193
36. Hlawitschka M, Loukota R, Echelt U. Functional and radiological results of open and closed treatment of intracapsular (diacapitular)condylar fractures of the mandible. *Int J Oral Maxillofac Surg* 2005;34:597
37. Hlawitschka M, Eckelt U. Assessment of patients treated for intracapsular fractures of the mandibular condyle by closed techniques. *J Oral Maxillofac Surg* 2002;60:784
38. Choi BH. Magnetic resonance imaging of the temporomandibular joint after functional treatment of bilateral condylar fractures in adults. *Int J Oral Maxillofac Surg* 1997;26:344
39. Cascone P, Leonardi R, Marino S, et al. Intracapsular fractures of mandibular condyle: diagnosis, treatment, and anatomical and pathological evaluations. *J Craniofac Surg* 2003;14:184
40. Haug RH, Brandt MT. Closed reduction, open reduction, and endoscopic assistance: current thoughts on the management of mandibular condyle fractures. *Plast Reconstr Surg* 2007;120 (suppl 2):90S–102S
41. MacLennan WD. Consideration of 180 cases of typical fractures of the mandibular condylar process. *Br J Plast Surg* 1952;5:122
42. Palmieri C, Ellis E III, Throckmorton GS. Mandibular motion after closed and open treatment of unilateral mandibular condylar process fractures. *J Oral Maxillofac Surg* 1999;57:764
43. Ellis E III, Simon P, Throckmorton GS. Occlusal results after open or closed treatment of fractures of the mandibular condylar process. *J Oral Maxillofac Surg* 2000;58:260
44. Ellis E III, Throckmorton GS. Bite forces after open or closed treatment of mandibular condylar process fractures. *J Oral Maxillofac Surg* 2001;59:389
45. Throckmorton GS, Ellis E III. Recovery of mandibular motion after closed and open treatment of unilateral mandibular condylar process fractures. *Int J Oral Maxillofac Surg* 2000;29:421
46. Throckmorton GS, Ellis E III, Hayasaki H. Masticatory motion after surgical or nonsurgical treatment for unilateral fractures of the mandibular condylar process. *J Oral Maxillofac Surg* 2004;62:127
47. Eckelt U, Schneider M, Erasmus F, et al. Open versus closed treatment of fractures of the mandibular condylar process—a prospective randomized multi-centre study. *J Craniomaxillofac Surg* 2006;34:306
48. Schneider M, Lauer G, Eckelt U. Surgical treatment of fractures of the mandibular condyle: a comparison of long term results following different approaches—functional, axiographical, and radiological findings. *J Cranio-Maxillofacial Surg* 2007;35:151
49. Hovinga J, Boering G, Stegenga B. Long term results of nonsurgical management of condylar fractures in children. *Int J Oral Maxillofac Surg* 1999;28:429
50. Gerbino G, Boffano P, Tosco P, et al. Long-term clinical and radiological outcomes for the surgical treatment of mandibular condylar fractures. *J Oral Maxillofac Surg* 2009;67:1009–1014