

65. Kawai K, Urano M, Ebisu S. Effect of surface roughness of porcelain on adhesion of bacteria and their synthesizing glucans. *J Prosthet Dent* 2000;83:664–667
66. Jager N, Feilzer AJ, Davidson CL. The influence of surface roughness on porcelain strength. *Dent Mater* 2000;16:381–388
67. Nissan J, Dmitry Y, Assif D. The use of reinforced composite resin cement as compensation for reduced post length. *J Prosthet Dent* 2001;86:304–308
68. Touti B, Miara P, Nathanson D. *Odontologia Estética e Restaurações Cerâmicas*. São Paulo, Brazil: Ed. Santos, 2000

Zygomatic Metastasis From Breast Cancer

Matteo Brucoli, MD, Francesco Arcuri, MD,
Livia Stellin, MD, Arnaldo Benech, MD, DDS

Abstract: Breast cancer continues to be the second most common cancer among women, after nonmelanoma skin cancer; in the United States, there is an average lifetime risk of 11% for developing a breast malignancy. Metastatic tumors from distant primary foci to the maxillofacial (MF) region are reported to account for only 1% of all MF malignancies, usually with grave prognosis. In the MF region, the bones more frequently involved in metastasis are the mandible, maxilla, temporal bone, frontal bone, and malar bone; the soft tissues more affected are gingiva, parotid gland, tongue, submandibular gland, and cheek. We describe a unique case of a solitary mass found in the body of the right zygoma, revealing a metastasis from breast cancer. According to the literature, the zygomatic complex is a very unusual site for metastasis; we found only 4 cases of metastatic localization from lung, rectum, liver, and uterine cancer. In MF region, oral and nasal cavity has been described as atypical sites of metastasis from breast cancer; this is to our knowledge the first recorded instance of malar metastasis from breast cancer.

Key Words: Zygomatic, breast, metastasis, cancer

Breast cancer continues to be the second most common cancer among women, after nonmelanoma skin cancer; in the United States, there is an average lifetime risk of 11% for developing a breast malignancy.¹ An average woman has a 3% to 4% chance of death from a breast malignancy; risk factors include family/personal history of breast malignancy, early menarche, increasing age, late menopause, alcohol consumption, nulliparity, and previous exposure to ionizing radiation.² Genetic mutations such as BRCA1/BRCA2

From the Department of Maxillo-Facial Surgery Azienda Ospedaliera Maggiore della Carità University of Piemonte Orientale “Amedeo Avogadro,” Novara, Italy.

Received May 17, 2010.

Accepted for publication July 3, 2010.

Address correspondence and reprint requests to Francesco Arcuri, MD, S.C.D.U. di Chirurgia Maxillo-Facciale, Ospedale Maggiore della Carità, Corso Mazzini 18, 28100 Novara, Italy; E-mail: fraarcuri@libero.it

The authors report no conflicts of interest.

Copyright © 2010 by Mutaz B. Habal, MD

ISSN: 1049-2275

DOI: 10.1097/SCS.0b013e3181f538b4

are positive predictors,³ and risk of disease in these individuals has been estimated at 60% to 80%.⁴ Metastatic tumors from distant primary foci to the maxillofacial (MF) region are reported to account for only 1% of all MF malignancies, usually with grave prognosis.^{5–9} Most patients have had a previously known primary cancer; nevertheless, metastasis in MF region was the initial manifestation in approximately one third of the patients, and in some cases, the primary tumor remains unknown despite additional investigations.^{10–14} Shen et al¹⁵ in 2009 reported a review of the Chinese and English literature for metastatic tumors to the MF region; in the search conducted from January 1950 to April 2007, they collected 461 articles with 746 histopathologically confirmed cases of MF metastatic tumors. According to their study, the most frequent sites of primary cancers were lung and bronchus, breast, kidney, liver with internal biliary ducts, and prostate.

In the MF region, the bones more frequently involved in metastasis were mandible, maxilla, temporal bone, frontal bone, and malar bone; the soft tissues more affected were gingiva, parotid gland, tongue, submandibular gland, and cheek. We describe a unique case of a solitary mass found in the body of the right zygoma, revealing a metastasis from breast cancer.

CLINICAL REPORT

We introduce a case of a 61-year-old woman who underwent in 2006 a left-sided radical mastectomy with axillary clearance; the histopathologic examination showed invasive ductal carcinoma of the breast G3 pT4 N1a (2N+/26) with local vascular and neuronal invasion and the following immunohistochemical profile: ER, 70%; PgR, 0%; C-erb2 positive.

The patient was put on adjuvant chemotherapy with FEC (fluorouracil, epirubicin, and cyclophosphamide)–docetaxel (Taxotere) from June 2006 to October 2006; from November 2006, she was put on hormone therapy with anastrozole with a result clinically and radiologically free from disease until December 2009.

Laboratory tests, performed in this period as follow-up, revealed an abnormal increase in creatine, aspartate aminotransferase, alanine aminotransferase, and gamma-glutamyl transpeptidase levels associated to pathologic serum levels of the tumoral markers carcinoembryonic antigen (5.05) and CA-15-3 (70.10).

On January 2010, a positron emission tomography (PET) total body was undertaken, and it revealed 3 foci localized in the right iliac crest, liver, and zygoma; a computed tomography (CT)

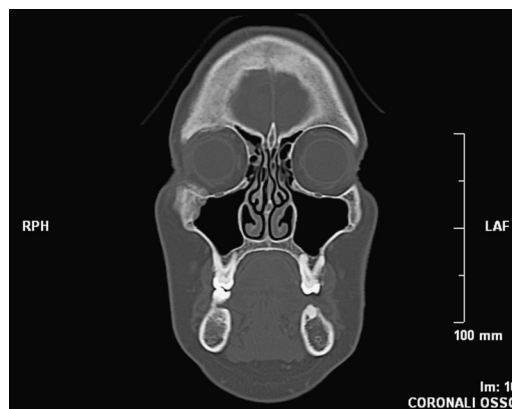


FIGURE 1. Coronal CT scan demonstrating the right zygomatic lesion, extended to the orbit, the maxillary sinus, and the soft tissue of the cheek.

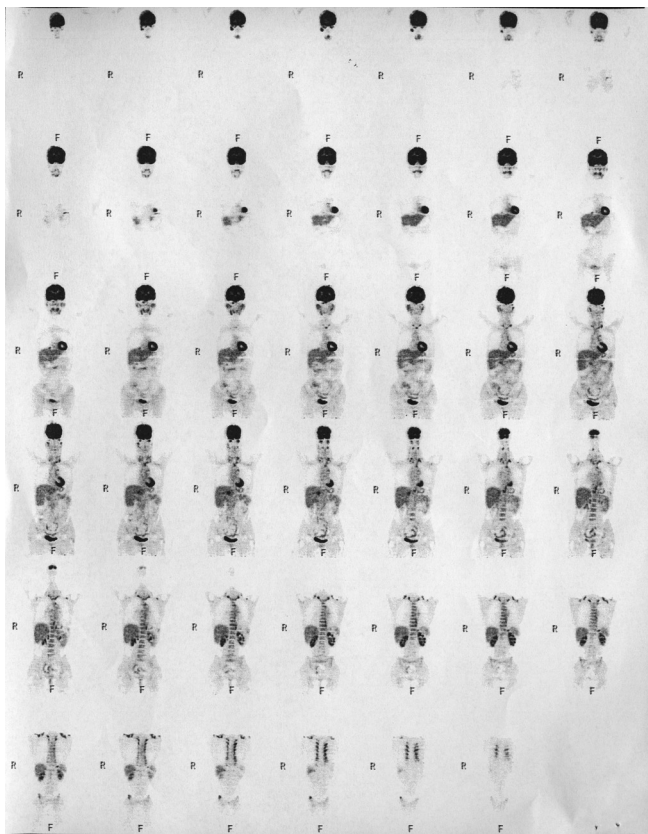


FIGURE 2. Positron emission tomography total body.

showed the lesion on the right zygoma extended to the orbit, the maxillary sinus, and the soft tissue of the cheek (Figs. 1–5).

On February, the patient was put on hormonotherapy with exemestane, and on March, she was referred by her general prac-

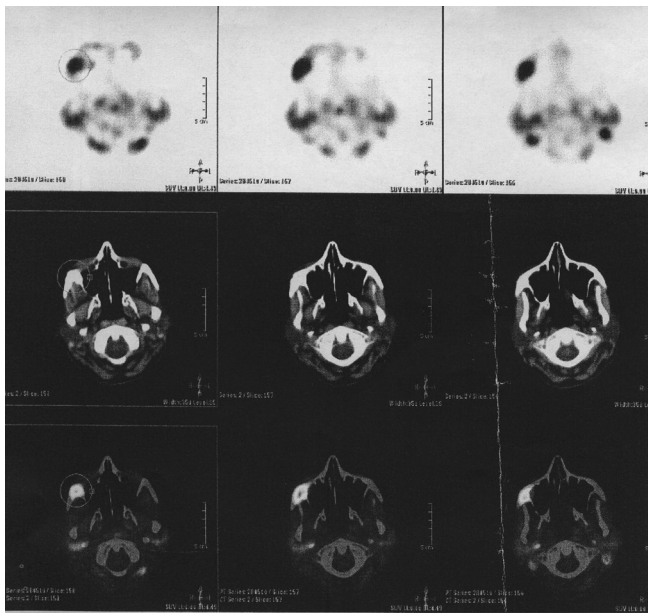


FIGURE 3. Axial CT-PET scan confirming the zygomatic metastasis.

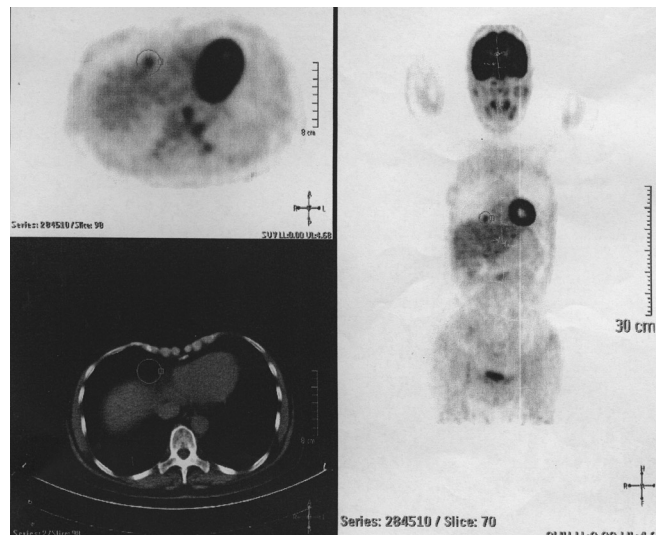


FIGURE 4. Axial CT-PET scan demonstrating the hepatic mass.

itioner to our clinic for a swelling and painful facial mass; the medical examination revealed an asymmetry of the midface due to the zygomatic mass and a mild proptosis; after few days, we performed an incisional biopsy under general anesthesia through an intraoral access with a high index of suspicion for breast metastasis, and the definitive histopathologic examination confirmed our initial diagnosis.

DISCUSSION

Immunohistochemical analysis is a reliable diagnostic tool for identification of the likely site of the primary lesion in cases in which unexpected metastatic foci are identified.¹⁶ Breast carcinoma has a relatively characteristic immunohistochemical profile that

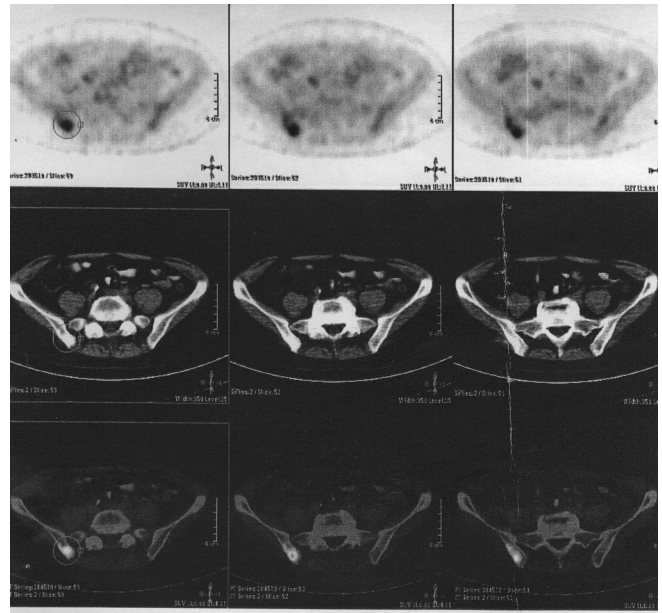


FIGURE 5. Axial CT-PET scan revealing a metastasis to the iliac crest.

allows identification with a very high degree of certainty. Cytokeratins 7 and 20 allow localization of the site of origin of the metastatic tumor cells to limited anatomic regions.¹⁷ Cytokeratin 20 is a type I keratin that exhibits a relatively restricted range of tissue expression; it is found primarily in epithelium that derives from the gastrointestinal tract, urothelium, and Merkel cells of the skin. Cytokeratin 7 is a type II keratin and is identified in a variety of glandular epithelia to include endometrium, ovary, lung, and breast; it seems absent for the most part in adenocarcinomas arising in the gastrointestinal tract. Breast carcinomas typically show a cytokeratin 7–positive/cytokeratin 20–negative immune profile, as was evident in this case.¹⁸ In addition, because the epithelial cells of the normal breast mammary glands are responsive to estrogen and progesterone hormone levels, the cells of adenocarcinomas arising from the breast glands often have estrogen and progesterone receptor sites on their cell membranes that can be decorated with appropriate immunohistochemical stains.¹⁹ In the present case, estrogen receptor was positive, and progesterone receptor was negative; in conjunction with the cytokeratin 7/20 profile, identification of the lesion as a metastatic breast adenocarcinoma was virtually ensured. Solomayer et al²⁰ in 2000 published a retrospective study of 648 patients with metastatic breast cancer treated from 1977 to 1985. First metastasis was seen in the skeletal system (thoracic spine, pelvis, lumbar spine, and ribs) in 296 patients (46%), in the visceral organs (liver, lung, brain, and ovaries) in 268 patients (41%), and in both systems in 84 patients (13%). The disease remained confined to the skeleton or the visceral system in 180 patients (28%) and 188 patients (29%), respectively. Two hundred eighty patients (43%) developed both bone and visceral metastases. According to other studies,^{21,22} patients with bone metastases at the time of first relapse had a significantly better prognosis in terms of survival, overall survival, and metastasis-free interval than patients with visceral metastases. Patients with both osseous and visceral metastases had the same prognosis as patients with visceral metastases only at first relapse.

In conclusion, the above case is significant for multiple reasons; according to the literature, the zygomatic complex is a very unusual site for metastasis; we found only 4 cases of metastatic localization from lung,²³ rectum,²⁴ liver,²⁵ and uterine²⁶ cancer. In MF region, oral²⁷ and nasal²⁸ cavities have been described as atypical sites of metastasis from breast cancer; this is to our knowledge the first recorded instance of malar metastasis from breast cancer.

REFERENCES

- American Cancer Society. *Breast Cancer Facts & Figures 2005–2006*. Atlanta, GA: American Cancer Society, Inc
- Norton J, Bollinger RR, Chang AE, et al. *Surgery: Basic Science and Clinical Evidence*. New York, NY: Springer-Verlag, 2001:1715–1719
- Claus EB, Schildkraut J, Iversen ES, et al. Effect of BRAC1 and BRAC2 on the association between breast cancer risk and family history. *J Natl Cancer Inst* 1998;90:1824
- Brody LC, Biesecker BB. Breast cancer susceptibility genes: BRAC1 and BRAC2. *Rev Mol Med* 1998;77:208
- Pruckmayer M, Glaser C, Marosi C, et al. Mandibular pain as the leading clinical symptom for metastatic disease: nine cases and review of the literature. *Ann Oncol* 1998;9:559
- Wu YT, Zhang ZY, Yu SF, et al. Metastatic carcinoma to the oral tissue and jaws: a study of 25 cases. *Zhonghua Kou Qiang Yi Xue Za Zhi* 1990;25:258
- Van der Waal RI, Buter J, Van der Waal I. Oral metastases: report of 24 cases. *Br J Oral Maxillofac Surg* 2003;41:3
- Meyer I, Shklar G. Malignant tumors metastatic to mouth and jaws. *Oral Surg Oral Med Oral Pathol* 1965;20:350
- Li TS, Xu Gz. Malignant neoplasm metastatic to oral and maxillofacial region: report of 7 cases. *Ai Zheng* 1983;2:102
- Sanchez Aniceto G, Garcia Penin A, De la Mata Pages R, et al. Tumors metastatic to the mandible: analysis of nine cases and review of the literature. *J Oral Maxillofac Surg* 1990;48:246
- Cash CD, Royer RQ, Dahlin DC. Metastatic tumors of the jaws. *Oral Surg Oral Med Oral Pathol* 1961;14:897
- Keller EE, Gunderson LL. Bone disease metastatic to the jaws. *J Am Dent Assoc* 1987;115:697
- Batsakis JG, McBurney TA. Metastatic neoplasms to the head and neck. *Surg Gynecol Obstet* 1971;133:673
- Schwartz ML, Baredes S, Mignogna FV. Metastatic disease to the mandible. *Laryngoscope* 1988;98:270–273
- Shen ML, Kang J, Wen YL, et al. Metastatic tumors to the oral and maxillofacial region: a retrospective study of 19 cases in West China and review of the Chinese and English literature. *J Oral Maxillofac Surg* 2009;67:718–737
- Brown RW, Campagna LB, Dunn JK, et al. Immunohistochemical identification of tumor markers in metastatic adenocarcinoma: a diagnostic adjunct in the determination of primary site. *Am J Clin Pathol* 1997;107:12
- Tot T. Cytokeratins 20 and 7 as biomarkers: usefulness in discriminating primary from metastatic adenocarcinoma. *Eur J Cancer* 2002;38:758
- Tot T. The role of cytokeratins 20 and 7 and estrogen receptor analysis in separation of metastatic lobular carcinoma of the breast and metastatic signet ring cell carcinoma of the gastrointestinal tract. *Acta Pathol Microbiol Immunol Scand* 2000;108:467
- Rose P, Oberman H. *Atlas of Tumor Pathology, Third Series, Fascicle 7: Tumors of the Mammary Gland*. Washington, DC: American Registry of Pathology and the Armed Forces Institute of Pathology, 1993: 157–168
- Solomayer E-F, Diel IJ, Meyberg GC, et al. Metastatic breast cancer: clinical course, prognosis and therapy related to the first site of metastasis. *Breast Cancer Res Treat* 2000;59:271–278
- Coleman RE, Smith P, Rubens RD. Clinical course and prognostic factors following bone recurrence from breast cancer. *Br J Cancer* 1998;77:336–340
- Yamashita K, Takafumi U, Komatsubara Y, et al. Breast cancer with bone only metastases. Visceral metastases-free rate in relation to anatomic distribution of bone metastases. *Cancer* 1991;69:634–637
- Veerappan G, Lettieri C, Cuneo B. Squamous cell lung cancer presenting as a malar mass. *Neoplasia* 2003;5:467–468
- Danikas D, Theodorou SJ, Arvanitis ML, et al. Malar metastasis from rectal carcinoma: a case report. *Am Surg* 1999;65:1150–1152
- Neff BA, Pribitkin EA, Willcox TO Jr. Hepatocellular cancer metastatic to the zygoma: primary resection and immediate reconstruction. *Ear Nose Throat J* 2002;81:57–58
- Challagalla JD, Smith R, Mitnick R, et al. Carcinoma of the uterine cervix metastatic to behind the zygomatic arch: a case report. *Am J Otolaryngol* 1999;20:195–197
- Rajesh KS, Varma BR, Bhat KM. Metastasis to maxillary gingiva from carcinoma of breast. A case report. *Indian J Dent Res* 1998;91: 23–27
- Liao HS, Hsueh C, Chen SC, et al. Solitary nasal cavity metastasis of breast cancer. *Breast J* 2010;16:321–322

Huge Maxillofacial Teratomas

Bo Li, PhD,*† Xing Long, PhD, DDS,† Zhongxing Wu, PhD,† Xinming Chen, PhD‡

Abstract: Teratomas arising from the head and neck are extremely rare. Sporadic reports in the literature mostly involve infant and young people. In this clinical report, we present a huge teratoma of the infratemporal fossa in an old patient. Current diagnosis and management approaches of this rare entity are described.