

See discussions, stats, and author profiles for this publication at: <https://www.researchgate.net/publication/309805188>

Stapled hemorrhoidopexy: no more a new technique

Article · November 2016

DOI: 10.21037/ales.2016.11.02

CITATIONS

0

READS

11

9 authors, including:



[Pasquale Cianci](#)

Università degli studi di Foggia

29 PUBLICATIONS 5 CITATIONS

SEE PROFILE



[Amedeo Altamura](#)

Università degli Studi di Bari Aldo Moro

4 PUBLICATIONS 2 CITATIONS

SEE PROFILE



[Nicola Tartaglia](#)

Università degli studi di Foggia

37 PUBLICATIONS 88 CITATIONS

SEE PROFILE



[Vincenzo Neri](#)

Università degli studi di Foggia

139 PUBLICATIONS 371 CITATIONS

SEE PROFILE

Some of the authors of this publication are also working on these related projects:



T-Tube in Pancreatoduodenectomy [View project](#)



T-Tube in Pancreatoduodenectomy [View project](#)

Stapled hemorrhoidopexy: no more a new technique

Pasquale Cianci, Amedeo Altamura, Nicola Tartaglia, Alberto Fersini, Emilio Calabrese, Umberto De Stefano, Maria Rosaria Menga, Antonio Ambrosi, Vincenzo Neri

Department of Medical and Surgical Sciences, University of Foggia, Foggia, Italy

Contributions: (I) Conception and design: P Cianci, A Altamura; (II) Administrative support: None; (III) Provision of study materials or patients: None; (IV) Collection and assembly of data: N Tartaglia, A Fersini, E Calabrese, U De Stefano, MR Menga; (V) Data analysis and interpretation: None; (VI) Manuscript writing: All authors; (VII) Final approval of manuscript: All authors.

Correspondence to: Pasquale Cianci, Luigi Pinto Str. 1, 71122 Foggia, Italy. Email: ciancidoc1@virgilio.it.

Abstract: Haemorrhoidal disease affect between 4.4% and 36.4% of the general population. The common symptoms are: bleeding, prolapse, pain, discharge, itching and hampered anal hygiene. There is no correlation between specific symptoms and anatomic grading. Apparently severe looking haemorrhoids can cause relatively few symptoms. Open haemorrhoidectomy, as described by Milligan, has been accepted worldwide as the best choice for treatment of symptomatic haemorrhoids. In 1998, Longo proposed a procedure for haemorrhoidectomy with minimal postoperative pain, no perianal wound requiring postoperative wound care and a relatively short operative time. His technique presented a new notion for treating haemorrhoids as he proposed circumferential rectal mucosectomy that results in mucosal lifting (anopexy). His aim was not excision of the haemorrhoidal tissue but rather restoring anatomical and physiological aspects of the haemorrhoidal plexus. The grading system described by Goligher, is the most commonly used and is based on objective findings and patient history. Stapled hemorrhoidopexy is performed for grade III and IV, for grade II in case of major bleeding. In lithotomy position and spinal anesthesia and after taking all aseptic precautions, the procedure of stapled hemorrhoidectomy was performed according to Longo's technique. After this surgical procedure, the need to manually reduce prolapse will have been cured in approximately 90% of patients and the overall preoperative symptoms will be much reduced in the great majority. There should be no anal pain. Bowel habits should have returned to a normal pattern without urgency. One year follow-up or longer 11% of patients had remaining or recurrent prolapse, the reintervention rate is about 10%.

Keywords: Stapled hemorrhoidopexy; hemorrhoids; anal canal diseases; coloproctology; gastrointestinal surgery

Received: 08 September 2016; Accepted: 12 October 2016; Published: 09 November 2016.

doi: 10.21037/ales.2016.11.02

View this article at: <http://dx.doi.org/10.21037/ales.2016.11.02>

Introduction

In the literature, there are several theories describing the causes of the haemorrhoidal disease. Some believe that it is primarily a disease of the veins in line with the varicose veins in the esophagus. A morphological and functional failure of a sphincter mechanism coordinating the filling and drainage of the anorectal vascular cushions may be the cause (1). Another hypothesis is that the disease is caused by a weakening of the collagen support in the anal canal where the submucosal collagen fibrils degenerates with sliding

mucosa during defecation or physical activity as a result (2). A third theory suggests an increased arterial flow to the vascular plexus (3). Constipation and bowel habits with straining are associated with the haemorrhoidal disease (4,5). The hemorrhoidal disease affects the general population between 4.4% and 36.4% (6,7). Physiologically hemorrhoids are anal cushions that can become symptomatic through prolapse and bleeding. When they become symptomatic you may occur secondary symptoms: pain, pruritus and mucus loss. Often it is not found correlation between the

presence of hemorrhoids and the clinical symptoms (6,8). The common symptoms are: bleeding, prolapse, pain, discharge, itching and hampered anal hygiene. There is no correlation between specific symptoms and anatomic grading. The presence of a severe haemorrhoidal prolapse can cause poor symptomatology (2), while the presence of normal anal cushions may be associated with important clinical symptoms that can cause great anxiety in patients. In this last case, the socioeconomic and cultural factors play an important. A few attempts to create a symptom score have been made, but a validated symptom score is not available at the moment. History should include toilet habits, stool frequency, stool consistency and difficulties in rectal emptying. Dietary habits in terms of fiber intake should be assessed. Milligan *et al.* in 1937 proposed the open hemorrhoidectomy for the treatment of symptomatic hemorrhoids, since then this surgical technique was the most practiced and accepted in the world (9,10). Despite its effectiveness, this technique is associated with postoperative pain for the presence of open wounds in a sensitive area and that require local therapy. For these reasons, the technique is not well accepted by patients and different approaches have been advocated from time to time (7,11). In the past years, several studies (9,11,12) have modified the anatomy and physiology of haemorrhoids underlying some important pathogenetic aspects. These findings are also the rational basis of a totally new surgical approach in the treatment of haemorrhoidal disease. In 1998 Longo proposed what sounded, at the time, like an ideal solution: a procedure for haemorrhoidectomy with minimal postoperative pain, no perianal wound requiring postoperative wound care and a relatively short operative time (13). His technique presented a new notion for treating haemorrhoids as he proposed circumferential rectal mucosectomy that results in mucosal lifting (anopexy). His aim was not excision of the haemorrhoidal tissue but rather restoring anatomical and physiological aspects of the haemorrhoidal plexus (14). As early as 2001, there were several studies to confirm that stapled haemorrhoidopexy is a safe procedure that is associated with a shorter operative time, low postoperative pain, shorter hospital stay and a more rapid return to normal activities of daily living than other surgical techniques (15). Several subsequent randomized controlled trials and reviews confirmed these findings, with some studies claiming that stapled haemorrhoidopexy is the most effective and safe procedure for haemorrhoids (16). Based on these early successes and the expected interest in new procedures that

might reduce postoperative pain, stapled haemorrhoidopexy has acquired a considerable popularity (17) with a reputation as a safe and effective alternative approach for the treatment of haemorrhoids (18). There have been recent calls for further randomized trials to investigate the long-term outcomes of stapled haemorrhoidopexy. Whether such trials are now practical is debatable. Given the proven short-term benefits of the stapled technique, it is possible that clinicians and patients will be reluctant to randomise to open surgery. Long-term follow-up data is already beginning to emerge (19-23), and perhaps future research efforts might better be engaged in undertaking a comprehensive cost-effectiveness analysis, incorporating both hospital and community costs. The latest evidence on stapled haemorrhoidopexy suggests that it is a technique that is finally coming of age and establishing itself as a credible alternative to conventional haemorrhoidectomy. It is probably most suited to the treatment of grade III, and perhaps circumferential grade II, haemorrhoidal prolapse. Controversy remains regarding its role in large volume and grade IV prolapse, due to increased rates of recurrence. Until this is resolved, it is unlikely that stapled haemorrhoidopexy will attain acceptance as the preferred "gold standard". In comparison, the fate of conventional haemorrhoidectomy appears somewhat uncertain, accepting that it will continue to have a role in specific circumstances. It is likely that "patient's choice" will ultimately determine its survival or otherwise, and will be driven by how acceptable postoperative pain is in the era of modern surgical technology.

Patient selection and workup

Treatment of the haemorrhoidal disease and assessment of treatment outcome must be based on a uniform grading. Investigation in different positions is described, lithotomy position, left lateral position (Sims) position, sitting on a toilet chair and photo documentation with the patient standing or sitting. Grading is dependent on the position of the patient examined. The prerequisite for a proper grading is standardized examination conditions, or at least, a description of the position during examination. The grading system described by Goligher, is the most commonly used and is based on objective findings and history (24):

- (I) Grade I: no prolapse, vascular cushions in the anal canal visualized by endoscopy;
- (II) Grade II: prolapse during defecation, but spontaneous reduction;
- (III) Grade III: prolapse during defecation, which need

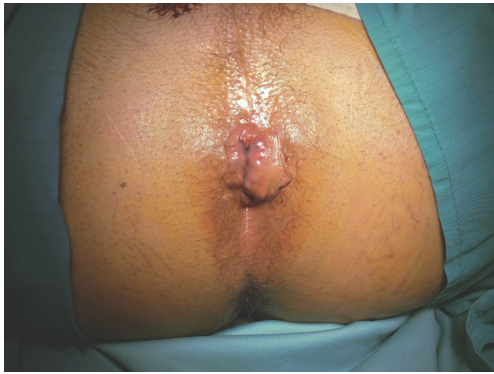

Figure 1 Grade III hemorrhoids.

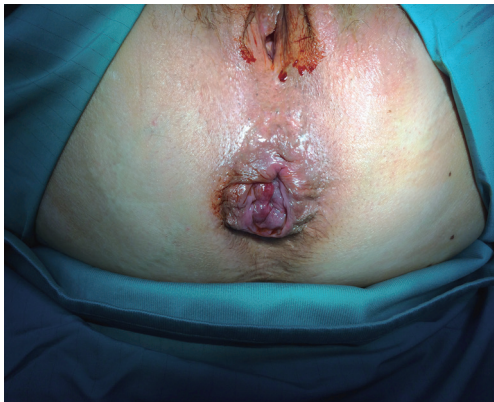

Figure 2 Grade IV hemorrhoids.

manually reduction;

- (IV) Grade IV: persistent prolapse irrespective attempt to reduce the prolapse.

Clinical examination can be performed in different positions. The patient can be placed in the prone position, on the left side with knees bent to his chest, or in the knee-elbow position. The inspection will evaluate the perianal skin and anus closure. At this stage, grade IV haemorrhoids will already be visible. The strain can be highlighted haemorrhoids of grade II and III as spontaneous prolapse. Subsequently, digital rectal exam will evaluate the functionality of sphincter anus. Grade II–IV haemorrhoids may be appreciated as tense-elastic cushions. The instrumental exams includes colonoscopy and defecography; the first is performed both in women than in men, especially in the case of bleeding and family history of malignant disease, the second is useful in women and optional for men. This latest exam helps the surgeon to exclude the presence of rectal prolapse, rectocele, edrocele

and uro-gynecological pathologies associated. Surgery is performed for grade III and IV (*Figures 1,2*), for grade II in case of major bleeding. Absolute contraindications are the presence of abscess, gangrene, anal stenosis and complete rectal prolapse.

Pre-operative preparation

Preoperatively, the patient is subjected to blood and urine tests, chest X-ray and electrocardiogram. These tests are normally done a few days prior to surgery. These exams are performed prior to admission. The anti-platelet drugs such as aspirin should be discontinued three days before the surgery, while the anticoagulants should be replaced with subcutaneous heparin seven days before. For spinal anesthesia, dietary restrictions vary. The patient must observe fasting after midnight, it is tolerable 2 hours before take, with a little water, antihypertensive and antidiabetic drugs. It would be better perform this type of surgery in the hospital and not in outpatient. Admission occurs on the same day of the surgery and after the anesthesiologist examination the patient is given the informed consent form that must be well understood and signed. Two or three hours before surgery, a low enema is practiced to eliminate solid stool that could reduce the view of the operating field. Finally, a sedative is administered before surgery.

Equipment preference card

- ❖ Team: two surgeons, two nurses.
- ❖ Procedure: stapled hemorrhoidopexy.
- ❖ Anesthesia: spinal.
- ❖ Antibiotic prophylaxis: single dose of prophylactic antibiotic, cephalosporin 2 g (monocef), was given intravenously 2 h before the procedure.
- ❖ Position: lithotomy.
- ❖ Skin preparation: wash with iodopovidone solution (5 min).
- ❖ Equipment: suction apparatus, headlamp (available), urinary catheter, minor instrumentation set, 10 cm × 10 cm gauzes, 1 stapler (special sterile kit consisting of a circular stapler, 33 mm, a circular anoscope with dilator and a suture anoscope), lubricating solution, long gauze for the final buffer.
- ❖ Suture: 2-0 prolene for pursestring, 3-0 polygalactine for hemostasis along staple line.
- ❖ Other equipment: one precision scale to weigh the surgical specimen.

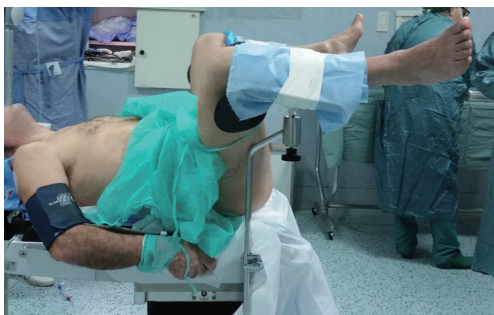

Figure 3 Lithotomy position.

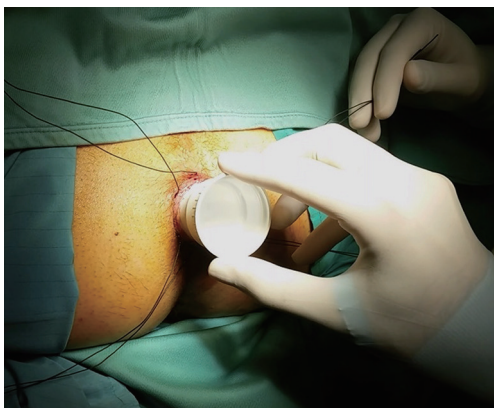

Figure 4 Insertion of the obturator to gently dilate the anal sphincter.

Procedure

The patient can be placed in the lithotomy position, jack knife position or on the left side with knees to chest, it is generally preferred the lithotomy position (*Figure 3*). All patients receive antibiotic prophylaxis before induction of anesthesia. The same way as open hemorrhoidectomy, different types of anesthesia can be chosen, local, spinal or general can be used, and the choice depends on the surgeon's preferences. Urinary catheter is positioned in all patients. After disinfection of the surgical field, stapled hemorrhoidopexy is performed with Longo's technique. The anal canal is manually dilated, with subsequent insertion of the obturator (*Figure 4*). Obturator is extracted and placed inside the circular anal dilator, and simultaneously inserted into the anal canal. After obturator removing will observe the placement within the external hemorrhoidal prolapse (*Figure 5*). Anal dilator is positioned correctly when the inside edge past the dentate line. This will help prevent damage to the dentate line and the

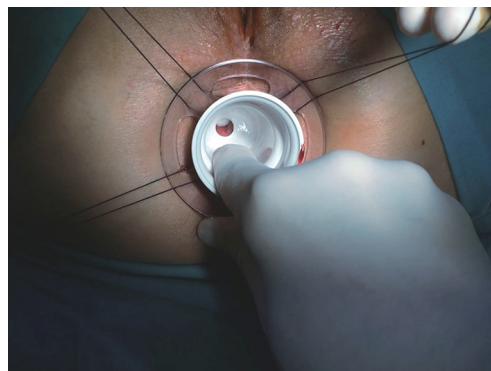


Figure 5 Insertion of circular anal dilator with obturator which is then removed.

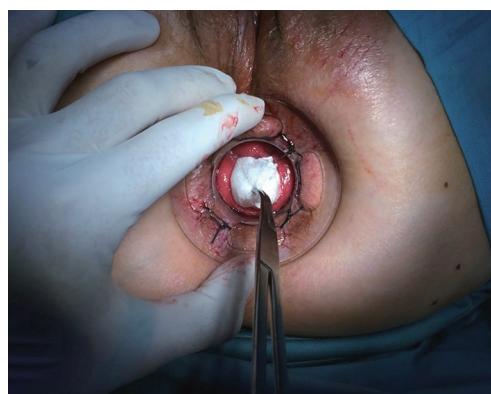


Figure 6 The circular anal dilator is fully affixed to the perineum with three to four sutures (0 silk).

internal sphincter. Externally anal dilator is provided with four slits through which is firmly fixed to the perianal skin with four silk staples (*Figure 6*). Inside the anal dilator is positioned anoscope, the surgeon rotates the anoscope and manufactures a circumferential purse string of 2-0 prolene. The correct height for the suture is at 2 cm from the apex of hemorrhoids, and it must include only mucosa and submucosa (*Figure 7*). At each rotation, the anoscope must be extracted and inserted again to avoid the rolling of the mucosa with consequent asymmetry of the purse-string. At the end, while tightening the suture is inserted a finger inside to check its circumferential integrity. At this point the open circular stapler is introduced in such a way that the anvil goes beyond the suture line. The suture is tightened and closed with a surgical knot around the stem of the stapler and the two ends of the suture thread are pulled through the lateral casing slits. The ends of the suture are

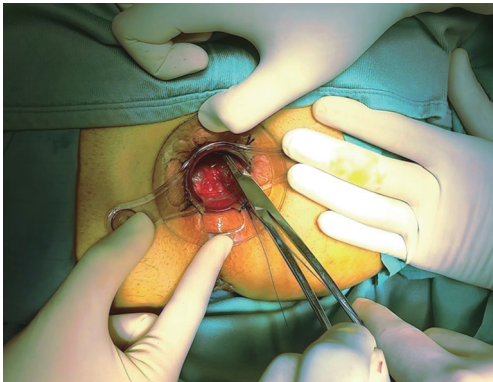


Figure 7 Prolene circumferential purse string.

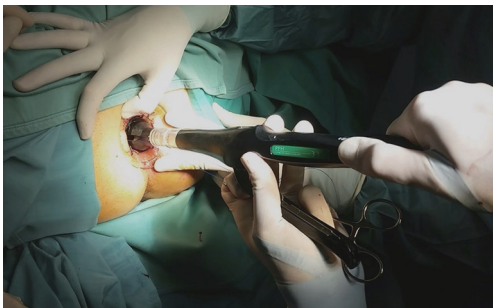


Figure 8 Closure of the stapler and fired.

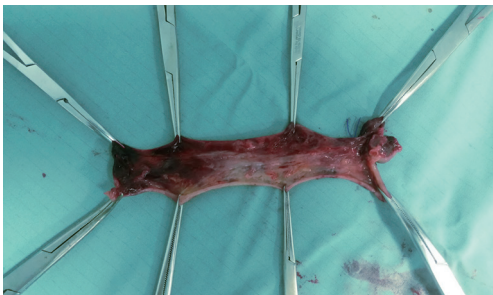


Figure 9 Surgical specimen.

knotted externally or fixed using a clamp. Pulling slightly and constantly the terminal portion of the suture the stapler is tightened so as to favor the entry of the tissue inside the casing. Once the casing reaches the half of the anal dilator the stapler should be pushed into the anal canal and completely closed. The stapler is aligned to the longitudinal axis of the anal canal, and after releasing the block it is fired. The closure must be maintained for 30 seconds to aid in hemostasis (*Figure 8*). In females posterior vaginal wall was

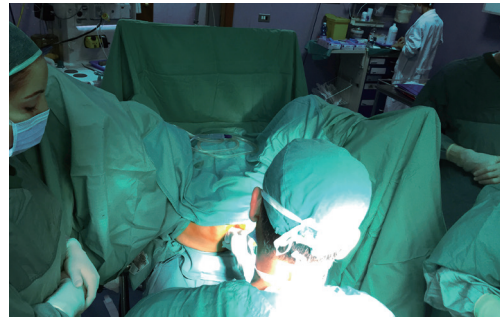

Figure 10 Operating team.

checked before firing the stapler to prevent entrapment. The stapler was then one turn anticlockwise opened to its maximum and gently withdrawn. The staple line should be well checked for possible bleeding that can be corrected with surgical staples of polyglactin 3-0. At the end of operation, anal canal was packed with gauze dressing which was removed in the morning after surgery. The circular sample can be sent for histopathological analysis (*Figure 9*).

Role of team members

The team consists of four persons (*Figure 10*): (I) the surgeon who performs the surgery; (II) assistant (surgeon or trainee surgeon) that helps in aspiration and maintain the correct position of the instrumentation and then draw up the histology; (III) the instrumentalist nurse prepares the surgical site and assists the surgeon with the correct surgical instruments; finally, (IV) a second circulating nurses for all that can occur during surgery and in conclusion cleans instrumentation.

Post-operative management

Patients normally eat the next day. On the same day they remove the urinary catheter and the gauze pad. For the evaluation of postoperative pain it is useful to use the VAS scale (0 indicates no pain; and 10, maximum pain). The pain can be estimated at 12 or 24 hours after surgery and at discharge. Pain therapy consists of a basic analgesia (paracetamol or ketorolac) on request. At discharge the patients receive a laxative syrup to be taken once a day for 15 days and the basic analgesia. Generally the average hospital stay is 2–3 days. The follow-up consists of a patient interview and physical examination to 15 days, 1 month, and 2 months after surgery.

Tips, tricks and pitfalls

After its description, some surgeons have had serious complications, but this was due to technical errors and a short learning curve. This technique is simple but needs to be applied properly. It is important that the technique is transmitted by an experienced surgeon, and including at least 25 interventions as primary surgeon. Another important aspect is the indication for surgical treatment of hemorrhoidal disease. Postoperative bleeding depends on the attention that the operator dedicated to the control of hemostasis, in 1–2% of cases may need reoperation. The cases of stenosis of the staple line are rare but may require dilations. If there is a partial dehiscence of the staple line can suffice observation. The externalized staples should be removed because they can give granulomas that bleed easily and cause prolonged postoperative pain. Compared to open hemorrhoidectomy in 30–40% of the stapled hemorrhoidopexy occurs a defecatory urgency. An answer to this could be that the suture line engages a sensitive area of the lower rectum, but it will resolve spontaneously within the first week.

Some serious complications have been described in the literature: *tearing of the rectal wall* may be due to a purse string too high or irregular, excessive tensile force during the closure of the stapler may also be responsible; irregular or high purse string may also be responsible for the *obliteration of the rectal lumen*; *rectovaginal fistula* can occur in women when the bag in the front wall is too deep and during the closure of the stapler is not checked the posterior vaginal wall; resection of the internal anal sphincter could happen if the purse string is too low, so that the internal sphincter will be pulled into the case of the stapler and partially or totally resected.

Other rare but serious complications: some patients 3–5 days after surgery have intense *pelvic pain*, this symptom often requires the use of benzodiazepines and morphine; rare reports have described some cases of *necrosis* of the staple line and *Fournier's gangrene* of the anus; moreover, also some cases of pelvic emphysema extended to the retroperitoneum have been described. Despite the rarity of these severe complications may occur and are difficult to explain to the patient that has suffered. To date more than 4 million stapled hemorrhoidopexy have been performed worldwide with complications in very low percentage, the most serious events are rarer. For success in this type of surgery it is essential to give adequate information to the patient and perform the surgery with proper technique.

In conclusion this technique is feasible and easily reproducible, the reduction of the haemorrhoidal prolapse occurs in approximately 90% of patients with moderate postoperative pain. After a few days or at most a few weeks bowel habits return to a normal pattern without urgency. However, approximately 40% of patients may have occasional symptoms such as involuntary gas passage and soiling. After one year or longer 11% of patients may present remaining or recurrent prolapse, the reintervention rate is about 10% including a second stapled hemorrhoidopexy, open hemorrhoidectomy, excision of symptomatic skin tags, or rubber band ligation.

Acknowledgements

None.

Footnote

Conflicts of Interest: The authors have no conflicts of interest to declare.

References

1. Aigner F, Gruber H, Conrad F, et al. Revised morphology and hemodynamics of the anorectal vascular plexus: impact on the course of hemorrhoidal disease. *Int J Colorectal Dis* 2009;24:105-13.
2. Haas PA, Fox TA Jr, Haas GP. The pathogenesis of hemorrhoids. *Dis Colon Rectum* 1984;27:442-50.
3. Aigner F, Bodner G, Gruber H, et al. The vascular nature of hemorrhoids. *J Gastrointest Surg* 2006;10:1044-50.
4. Johanson JF, Sonnenberg A. The prevalence of hemorrhoids and chronic constipation. An epidemiologic study. *Gastroenterology* 1990;98:380-6.
5. Riss S, Weiser FA, Schwameis K, et al. Haemorrhoids, constipation and faecal incontinence: is there any relationship? *Colorectal Dis* 2011;13:e227-33.
6. Hardy A, Chan CL, Cohen CR. The surgical management of haemorrhoids--a review. *Dig Surg* 2005;22:26-33.
7. Loder PB, Kamm MA, Nicholls RJ, et al. Haemorrhoids: pathology, pathophysiology and aetiology. *Br J Surg* 1994;81:946-54.
8. Jóhannsson HO, Graf W, Pählman L. Long-term results of haemorrhoidectomy. *Eur J Surg* 2002;168:485-9.
9. Buls JG, Goldberg SM. Modern management of hemorrhoids. *Surg Clin North Am* 1978;58:469-78.
10. Practice parameters for the treatment of hemorrhoids.

- The Standards Task Force American Society of Colon and Rectal Surgeons. *Dis Colon Rectum* 1993;36:1118-20.
11. [Senagore A, Mazier WP, Luchtefeld MA, et al. Treatment of advanced hemorrhoidal disease: a prospective, randomized comparison of cold scalpel vs. contact Nd:YAG laser. *Dis Colon Rectum* 1993;36:1042-9.](#)
 12. [Thomson WH. The nature of haemorrhoids. *Br J Surg* 1975;62:542-52.](#)
 13. [Longo A. Treatment of hemorrhoid disease by reduction of mucosa and hemorrhoidal prolapse with a circular suturing device: a new procedure. Bologna: Proceedings of the 6th World Congress of Endoscopic Surgery, Rome, Italy; Monduzzi Publishing, 1998:777-84.](#)
 14. [Infantino A, Altomare DF, Bottini C, et al. Prospective randomized multicentre study comparing stapler haemorrhoidopexy with Doppler-guided transanal haemorrhoid dearterialization for third-degree haemorrhoids. *Colorectal Dis* 2012;14:205-11.](#)
 15. [Laughlan K, Jayne DG, Jackson D, et al. Stapled haemorrhoidopexy compared to Milligan-Morgan and Ferguson haemorrhoidectomy: a systematic review. *Int J Colorectal Dis* 2009;24:335-44.](#)
 16. [Stuto A, Favero A, Cerullo G, et al. Double stapled haemorrhoidopexy for haemorrhoidal prolapse: indications, feasibility and safety. *Colorectal Dis* 2012;14:e386-9.](#)
 17. [Jayaraman S, Colquhoun PH, Malthaner RA. Stapled hemorrhoidopexy is associated with a higher long-term recurrence rate of internal hemorrhoids compared with conventional excisional hemorrhoid surgery. *Dis Colon Rectum* 2007;50:1297-305.](#)
 18. [Basso L, Cavallaro G, Polistena A. Experience of 3711 stapled haemorrhoidectomy operations \(*Br J Surg* 2006; 93: 226-230\). *Br J Surg* 2006;93:507.](#)
 19. [Van de Stadt J, D'Hoore A, Duinslaeger M, et al. Long-term results after excision haemorrhoidectomy versus stapled haemorrhoidopexy for prolapsing haemorrhoids; a Belgian prospective randomized trial. *Acta Chir Belg* 2005;105:44-52.](#)
 20. [Ganio E, Altomare DF, Milito G, et al. Long-term outcome of a multicentre randomized clinical trial of stapled haemorrhoidopexy versus Milligan-Morgan haemorrhoidectomy. *Br J Surg* 2007;94:1033-7.](#)
 21. [Riss S, Riss P, Schuster M, et al. Impact of stapled haemorrhoidopexy on stool continence and anorectal function: long-term follow-up of 242 patients. *Langenbecks Arch Surg* 2008;393:501-5.](#)
 22. [Kanellos I, Zacharakis E, Kanellos D, et al. Long-term results after stapled haemorrhoidopexy for third-degree haemorrhoids. *Tech Coloproctol* 2006;10:47-9.](#)
 23. [Slim K. Long-term outcome of a multicentre randomized clinical trial of stapled haemorrhoidopexy versus Milligan-Morgan haemorrhoidectomy \(*Br J Surg* 2007; 94: 1033-1037\). *Br J Surg* 2007;94:1306-7; author reply 1307.](#)
 24. [Goligher JC. Advances in proctology. *Practitioner* 1964;193:526-32.](#)

doi: 10.21037/ales.2016.11.02

Cite this article as: Cianci P, Altamura A, Tartaglia N, Fersini A, Calabrese E, De Stefano U, Menga MR, Ambrosi A, Neri V. Stapled hemorrhoidopexy: no more a new technique. *Ann Laparosc Endosc Surg* 2016;1:25.