

Analysis of Complications Following Endoscopically Assisted Treatment of Mandibular Condylar Fractures

Francesco Arcuri, MD, Matteo Bruccoli, MD,
Nicola Baragiotta, MD, Rodolfo Benech, MD,
Sonia Ferrero, MD, Arnaldo Benech, MD, PhD

Background: Within the field of facial reconstructive surgery, minimally invasive procedures are used for the treatment of temporomandibular joint disorders, traumas, and salivary glands and base of skull tumors. The recent report of endoscopic approach for treating subcondylar fractures of the mandible is designed to provide a new method for the treatment of subcondylar fractures using an endoscope through a limited transoral incision. To the best of our knowledge, the advantages and the disadvantages of an endoscopically assisted approach to mandibular condylar fracture have not been verified in studies with a high level of evidence. The objective of this article was to present our experience regarding the endoscopically assisted reduction of subcondylar mandibular fractures with a special focus on complications.

Methods: The records of 14 patients who underwent surgical repair of subcondylar fractures by transoral endoscopic-assisted technique from January 2005 to December 2008 at the Maxillofacial Surgery Unit of Novara Major Hospital were reviewed retrospectively. The measures for the surgical objectives included the following outcome variables: (1) operation time, (2) cosmetic outcome, (3) salivary fistulas, (4) infection, (5) delayed wound healing, (6) facial nerve damage, (7) hemorrhage, (8) repeat interventions, (9) bone consolidation, (10) occlusion changes, and (11) temporomandibular joint dysfunction.

Results: Our data show that we have had 4 complications (28%) experienced by 4 different patients: (1) arterial hemorrhage, (2) facial nerve injury, (3) nonunion, and (4) partial condylar reabsorption.

Conclusions: Although we cannot draw statistically significant conclusions, we think that further randomized clinical trials should be necessary to analyze this method; we believe that there is not an ideal approach for a fracture, but each patient needs to be fully evaluated carefully preoperatively, and the more convenient approach needs to be selected for each case.

Key Words: Mandibular condyle, complications, endoscopic approach

From the Department of Maxillo-Facial Surgery Azienda Ospedaliera Maggiore della Carità University of Piemonte Orientale "Amedeo Avogadro," Novara, Italy.

Received May 23, 2011.

Accepted for publication January 2, 2012.

Address correspondence and reprint requests to Francesco Arcuri, MD, S.C.D.U. di Chirurgia Maxillo-Facciale, Ospedale Maggiore della Carità, Corso Mazzini 18, 28100 Novara, Italy; E-mail: fraarcuri@libero.it

The authors report no conflicts of interest.

Copyright © 2012 by Mutaz B. Habal, MD

ISSN: 1049-2275

DOI: 10.1097/SCS.0b013e31824de328

Fractures of the mandibular condyle are common and account for 9% to 45% of all mandibular fractures. They can occur as single or bilateral fractures and can be concomitant to other fractures of the jaws.¹⁻³

Their treatment is one of the most controversial aspects in maxillofacial surgery; the existence of this issue is based on different criteria and indications even among high-volume centers for open reduction and internal fixation (ORIF) versus closed reduction (CR) with maxillomandibular fixation (MMF).⁴⁻⁶

Open reduction and internal fixation achieves an anatomic reduction of the fracture, but it is still associated with some complications such as (1) salivary fistulas, (2) temporary or permanent facial nerve damage, (3) unaesthetic facial scarring, and (4) bleeding from the maxillary artery and the retromandibular vein. Closed reduction/MMF bypass these risks but present some disadvantages, such as (1) difficulty of anatomic reduction, (2) necessity for a variable period for MMF, and (3) uncertainty about long-term temporomandibular joint (TMJ) function.^{7,8}

Within the field of facial reconstructive surgery, minimally invasive procedures are used for the treatment of TMJ disorders, traumas, and salivary glands and base of skull tumors. The recent report of endoscopic approach for treating subcondylar fractures of the mandible is designed to combine the advantages of the 2 methods mentioned previously; it provides a new method for the treatment of subcondylar fractures using an endoscope through a limited transoral incision.^{9,10}

In conjunction with the transoral approach, the scars are invisible, and the risk of facial nerve damage is minimal; however, the procedure is time-consuming with a steep learning curve. To the best of our knowledge, the advantages and the disadvantages of an endoscopically assisted approach to mandibular condylar fracture have not been verified in studies with a high level of evidence.^{11,12}

The objective of this article was to present our experience regarding the endoscopically assisted reduction of subcondylar mandibular fractures with a special focus on complications.

MATERIALS AND METHODS

The records of 17 patients who underwent surgical repair of subcondylar fractures by transoral endoscopic-assisted technique from January 2007 to December 2009 at the Maxillofacial Surgery Unit of the Novara Major Hospital were reviewed retrospectively.

Four patients had other coexisting facial fractures and consequently were excluded. We could not contact 1 patient; finally, 12 cases were included in this analysis of isolated and monolateral condylar fracture (Fig. 1).

The mean age was 36.7 years (range, 18–63 years); there were 9 men (75%) and 3 women (25%). Mandibular fractures were the results of fall (7 cases), motor vehicle accident (2 cases), assault (2 cases), and sports injury (1 case). The patients had injury to the right condyle in 7 cases and to the left condyle in 5 cases. Inclusions criteria of the following conditions were required as indications to endoscopic treatment: (1) adult patients with no severe comorbidities, (2) displacement of the condyle with an inclination greater than

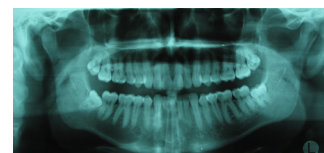


FIGURE 1. Preoperative orthopantogram demonstrating the condylar fracture.

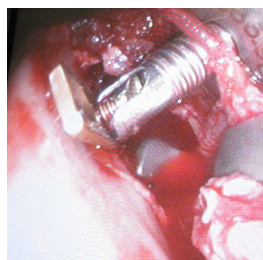


FIGURE 2. Intraoperative photograph showing the osteosynthesis.

30 degrees and an interfragment overlapping greater than 2 mm, (3) malocclusion and/or inability to achieve adequate occlusion with CR, (4) vertical shortening of the ascending ramus. Patients with high condylar intracapsular fractures, nondisplaced fractures, or fractures without functional impairment were excluded from this study and were treated by means of ORIF with a retroauricular approach (intracapsular fractures) or CR and MMF (nondisplaced fractures and fractures without impairment). Panoramic radiographs and computed tomographic scans were taken preoperatively, and an informed consent was obtained. The procedure was performed under general anesthesia using endoscopic instruments (Subcondylar-Ramus Fixation Set; Synthes, West Chester, PA); surgical repair was performed through an intraoral incision near the oblique line; dissection was carried along the lateral side of the ascending ramus using an endoscope (4 mm; 30 degrees; Karl Storz GmbH, Tuttingen, Germany). After adequate anatomic reduction, fixation was obtained using noncompression miniplates (2.0 AO/ASIF; Synthes). Postoperative soft MMF with elastics was required for 7 days. Postoperative conventional radiographic or computed tomographic scans were taken to check fracture osteosynthesis, and a soft diet was ordered for 1 month (Fig. 2). After that, if a patient had mandibular hypomobility, mouth-opening exercises were taught. Patients were then carefully observed with a clinical follow-up performed at 1 week, 1 month, 3 months, 6 months, and 1 year; radiologic controls were scheduled in the immediate postoperative, at 6 months and at 1 year. The median follow-up was 15 months (range, 8–19 months); all patients were controlled until they obtained maximum return to function or failed to keep a scheduled follow-up. The measures for the surgical objectives included the following outcome variables: (1) operation time, (2) cosmetic outcome, (3) salivary fistulas, (4) infection, (5) delayed wound healing, (6) facial nerve damage, (7) hemorrhage, (8) repeat interventions, (9) bone consolidation, (10) occlusion changes, and (11) TMJ dysfunction.

RESULTS

The mean operating time was 112 minutes including MMF; the minimum registered operated time was 56 minutes in a patient with a laterally displaced condyle, and the maximum registered time was 193 minutes for a patient in whom the reduction was challenging because of an intraoperative hemorrhage.

The condyle was placed into the temporalis fossa in all cases. Fixation with 2- and 4-hole miniplates was performed with adequate reduction of the proximal fragment in 11 cases (91.7%); only 1 nonunion (8.3%) was documented in a patient and was the direct consequence of an inadequate reduction. Open surgery was performed 3 months later by a retromandibular approach. Nine subcondylar fractures (75%) were fixed with 1 miniplate. Three cases (25%) underwent fixation with 2 miniplates.

Examination on the basis of conventional radiography in 7 (58.3%) of the 12 patients and axial, coronal, and three-dimensional

computed tomographic scanning in 5 (41.7%) of the 12 patients showed an acceptable osteosynthesis except in 1 patient with a failure of fixation but with a satisfactory occlusion. Adequate consolidation of the fracture was observed in all the patients at the end of the follow-up period.

Temporary weakness of the facial nerve was detected in 1 case (8.3%) with a recovery to normal function after 2.8 months; no patients had permanent weakness of the facial nerve. There was the absence of any salivary fistula, visible scarring, and infections. The mean maximal interincisal mouth opening was 39 mm, and in all patients except 1, good occlusion without dysfunctional symptoms as well as facial morphology was restored. One patient (8.3%) complained of a slight malocclusion and a TMJ dysfunction: partial condylar reabsorption was present at 2 years' follow-up.

DISCUSSION

One of the most common concerns with subcondylar fractures treated by CR/MMF is the limited function of the TMJ because of shortening of the ascending ramus with subsequent malocclusion. Surgeons must be reminded of other complications, such as deviation of mouth opening and habitual dislocation of the TMJ on the contralateral side, before considering CR/MMF.^{7,8}

In adult patients with severe displacement of the proximal fragment, open bite, malocclusion, and loss of the mandibular ramus height, CR/MMF may lead to unsatisfying results. Traditional ORIF has been considered the alternative treatment, but it is not free from complications, such as visible scars, hemorrhage, facial nerve injury, wound infection, avascular necrosis of the proximal segment, and complications related to the osteosynthesis process. New instruments are leading facial reconstructive surgeons to perform endoscopic-assisted treatment of mandibular fractures, but no inclusion criteria are selectively applied such as those reported for ORIF, and serious potential complications should be kept in mind especially by inexperienced surgeons.^{13–15}

Our data show that we have had 4 complications (33.3%) experienced by 4 different patients (Table 1): the first case was due to an arterial hemorrhage that forced us to abandon intraoperatively the endoscopic technique; we convert the procedure to an open approach by a preauricular access, thus increasing the mean time and the morbidity.

The second issue regarded the facial nerve injury: although there was a complete recovery after 1-year follow-up, we experienced a temporary paralysis of cranial nerve VII with a comprehensive complaint from the young patient and the family.

The third complication was due to a poor intraoperative reduction of the mandibular condyle that led to a nonunion that was documented after 3 months by conventional radiography (Fig. 3). Open surgery by a retromandibular approach was performed immediately to correct the bad osteosynthesis.

The last issue regarded the long-term outcome of a patient who developed a partial condylar reabsorption that was present at 2 years'

TABLE 1. Incidence of Postoperative Complications

Complications Following Endoscopic Technique	No. Cases (%)
Failed osteosynthesis	1 (8.3)
Partial condylar reabsorption	1 (8.3)
Intraoperative hemorrhage	1 (8.3)
Facial nerve injury	1 (8.3)
Total	4

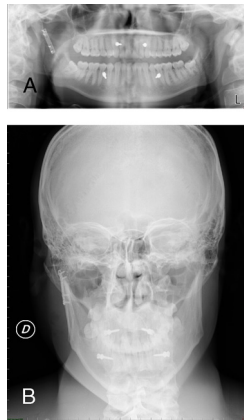

FIGURE 3. A and B, Postoperative conventional radiography demonstrating the successful reduction.

follow-up. This patient complained of a slight malocclusion and a TMJ dysfunction; an orthopantomography was performed, revealing the postoperative complication. Although we can speculate that this condition was due to a potential avascular necrosis of the condylar head, we did not find a feasible etiopathogenesis.

Within the limitations of this investigation, the results show that we had 2 reversible (hemorrhage, 8.3%; nerve injury, 8.3%) and 2 irreversible (nonunion, 8.3%; condylar reabsorption, 8.3%) complications. Complications do occur, and risks and benefits should be preoperatively considered.

Scientific literature is very controversial about endoscopic approach, and the majority of the studies report great success and few complications compared with the traditional methods. Lee et al¹⁶ reported their experience with the endoscopic-assisted treatment of 40 subcondylar fractures, and they observed 3 plate fractures. Chen et al¹⁷ described a normal range of TMJ function 3 months after surgery in 8 patients with subcondylar mandibular fractures, and Schön et al¹⁸ reported good functional results observed 18 months after surgery with maximal interincisal opening of more than 40 mm for 8 patients affected by subcondylar fracture and treated by endoscopic approach.

Kellman¹⁹ used this approach in 12 patients with 17 fractures. He described 2 patients who underwent the anterior open approach and 4 patients who underwent reduction but whose fractures were not fixed with miniplates. Schmelzeisen et al,²⁰ in a large multicenter randomized clinical trial enrolling 74 patients, reported postoperative complications for 10 patients who underwent endoscopic-assisted procedures including 1 inadequate reduction, 1 infection, 3 cases of swelling, and 5 patients with facial nerve damage.

CONCLUSIONS

Although we cannot draw statistically significant conclusions, we think that further randomized clinical trials are necessary to analyze this method; we believe that there is not an ideal approach for a fracture, but each patient needs to be fully evaluated carefully preoperatively, and the more convenient approach needs to be selected for each case.

It will be possible to better understand risks and benefits of this technique, comparing this route with other accesses and eventually extending this surgical technique to other pathologic situations such as developmental disorders and neoplasia at the TMJ area. Intensive training in the endoscopic techniques and handling of the instruments is mandatory before the endoscopic approach for the treatment of condylar fractures can be selected.

REFERENCES

1. Ellis E III, Moos KF, el Attar A. Ten years of mandibular fractures: an analysis of 2,137 cases. *Oral Surg Oral Med Oral Pathol* 1985;59:120
2. Ellis E III, Simon P, Throckmorton GS. Occlusal results after open or closed treatment of fractures of the mandibular condylar process. *J Oral Maxillofac Surg* 2000;58:260–268
3. Ellis E III, Throckmorton GS, Palmieri C. Open treatment of condylar process fractures: of adequacy of repositioning and maintenance of stability. *J Oral Maxillofac Surg* 2000;58:27–34
4. Brandt T, Haug RH. Open versus closed reduction of adult mandibular condyle: a review of the literature regarding the evolution of current thoughts on management. *J Oral Maxillofac Surg* 2003;61:1324–1332
5. Haug RH, Assael LA. Outcomes of open versus closed treatment of mandibular subcondylar fractures. *J Oral Maxillofac Surg* 2001;59:370–375
6. Haug RH, Brandt T. Traditional versus endoscope-assisted open reduction with rigid internal fixation (ORIF) of adult mandibular condyle fractures: a review of the literature regarding current thoughts on management. *J Oral Maxillofac Surg* 2004;62:1272–1279
7. Zachariades N, Mezitis M, Mourouzis C, et al. Fractures of the mandibular condyle: a review of 466 cases—literature review, reflections on treatment and proposals. *J Craniomaxillofac Surg* 2006;34:421
8. Eckelt U, Schneider M, Erasmus F, et al. Open versus closed treatment of fractures of the mandibular condylar process—a prospective randomized multi-centre study. *J Craniomaxillofac Surg* 2006;34:306
9. Jensen T, Jensen J, Norholt SE, et al. Open reduction and rigid internal fixation of mandibular condylar fractures by an intraoral approach: a long-term follow-up study of 15 patients. *J Oral Maxillofac Surg* 2006;64:1771
10. Loukota RA. Endoscopically assisted reduction and fixation of condylar neck/base fractures: the learning curve. *Br J Oral Maxillofac Surg* 2006;44:480
11. Honda T, Nozaki M, Iono N, et al. Endoscope-assisted facial fracture repair. *World J Surg* 2001;25:1075–1083
12. Jacobovitz J, Lee C, Trabulsy PP. Endoscopic repair of mandibular subcondylar fractures. *Plast Reconstr Surg* 1998;101:437
13. Schön R, Fakler O, Gellrich NC, et al. Five-year experience with the transoral endoscopically assisted treatment of displaced condylar mandible fractures. *Plast Reconstr Surg* 2005;116:44
14. Miloro M. Endoscopic-assisted repair of subcondylar fractures. *Oral Surg Oral Med Oral Pathol Oral Radiol Endod* 2003;96:387–391
15. Lauer G, Schmelzeisen R. Endoscope-assisted fixation of mandibular condylar process fractures. *J Oral Maxillofac Surg* 1999;57:36
16. Lee C, Mueller RV, Lee K, et al. Endoscopic subcondylar repair. Functional, aesthetic and radiographic outcomes. *Plast Reconstr Surg* 1998;102:1434–1443
17. Chen C-T, Lai J-P, Tung T-C, et al. Endoscopically assisted mandibular subcondylar fracture repair. *Plast Reconstr Surg* 1999;103:60
18. Schön R, Schramm A, Gellrich NC, et al. Follow-up of condylar fractures of the mandible in 8 patients at 18 months after transoral endoscopic-assisted open treatment. *J Oral Maxillofac Surg* 2003;61:49
19. Kellman RM. Endoscopic assisted repair of subcondylar fractures of the mandible: an evolving technique. *Arch Facial Plast Surg* 2003;5:244–250
20. Schmelzeisen R, Cienfuegos-Monroy R, Schön R, et al. Patient benefit from endoscopically assisted fixation of condylar neck fractures—a randomized controlled trial. *J Oral Maxillofac Surg* 2009;67:147–158