

The continued use of radiation alone for NLPHL is an accident of history and not the result of an evidence-based comparison. Clinicians should consider treating limited stage NLPHL the same as classical HL, especially given the available evidence that doing so appears to produce superior treatment outcomes.

Joseph M. Connors

BCCA Centre for Lymphoid Cancer, University of British Columbia, Vancouver, BC, Canada

Conflict-of-interest disclosure: The author declares no competing financial interests.

Correspondence: Joseph M. Connors, BCCA Centre for Lymphoid Cancer, University of British Columbia, 600 West 10th Ave, Vancouver, BC V5Z 4E6, Canada; e-mail: jconnors@bccancer.bc.ca.

References

1. Nogová L, Reineke T, Brillant C, et al; German Hodgkin Study Group. Lymphocyte-predominant and classical Hodgkin's lymphoma: a comprehensive analysis from the German Hodgkin Study Group. *J Clin Oncol*. 2008;26(3):434-439.

2. Savage KJ, Skinnider B, Al-Mansour M, Sehn LH, Gascoyne RD, Connors JM. Treating limited-stage nodular lymphocyte predominant Hodgkin lymphoma similarly to classical Hodgkin lymphoma with ABVD may improve outcome. *Blood*. 2011;118(17):4585-4590.
3. Feugier P, Labouyrie E, Djeridane M, et al. Comparison of initial characteristics and long-term outcome of patients with lymphocyte-predominant Hodgkin lymphoma and classical Hodgkin lymphoma at clinical stages IA and IIA prospectively treated by brief anthracycline-based chemotherapies plus extended high-dose irradiation. *Blood*. 2004;104(9):2675-2681.
4. Nogová L, Reineke T, Eich HT, et al. Extended field radiotherapy, combined modality treatment or involved field radiotherapy for patients with stage IA lymphocyte-predominant Hodgkin's lymphoma: a retrospective analysis from the German Hodgkin Study Group (GHSG). *Ann Oncol*. 2005;16(10):1683-1687.
5. Chen RC, Chin MS, Ng AK, et al. Early-stage, lymphocyte-predominant Hodgkin's lymphoma: patient outcomes from a large, single-institution series with long follow-up. *J Clin Oncol*. 2010;28(1):136-141.
6. Wirth A, Yuen K, Barton M, et al. Long-term outcome after radiotherapy alone for lymphocyte-predominant Hodgkin lymphoma: a retrospective multicenter study of the Australasian Radiation Oncology Lymphoma Group. *Cancer*. 2005;104(6):1221-1229.

© 2013 by The American Society of Hematology

To the editor:

Homozygosity by descent of a 3Mb chromosome 17 haplotype causes coinheritance of Glanzmann thrombasthenia and primary ciliary dyskinesia

Glanzmann thromboasthenia (GT) is an autosomal recessively inherited bleeding diathesis, and mutations within the genes (ITGA2B and ITGB3) that code for subunits of the α IIb β 3 integrin have been shown to be responsible for this disorder.¹

The GT clinical phenotype can be modulated by a series of factors, acquired as well as inherited.²

We now report the coinheritance in 2 siblings of GT and primary ciliary dyskinesia (PCD). A 5-generation family history excluded consanguinity. Approval was obtained from the Ospedali Riuniti (Foggia, Italy) Institutional Review Board for these studies. Written informed consent was obtained from the parents in accordance with the Declaration of Helsinki.

The patients were a 9-year-old boy and his 6-year-old brother (Figure 1) who had mucocutaneous bleeding diathesis soon after birth. A diagnosis of GT was confirmed by complete platelet failure to aggregate in response to adenosine 5-diphosphate, epinephrine, collagen, and thrombin and lack of the α IIb β 3 platelet receptor in flow cytometry studies. In both patients, the presence of an opposite position of the internal organs (heart, stomach, spleen, liver, and gallbladder) and bronchiectasis allow for the diagnosis of PCD. In both of these patients, an atrial septal defect, a patent foramen ovale, and an ostium secundum (in the older and in the younger boy, respectively), was observed. In addition, sinus disease with recurrent infections gave rise to recurrent epistaxis, which needed the combined use of recombinant activated factor VII and antifibrinolytics, because of refractoriness to platelet transfusion due to the appearance of antibodies against platelet antigens. Both parents and the 14-year-old sister were asymptomatic.

Sequencing of ITGA2B and ITGB3 genes revealed the presence of a novel homozygous nonsense mutation within the ITGB3 gene (p.W264X, c.G33289A). Both parents were heterozygous, whereas the sister did not carry the mutation.

Clinical and instrumental information indicated the cosegregation of both diseases and suggested the contemporary inheritance of mutated alleles of different genes, raising the possibility of their linked

germinal transmission. Usually, because of crossing over, genes follow the expected inheritance patterns predicted by Mendel's Theory of Independent Assortment, and their probability to be separated across generations depends on how far genes are.

PCD is inherited in an autosomal recessive manner and shows high locus heterogeneity, ~20 genes being known to be associated with the disease.³⁻¹⁰ One of them, CCDC103, is located in a 3Mb segment on the chromosome 17q, between the ITGA2B and ITGB3 genes. Thus, we explored whether the clinical phenotype observed in the family investigated might be ascribed to the inheritance of a chromosome 17q haplotype. In both patients, sequencing of the CCDC103 gene showed a homozygous missense mutation, p.H154P (c.A2826C), previously reported in families of Pakistan and German origin.⁷ Both parents and grandmothers were heterozygous, whereas the sister did not carry the mutation. To further confirm the pathogenetic role of a chromosome 17q haplotype inheritance, we analyzed informative gene polymorphisms. All alleles cosegregate (Figure 1), providing evidence of the existence of a 3Mb chromosome 17q haplotype, which carries both the ITGB3 p.W264X and the CCDC103 p.H154P gene mutation. The presence of an inherited haplotype and the absence of self-reported consanguinity strongly suggest a common ancestor and a founder effect of a rare haplotype.

To our knowledge, this paper is the first to describe coinheritance of GT with PCD, a hereditary disease that affects GT clinical phenotype by modulating bleeding risk because of the presence of sinusitis, bronchiectasis, and malformations needing surgical approaches, as atrial septal defects.

Giovanna D'Andrea

Genetica Medica, Università di Foggia, Foggia, Italy

Michele Schiavulli

Centro Regionale per le Emocoagulopatie, Azienda Ospedaliera Santobono-Pausillipon, Naples, Italy

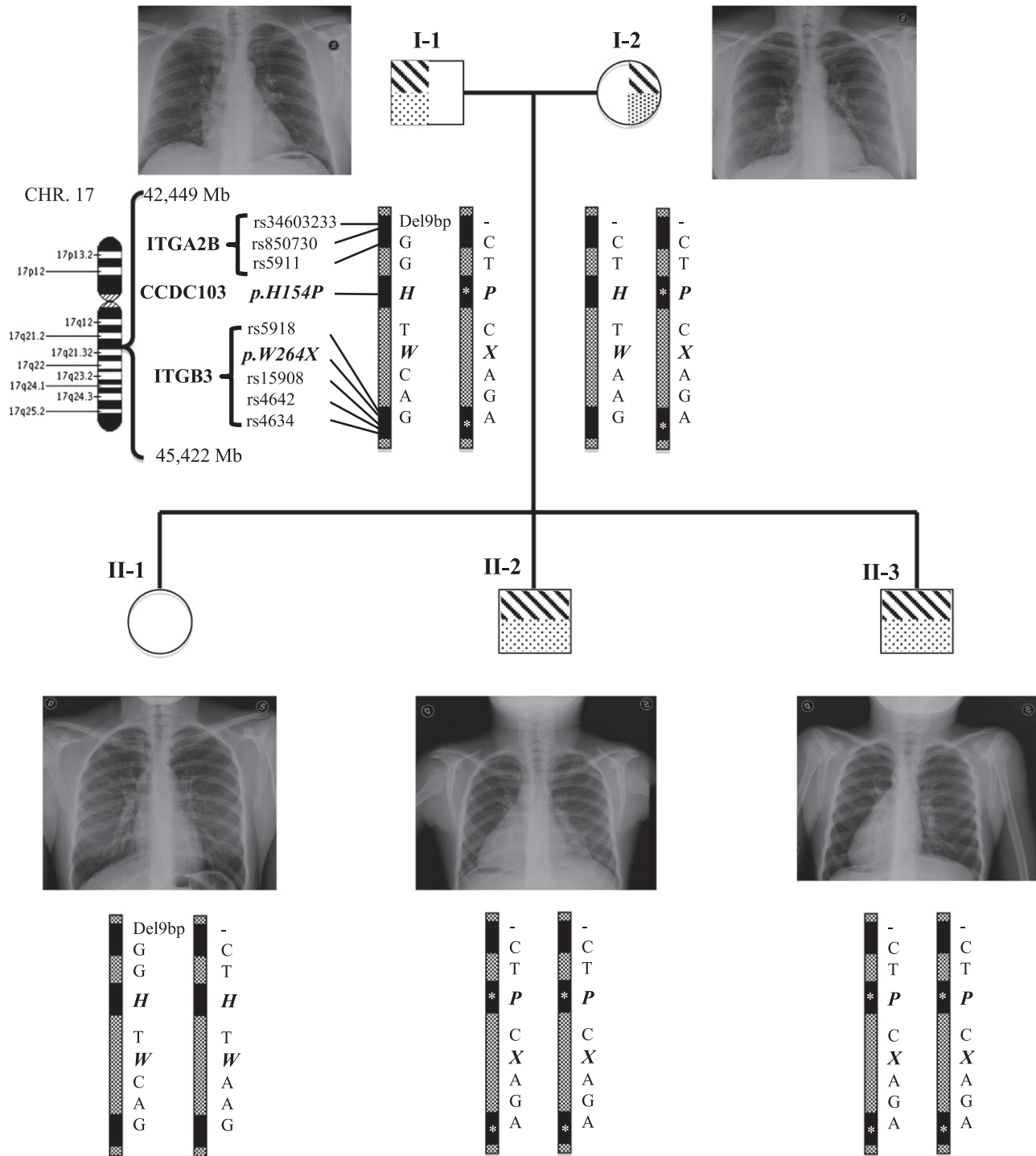


Figure 1. The genealogical chart of an Italian family with coinheritance of GT and PCD. Chest radiology images are shown. Below is an ideogram of the chromosome 17 and the 3Mb segment containing the ITGA2B, ITGB3, and CCDC103 genes (filled boxes). Genotypes of common and causative mutations (bold) are indicated, and the inherited causative haplotype is reported (asterisks).

Claudia Dimatteo
 Genetica Medica, Università di Foggia,
 Foggia, Italy

Rosa Santacroce
 Genetica Medica, Università di Foggia,
 Foggia, Italy

Egidio Guerra
 Divisione di Radiologia, Ospedali Riuniti Foggia,
 Foggia, Italy

Vittoria A. C. Longo
 Genetica Medica, Università di Foggia,
 Foggia, Italy

Elvira Grandone

*Unita' di Aterosclerosi e Trombosi,
Scientific Institute for Research, Hospitalization and Health Care,
Casa Sollievo della Sofferenza,
San Giovanni Rotondo, Italy*

Maurizio Margaglione

*Genetica Medica, Università di Foggia,
Foggia, Italy*

Contribution: G.D. performed experiments, collected and analyzed data; M.S. recruited patients, collected and interpreted clinical data, and contributed to and revised the manuscript; C.D. performed experiments and made the figures; R.S. revised the manuscript, and contributed to the analysis of the results; E. Guerra performed radiology studies and revised the manuscript; V.A.C.L. performed experiments and revised the manuscript; E. Grandone designed the study, interpreted the data, and revised the draft and final manuscript; and M.M. designed and performed the research, collected, analyzed, and interpreted the data, and wrote the draft and final manuscript.

Conflict-of-interest disclosure: The authors declare no competing financial interests.

Correspondence: Maurizio Margaglione, Medical Genetics, Department of Clinical and Experimental Medicine, University of Foggia, viale Pinto, Foggia 71122 – Italy; e-mail: m.margaglione@unifg.it.

References

1. George JN, Caen JP, Nurden AT. Glanzmann's thrombasthenia: the spectrum of clinical disease. *Blood*. 1990;75(7):1383-1395.
2. D'Andrea G, Margaglione M; Glanzmann's Thrombasthenia Italian Team (GLATIT). Glanzmann's thrombasthenia: modulation of clinical phenotype by alpha2C807T gene polymorphism. *Haematologica*. 2003;88(12):1378-1382.
3. Ferkol TW, Leigh MW. Ciliopathies: the central role of cilia in a spectrum of pediatric disorders. *J Pediatr*. 2012;160(3):366-371.
4. Leigh MW, Pittman JE, Carson JL, et al. Clinical and genetic aspects of primary ciliary dyskinesia/Kartagener syndrome. *Genet Med*. 2009;11(7):473-487.
5. Becker-Heck A, Zohn IE, Okabe N, et al. The coiled-coil domain containing protein CCDC40 is essential for motile cilia function and left-right axis formation. *Nat Genet*. 2011;43(1):79-84.
6. Horani A, Druley TE, Zariwala MA, et al. Whole-exome capture and sequencing identifies HEATR2 mutation as a cause of primary ciliary dyskinesia. *Am J Hum Genet*. 2012;91(4):685-693.
7. Kott E, Duquesnoy P, Copin B, et al. Loss-of-function mutations in LRRC6, a gene essential for proper axonemal assembly of inner and outer dynein arms, cause primary ciliary dyskinesia. *Am J Hum Genet*. 2012;91(5):958-964.
8. Hjeij R, Lindstrand A, Francis R, et al. ARMC4 mutations cause primary ciliary dyskinesia with randomization of left/right body asymmetry. *Am J Hum Genet*. 2013;93(2):357-367.
9. Tarkar A, Loges NT, Slagle CE, et al; UK10K. DYX1C1 is required for axonemal dynein assembly and ciliary motility. *Nat Genet*. 2013;45(9):995-1003.
10. Panizzi JR, Becker-Heck A, Castleman VH, et al. CCDC103 mutations cause primary ciliary dyskinesia by disrupting assembly of ciliary dynein arms. *Nat Genet*. 2012;44(6):714-719.



blood[®]

2013 122: 4289-4291
doi:10.1182/blood-2013-09-528943

Homozygosity by descent of a 3Mb chromosome 17 haplotype causes coinheritance of Glanzmann thrombasthenia and primary ciliary dyskinesia

Giovanna D'Andrea, Michele Schiavulli, Claudia Dimatteo, Rosa Santacroce, Egidio Guerra, Vittoria A. C. Longo, Elvira Grandone and Maurizio Margaglione

Updated information and services can be found at:
<http://www.bloodjournal.org/content/122/26/4289.full.html>

Articles on similar topics can be found in the following Blood collections
[Platelets and Thrombopoiesis](#) (689 articles)

Information about reproducing this article in parts or in its entirety may be found online at:
http://www.bloodjournal.org/site/misc/rights.xhtml#repub_requests

Information about ordering reprints may be found online at:
<http://www.bloodjournal.org/site/misc/rights.xhtml#reprints>

Information about subscriptions and ASH membership may be found online at:
<http://www.bloodjournal.org/site/subscriptions/index.xhtml>