

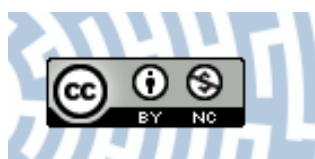


You have downloaded a document from  
**RE-BUŚ**  
repository of the University of Silesia in Katowice

**Title:** Increase in the incidence of parotid gland tumors in the years 2005-2014

**Author:** Grażyna Stryjewska-Makuch, Bogdan Kolebacz, Małgorzata A. Janik, Agnieszka Wolnik

**Citation style:** Stryjewska-Makuch Grażyna, Kolebacz Bogdan, Janik Małgorzata A., Wolnik Agnieszka. (2017). Increase in the incidence of parotid gland tumors in the years 2005-2014. "Otolaryngologia Polska" (2017, nr 2, s. 29-34).



Uznanie autorstwa - Użycie niekomercyjne - Licencja ta pozwala na kopiowanie, zmienianie, remiksowanie, rozprowadzanie, przedstawienie i wykonywanie utworu jedynie w celach niekomercyjnych. Warunek ten nie obejmuje jednak utworów zależnych (mogą zostać objęte inną licencją).



# Increase in the incidence of parotid gland tumors in the years 2005–2014

**Authors' Contribution:**  
A – Study Design  
B – Data Collection  
C – Statistical Analysis  
D – Data Interpretation  
E – Manuscript Preparation  
F – Literature Search  
G – Funds Collection

Grażyna Stryjewska-Makuch<sup>1BDEF</sup>, Bogdan Kolebacz<sup>1A</sup>, Małgorzata A. Janik<sup>2C</sup>,  
Agnieszka Wolnik<sup>1BF</sup>

<sup>1</sup>Independent Public Research Hospital No. 7 of Silesian Medical University in Katowice, Upper Silesian Medical Centre, Department of Laryngology and Laryngological Oncology, ul. Ziołowa 45/47, 40-635 Katowice, Poland

<sup>2</sup>University of Silesia, Institute of Informatics, Department of Biomedical Computer Systems, ul. Będzińska 39, 41-200 Sosnowiec, Poland

Article history: Received: 30.08.2016 Accepted: 15.12.2016 Published: 30.04.2017

## ABSTRACT:

**Introduction:** Salivary gland tumours account for 3-6% of tumours of the head and neck. About 80% of salivary gland tumors occur in parotid glands, 10-17% of which are malignant. The aim of the study was to assess whether there is an upward trend in cancer incidence within the parotid glands, with particular emphasis on cancers.

**Materials and methods:** 322 patients underwent surgery and 328 parotid gland tumours were removed in the years 2005-2014 at the Department of Laryngology and Laryngological Oncology of the Upper Silesian Medical Centre in Katowice-Ochojec. Clinical, histopathological and statistical analyses of the removed parotid gland tumours were performed.

**Results and discussion:** A significant increase in the incidence of benign tumours, especially mixed and Warthin tumours, was demonstrated. There was no significant increase in the number of malignant tumours over the analysed period of time.

## KEYWORDS:

parotid gland neoplasms, epidemiology, histopathology

## INTRODUCTION

Salivary glands may be affected by inflammation, sialolithiasis, as well as benign or malignant tumours. Salivary gland tumours account for 3-6% of head and neck tumours, 70-85% of which are found in the salivary glands. These tumours are mostly benign – 80-95%, whereas malignant tumours account for 10-17% of cases [1-7]. The 1991 WHO histological classification lists 32 types of tumours of epithelial glandular tissue of the salivary glands in addition to numerous non-epithelial tumours, lymphomas and secondary malignancies. From a clinical perspective, it is important whether the malignant tumour is low-grade (mucoepidermoid carcinoma and polymorphous low-grade adenocarcinoma, acinic cell carcinoma, basal cell adenocarcinoma, epithelial-myoeithelial carcinoma, cystocarcinoma), intermediate-grade (adenoid cystic carcinoma, sebaceous carcinoma, myoeithelial carcinoma, lymphoepithelial carcinoma) or high-grade (squamous cell carcinoma, mucoepidermoid high-grade carcinoma, carcinoma ex pleomorphic adenoma, salivary duct carcinoma, oncocytic carcinoma

or adenocarcinoma not otherwise specified). Tumours of non-epithelial origin (hemangiomas, lipomas, tumours of neurogenic or mesenchymal origin, sarcomas), lymphomas, secondary tumours and non-classified tumours may also be found within salivary glands.

Histopathological analysis of parotid gland tumours in patients, who underwent surgery at the Department of Otolaryngology and Laryngological Oncology of the Upper Silesian Medical Centre in Katowice-Ochojec in the years 2005-2014, aimed to verify the hypothesis whether the upward trend in the incidence of cancer applies to the major salivary glands. We were interested in the predominant histopathological type of cancer in the parotid glands, as well as any correlations between the incidence of cancer and gender, patient age, and side of the salivary gland (right vs. left). Attention was focused on the time elapsed between detection of the tumor by the patient and hospital admission for treatment, clinical stage of the disease, presence of facial nerve paralysis before and after surgery, and possible cancer recurrence after treatment.

## MATERIALS AND METHODS

Three hundred and twenty-two patients were treated for the parotid gland tumour in the years 2005-2014. The operated group consisted of 172 women and 150 men aged 21 to 87 years. In 6 patients, two histologically different tumours were found in the removed parotid glands; therefore, 328 tumours were examined in the group of 322 patients. All patients underwent surgical removal of the parotid gland with identification and preservation of the facial nerve. The surgical technique was uniform.

All cases of malignant tumours were subject to detailed analysis. Clinical staging of the tumour was evaluated according to the 2009 TNM classification in accordance with the guidelines of the International Union Against Cancer (IUAC) and the American Joint Committee of Cancer (AJCC).

Classification of lymph nodes was based on histopathological evaluation. We focused on the time elapsed between the moment patient noticed the tumour and the moment of surgery as well as the presence of facial nerve paralysis before and after excision of the salivary gland. Statistical analysis encompassed the relationship between tumor incidence and patient gender and age. Moreover, we checked whether there was an upward trend in the incidence of benign and malignant tumours of the examined salivary glands.

## RESULTS

As expected, benign tumours predominated in the study material, accounting 86.9% (285) of all examined lesions. Malignant tumours were diagnosed in 43 patients representing 13.1% of all cases. Warthin tumours (118 cases) and mixed tumours (109 cases) clearly prevailed among benign tumours. Detailed histopathological analysis of benign tumours identified in the removed salivary glands is shown in Table I.

In five removed salivary glands Warthin tumour was accompanied by cystadenoma oncocyticum, basal cell adenoma, and in three cases – by a mixed tumour. In 38 salivary glands the pathologist confirmed presence of satellite lesions in both removed parotid gland lobes. In 28 salivary glands these lesions were benign, whereas malignancy was confirmed in ten. Malignancy was diagnosed in 27 women and 16 men aged 21-86 years. Malignant tumours were most often observed in patients aged 51 to 69 years (24 out of 43 patients).

We found 22 and 21 malignant tumours in the right and left parotid gland, respectively. In contrast to benign tumours, there was no predominance of one histopathological type of a

tumour. B-cell lymphoma was recognised in 10 cases (23.3%), in mucoepidermoid carcinoma in 8 cases (18.6%), and there were 7 cases (16.3%) of adenocarcinoma and 5 cases of acinic cell carcinoma. The distribution of malignant tumours in the parotid salivary glands according to the histopathological type of tumour is shown in Table II.

Twenty patients reported a parotid gland tumour within a one-year period, 14 patients - between one year and four years, and 5 patients within twenty-five years. Four people had great difficulty specifying the duration of the disease. Each case of diagnosed malignancy was evaluated. Twelve T1, sixteen T2, ten T3 and five T4a tumours were removed. In 12 cases, malignant tumours of the salivary glands were accompanied by metastasis to regional lymph nodes classified as N1, while no metastatic nodes were found in 27 patients. In two patients, the nodes were classified as N2a, and in two others as N2b. Nine of the treated patients were in clinical stage I of the disease, stage II – 10 patients, stage III – 16 patients and stage IV - 8 patients.

Transient weakness of the superior branches of the facial nerve was observed in 2 patients following complete removal of the parotid gland due to cancer, while the inferior branches were affected in 5 patients. In 8 cases we noted paralysis of all branches of the facial nerve, and in this group the nerve was resected deliberately for oncological reasons in one patient.

In order to assess the relationship between the number of tumours and the year, the Spearman's rank correlation coefficients were calculated. Based on the results, it was found that the total number of tumours increased over the subsequent years ( $r=0.8632$ ,  $p=0.0013$ ), and in particular there was an increase in the incidence of mixed tumour ( $r=0.7131$ ,  $p=0.0161$ ) and Warthin tumour ( $r=0.8659$ ,  $p=0.0012$ ). The total number of tumours also rose ( $p=0.0002$ ), but only an increase in the incidence of benign tumours was significant. The correlation for benign tumours was  $r=0.8632$  ( $p=0.0013$ ), while there was no correlation with time for malignant tumours ( $r=0.1896$ ,  $p=0.5998$ ). Chi-square test was applied to assess the differences in the number of tumours in subsequent years. No significant differences in the average number of malignant tumours over the subsequent years were observed, which is consistent with the results obtained from correlation analysis. However, the number of malignant tumours is statistically different ( $p<0.05$ ) from the number of benign tumours in each of the indicated time points.

## DISCUSSION

According to the available literature, benign tumours are most common in the parotid gland, with a predominance of mixed

**Tab. I.** Benign tumours of the parotid glands operated in the years 2005-2014.

	HISTOLOGICAL TYPE OF TUMOUR	YEAR										NUMBER OF TUMOURS
		2005	2006	2007	2008	2009	2010	2011	2012	2013	2014	
1	mixed tumour	4	11	3	4	15	11	10	18	13	20	109
2	Warthin tumour	7	6	10	8	7	10	11	21	18	20	118
3	basal cell adenoma	1	0	1	0	0	0	1	2	1	0	6
4	cystadenoma oncocyticum	0	0	1	0	1	0	0	2	1	0	5
5	myoepithelioma	0	1	0	0	1	0	0	0	1	1	4
6	lipoma	1	1	1	0	0	0	0	0	2	2	7
7	cyst	0	0	1	1	0	2	0	2	0	3	9
8	pilomatrixoma	0	0	1	0	0	0	0	0	0	0	1
9	lymphoepithelial cyst	0	0	0	0	2	2	0	2	1	0	7
10	fibrosis	0	0	1	0	0	0	0	0	2	0	3
11	melanosis	0	0	1	0	0	0	0	0	0	0	1
12	chronic inflammation	0	1	2	0	0	2	0	0	0	0	5
13	hyalinisation	0	0	0	0	1	0	0	0	0	0	1
14	atheroma	0	0	0	0	1	0	0	1	0	0	2
15	lymphadenitis chronica	0	0	0	0	0	0	1	1	1	0	3
16	progressive transformation of germinal center	0	0	0	0	0	0	1	0	0	0	1
17	epithelial-myoepithelial carcinoma	0	0	0	0	0	0	0	0	2	0	2
18	monomorphic adenoma	0	0	0	0	0	0	1	0	0	0	1
	Total	13	20	22	13	28	27	25	49	42	46	285

tumours over lymphadenomas [1, 2]. In some works, this preponderance is more than double [3-10]. Warthin tumours were more often found in our material. This tumour can be multifocal [11] and in 3-14% of cases may be found bilaterally [12, 13]. The main factors affecting the incidence of lymphadenoma include long-term smoking [14], ionizing radiation [15] and previous infection with the Epstein-Barr virus [16].

Development of a malignant tumour within the lymphadenoma is rare and malignant transformation may involve lymphatic stroma giving rise to a lymphoma [17, 18]. Warthin tumour is not classified as oncocytic carcinoma, but they two can coexist [19]. In our material, in five operated parotid glands Warthin tumour coexisted with benign epithelial tumours with oncocytic differentiation – cystadenoma oncocyticum.

Malignant tumours of the operated parotid glands, which accounted for 13.1% of the study material, were analysed in detail. In the literature the incidence of malignant parotid gland

tumours ranges from 10.5% to 25% [7, 15, 20-25]. Among malignant tumours in adults, the most frequently observed were mucoepidermoid carcinoma [8, 24, 28], adenoid cystic carcinoma [2, 15] and squamous carcinoma [5]. A large retrospective analysis of 2737 patients in the Netherlands [15] demonstrated that the incidence of adenoid cystic carcinoma and adenocarcinoma was similar (16.5% each). Acinic cell cancer was present in 14.78% and mucoepidermoid carcinoma in 13.6% of patients. In the material obtained from the Taiwanese population [1] acinic cell cancer was found most frequently, namely in 22.9% of cases.

There are not many cases of B-cell lymphoma described in the available literature. The work of Fenstein [29] presents an analysis of the data acquired over 35 years of observation from the National Cancer Institute's Surveillance, Epidemiology, and End Results. Moreover, it describes 2140 patients with primary parotid gland lymphoma. B-cell lymphomas accounted for 27.9% of tumours in this group.

**Tabela II.** Malignant tumours of the parotid glands operated in the years 2005-2014.

	HISTOLOGICAL TYPE OF TUMOUR	YEAR										NUMBER OF TUMOURS
		2005	2006	2007	2008	2009	2010	2011	2012	2013	2014	
1	B-cell lymphoma	2	1	1	0	0	1	1	0	0	4	10
2	adenocarcinoma	0	0	0	2	1	0	1	1	0	2	7
3	mucoepidermoid carcinoma	0	2	0	0	0	1	0	0	2	3	8
4	acinic cell carcinoma	1	1	0	0	0	0	0	0	2	1	5
5	clear cell carcinoma	0	0	0	1	0	0	0	0	0	0	1
6	melanotic carcinoma	0	0	0	1	0	0	0	0	0	1	2
7	epithelial-myoepithelial carcinoma	0	1	1	0	0	0	0	0	1	0	3
8	squamous carcinoma	0	1	0	0	0	0	0	0	0	0	1
9	undifferentiated carcinoma	0	0	0	0	0	1	0	0	0	0	1
10	papillary carcinoma	0	0	0	0	0	0	0	1	0	0	1
11	Lymphoepithelial tumour	0	0	0	0	0	0	0	0	1	0	1
12	sarcoma	0	0	0	0	0	0	0	0	1	0	1
13	malignant mixed tumour	0	0	0	0	0	0	0	0	0	2	2
	number of malignant tumours	3	6	2	4	1	3	2	1	8	13	43
	number of benign tumours	13	20	22	13	28	27	25	49	42	46	285
	number of all the removed tumours	16	26	24	17	29	30	27	50	50	59	328

We chose the total parotidectomy as the only method of removing parotid gland tumours. The number of detected tumour satellite lesions in both removed lobes of 37 operated salivary glands confirmed the validity of this decision. The left satellite lesion could be the starting point of another cancer, and reoperation of the salivary glands is associated with a high risk of damage to the facial nerve. The duration of symptoms among our patients was similar to that presented by other authors [7] and lasted for about one year prior to entering the hospital.

The present study recorded and confirmed statistically an overall increase in the incidence of parotid gland tumours over the analysed years. Other authors operating on large salivary glands made similar observations [7, 15, 21, 22]. An increase

in the number of removed cancers failed to prove unequivocally a statistically significant rise in the number of malignant parotid gland tumours.

## CONCLUSIONS

The number of operated tumours of the parotid glands doubled over the years 2012-2014. A significant increase in the number of removed malignant tumours was reported in 2014. Thirteen tumours were removed, which accounted for 30% of malignant tumours operated in the years 2005-2014. The data do not permit to conclude that there is a statistically significant upward trend in the incidence of malignant parotid gland tumours over the analysed period of time.

## REFERENCES

- Chan W.H., Lee K.W., Chiang F.Y., Ho K.Y., Chai C.Y., Kuo W.R.: Features of parotid gland diseases and surgical results in southern Taiwan. *Kaohsiung J. Med. Sci.* 2010; 26: 483-492.
- Fonseca F.P., de Carvalho M.V., de Almeida O.P., Rangel A.L., Takizawa M.C., Bueno A.G., Vargas P.A.: Clinicopathologic analysis of 493 cases of salivary gland tumours in a Southern Brazilian population. *Oral Surg. Oral Med. Oral Pathol. Oral Radiol.* 2012; 114: 230-239.



3. Gierek T., Majzel K., Witkowski M., Jura-Szołtys E.: Gruczolaki limfatyczne ślinianki przyusznej – analiza 75 przypadków. *Otolaryngol. Pol.* 2004; 58: 899–902.
4. Ziółkowska M., Bień S., Okła S., Żyłka S.: Charakterystyka epidemiologiczno-kliniczna 705 nowotworów gruczolów ślinowych. *Otolaryngol. Pol.* 2013; 67: 154–163.
5. Żuchnik-Wrona A., Kupisz K.: Guzy ślinianek przyusznych – diagnostyka i leczenie w oparciu o materiał Oddziału Otolaryngologii Chirurgii Głowy i Szyi Wojewódzkiego Szpitala Specjalistycznego w Lublinie w latach 2000–2005. *Borgis – Nowa Medycyna.* 2006; 2: 34–37.
6. Lee Y.M., Choi H.J., Kim J.W., Kim J.H.: Parotid gland tumours in a Korean population. *J. Craniofac. Surg.* 2012; 23: 205–209.
7. Wierzbicka M., Kopeć T., Szyfter W., Bem G.: Epidemiologia guzów niezłośliwych ślinianek podżuchwowych i przyusznych na podstawie 675 przypadków. *Otolaryngol. Pol.* 2010; 64: 281–287.
8. Tilakaratne W.M., Jayasooriya P.R., Tennakoon T.M., Saku T.: Epithelial salivary tumours in Sri Lanka: a retrospective study of 713 cases. *Oral Surg. Oral Med. Oral Pathol. Oral Radiol. Endod.* 2009; 108: 90–98.
9. Bartkowiak Ł., Przewoźna J., Ryglewicz B., Stefaniak K.: Guzy nowotworowe ślinianek – analiza retrospektywna materiału operacyjnego Kliniki Otolaryngologii i Onkologii Laryngologicznej Akademii Medycznej im. Karola Marcinkowskiego w Poznaniu w latach 1995–2002 ze szczególnym uwzględnieniem guzów nawrotowych. *Nowiny Lekarskie.* 2006; 75: 320–322.
10. Chulam T.C., Noronha Francisco A.L., Goncalves Filho J., Pinto Alves C.A., Kowalski L.P.: Warthin's tumour of the parotid gland: our experience. *Acta Otorhinolaryngol. Ital.* 2013; 33: 393397.
11. Przewoźny T., Stankiewicz C., Narożny W., Kuczkowski J.: Guz Warthina ślinianki przyusznej. Analiza epidemiologiczno-kliniczna 127 przypadków. *Otolaryngol. Pol.* 2004; 58: 583–591.
12. Przewoźny T., Stankiewicz C., Narożny W., Kuczkowski J.: Obustronny guz Warthina ślinianki przyusznej. *Otolaryngol. Pol.* 2004; 58: 1203–1209.
13. Bilewicz R., Burduk P.K., Burduk D., Kaźmierczak W.: Mnogie obustronne gruczolaki limfatyczne ślinianek przyusznych. *Otolaryngol. Pol.* 2006; 60: 139–142.
14. Yoo G.H., Eisele D.W., Askin F.B., Driben JS, Johns ME.: Warthin's tumour: a 40-year experience at The Johns Hopkins Hospital. *Laryngoscope.* 1994; 104: 799–803.
15. de Ridder M., Balm A.J., Smelee L.E., Wouters M.W., van Dijk B.A.: An epidemiological evaluation of salivary gland cancer in the Netherlands (1989–2010). *Cancer Epidemiol.* 2015; 39:14–20.
16. Santucci M., Gallo O., Calzolari A., Bondi R.: Detection of Epstein-Barr viral genome in tumour cells of Warthin's tumour of parotid gland. *Am. J. Clin. Pathol.* 1993; 100: 662–665.
17. Banik S., Howell J.S., Wright D.H.: Non-Hodgkin's lymphoma arising in adenolymphoma – A report of two case. *J. Pathol.* 1985; 146: 167–177.
18. Ferrero S., Cattaneo L., Peri A., Braidotti P. et al.: Poorly differentiated carcinoma arising from adenolymphoma of the parotid gland. *BMC Surg.* 2003; 3: 1–5.
19. Zajdel K., Gałązka K., Stachura J., Kurzyński M., Składzień J.: Rozwój niskozróżnicowanego raka w wielogniskowym guzie Warthina u pacjenta z onkocytosą ślinianek przyusznych – opis przypadku. *Otorinolaryngologia.* 2005; 4: 202–206.
20. Olejniczak I., Kozłowski Z., Dąbrowska K., Łukomski M.: Guzy ślinianki przyusznej – obraz kliniczny, sposób postępowania i wyniki leczenia. *Otolaryngol. Pol.* 2008; 62: 446–450.
21. Suwała P., Wilczyński K., Barnaś S.: Nowotwory ślinianek przyusznych w materiale Klinicznego Oddziału Otolaryngologicznego 4 Wojskowego Szpitala Klinicznego z Polikliniką we Wrocławiu w latach 1992–2010. *Otolaryngol. Pol.* 2012; 66: 43–45.
22. Kubacka M., Orendorz-Frączkowska K., Pazdro-Zastawny K., Morawska-Kochman M., Kręcicki T.: Ocena epidemiologiczna nowotworów gruczolów ślinowych u pacjentów leczonych w Klinice Otolaryngologii we Wrocławiu w latach 2001–2010. *Otolaryngol. Pol.* 2013; 67: 30–33.
23. Sungur N., Akan I.M., Ulusoy M.G., Ozdemir R., Kilinç H., Ortak T.: Clinicopathological evaluation of parotid gland tumours: a retrospective study. *J. Craniofac. Surg.* 2002; 13: 26–30.
24. Maahs G.S., de Oliveira Oppermann P., Maahs L.G.P., Machado Filho G.M., Ronchi A.D.: Parotid gland tumours: a retrospective study of 154 patients. *Braz. J. Otorhinolaryngol.* 2015; 81: 301–306.
25. Bień S., Ziółkowska M., Kamiński B., Klimas A., Okła S., Postuła S., Żyłka S.: Ocena epidemiologiczna i kliniczna nowotworów gruczolów ślinowych. *Studia Medyczne Akademii Świętokrzyskiej.* 2006; 3: 21–29.
26. Moghadam S.A., Moghadam F.A., Dadfar M.: Epithelial Salivary Gland Tumors in Ahvaz, Southwest of Iran. *J. Dent. Res Dent. Clin. Dent Prospects.* 2010; 4: 120–123.
27. Feinstein A.J., Ciarleglio M.M., Cong X., Otremba M.D., Judson B.L.: Parotid gland lymphoma: prognostic analysis of 2140 patients. *Laryngoscope.* 2013; 123: 1199–1203.

Word count: 1800? Tables: 2 Figures: – References: 27

---

Access the article online: DOI: 10.5604/01.3001.0009.8412 Table of content: <http://otolaryngologypl.com/resources/html/articlesList?issuelid=9815>

---

**Corresponding author:** Grażyna Stryjewska-Makuch M.D., Independent Public Research Hospital No. 7 of Silesian Medical University in Katowice, Upper Silesian Medical Centre, Department of Laryngology and Laryngological Oncology, ul. Ziołowa 45/47, 40-635 Katowice, Poland, tel.+48 32 359 80 00, e-mail: [HYPERLINK „mailto:makuch\\_mg@wp.pl”](mailto:HYPERLINK_mailto:makuch_mg@wp.pl) makuch\_mg@wp.pl

---

**Copyright** © 2017 Polish Society of Otorhinolaryngologists Head and Neck Surgeons. Published by Index Copernicus Sp. z o.o. All rights reserved.

---

**Competing interests:** The authors declare that they have no competing interests.

---

**Cite this article as:** Stryjewska-Makuch G, Kolebacz B, Janik M. A., Wolnik A.: Increase in the incidence of parotid gland tumors in the years 2005–2014; Otolaryngol Pol 2017; 71 (2): ?-??

---