

## CASE REPORT

# Mass on the head : Spontaneous arteriovenous fistula of the superficial temporal artery

Shusuke Yagi<sup>1,2</sup>, Yoshihito Saijo<sup>1</sup>, Taku Matsuda<sup>3</sup>, Yasuhisa Kanematsu<sup>3</sup>, and Masataka Sata<sup>1</sup>

<sup>1</sup>Department of Cardiovascular Medicine, Tokushima University Graduate School of Biomedical Sciences, Tokushima, Japan, <sup>2</sup>Department of Community Medicine and Human Resource Development, Tokushima University Graduate School of Biomedical Sciences, Tokushima, Japan, <sup>3</sup>Department of Neurosurgery, Tokushima University Graduate School of Biomedical Sciences, Tokushima, Japan

**Abstract :** An arteriovenous fistula of the superficial temporal artery (STA) is a direct and abnormal communication between the STA, feeding artery, and superficial temporal vein, draining veins that bypass the capillary network. Several cases of trauma-induced or iatrogenic-induced arteriovenous fistula (AVF) of the STA have been reported ; however, spontaneous AVF of the STA not associated with trauma or medical treatment are extremely rare. Herein, we present a case of spontaneous AVF of the STA diagnosed in old age. *J. Med. Invest.* 66 : 209-210, February, 2019

**Keywords :** vascular malformation, the elderly, pulsation

## INTRODUCTION

An arteriovenous fistula (AVF) of the superficial temporal artery (STA) is a direct and abnormal communication between the STA, feeding artery, and superficial temporal vein (STV), draining veins that bypass the capillary network. Several cases of trauma-induced or iatrogenic-induced AVF of the STA have been reported ; however, spontaneous AVF of the STA without association with trauma or medical treatment are extremely rare (1, 2). Herein, we present a case of spontaneous AVF of the STA diagnosed in old age.

## CASE REPORT

A 70-year-old man with a history of hypertension presented for evaluation of reduced left ventricular ejection fraction which was detected by preoperative echocardiography for prostatic enlargement surgery. Routine physical examination revealed a reddish soft mass with pulsation on the head (Figure1). A small lump had been pointed out since he was born, but he never had symptoms ; thus, no examination was performed. He had no history of head injury or medical treatment on the head, but noticed that the mass had been growing recently. Magnetic resonance angiography showed no abnormality in the intracranial artery, but showed that the mass was fed by the left STA (Figure 2A). Coronary angiography showed no stenosis in the coronary artery, indicating previous hypertension-induced heart failure, which was treated with antihypertensive drugs. Cerebral angiography of the external jugular vein showed that mass fed by the left STA was drained to the left STV (Figure 2B), suggesting spontaneous AVF of the STA. Surgical treatment was recommended, but the patient chose follow-up. He is still visiting the hospital for AVF follow-up and prostatic enlargement with no complication.

Received for publication October 11, 2018 ; accepted December 3, 2018.

Address correspondence and reprint requests to Shusuke Yagi, MD, PhD, Department of Cardiovascular Medicine, Tokushima University Graduate School of Biomedical Sciences, Tokushima, 3-18-15 Kuramotocho, Tokushima 770-8503, Japan and Fax : +81-88-633-7894.

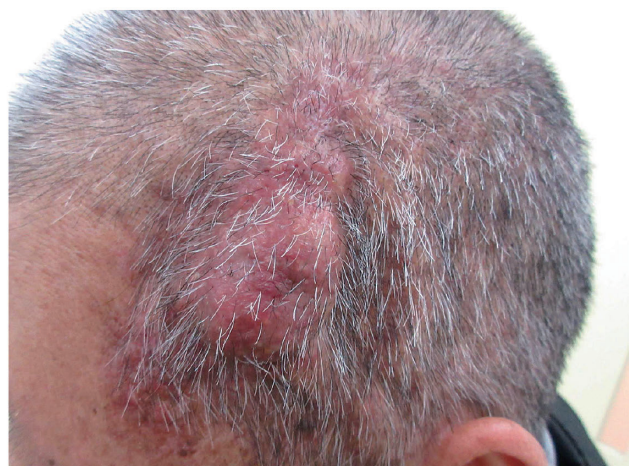

Figure1. Head mass

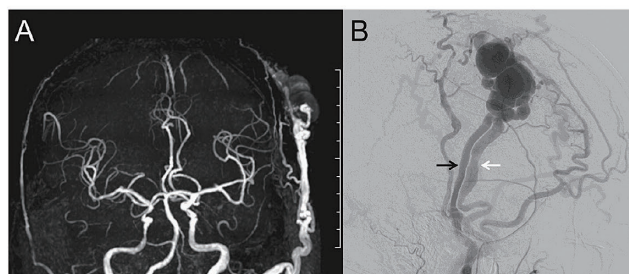


Figure2. A : Magnetic resonance angiography image, B : Cerebral angiography image (Black arrow : STA, White arrow : STV)

## DISCUSSION

The STA and STV typically are grossly dilated and tortuous, resembling a varix which presented a pulsating mass. AVF of the STA was usually noticed as a small, subcutaneous lump, which, over time, evolves into a painless, swollen, continuous palpable thrill, pulsation, and deforming mass (1). He had presented several clinics due to common medical problems including common cold and hypertension ; however, the mass had not been pointed out. Sometimes, it can be underdiagnosed, because AVF of the STA may be covered by hair. Thus, careful observation of the head especially during the first visit is essential even in patients with no complaints on the head, and physician should be aware that spontaneous AVF of the STA is a differential diagnosis of head mass.

The pathogenetic mechanisms have not been fully elucidated. A literature review revealed that 21.9% of AVF patients had hypertension, while others had history of hypertension-related disease including abdominal aortic aneurysm, angina, and cerebral infarction (3). Pathological studies of spontaneous AVF of the STA revealed hyperplasia of the intima-media complex and adventitia as well as partial indistinctness of the internal elastic lamina, mimicking atherosclerotic vascular disease (3). Thus, acquired factors such as hypertension and arteriosclerosis may be attributed to AVF development.

Although AVF of the STA is not life-threatening and AVF rupture has not been reported, subsequent head injury may cause AVF

rupture (4). Thus, surgical resection or endovascular occlusion should be recommended in high risk patients with growing mass (1). The patient chose follow-up rather than surgical treatment ; thus head injury should be avoided as it may lead to AVF rupture.

## CONFLICT OF INTEREST

The authors have no conflicts of interest to disclose.

## REFERENCES

- 1 Yang M, Pan L, Cai MJ, Ma LT, Xu GZ, Li J, *et al.* : Spontaneous arteriovenous fistula of the superficial temporal artery : Diagnosis and treatment. *Clin Neurol Neurosurg* 123 : 18-24, 2014
- 2 Asai K, Tani S, Imai Y, Mineharu Y, Sakai N : Traumatic arteriovenous fistula of the superficial temporal artery. *J Surg Case Rep* 2015 : 2015
- 3 Kawai H, Hamasaki T, Imamura J, Tomonori N, Odashiro T, Yamahata H, *et al.* : Three cases of spontaneous superficial temporal artery aneurysm with literature review. *Neurol Med Chir (Tokyo)* 54 : 854-60, 2014
- 4 Sharma A, Tyagi G, Sahai A, Bajjal SS : Traumatic aneurysm of superficial temporal artery. CT demonstration. *Neuroradiology* 33 : 510-2, 1991