

CASE REPORT

A case of advanced colon cancer arising from a colonic graft for an esophago-bronchial fistula : A case report

Haruka Takasugi^{1,2}, Takahiro Yoshida¹, Takeshi Nishino¹, Masakazu Goto¹, Seiya Inoue¹, Daisuke Matsumoto¹, Tomohiro Inui¹, Hiromitsu Takizawa¹, Hideo Tsuzuki², Toshikatsu Taniki², and Akira Tangoku¹

¹Department of Thoracic, Endocrine Surgery and Oncology, Tokushima University Graduate School, Tokushima, Japan, ²Department of General Surgery, JA Kochi Kouseiren, Kochi Japan

Abstract : Neoplasm of a colonic graft after esophageal reconstruction is rare. We treated a colon cancer patient who developed malignancy in a colonic graft after esophagectomy and reconstruction through a retrosternal route. A male had undergone esophagectomy in his 50s due to a benign esophago-bronchial fistula. His dysphagia became exacerbated 20 years later, and further examinations showed a circumferential tumor on the esophago-colonic anastomosis. He underwent resection of the colonic graft adenocarcinoma with median sternotomy after neoadjuvant chemotherapy. Gastric tube reconstruction was performed through a retrosternal route. This report should be informative in terms of making decisions from an initial reconstruction to follow-up and choosing a therapeutic strategy for colonic graft cancer in the future. *J. Med. Invest.* 66 : 190-193, February, 2019

Keywords : Esophagectomy, Colonic graft, Colonic interposition, Colon cancer, Esophago-bronchial fistula

INTRODUCTION

Patients receiving esophagectomy occasionally develop metachronous malignancies in the reconstructed organs, with advanced age and long duration after surgery increasing the risk. Resection of reconstructive organs after esophagectomy is invasive. Therefore, we need to decide upon an operative procedure with consideration for the balance between invasiveness and curability. Even though it is recommended that patients who undergo esophagectomy undergo postoperative screening, the duration between reconstructive surgery and the occurrence of malignancy in the reconstructed organ is long, and in general it is difficult to detect a carcinoma after treatment such as endoscopic resection. There have been a few reports concerning treatments for adenocarcinoma arising from a colonic graft in esophageal reconstruction (1-11). Here, we report a case of advanced colon cancer in a cervical lesion that developed into malignancy 20 years after esophagectomy for benign esophago-bronchial fistula and reconstruction by a colonic graft.

CASE

A man in his 70s who 20 years prior had visited his previous hospital with exacerbation of dysphagia and an esophago-bronchial fistula due to severe reflux esophagitis was diagnosed. Bypass surgery was performed in the hospital using a graft of a left-side colon (transverse to descending colon) segment with a pedicle of left colic vessels through a retrosternal route, even though details including the decision of choice of reconstructive organ could not be limited. Transthoracic excision of the isolated thoracic esophagus was done at a later date. Past medical history included an endoscopic sphincterotomy for choledocholithiasis in his 60s,

balloon dilatation and endoscopic polypectomy for colon polyps, and esophago-colonic anastomotic stenosis. Thin endoscopic findings showed a circumferential mass with severe stenosis from 18 to 24 cm from the incisor. The esophago-colonic anastomotic border could not be identified (Fig. 1a). Left recurrent nerve paralysis was not identified. Upper gastro-intestinal radiography revealed an apple core sign, and computed tomography scanning showed a locally advanced tumor that retracted the trachea with no evidence of distant metastasis. Well-differentiated tubular adenocarcinoma was confirmed by histopathological examination followed by CDX2 staining as a marker of colonic cancer about endoscopic biopsy specimens.

The patient was a light smoker, at 30 packs per year, and a social drinker.

Laboratory examinations before treatment were within normal limits.

Neoadjuvant chemotherapy (mFOLFOX6 (LV/5-FU/L-OHP) × 6 course) was initially performed for advanced colon cancer involving serosa of the colonic graft and the esophagus (Fig. 1b). After neoadjuvant chemotherapy, the tumor lesion shrunk in size (Fig. 2a). Severe stenosis remained after chemotherapy (Fig. 2b). Adverse events included Grade 2 peripheral neuropathy. Radical resection was conducted. Median sternotomy was needed due to severe adhesion between the colonic graft and the retrosternal space. The cervical esophagus and the colonic graft were divided with safety margins from the tumor, the colonic graft was divided from the stomach, and the roots of the left colic vessels were ligated for lymph node dissection as shown in Fig. 3. Reconstruction was performed using a gastric tube through the retrosternal route due to the short distance of this route. Oral intake was started at 19 post-operative days after dysphagia rehabilitation, and the patient was discharged 7 weeks after surgery. Postoperative complications were left recurrent nerve paralysis, which may have been caused by severe adhesion, surgical site infection of the chest wall and anastomotic stenosis.

The final diagnosis was colon cancer, classified as T, type 3, 15×15 mm, tubular adenocarcinoma, pT3, pN0 (0/22), cM0, f Stage IIA according to the 8th edition of the UICC TNM classification.

Received for publication August 20, 2018 ; accepted September 28, 2018.

Address correspondence and reprint requests to Takahiro Yoshida, M.D., Ph.D., 3-18-15, Kuramoto-cho, Department of Thoracic, Endocrine Surgery and Oncology, Tokushima University Graduate School, Japan and Fax : +81-88-633-7144.

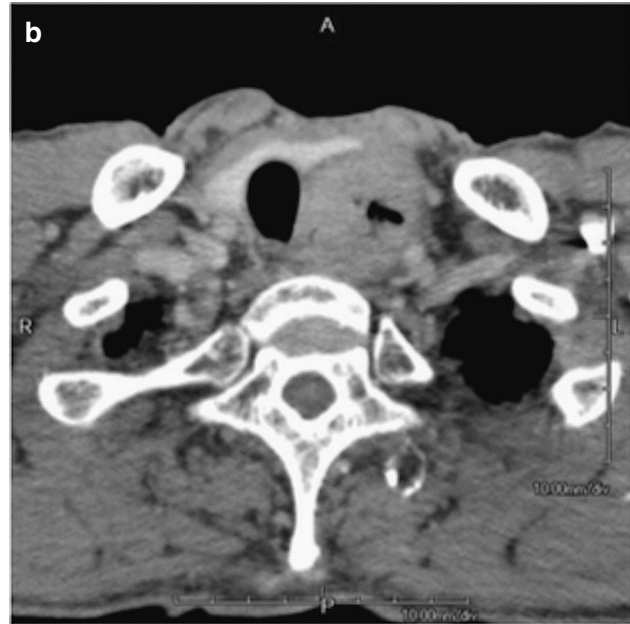
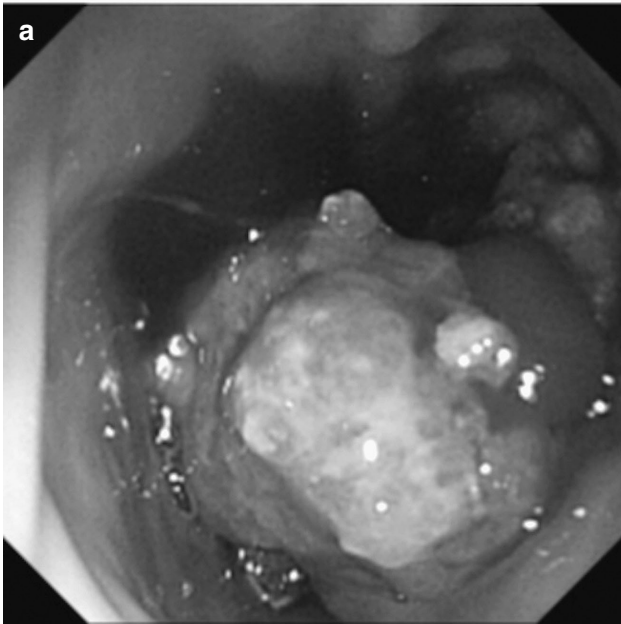


Fig. 1a An endoscopic finding prior to chemotherapy

Fig. 1b A severe stenotic slice of the esophago-colonic anastomosis prior to chemotherapy

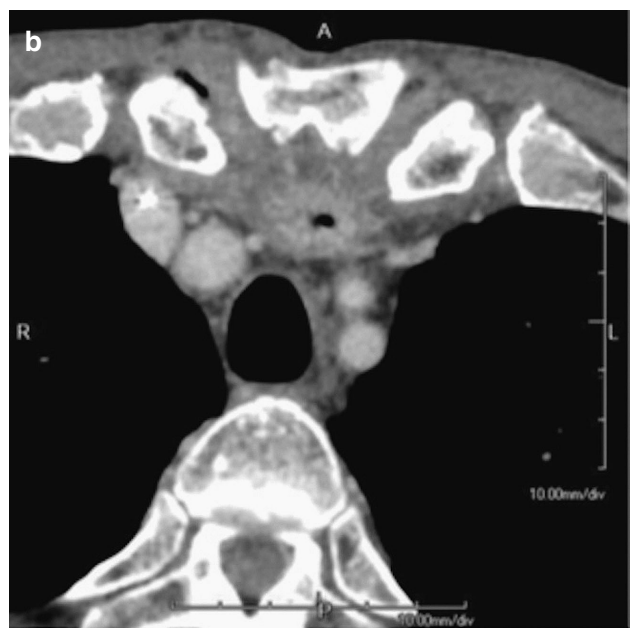
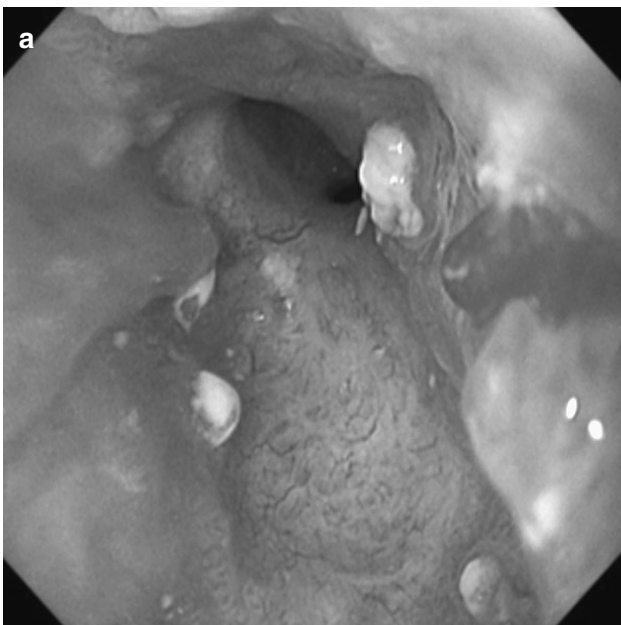

Fig. 2a An endoscopic finding after chemotherapy

Fig. 2b A severe stenotic slice of the esophago-colonic anastomosis after chemotherapy

Unfortunately, this patient developed local and pleural recurrences with left pleural effusion 6 months after resection of the colonic graft cancer. Disease-free survival was 6 months, postoperative survival was 17 months and overall survival was 21 months.

DISCUSSION

A colonic graft for esophageal reconstruction is done in approxi-

mately 5% of cases according to the Comprehensive Registry of Esophageal Cancer in Japan, Japan Esophageal Society. It is suspected that a colonic graft was used for disproportionate length and capacity of conduit and in this case in a previous hospital. The patient noticed improvement of his dysphagia by gastric conduit reconstruction ; however, he mentioned that the amount of oral intake and reflux had been better with the colonic graft. A neoplasm arising in the colon segment used for esophageal reconstruction is rare. Therefore, standard treatment has not been established,

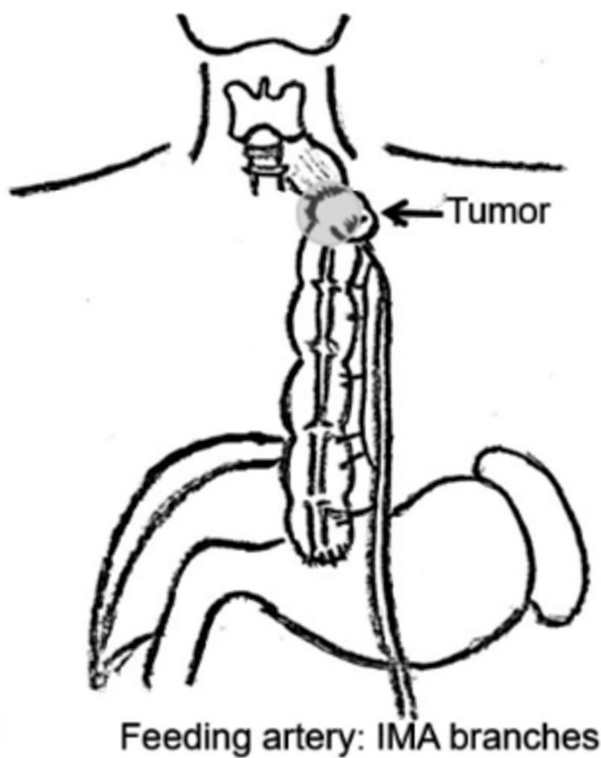


Fig. 3 Schema of the tumor location
Resection of the cervical esophagus and the total colonic graft with median sternotomy

and it is necessary to choose a treatment on an individual-case basis. Long-term exposure of gastric acid content or bile also could cause development of the neoplasm in the colonic graft (11). The colon used for reconstruction should be examined prior to the reconstruction surgery to determine whether neoplasms or polyps exist there; furthermore, if any colonic diverticular or malignancy is identified, the colon should not be used for esophageal reconstruction (12).

Even though we prefer to do minimally invasive treatment, neoadjuvant chemotherapy followed by total resection of the colonic graft and lymph node dissection was performed in this case without any physical restrictions. There was an alternative strategy available in this case, such as partial colectomy with free jejunum graft reconstruction under sternal split incision. However, we considered the difficulties of microvascular anastomosis and recovery if jejunum-colonic anastomotic leakage occurred in this retrosternal route. It was also difficult to divide the adhesion of this colonic graft and change the route from a retrosternal to an antehoracic one. Although chemotherapy shrunk the size of the tumor, postoperative left recurrent nerve palsy due to tumor involvement could not be avoided. Surgery without preoperative chemotherapy also could be applicable for this case, because neoadjuvant chemotherapy is still a controversial approach in colorectal cancer (13). Overall survival was limited to 21 months in this case. Early local recurrence, depression of performance status after recurrence and difficulty in administration of standard chemotherapies afterward resulted in poor survival.

Including this case, most of the patients diagnosed with cancer of the colonic graft had symptoms. The number of patients diagnosed with cancer of an esophageal colonic graft is limited (1-11), as shown in Table 1. Our patient had chronic dysphagia after esophagectomy. Therefore, it was difficult for him to sense the new

Table 1 Reported cases of adenocarcinoma with a colonic graft (1968-2018)

Authors	Year	Age/gender	Reason for esophagectomy	Duration*Complaint	Treatment	Reconstruction	Location	Size	
Goldsmith HS ¹⁾	1968	48/F	Esophageal cancer	2y	Follow-up	Partial resection	Cologastrostomy	The end of colon inter-position	40 mm
Haerr RW ³⁾	1987	72/M	Esophageal cancer	9y	Abdomen discomfort	Chemoradiotherapy	-	Proximal to the distal anastomotic site	-
Houghton AD ⁴⁾	1989	64/M	Benign stenosis	20y	Dysphagia	Total resection of the colonic graft	Gastric tube	-	-
Lee SJ ⁵⁾	1994	75/F	Laryngeal cancer	20y	Dysphagia	Total resection of the colonic graft	Free jejunum	-	-
Altorjay A ⁶⁾	1995	70/M	Esophagitis	5y	Dysphagia	Partial resection	Roux-en-Y	-	-
Liau CT ⁷⁾	2004	79/M	Esophageal cancer	30y	Dysphagia	Chemotherapy	-	-	-
Bando H ²⁾	2010	80/M	Esophageal cancer	14y	Follow-up	Endoscopic submucosal dissection	-	-	20 mm
Shersher DD ⁸⁾	2011	60/M	Benign stenosis	40y	Dysphagia	Total resection of the colonic graft	Gatric tube	25 cm distance from the incisors, 1 cm distal to the anastomosis	31 mm
Aryal MR ⁹⁾	2013	60/M	Benign stenosis	30y	Dysphagia	Chemotherapy	-	45 cm from the incisor tooth	40 mm
Grunner S ¹¹⁾	2013	59/F	Benign stenosis	55y	Dysphagia	Partial resection	Roux-en-Y	Anastomotic site of the colon and the remnant stomach	35 mm
Yamamoto M ¹⁰⁾	2015	83/M	Esophageal cancer	14y	Medical check-up	Partial resection	Gastric tube	45 cm from the incisor tooth	45 mm
Our case	2015	70/M	Sever reflux esophagitis	20y	Dysphagia	Total resection of the colonic graft	Gastric tube	18 cm from the incisor tooth	15 mm

Duration*, years after esophagectomy

symptoms caused by obstruction from the cancerous lesion. He had not undergone any examinations since his 60s. Most cases undergo partial resection and end-to-end anastomosis (1, 6, 10, 11). Additionally, Roux-en-Y (12) or free jejunum (5) reconstruction has been reported. Total resection of the colonic graft such as in our case was rare. Some cases are treated by chemotherapy (9). In these cases, achieving a balance between curability and invasiveness is challenging, and preservation of the colonic graft and its blood supply are difficult in advanced colon cancer patients. Thinking of our case, not only regular medical examination for colon cancer but also investigation of dysphasia after esophageal reconstruction is thought to be important for early diagnosis. Furthermore, possibility of dysphasia by other diseases except for postoperative anastomotic stenosis needs to be informed to the patient.

In conclusion, we reported a case of locally advanced colon cancer arising on the oral wedge of anastomosis in the retrosternal colonic graft 20 years after esophagectomy and reconstruction. Total resection of the colon graft and reconstruction using a gastric tube through a retrosternal route was performed after neoadjuvant chemotherapy. This report should be informative in terms of making decisions from an initial reconstruction to follow-up and choosing a therapeutic strategy for colonic graft cancer in the future.

ABBREVIATIONS

CT : Computed Tomography ; mFOLFOX : modified FOLFOX 6 ; l-LV : L-leucovorin ; 5-FU : 5-fluorouracil ; L-OHP : oxaliplatin ; p : pathological ; c : clinical ; T : depth of tumor invasion ; N : extent of lymph node metastasis ; M : other distant metastasis ; f Stage : final Stage.

DECLARATIONS

Ethics approval and consent for publication

The present study was conducted in accordance with the ethical standards of our institution.

Consent for publication

All presentations in this manuscript were granted consent to publication from the family of the patient.

Competing interest

The authors declare that they have no competing interests.

Authors' contribution

HT and TY analyzed and interpreted the patient's data and examination findings. TN, MG, SI, DM and TI are surgeons who performed treatments for this patient. The manuscript was prepared by HT under the supervision of TY, AT, TT and HT. All authors read and approved the final manuscript.

ACKNOWLEDGEMENT

The authors would like to express their appreciation to Hisanori Uehara M.D., Yoshimi Bando M.D., Akiko Yoneda M.D., Shunsuke Watanabe M.D., and their colleagues of the Division of Pathology, Tokushima University Hospital, Tokushima, Japan for their assistance with the histopathological diagnoses.

AUTHORS' INFORMATION

¹Department of Thoracic, Endocrine Surgery and Oncology, Tokushima University Graduate School, 3-18-15, Kuramoto-cho, Tokushima, 770-8503, Japan. ²Department of General Surgery, JA Kochi Kouseiren, 526-1, Aza-nakano, Myouken, Nangoku, Kochi, 783-8509, Japan

ENDNOTES

All queries should be forwarded to the author for correspondence at the address above.

REFERENCES

1. Goldsmith HS, Beattie Jr. EJ : Malignant villous tumor in a colon bypass. *Ann Surg* 167 : 98-100, 1968
2. Bando H, Ikematsu H, Fu KI, Oono Y, Kojima T, Minashi K, Minashi K, Yano T, Matsuda T, Saito Y, Kaneko K, Ohtsuet K : A laterally spreading tumor in a colonic interposition treated by endoscopic submucosal dissection. *World J Gastroenterol* 16 : 392-4, 2010
3. Haerr RW, Higgins EM, Seymore CH, El-Mahdi AM : Adenocarcinoma arising in a colonic interposition following resection of squamous cell esophageal cancer. *Cancer* 60 : 2304-7, 1987
4. Houghton AD, Jourdan M, McColl I : Dukes A carcinoma after colonic interposition for oesophageal stricture. *Gut* 30 : 880-1, 1989
5. Lee SJ, Koay CB, Thompson H, Nicolaidis AR, Das Gupta AR : Adenocarcinoma arising in an oesophageal colonic interposition graft. *J Laryngol Otol* 108 : 80-3, 1994
6. Altorjay A, Kiss J, Vörös A, Szanto I, Bohak A : Malignant tumor developed in colon-esophagus. *Hepato-gastroenterology* 42 : 797-9, 1995
7. Liao CT, Hsueh S, Yeow KM : Primary adenocarcinoma arising in esophageal colon interposition : report of a case. *Hepato-gastroenterology* 51 : 748-9, 2004
8. Shersher DD, Hong E, Warren W, Penfield Faber L, Liptay MJ : Adenocarcinoma in a 40-Year-Old Colonic Interposition Treated With Ivor Lewis Esophagectomy and Esophagogastric Anastomosis. *Ann Thorac Surg* 92 : e113-4, 2011
9. Aryal MR, Mainali NR, Jalota L, Altomare JF : Advanced adenocarcinoma in a colonic interposition segment. *BMJ Case Reports*. 2013 ; 2013 : bcr2013009749. doi : 10.1136/bcr-2013-009749.
10. Yamamoto M, Yamasaki M, Sakai D, Makino T, Miyazaki Y, Takahashi T, Kurokawa Y, Nakajima K, Takiguchi S, Mori M, Doki Y : A Case of Colon Cancer That Developed in the Subcutaneously Reconstructed colon after Esophagectomy for Thoracic Esophageal Cancer : *Jpn J Cancer Chemother* 42 : 2230-2, 2015
11. Grunner S, Gilshtein H, Kakiashvili E, Kluger Y : Adenocarcinoma in Colonic Interposition. *Case Rep Oncol* 6 : 186-8, 2013
12. Fritscher-Ravens A, Sriram PV, Thonke F, Jaecle S, Maydeo A, Soehendra N : Synchronous adenocarcinoma in the transposed colonic conduit after esophagectomy for squamous cell cancer : endoscopic palliative resection while awaiting surgery *Gastrointest Endosc* 50 : 852-4, 1999
13. Walker AS, Zwintscher NP, Johnson EK, Maykel JA, Stojadinovic A, Nissan A, Avital I, Brucher BL, Steele SR : Future directions for monitoring treatment response in colorectal cancer *J Cancer* 5 : 44-57, 2014