

Intravenous Acetaminophen Hepatotoxicity in a Liver Transplant Patient

Thi Khuc¹, Khaled Selim¹

¹ Loma Linda University Medical Center, Loma Linda, CA, United States

INTRODUCTION: Eighty to ninety percent of APAP is metabolized by glucuronidation and sulfation and excreted in urine. The remaining 5-10% of APAP is metabolized by CYP450/CYP2E into N-acetyl-p-benzoquinone imine (NAPQI), the toxic metabolite responsible for APAP hepatotoxicity.³ NAPQI is inactivated when conjugated to tripeptide glutathione. During APAP overdose, excessive quantities of NAPQI and depleted glutathione stores lead to hepatotoxicity.³ There exists only two case reports on hepatotoxicity associated with therapeutic doses of IV APAP in post-operative patients with native livers, however, one was confounded by post-operative shock liver.^{4,5} There is no validated nomogram to guide treatment of IV APAP overdose or toxicity. NAC therapy remains the mainstay for PO APAP overdose.

CASE REPORT: A 69 year old male with a past medical history of secondary biliary liver cirrhosis status post orthotopic liver transplantation in 2006, Hepatocellular carcinoma of the explanted liver, splenic artery aneurysm status post splenectomy and newly diagnosed prostate adenocarcinoma was admitted to the Urology service for planned robotic-assisted prostatectomy. Eighteen days prior to presentation, the patient was medically cleared by Transplant Hepatology for prostatectomy. He was noted

to have a normal functioning hepatic graft and advised to continue taking tacrolimus 0.5 mg twice daily. At that time, aminotransferase (AST) was 23 IU/L, alanine aminotransferase (ALT) 24 IU/L, total bilirubin (TBili) 1.4 mg/dL, and international normalized ratio (INR) 1.0.

He underwent uncomplicated robotic-assisted prostatectomy, requiring no fluid resuscitation, vasopressor support or blood products. Post-operatively, vital signs remained normal with no episodes of hypotension. Physical exam was notable for mild tenderness to palpation around the laparoscopic incision sites. He was started on a clear liquid diet and IV APAP 1000 mg every 6 hours for 36 hours, followed by PO APAP 650 mg every 6 hours for post-operative pain.

On post-operative day 1, AST was 2275 IU/L, ALT 2521 IU/L, TBili 1.3 mg/dL, and INR 1.4. On post-operative day 2, AST was 2751 IU/L, ALT 3447 IU/L, TBili 1.9 mg/dL and INR 1.5 (Figure 1).

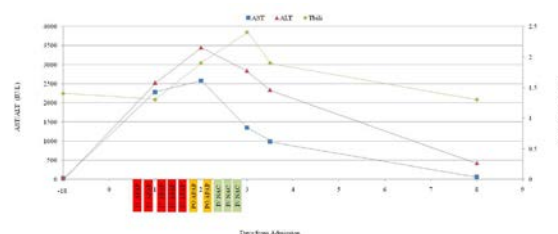


Figure 1. AST, ALT, Total Bilirubin Levels Before, During, and After Hospital Admission

The patient developed a diffuse, pruritic maculopapular rash around his torso and bilateral upper arms, unrelieved by oral

Accepted for Publication: Mar 2019

The authors have no funding, financial relationships, or conflicts of interest to disclose. Send correspondence to: tkhuc@llu.edu

diphenhydramine. All orders for acetaminophen were stopped. Liver Doppler ultrasound was normal. By this time, the patient had received 5000 mg of IV APAP and 650 mg of PO APAP total. A serum acetaminophen level was drawn 10 hours after the last IV APAP dose and noted to be < 15 ug/mL. Hepatology was consulted.

The patient reported consuming daily herbal supplements for the past 14 months, including saw palmetto, pygeum, cranberry extract, pumpkin seed extract and beta-sitosterol. He stopped taking the herbal supplements 7 days prior to the prostatectomy. He denied alcohol use and reported minimal nausea, but no vomiting. His average daily intake was 3.5 liters. Work up for infectious etiologies was negative.

The patient was started on IV NAC, with a loading dose of 150 mg/kg followed by a maintenance dose of 50 mg/kg over 4 hours, then 100 mg/kg over 16 hours. Within 18 hours, AST was 1350 IU/L, ALT 2836 IU/L, and INR 1.5. TBili increased to 2.4 mg/dL. Following completion of IV NAC therapy, AST was 986 IU/L, ALT 2340 IU/L, TBili 1.9 mg/dL, and INR 1.4. His macular papular rash resolved during IV NAC therapy.

The patient was discharged home on post-operative day 4. Labs during his outpatient Hepatology follow-up appointment 4 days after discharge were AST 62 IU/L, ALT 426 IU/L, TBili 1.3 mg/dL, and INR 1.1.

DISCUSSION: This is the first case of acute liver toxicity in a post-OLT patient who received therapeutic doses of IV APAP subsequently responded to IV NAC therapy. The patient's AST, ALT, TBili and INR were normal prior to IV APAP exposure. Elevations in AST, ALT, TBili, and INR improved after IV APAP was discontinued and IV NAC initiated. A serum APAP level drawn 10 hours after the last IV APAP administration was < 15 ug/mL, consistent with therapeutic dosage. There was no

evidence of hypotension or APAP overdose in the electronic medical records. All other etiologies for acute liver toxicity were ruled out, including shock liver, infection and vascular compromise.

Risk factors that have been shown to increase the risk of hepatotoxicity in APAP overdose patients include malnutrition, eating disorders, AIDS, alcoholism, antiepileptic medications, and tuberculosis medications.⁶ Our patient did not have any of these risk factors. Although he experienced nausea post-operatively, daily total intake was adequate and there were no periods of fasting or malnutrition. It is unlikely the patient's hepatotoxicity was due to herbal drug induced liver injury or herbal-drug interactions with IV APAP. Case reports exist on saw palmetto associated cholestatic hepatotoxicity.⁷ However, prospective trials have found little evidence of liver injury linked to saw palmetto.⁸ There was no history of hepatotoxicity during the 14 months that the patient consumed saw palmetto and he ceased saw palmetto consumption 7 days prior to admission. Online Pubmed literature searches on hepatotoxicity due to pygeum, cranberry extract, pumpkin seed extract or beta-sitosterol did not yield results.

The patient's transplant liver may have been predisposed to IV APAP toxicity, even at therapeutic doses. It is possible APAP metabolism is altered in transplant livers compared to native livers. A study on 13 liver transplant patients concluded APAP metabolism was transiently altered in orthotopic livers following liver transplantation, resulting in enhanced NAPQI production.⁹ Liver Transplant Centers in the Scientific Registry of Transplant Recipients have issued post-OLT guidebooks for patients, recommending no more than 1500 mg to 2000 mg of PO APAP daily, lower than the daily maximum limit of 4000 mg.^{10,11,12} Furthermore, studies show

decreased glutathione levels in transplant livers after undergoing pre-transplant cold storage preservation and post-transplant reperfusion. It is possible transplant livers carry less glutathione stores, rendering them more susceptible to hepatotoxicity from NAPQI concentrations that a native liver would tolerate.¹³ Further studies on what is considered safe, therapeutic IV APAP dosing in post-OLT patients is needed to prevent hepatotoxicity in this patient population.

REFERENCES:

1. Jahr JS, Lee VK. Intravenous acetaminophen. *Anesthesiol Clin*. 2010;28(4):619-645.
2. Ofirmev (acetaminophen injection) [package insert]. Hazelwood, Missouri: Mallinckrodt Hospital Products Inc.; Dec, 2014.
3. Yoon E, Babar A, Choudhary M, Kutner M, Pysopoulos N. Acetaminophen-Induced Hepatotoxicity: a Comprehensive Update. *J Clin Transl Hepatol*. 2016;4(2):131-42.
4. Lee PJ, Shen M, et al. Possible hepatotoxicity associated with intravenous acetaminophen in a 36-year-old female patient. *Pharmacy and Therapeutics*. 2015;40(2):123-32.
5. Seifert SA, Kovnat D, et al. Acute hepatotoxicity associated with therapeutic doses of intravenous acetaminophen. *Clin Toxicol*. 2016;54(3):282-285.
6. Ferner RE, Dear JW, Bateman DN. Management of paracetamol poisoning. *BMJ*. 2011;342:d2218. doi: 10.1136/bmj.d2218.
7. Lapi F, Gallo E, Giocaliere E, et al. Acute liver damage due to Serenoarepens: a case report. *Br J Clin Pharmacol*. 2010;69(5):558-60.
8. Avins AL, Bent S, Staccone S, Badua E, Padula A, Goldberg H, Neuhaus J, Hudes E, Shinohara K, Kane C. A detailed safety assessment of a saw palmetto extract. *Complement Ther Med*. 2008;16(3):147-154
9. Park JM, Lin YS, Calamia JC, et al. Transiently altered acetaminophen metabolism after liver transplantation. *Clin Pharmacol Ther*. 2003;73(6):545-553.
10. University of California San Francisco Medical Center. (2001). *Liver Transplant Patient Handbook*. San Francisco, CA: UCSF Liver Transplant Service.
11. Oregon Health and Science University Portland Veterans Affairs Medical Center Combined Liver Transplant Program. (n.d.). *Resuming Life After Liver Transplant*. Portland, OR: Oregon Health and Science University.
12. What Over-the-Counter (OTC) Medications are Safe for Liver Transplant Recipients? *Penn Medicine Transplant*. 2011. <https://www.pennmedicine.org/updates/blog/s/transplant-update/2011/august/otcmedicines-safe-for-liver-transplant>. Accessed February 10, 2019.
13. Grezzana Filho T, Corso C, et al. Liver glutathione depletion after preservation and reperfusion in human liver transplantation. *Acta Cir Bras*. 2006;21(4):223-229.