



New bulking agent for the treatment of vesicoureteral reflux: Polymethylmethacrylate/dextranomer

Sang Woon Kim¹, Yong Seung Lee¹, Young Jae Im², Sang Won Han¹

¹Department of Urology, Urological Science Institute, Yonsei University College of Medicine, ²Department of Urology, Seoul National University College of Medicine, Seoul, Korea

Purpose: The aim of this study was to report preliminary results of endoscopic treatment of vesicoureteral reflux in children with a single injection of a new bulking agent, cross-linked dextran and polymethylmethacrylate mixture.

Materials and Methods: We performed a single-center, single surgeon, prospective, off-label study using polymethylmethacrylate/dextranomer to treat vesicoureteral reflux. All patients underwent endoscopic injection, followed by renal ultrasound and voiding cystourethrogram at 3 months postoperatively to identify *de novo* or worsening hydronephrosis and vesicoureteral reflux correction (to Grade 0 or I).

Results: Eighteen patients underwent injection of polymethylmethacrylate/dextranomer at our institution between April 2013 and December 2013. Ten were males and eight were females, with a median age of 58 months (range, 6 months to 5 years). Vesicoureteral reflux was unilateral in three patients and bilateral in 15, for a total of 33 renal refluxing units. Vesicoureteral reflux was Grade I in one renal refluxing unit, Grade II in 12, Grade III in 16, and Grade IV in four. Mean injected volume was 0.86 mL. Reflux was corrected in 23 renal refluxing units (69.7%) according to the 3-month voiding cystourethrogram. Complications included urinary retention in one patient. Mild pyelectasis was noted in one patient at 3 months, which spontaneously resolved 3 months later.

Conclusions: Our short-term data show that polymethylmethacrylate/dextranomer injection can be used to treat vesicoureteral reflux with comparable efficacy to other substances currently used and a low rate of complications. Long-term follow-up is required to confirm the usefulness of this material in treating vesicoureteral reflux.

Keywords: Endoscopy; Injections; Vesico-ureteral reflux

This is an Open Access article distributed under the terms of the Creative Commons Attribution Non-Commercial License (<http://creativecommons.org/licenses/by-nc/4.0>) which permits unrestricted non-commercial use, distribution, and reproduction in any medium, provided the original work is properly cited.

INTRODUCTION

Endoscopic injection for the treatment of vesicoureteral reflux (VUR) was initially introduced by Matouschek in 1981, and O'Donnell and Puri [1] reported the first clinical

results in 1984. After the United States (US) Food and Drug Administration (FDA) approved dextranomer/hyaluronic acid copolymer (Dx/HA, Deflux; Q-Med, Scandinavia, Uppsala, Sweden) for the treatment of VUR in 2001, endoscopic injection has gained popularity because of its

Received: 9 January, 2018 • **Accepted:** 17 March, 2018

Corresponding Author: Sang Won Han

Department of Urology, Urological Science Institute, Yonsei University College of Medicine, 50-1 Yonsei-ro, Seodaemun-gu, Seoul 03722, Korea

TEL: +82-2-2228-2310, FAX: +82-2-312-2538, E-mail: SWHAN@yuhs.ac

ORCID: <http://orcid.org/0000-0003-0941-1300>

substantial benefits, including straightforward technique, minimal invasiveness, low rate of complications, and acceptable success rate. This has been accompanied by a reevaluation of the treatment philosophy for VUR, and some urologists even recommend endoscopic injection as first-line treatment for VUR [2,3].

The ideal substance for injection therapy should have two major characteristics. The first is “anatomic integrity”, enabling the material to pass through the endoscope and maintain its volume over time. The other component is “material safety”, which requires biocompatibility and lack of migration from the site of injection. Since the first use of polytetrafluoroethylene (Teflon) as a bulking agent for treating reflux, various materials such as polydimethylsiloxane (PDMS, Macroplastique; Uroplasty, Inc., Minnetonka, MN, USA) and autologous materials have been proposed as alternative agents. However, several drawbacks, including particle migration and low efficacy, have limited usage of these agents. For the last decade, Dx/HA has become the most popular bulking agent worldwide because of its safety and efficacy [4]. Nevertheless, there is a paucity of evidence-based literature regarding the long-term effects of Dx/HA injection for VUR. The biodegradable nature of Dx/HA has been identified as a possible cause for the high recurrence rate during follow-up, emphasizing the need to continue the search for alternative substances for injection therapy [5].

A recently developed dermal filler consisting of polymethylmethacrylate (PMMA) and cross-linked dextran (PMMA/Dx, Dexol; Chungwha Medipower Corporation, Seoul, Korea) demonstrated good efficacy and durability for soft tissue augmentation, without complications [6]. PMMA, a synthetic non-biodegradable material, has been used in cosmetic surgery with a good safety record [7]. It consists of 32 to 120 μ m microspheres with a smooth surface and maintains its volume more than 10 years after injection [8]. Cross-linked dextran (dextranomer) has been used for wound-healing purposes and is a key ingredient in Dx/HA. We conducted a prospective study to evaluate the efficacy of PMMA/Dx in children with primary VUR during 3-month follow-up.

MATERIALS AND METHODS

1. Patients

This is a single-center, prospective, off-label study performed by a single surgeon (SW Han). The protocol was approved by the committee of ethics of research protocols at Severance Hospital (approval number: 1-2012-0057). Parents

signed an informed consent form for each patient. We selected children under the age of 7 years with Grade I to V VUR requiring correction, whose parents understood and agreed with the purpose of study. Every child had a recent preoperative voiding cystourethrogram (VCUG) and dimercaptosuccinic acid (DMSA) renal scan. Preoperative urine cultures were collected from all patients, and sterile urine was confirmed before patients underwent endoscopic injection. The indications for endoscopic correction in the majority of patients were breakthrough infections during antibiotic prophylaxis or persistent high-grade VUR. In some patients, reflux correction was performed at the request of parents.

The exclusion criteria consisted of neurogenic bladder, reflux secondary to another anatomical malformation of the urinary tract (e.g., obstruction, duplex system), previous surgical or endoscopic procedures, and suspected or confirmed dysfunctional voiding by clinical findings or abnormal results (e.g., irregular bladder wall, diverticulum) on VCUG. Children with paraureteral diverticulum on VCUG were also excluded. According to our standard protocol, all patients underwent VCUG and renal ultrasound at 3 months postoperatively to evaluate correction of reflux and absence of *de novo* or worsening hydronephrosis. Reflux Grade I or less at this follow-up evaluation was defined as success. DMSA renal scan at 1 year after their first injection was planned. Patients continued antibiotic prophylaxis until VUR resolution was demonstrated on VCUG.

2. Injection material

The PMMA/Dx agent consists of 75% cross-linked dextran and 15% PMMA; it was approved by the Korean FDA for soft tissue augmentation in 2010. Cross-linked dextran and PMMA are microspheres with diameters of 45 to 120 μ m and 32 to 120 μ m, respectively. These microspheres account for 90% of the volume and are suspended in hypromellose solution, which comprises the other 10%. This bulking agent is biocompatible, nonresorbable microparticle-free and migration resistant.

3. Technique

While the patient received general anesthesia, endoscopic treatment was performed with a 21-gauge needle and 1ml syringe of PMMA/Dx using a 10-Fr cystoscope (Karl Storz, Tuttlingen, Germany). All injection was performed using subureteric transurethral injection (STING) or hydrodistention implantation technique (HIT), or a combination of both techniques, depending on the anatomy of the ureteral meatus and the surgeon's preference. The

surgeon had an extensive experience of more than a thousand cases with previous injection materials, including Dx/HA and PDMS.

4. Statistics

The primary outcome was surgical success on postoperative VCUG. Secondary outcomes included the occurrence of adverse events. We planned to recruit a sufficient number of patients to have 30 ureters treated with PMMA/

Dx injections, expecting a 5% to 10% loss to follow-up. All data analyses were performed using IBM SPSS Statistics ver. 20.0 (IBM Co, Armonk, NY, USA).

RESULTS

Patient demographics are presented in Table 1. A total of 18 patients underwent endoscopic treatment of VUR using PMMA/Dx at Severance Hospital between April 2013 and December 2013. VUR was unilateral in three and bilateral in 15, comprising 33 renal refluxing units (RRUs). VUR was Grade I in one RRU, Grade II in 12 RRUs, Grade III in 16 RRUs, and Grade IV in four RRUs. Recurrent febrile urinary tract infections (UTIs) served as the only indication for surgery in 13 patients (72.2%), Grade IV VUR was the indication in three patients (16.7%), and parental request for reflux correction was the indication in two patients (11.1%). The STING technique was used in 20 RRUs, whereas HIT or combination of both techniques was adopted in the other 13 RRUs to create the appearance of a “volcanic bulge” (Fig. 1).

The VCUG results at 3 months postoperatively are summarized in Table 2. Overall, the endoscopic injection corrected VUR in 23 of 33 RRU (69.7%) at 3 months. Of the four patients (4 ureters) who demonstrated improvement of reflux to Grade I, none received further treatment, and no complications such as febrile UTI occurred. In nine patients (10 ureters) with residual VUR greater than Grade I (failures), postoperative VUR was downgraded to Grade II in six ureters and Grade III in one ureter, and three ureters demonstrated no change after injection. In these nine patients with residual VUR, one patient with remnant bilateral VUR of Grades II and III had a suspected febrile UTI and underwent ureteral reimplantation. The other eight patients developed no UTI and underwent no

Table 1. Patient demographics at baseline

Variable	Value
Number of patients	18
Gender	
Male	10
Female	8
Number of RRUs	33
Laterality	
Unilateral	3
Bilateral	15
RRU grade (n=33)	
I	1 (3.0)
II	12 (36.4)
III	16 (48.5)
IV	4 (12.1)
Indications for surgery	
Breakthrough UTI	13 (72.2)
Persistent high-grade VUR	3 (16.7)
Parents' request	2 (11.1)
Incidence of cortical defect on renal scan (n=33)	15 (45.5)
Age at surgery (mo)	48 (31–62)
Injected volume (mL)	0.91±0.384

Values are presented as number only, number (%), median (interquartile range), or mean±standard deviation.

RRU, renal refluxing unit; UTI, urinary tract infection; VUR, vesicoureteral reflux.

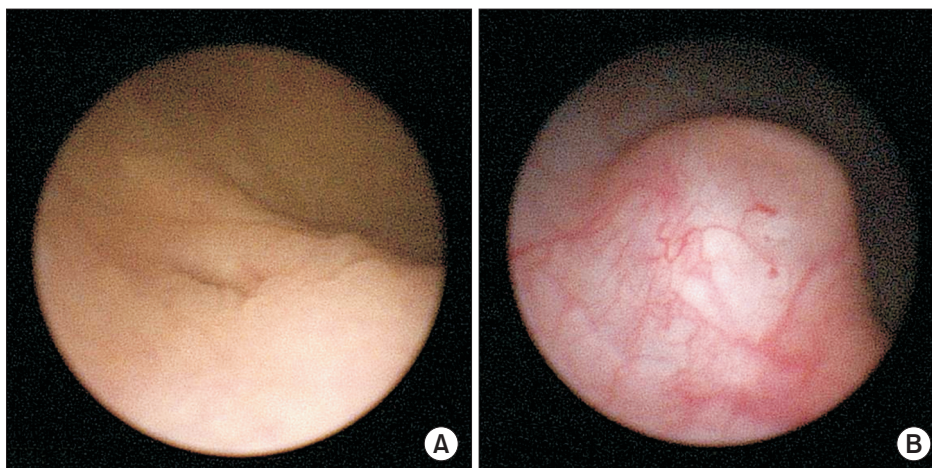


Fig. 1. (A) preoperative cystoscopic finding, (B) competent ureteral orifice on the top of a “volcano” after injection of polymethylmethacrylate/dextranomer injection.

Table 2. Outcome of single endoscopic injection of polymethylmethacrylate/dextranomer in 33 RRUs with regard to the initial VUR grade at 3-month follow-up

VUR grade	No. of RRUs	No. of improved to Grade I	No. of failures	Success rate (%)
I	1	0	0	100.0
II	12	2	1	91.7
III	16	1	7	56.3
IV	4	1	2	50.0
Total	33	4	10	69.7

RRU, renal refluxing unit; VUR, vesicoureteral reflux.

further treatment during follow-up. Except one patient who underwent postoperative DMSA scan after ureteral reimplantation, follow-up renal scan was performed 1 year after endoscopic injection and no newly developed cortical defect was seen after either of successful or even failed injection.

Postoperative complications included urinary retention developed in one patient, which improved after 2 weeks of urethral catheterization. In one patient, mild pyelectasis was noted on ultrasonography at 3 months, which spontaneously resolved 3 months later. No significant complications such as dysuria, allergic reaction, lumbar pain were identified.

DISCUSSION

To our knowledge, this is the first study to evaluate the efficacy of PMMA/Dx for treating patients with VUR via endoscopic injection. The results of this preliminary study were satisfactory, with a success rate of 69.7% RRUs. Given that the reported success rates with Dx/HA range from 68% to 92% [9], the success rates in this study are comparable to those obtained with other substances currently in use. No significant complications were identified. Furthermore, with the documented nonabsorbable property of PMMA/Dx, we do not anticipate that there will be a significant loss of implant volume over time.

Endoscopic injection therapy changed the treatment paradigm of VUR after Dx/HA was approved by the US FDA in 2001, and the number of children with VUR treated with injection therapy dramatically increased between 2002 and 2006 [2]. However, debate continues regarding the ideal bulking agent for endoscopic therapy of VUR. Currently, the most popular bulking agent is Dx/HA. This is a highly hydrophilic dextran polymer with a good safety profile and a base of nonanimal-stabilized HA, which is easily injected by manual pressure without the need for an injection gun. Endoscopic injection with Dx/HA demonstrated an overall mean success rate of 77% and infrequent complications following the procedure [4]. However, with increasing usage

of Dx/HA, concerns have emerged regarding long-term durability and complications of injection therapy.

There have been several reports of successful long-term results with Dx/HA [10,11]. Nevertheless, routine follow-up VCUG was not conducted in most studies, which reduced the validity of their results, and declining success rates over time have been reported [5,12]. One possible explanation for the decreasing success rate is movement of the injection material. Lee et al. [12] reported that Dx/HA was no longer located at the initial injection site when ureteral reimplantation was performed after failed injection therapy. Its biodegradable nature also likely contributes to the decreasing efficacy of Dx/HA over time. Although Dx acts as a cell attractant material, specifically recruiting fibroblasts that synthesize new collagen and thereby resulting in endogenous tissue augmentation, it is slowly degraded within the body by hydrolysis. Furthermore, most of the HA disappears within several weeks after injection [13]. Stenberg et al. [14] observed that implant volume was reduced by 23% at 1 year after subcutaneous implantation of Dx/HA in rats. Similarly, in children, the injected volume was reduced by 20% at 2 weeks after injection and continued to slowly decrease during follow-up (albeit not at a statistically significant rate) [15].

Many bulking agents have been investigated throughout the years to overcome the limitations of Dx/HA. The most notable material developed recently is a polyacrylate polyalcohol bulking copolymer (PPC, Vantris; Promedon, Cordoba, Argentina), which is a new non-biodegradable substance of synthetic origin belonging to the acrylic family. It was first introduced in 2010 for the treatment of VUR [16], and its large average diameter of 320 nm and non-biodegradable nature may produce better stability and long-term durability in treating VUR. Several studies reported successful short-term outcomes (88.6% to 93.8% VUR resolution rate) with PPC, which are similar or even superior to those reported with Dx/HA [17,18]. However, ureteral obstruction was more commonly seen with PPC than with Dx/HA [19], and a recent animal study revealed

that PPC led to severe fibrosis at the injection site [20]. These results have raised concerns regarding the possibility of ureteral obstruction after PPC injection and thereby limited the use of this material.

PMMA/Dx (Dexol), a PMMA and cross-linked dextran mixture, is a newly developed dermal filler for soft tissue augmentation, which is a commercially-available product approved by the Korean FDA in 2010. PMMA microspheres, fine spherical particles with a size of 45 μm to 120 μm (mean, 100 μm), are not subjected to phagocytosis because of their large molecular size. Furthermore, some PMMA microspheres are encapsulated by connective tissue consisting of fibroblasts, which inhibits their migration to other tissues and subsequent volume loss. In addition, PMMA is not degraded by enzymes *in vivo*. Dextran also stimulates fibroblasts after being absorbed by macrophages and is therefore replaced by autologous tissue, resulting in minimal loss of volume [21,22]. In an animal study comparing PMMA/Dx and Dx/HA, PMMA/Dx maintained its shape better at the injection site, even after 3 weeks, and showed significantly better volume maintenance [22]. Initial clinical reports with PMMA/Dx for soft tissue augmentation demonstrated that the material led to a significant increase in soft tissue volume and was well-circumscribed within the human subcutaneous tissue, without producing serious adverse events, such as inflammation or necrosis [23]. A subsequent long-term study also showed good durability and tolerability without volume loss over 18 months of follow-up [6].

Complications with Dx/HA injection mainly relate to obstruction at the injection site. Since the first report by Snodgrass [24] in 2004, publications on postoperative obstruction have been scarce and the reported incidence has been very low [24-26]. However, obstruction may simply be not identified, resulting in silent loss of renal function. Ureteral obstruction after injection therapy is usually due to extensive inflammation, with foreign body reaction and granuloma formation [26]. PMMA has been safely used as a dermal filler for more than 20 years with an incidence of granuloma formation below 0.2% [27]. A previous animal study revealed that infiltration of inflammatory cells or macrophages did not occur at the injection site with PMMA/Dx [22]. Foreign body reactions, such as granulomas, were not observed in any animal, which was similar to the findings with Dx/HA. In our current study, postoperative ultrasound demonstrated well-positioned material at the injection site, with no evidence of obstruction during our short-term follow-up period (3 months). Given that delayed obstruction could occur as late as 5 years after injection therapy, long-

term follow-up is required to confirm these results. Another concern for injection material is a particle migration, which limited the use of polytetrafluoroethylene. However, in a previous animal study, it was demonstrated that the average particle size of PMMA more than 40 μm prevents migration to other organs [28]. Considering that the average particle size of PMMA in the mixture was 100 μm , PMMA/Dx can be safely used into ureter without migration.

Some study limitations should be mentioned. First, the duration of follow-up was not sufficient to confirm the long-term effects or complications of the PMMA/Dx mixture. Another limitation is the absence of a control group in our series and a slightly lower success rate compared with previous results of Dx/HA. In our experience, due to a different particle size of PMMA/Dx from previous materials, a learning curve with the material to be accustomed to a tactile sensation and development of the mound is required. In addition, the small number of subjects included in our study impeded to conclude a precise comparative outcome. Nevertheless, the observed success rate suggests that further trials comparing PMMA/Dx and Dx/HA would be worthwhile. The results of the current study demonstrated that injection of PMMA/Dx beneath the mucosal layer of a refluxing ureter is safe, well tolerated, easy to perform, and effective. Additionally, the non-biodegradable nature of this material might be expected to have a long-term durability.

CONCLUSIONS

Off-label use of PMMA/Dx for injection therapy in primary VUR reveals that short-term success rates are 69.7%, which are comparable to those reported for the currently used bulking agent. PMMA/Dx may be a new effective material for endoscopic injection therapy in children with VUR. Long-term follow-up to confirm the durability and prolonged efficacy are necessary to confirm the usefulness of this material in treating VUR.

CONFLICTS OF INTEREST

The authors have nothing to disclose.

ACKNOWLEDGMENTS

This clinical trial was supported by Chungwha Medipower Corporation. Chungwha Medipower Corporation provided the injection materials and supported part of the research funding. Chungwha Medipower Corporation was not involved in the study design, data collection, interpretation

of data, or writing of the manuscript.

REFERENCES

- O'Donnell B, Puri P. Treatment of vesicoureteric reflux by endoscopic injection of Teflon. *Br Med J (Clin Res Ed)* 1984;289:7-9.
- Nelson CP, Copp HL, Lai J, Saigal CS; Urologic Diseases in America Project. Is availability of endoscopy changing initial management of vesicoureteral reflux? *J Urol* 2009;182:1152-7.
- Puri P, Pirker M, Mohanan N, Dawrant M, Dass L, Colhoun E. Subureteral dextranomer/hyaluronic acid injection as first line treatment in the management of high grade vesicoureteral reflux. *J Urol* 2006;176:1856-9; discussion 1859-60.
- Routh JC, Inman BA, Reinberg Y. Dextranomer/hyaluronic acid for pediatric vesicoureteral reflux: systematic review. *Pediatrics* 2010;125:1010-9.
- Holmdahl G, Brandström P, Läckgren G, Sillén U, Stokland E, Jodal U, et al. The Swedish reflux trial in children: II. Vesicoureteral reflux outcome. *J Urol* 2010;184:280-5.
- Kim MT, Ko K, Lee WK, Kim SC, Yang DY. Long-term safety and longevity of a mixture of polymethyl methacrylate and cross-linked dextran (Lipen-10[®]) after penile augmentation: extension study from six to 18 months of follow-up. *World J Mens Health* 2015;33:202-8.
- Lemperle G, Gauthier-Hazan N, Lemperle M. PMMA-Microspheres (Artecoll) for long-lasting correction of wrinkles: refinements and statistical results. *Aesthetic Plast Surg* 1998;22:356-65.
- Lemperle G, Romano JJ, Busso M. Soft tissue augmentation with artecoll: 10-year history, indications, techniques, and complications. *Dermatol Surg* 2003;29:573-87; discussion 587.
- Chertin B, Kocherov S, Chertin L, Natsheh A, Farkas A, Shinfeld OZ, et al. Endoscopic bulking materials for the treatment of vesicoureteral reflux: a review of our 20 years of experience and review of the literature. *Adv Urol* 2011;2011:309626.
- Läckgren G, Wählin N, Sköldenberg E, Stenberg A. Long-term followup of children treated with dextranomer/hyaluronic acid copolymer for vesicoureteral reflux. *J Urol* 2001;166:1887-92.
- Hunziker M, Mohanan N, D'Asta F, Puri P. Incidence of febrile urinary tract infections in children after successful endoscopic treatment of vesicoureteral reflux: a long-term follow-up. *J Pediatr* 2012;160:1015-20.
- Lee EK, Gatti JM, Demarco RT, Murphy JP. Long-term followup of dextranomer/hyaluronic acid injection for vesicoureteral reflux: late failure warrants continued followup. *J Urol* 2009;181:1869-74; discussion 1874-5.
- Hallén L, Dahlqvist A, Laurent C. Dextranomer in hyaluronan (DiHA): a promising substance in treating vocal cord insufficiency. *Laryngoscope* 1998;108:393-7.
- Stenberg A, Larsson E, Lindholm A, Ronneus B, Stenberg A, Läckgren G. Injectable dextranomer-based implant: histopathology, volume changes and DNA-analysis. *Scand J Urol Nephrol* 1999;33:355-61.
- McMann LP, Scherz HC, Kirsch AJ. Long-term preservation of dextranomer/hyaluronic acid copolymer implants after endoscopic treatment of vesicoureteral reflux in children: a sonographic volumetric analysis. *J Urol* 2007;177:316-20; discussion 320.
- Ormaechea M, Ruiz E, Denes E, Gimenez F, Dénes FT, Moldes J, et al. New tissue bulking agent (polyacrylate polyalcohol) for treating vesicoureteral reflux: preliminary results in children. *J Urol* 2010;183:714-7.
- Kocherov S, Ulman I, Nikolaev S, Corbetta JP, Rudin Y, Slavkovic A, et al. Multicenter survey of endoscopic treatment of vesicoureteral reflux using polyacrylate-polyalcohol bulking copolymer (Vantris). *Urology* 2014;84:689-93.
- Karakus SC, User İR, Kılıç BD, Akçaer V, Ceylan H, Ozokutan BH. The comparison of dextranomer/hyaluronic acid and polyacrylate-polyalcohol copolymers in endoscopic treatment of vesicoureteral reflux. *J Pediatr Surg* 2016;51:1496-500.
- Kocaoglu C. Endoscopic treatment of grades IV and V vesicoureteral reflux with two bulking substances: dextranomer hyaluronic acid copolymer versus polyacrylate polyalcohol copolymer in children. *J Pediatr Surg* 2016;51:1711-5.
- Kajbafzadeh AM, Sabetkish S, Khorramirouz R, Sabetkish N. Comparison of histopathological characteristics of polyacrylate polyalcohol copolymer with dextranomer/hyaluronic acid after injection beneath the bladder mucosa layer: a rabbit model. *Int Urol Nephrol* 2017;49:747-52.
- Goldberg DJ. Breakthroughs in US dermal fillers for facial soft-tissue augmentation. *J Cosmet Laser Ther* 2009;11:240-7.
- Jang MW, Jin BK, Lee SH, Park JH, Ryu JM, Yun SP, et al. Effect of PMMA and cross-linked dextran mixture on bio-safety and volume in rat. *Tissue Eng Regen Med* 2010;7:57-63.
- Yang DY, Lee WK, Kim SC. Tolerability and efficacy of newly developed penile injection of cross-linked dextran and polymethylmethacrylate mixture on penile enhancement: 6 months follow-up. *Int J Impot Res* 2013;25:99-103.
- Snodgrass WT. Obstruction of a dysmorphic ureter following dextranomer/hyaluronic acid copolymer. *J Urol* 2004;171:395-6.
- Vandersteen DR, Routh JC, Kirsch AJ, Scherz HC, Ritchey ML, Shapiro E, et al. Postoperative ureteral obstruction after subureteral injection of dextranomer/hyaluronic Acid copolymer. *J Urol* 2006;176:1593-5.
- Rubenwolf PC, Ebert AK, Ruummele P, Rösch WH. Delayed-onset ureteral obstruction after endoscopic dextranomer/hyaluronic acid copolymer (Deflux) injection for treatment of vesicoureteral reflux. *J Urol* 2009;181:1874-8.

- coureteral reflux in children: a case series. *Urology* 2013;81:659-62.
27. Lemperle G, Gauthier-Hazan N, Wolters M, Eisemann-Klein M, Zimmermann U, Duffy DM. Foreign body granulomas after all injectable dermal fillers: part 1. Possible causes. *Plast Reconstr Surg* 2009;123:1842-63.
28. Lemperle G, Morhenn VB, Pestonjamas V, Gallo RL. Migration studies and histology of injectable microspheres of different sizes in mice. *Plast Reconstr Surg* 2004;113:1380-90.