

Case report

Protein C 결핍에서 발생한 소모성 응고질환으로 인한
뇌내출혈로 야기된 뇌성마비 환자에 대한 증례기록연세대학교 의과대학 세브란스병원 재활의학과¹, 소아청소년과²
조유나¹ · 이영목² · 박은숙¹ · 최자영¹ · 박천웅¹ · 나동욱¹Cerebral Palsy due to Intracranial Hemorrhage
Caused by Consumptive Coagulopathy in Protein C
Deficiency: A Case Report

Protein C (PROC) is a potent anticoagulant inactivating coagulation factors Va and VIIIa. PROC deficiency is very rare condition inherited as an autosomal dominant or recessive trait, and associated with various thromboembolic and ischemic conditions. Moreover, severe form of PROC deficiency can cause fatal hemorrhagic complications due to consumptive coagulopathy. We reported two children with hemorrhagic stroke who were diagnosed as severe PROC deficiency caused by two different types of compound heterozygous PROC gene mutations. We described results of laboratory tests, genetic analysis, brain magnetic resonance images, and functional outcomes. Both children received prophylactic anticoagulation therapy and presented with purple-colored skin lesions during rehabilitation. Purpura fulminans caused by insufficient anticoagulation should be differentiated from hematoma caused by excessive anticoagulation therapy in these children.

Key Words: Purpura fulminans, Cerebral palsy, Protein C deficiency

Yoona Cho, MD¹, Young-Mock Lee, MD², Eun Sook Park, MD¹, Ja Young Choi, MD¹, Chung Park, MD¹, Dong-wook Rha, MD, PhD¹

¹Department and Research Institute of Rehabilitation Medicine, ²Department of Pediatrics, Gangnam Severance Hospital, Yonsei University College of Medicine, Seoul, Korea

Submitted: 24 August, 2016
Revised: 13 September, 2016
Accepted: 13 September, 2016

Correspondence to Dong-wook Rha, MD, PhD
Department and Research Institute of Rehabilitation, Medicine Yonsei University College of Medicine, Severance Rehabilitation Hospital, BioMechanics and Robotic Rehabilitation Laboratory, 50-1 Yonsei-ro Seodaemun-gu, Seoul 03722, Korea
Tel: + 82-2-2228-3717, Fax: +82-2-363-2795
E-mail: MEDICUS@yuhs.ac

Introduction

Non-progressive damage to the immature brain is a basic pathomechanism of cerebral palsy (CP), a group of disorders associated with movement and posture abnormalities¹. Multiple etiologies including congenital malformation, cerebral infarction, and hemorrhage can cause CP. In rare cases, perinatal stroke can result from inherited thrombotic pathology such as coagulation factor deficiency².

Protein C (PROC) is a potent anticoagulant that inactivates coagulation factors Va and VIIIa. PROC deficiency can be inherited as an autosomal dominant or recessive trait. Thrombophilic disease resulting from a heterozygous PROC gene mutation usually presents as a thromboembolic event such as deep vein thrombosis or ischemia. Homozygous or compound heterozygous mutations sometimes result in severe disseminated intravascular coagulation and consumptive coagulopathy^{3,4}. The estimated prevalence of severe PROC deficiency, which is derived from population carrier rates of PROC gene mutations, is 1 in 4,000,000 people³. Considering the birth rate in Korea, PROC

deficiency occurs in about one birth every 10 years⁵).

From a previous report in Korea, some patients with PROC deficiency presented with ischemic stroke; these patients had mild PROC deficiency and heterozygotic mutations⁶. However, to our knowledge, there has been no report about hemorrhagic stroke caused by consumptive coagulopathy in children with severe PROC deficiency. Here, we report two cases of children with PROC deficiency who were diagnosed with spastic CP caused by hemorrhagic stroke accompanied by purpura fulminans.

Case Reports

Case 1

A 4-day-old female infant without any perinatal complications was referred to the pediatric department for skin color changes on both feet (Fig. 1). Based on abnormal coagulation test results, PT/aPTT 13.4 sec/44 sec (normal range: 10.0–15.3/25.4–59.8), Fibrinogen 58 mg/dL (normal range: 162–462 mg/dL), D-dimer 62.5 mcg/mL (normal range: 0–0.65 mcg/ml), protein S 68% (normal range: 50–130%), and PROC < 0.01 IU/mL, which was lower than 1% of normal PROC level at the date of admission, and follow up study showed prolongation of PT/aPTT (23.9 sec/84.4 sec). Also the bloody cerebrospinal fluid was detected, PROC deficiency was diagnosed. Brain magnetic resonance imaging (MRI) showed subarachnoid and intraventricular hemorrhage with ventriculomegaly (Fig. 2A); subsequently, she received a ventriculoperitoneal shunt at 6 months old (Fig. 2B).

Genetic evaluation revealed compound heterozygous PROC gene mutations: a missense mutation (Arg211Trp) and a frameshift mutation (Gly239Serfs*8). Although the infant's parents had no personal or family history of venous thromboembolic

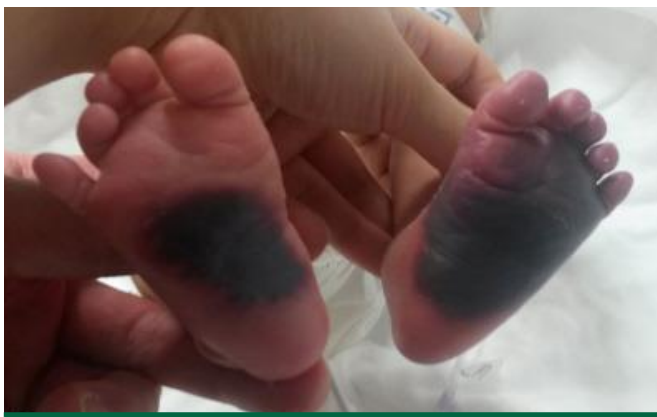

Fig. 1. Case 1 infant: A female infant was admitted to the hospital 4 days after birth. Skin color changes are observed in both feet.

disease, the mother had a missense mutation (Arg211Trp) at 2q14.3 and the father had a frameshift mutation (Leu242Prots) at 2q14.3. The infant received protein C concentrates replacement and the level of protein C was increased. She was referred to the rehabilitation department at 8 months of age after prescription of regular prophylactic low-molecular-weight heparin (LMWH) injections.

The infant had hypertonia in all four extremities; she was unable to control her neck movement and make eye contact, which corresponded to gross motor function classification system (GMFCS) level V, manual ability classification system (MACS) level V, and communication function classification system (CFCS) level V at 9 months old. During rehabilitation, both of her thighs became swollen and abruptly turned purple (Fig. 3). Hematoma was suspected initially, but the lesion expanded after tapering down LMWH. The lesion resolved after increasing the LMWH dosage; subsequently, purpura fulminans was diagnosed.

Case 2

A 7-day-old female infant presented with a hyperechoic lesion with cystic change on the bilateral frontal lobe upon fetal sonography. Upon coagulation factor analysis, PT/aPTT (12.3 sec/36.2 sec) was normal and D-dimer was increased to 1,016

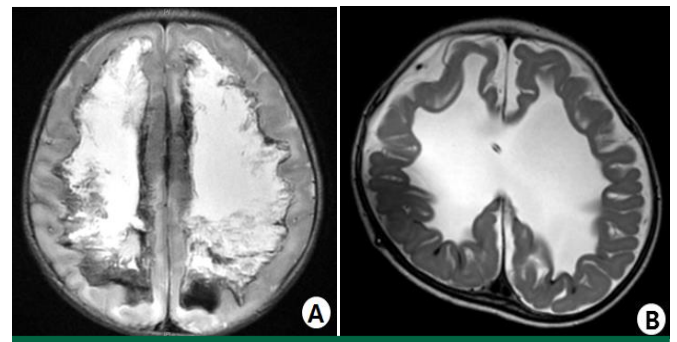


Fig. 2. Case 1 infant: Brain magnetic resonance images show bilateral hydrocephalus caused by intraventricular hemorrhage and subarachnoid hemorrhage in a fast-spin echo image (A) and decreased size of ventricles after ventriculoperitoneal shunt is observed (B).

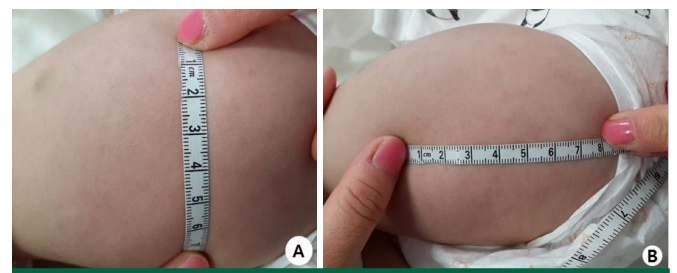


Fig. 3. Case 1 infant: Purpura fulminans developed on the infant's right thigh (A) and left thigh (B) during rehabilitation at 10 months old.

ng/mL (normal range : 0–243 ng/mL), Fibrinogen (225 mg/dL) was within normal range and PT/aPTT was prolonged to 18.2 sec/55.7 sec at follow up study. Also PROC (0.03 IU/mL, 3%) and protein S levels (0.47 IU/mL, 47%) were significantly lower than normal. Brain MRI revealed intracerebral hemorrhage, hydrocephalus, and vitreous hemorrhage with retinal detachment (Fig. 4A, 4B). Genetic evaluation showed compound heterozygous PROC gene mutations: a missense mutation (Arg211Gly) and an insertion mutation (718dupG).

Although the infant received regular LMWH injections, she represented with purple-colored skin lesions on the head and both feet 13 days after birth (Fig. 5). Because the lesions were hard with accompanying necrotic tissue, we diagnosed purpura fulminans: the lesions resolved after increasing the LMWH dose. After ventriculoperitoneal shunt surgery at 5 months old for aggravating hydrocephalus, the infant exhibited sudden growth of a hygroma on the cerebral falx and in the subdural space (Fig. 4C). The shunt valve pressure was increased and the hygroma had nearly resolved upon follow up neurosonography (Fig. 4D).

The infant had hypertonia in all four extremities; she was unable to control her neck movement and make eye contact, corresponding to GMFCS level V, MACS level V, and CFCS level V at 3 months old; she started post-operative rehabilitation.

Discussion

The PROC gene is located on chromosome 2, at 2q13–q14, which comprises nine exons⁴⁾. Common presentations of protein C deficiency developing at neonatal period are intracranial thrombosis and hemorrhage followed by purpura fulminans that usually lead to death⁷⁾. These two infants had compound heterozygous PROC gene mutations and presented with skin lesions typical of purpura fulminans. We believe these infants

developed consumptive coagulopathy due to PROC deficiency, which eventually caused massive intracerebral hemorrhages resulting in severe bilateral spastic CP corresponding to GMFCS level V.

Patients identified with severe PROC deficiency should be treated with long-term anticoagulant therapy to prevent further

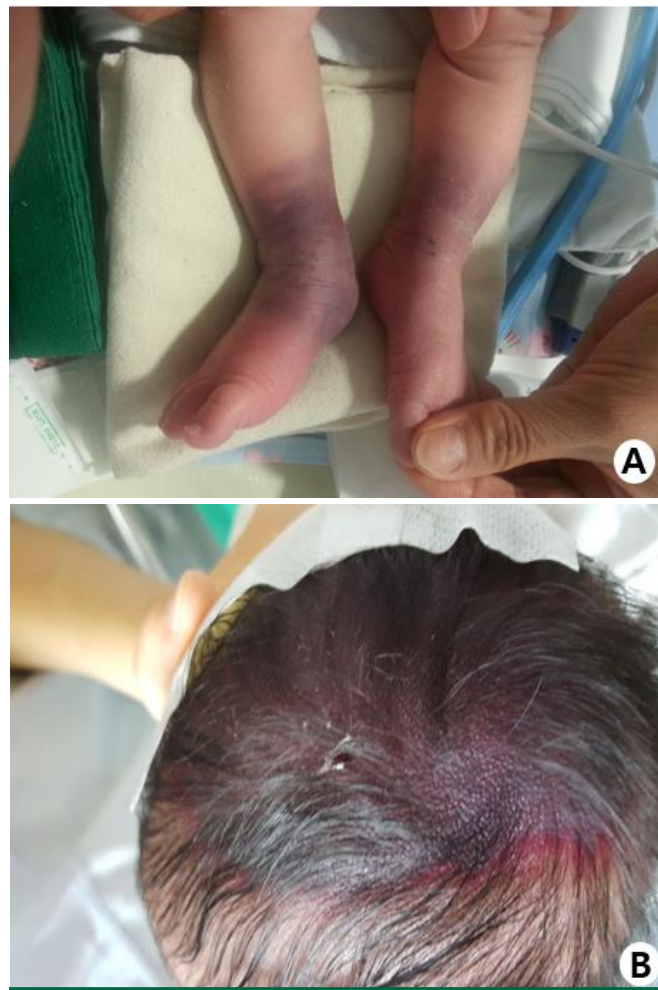

Fig. 5. Case 2 infant: Purpura fulminans is detected on both feet (A) and the head (B) of a female neonate at 13 days of age.

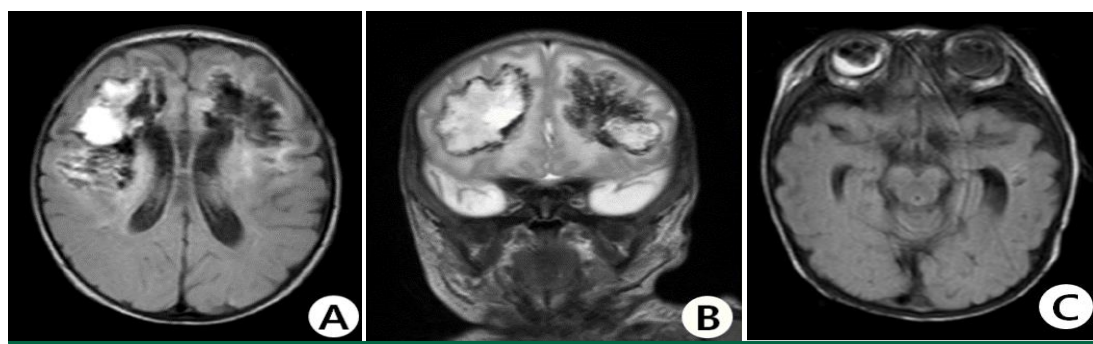


Fig. 4. Case 2 infant: Brain magnetic resonance images (T2-weighted images) show bilateral intracerebral hemorrhage before ventriculo peritoneal shunt surgery in the frontal lobe (A, B), and intraventricular, subarachnoid, and vitreous hemorrhages in T2-weighted flair image (C).

damage to the vessels. Several anticoagulant drugs are available; warfarin is commonly used, although it can induce skin necrosis. PROC is a vitamin K-dependent protein; the activated form of PROC acts as an anticoagulant by inactivating factors Va and VIIIa⁸⁾. Thus, patients with PROC deficiency are at a greater risk of warfarin-induced skin necrosis because additional warfarin is prescribed to compensate for the further loss of PROC. Many authors propose LMWH for life-long anticoagulation⁸⁾. LMWH is conveniently administered by injection and does not require monitoring. Patients with severe PROC deficiency can be administered PROC concentrate/replacement, although this treatment is very expensive and not currently popular³⁾.

Range of motion exercises commonly used during rehabilitation programs should be performed with caution because they might cause hematomas in patients with bleeding tendency. The hematoma was developed at frequently physical contacted area, but the character of purpura fulminans was painful and showed irregular margin and progressed abruptly necrotic change at palm, sole and thigh⁷⁾. Moreover, in patients with PROC deficiency, purpura fulminans caused by insufficient anticoagulation should be differentiated from hematoma caused by excessive anticoagulation therapy. The treatments of these two lesions are completely different, with reduction in the dose of anticoagulants to treat hematoma and increase in the dose of anticoagulants in purpura fulminans to prevent consumptive coagulopathy.

Thromboembolic disease can cause ischemic and hemorrhagic stroke in pediatric patients. Therefore, we recommend performing coagulation factor assays in children who experience stroke of unknown etiology. During rehabilitation, any change in skin color should be carefully evaluated to differentiate purpura fulminans due to consumptive coagulopathy from hematoma due to excessive anticoagulation.

요약

Protein C는 응고인자 Va와 VIIIa를 비활성시키는 항응고 인자로써 PROC 결핍은 매우 희귀한 질환으로 열성유전이 되며 다양한 혈전성 또는 허혈성 질환을 일으킬 수 있는 것으로 알려져 있다. 심한 경우에는 소모성 응고병증 상태를 야기시켜 사망에 이르게 할 수도 있다. 우리는 본 논문을 통하여 합성이질접합형(compound heterozygous)으로 유전된 PROC 결핍 환자에서 소모성 응고병증으로 인한 출혈성 뇌졸중 환자 두 명을 기술하였고, 진단검사와 유전자검사, 뇌 자기공명영상 이미지와 기능적 상태를 함께 분석하였다. 또한 PROC 결핍 환자에서 발생할 수 있는 합병증 중 전격성 자반 피부병변을 소개하여 항응고인자 투약치료로 인하여 발생가능한 혈종과 구별이 필요함을 소개하고자 하였다.

References

- 1) Morris C. Definition and classification of cerebral palsy: a historical perspective. *Dev Med Child Neurol Suppl* 2007;109:3-7.
- 2) Gibson CS, MacLennan AH, Haque WM, Haan EA, Priest K, Chan A, et al. Associations between inherited thrombophilias, gestational age, and cerebral palsy. *Am J Obstet Gynecol* 2005;193:1437.
- 3) Goldenberge NA, Manco-Johnson MJ. Protein C deficiency. *Haemophilia* 2008;14:1214-21.
- 4) Khan S, Dickerman JD. Hereditary thrombophilia. *Thromb J* 2006;4:15.
- 5) Korean Statistical Information Service [Internet]. Korea; [updated 2015 Sept 30]. Available from: <http://kosis.kr/>.
- 6) Kim E, Cha EY, Kim SY, Lee W, Sung IK, Chun CS. Stroke associated with protein C and S deficiency in neonate: report of two cases. *J Korean Soc Neonatol* 2007;14:71-7.
- 7) Ohga S, Kang D, Kinjo T, Ochiai M, Doi T, Ishimura M, et al. Paediatric presentation and outcome of congenital protein C deficiency in Japan. *Haemophilia* 2013 May;19(3):378-84.
- 8) Monagle P, Andrew M, Halton J, Marlar R, Jardine L, Vegh P, et al. Homozygous protein C deficiency: description of a new mutation and successful treatment with low molecular weight heparin. *Thromb Haemost* 1998;79:756-61.