

CASE REPORT

International Journal of Pain 2011;2:60-63
pISSN 2233-4793 / eISSN 2233-4807Received: November 22, 2011
Accepted: December 7, 2011

Chronic Mandibular Osteomyelitis with Normal Value of C-reactive Protein

Woo Young Park¹, Jong Bum Choi^{1,2}, Duck Mi Yoon^{1,2}, Do Hyeong Kim¹¹Department of Anesthesiology and Pain Medicine, ²Anesthesia and Pain Research Institute, Yonsei University College of Medicine, Seoul, Korea

A 58-year-old male was referred to our pain clinic with right lower facial pain of visual analogue scale 8/10 cm. One week ago, his right lower 3rd molar was extracted for vesicles at the buccal mucosal membrane and right lower facial hypoesthesia. Immunoserologic tests revealed negative varicella-zoster virus immunoglobulin-M, positive immunoglobulin-G and normal value of C-reactive protein. Buccal mucosa biopsy revealed squamous epithelial hyperplasia. Medications for pain control was pregabalin 150 mg PO bid, amitriptyline 10 mg PO hs, fentanyl patch 12.5 µg/h, carbamazepine 200 mg PO hs. C-arm guided block and pulsed radiofrequency lesioning was performed at mandibular branch of the right trigeminal nerve. And then VAS score was reduced to 4/10 cm. On facial bone CT, facial MRI and 3-phase bone scan, chronic osteomyelitis was suspected on the right mandible. Herpes zoster by atypical clinical manifestations was excluded. After additional biopsy and culture on lesion, antibiotics were used to treat the osteomyelitis and surgical follow-up was planned for surgical removal of necrotic tissue.

Key Words: C-reactive protein, herpes zoster, mandibular osteomyelitis.

Correspondence to: Jong Bum Choi, Department of Anesthesiology and Pain Medicine, Anesthesia and Pain Research Institute, Yonsei University College of Medicine, 211, Eonju-ro, Gangnam-gu, Seoul 135-720, Korea. Tel: +82-2-2019-3528, Fax: +82-2-3463-0940, E-mail: romeojb@naver.com

Osteomyelitis is an inflammatory disease of the osseous tissue which includes the bone marrow, sponge bone, cortical bone and periosteum. It starts at the marrow cavity and sponge bone, then expands to the cortical bone, and finally spreads to the periosteum to cause chronic pain around the osteomyelitis area [1]. Our case reiterates the need for early implementation of diagnostic imaging through such techniques as magnetic resonance imaging (MRI), computed tomography (CT), as well as prognostic signs of clinical symptoms and changes in blood test figures, for the accurate diagnosis of a patient with chronic mandibular osteomyelitis. This report aims to support diagnosis of facial pain and related chronic mandibular osteomyelitis.

CASE REPORT

A 58-year-old male patient visited the clinic with facial pain in the right mandibular area which developed one week before the OPD visit. According to his medical history, he had felt a twinge in the lower molars once every few days, beginning seven years prior to visiting the hospital. Six months before visiting, he had two of his right lower molars and one of his right upper molars extracted in the dental clinic of another hospital. One week before visiting the hospital, a bulla formed inside the right cheek and burst by itself. After this incident, the inside of his right cheek started to swell and the patient began to experience foreign body sensations and hypesthesia inside the right side of his mouth. A third molar extraction and dermatology consultation was carried

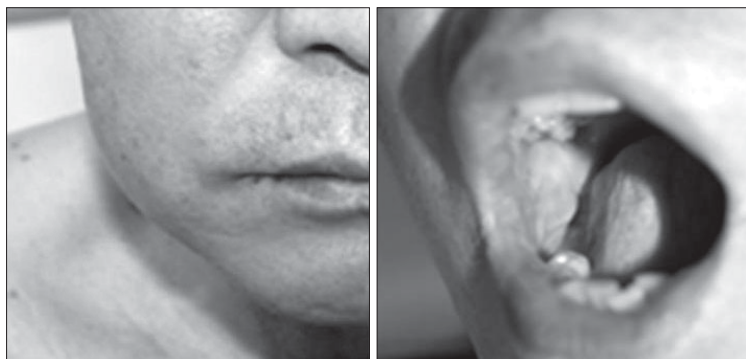

Fig. 1. Picture of edema in right cheek and buccal mucosal membrane.

out in the dental clinic of our hospital, and consultation was also requested to the pain clinic is suspicion of herpes zoster (Fig. 1). At the time of visit, a breakthrough pain of visual analogue scale (VAS) 8/10 cm occurred up to ten times a day, accompanied by sleep disturbances associated with the mandibular branch area of the trigeminal nerve. There were no signs of allodynia, hyperalgesia or tenderness in the physical examination, where hypesthesia of 7/10 was observed in the right mandibular facial skin, as well as stinging pain being felt when the edema on the buccal mucosa was stimulated. According to the immunoserologic test regarding the varicella-zoster virus, Immunoglobulin-G (IgG) antibody tested positive, Immunoglobulin-M (IgM) antibody tested negative, and the C-reactive protein (CRP) figures were normal. There were no characteristic skin symptoms and conditions of pain were also different to symptoms of herpes zoster. To exclude the possibility of osteomyelitis or tumor, an intraoral buccal mucosal membrane biopsy, facial MRI, facial bone CT, and a 3-phase bone scan were additionally performed. Accurate diagnosis had not been reached, but severe pain with signs of neuropathic pain was observed so 75 mg PO bid of pregabalin was prescribed but resulted in the pain worsening to VAS 10/10 cm. Additional administration of medication and nerve blockade were performed to ease the pain. The medication was increased to 150 mg PO bid of pregabalin, 10 mg PO hs of amitriptyline, and the inclusion of a 12.5 µg/h fentanyl patch, but the pain continued so 200 mg PO hs of carbamazepine was additionally administered to distinguish if the pain was caused by trigeminal neuralgia. VAS decreased to 6/10 cm after the medication. In regards to nerve blockade, the patient was hospitalized and a C-arm guided right trigeminal nerve third branch block was performed two times, right stellate ganglion block two times, right mental nerve block one time, and pulsed radiofrequency lesioning of the right trigeminal nerve third branch was performed one time, resulting is the VAS decreasing to 4/10 cm. An intraoral membrane biopsy was performed during the pain management procedures for the medication administration and nerve blockades, and the results indicated squamous cell hyperplasia. Buccal submucosal steroid injection was performed in the dermatology, which resulted in the edema in the intraoral right buccal mucosal membrane being reduced. Facial bone CT showed mandibular osteomyelitis in the extracted area and bone uptake increase in the form of osteomyelitis was observed in the 3-phase bone scan. The results of the facial MRI also showed osteomyelitis (Fig. 2). Breakthrough pain was reduced to two to three times a day, and sleep disturbance was improved with VAS being maintained at 4/10 cm, so the patient was discharged from the hospital. Antibiotics were administered after additional biopsy and culture tests in dental surgery, and a surgical debridement was performed.

DISCUSSION

Chronic osteomyelitis in the mandibular is not a common disease, but can occur after dental infection, complication after extraction, trauma in the mandibular, or after radiation therapy. Clinical symptoms can be regional pain, edema, trismus, and other various types of pain which are not general. It is diagnosed through imaging, biopsy, and culture tests, and is treated by surgical

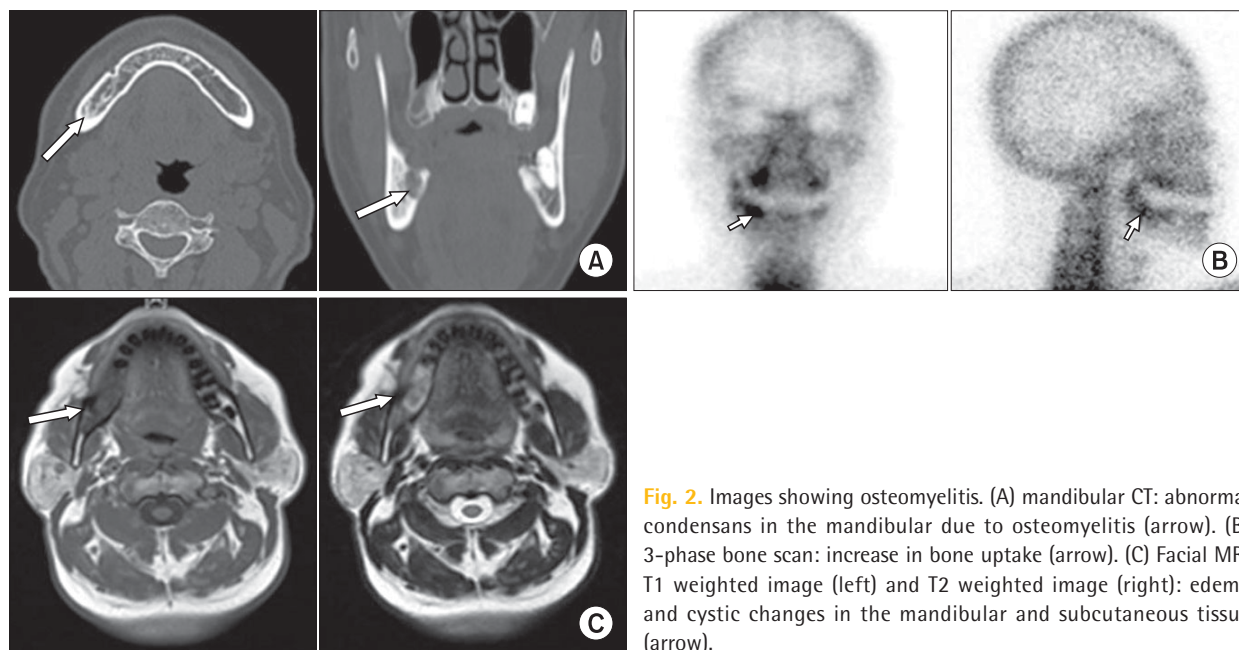


Fig. 2. Images showing osteomyelitis. (A) mandibular CT: abnormal condensans in the mandibular due to osteomyelitis (arrow). (B) 3-phase bone scan: increase in bone uptake (arrow). (C) Facial MRI T1 weighted image (left) and T2 weighted image (right): edema and cystic changes in the mandibular and subcutaneous tissue (arrow).

debridement and administration of antibiotics [2]. As in our case, osteomyelitis can occur as a serious complication due to the extraction of the third molar, and the resulting pain can be mistaken for atypical facial pain or herpes zoster in the trigeminal nerve [3]. Contrary to trigeminal nerve pain or typical facial pain, atypical facial pain is observed as pain that is not localized, has vague characteristics, and does not follow anatomical innervations. Also, the organic cause has not been identified. Therefore, diseases with chronic facial pain such as trigeminal neuralgia, neuralgia after herpes zoster, dental diseases, and defects in the temporomandibular joints can only be diagnosed through the exclusion process by medical history, physical examination, and diagnostic tests, but it is still difficult to distinguish between these diseases [4]. Bone scan, X-ray, CT, and MRI images can be used to diagnose mandibular osteomyelitis, where CT images are cost-effective in confirming changes in the mandibular. Bone scans show increased bone uptake, and in X-ray and CT, radiolucent areas and osteoclasia, sequestrum formation or calcification are observed. In MRI, osteoclasia and osteosclerosis, edema in the bone and subcutaneous fat, and cystic changes can also be observed. Pain and edema, and purulent discharge can accompany, while typical changes in radiation tests may not appear for several weeks. An increase of CRP, Immunoglobulin and complement figures can be considered as sensitive indicators for chronic osteomyelitis, but this is disputable [5]. Mandibular osteomyelitis can occur unilaterally from herpes zoster infection, but the symptoms are atypical, so differential diagnosis with postherpetic neuralgia is necessary [6,7]. Also, differential diagnosis should occur with facial bone fracture, tumor, trigeminal neuralgia, zoster sine herpette, atypical facial pain, and headaches which can cause pain in the head and neck, and to also distinguish secondary reasons, confirmation through CT or MRI radiologic tests, as well as physical examination are necessary [8]. CRP is a protein formed at the liver in response to infection or inflammation. However, the possibility of osteomyelitis should not be excluded even in normal figures of lower than 5 mg/L [9]. In our case, the CRP was normal, but the degree of pain was severe and symptoms did not match typical pain disorders. As a result, imaging tests were performed to identify other diseases that may cause the pain, and mandibular chronic osteomyelitis was observed. Although there were positive responses to IgG antibody, regarding the varicella-zoster virus, hypoesthesia in the right mandibular facial area and oral blistering one week before visiting the hospital, herpes zoster and osteomyelitis from herpes zoster were excluded since there were no typical allodynia or hyperalgesia. The pain had occurred several months before the blistering and there were no continuous skin lesions, which was followed by a negative response to the IgM antibody. As can be seen in our case, even when the CRP figures may be normal in patients with facial pain, accompanied

with a medical history of dental treatment, image testing such as CT, MRI, or bone scan can be used to confirm the possibility of facial pain from chronic osteomyelitis, and a diagnosis of chronic osteomyelitis through additional biopsy and culture tests can be made [10].

REFERENCES

1. Lee SB, Huh KH, Yi WJ, Kim M, Lee S: Osteomyelitis following extraction of lower third molar during pregnancy. *Korean J Oral Maxillofac Radiol* 2008; 38: 177-82.
2. Harris LF: Chronic mandibular osteomyelitis. *South Med J* 1986; 79: 696-7.
3. Ralf S, Maria M, Suarez C, Marc CM, Rainer S: Osteomyelitis of the mandible following third molar surgery: a regrettable consequence in a healthy patient. *Quintessence Int* 2009; 40: 351-4.
4. Lee HC, Ahn JY, Kim WO, Yoon DM: Atypical facial pain: a retrospective study. *Korean J Pain* 2003; 16: 181-4.
5. Kim SK, Jang HS: Treatment of chronic osteomyelitis in Korea. *Oral Surg Oral Med Oral Pathol* 2001; 92: 394-8.
6. Garty BZ, Dinari G, Sarnat H, Cohen S, Nitzan M: Tooth exfoliation and osteonecrosis of the maxilla after trigeminal herpes zoster. *J Pediatr* 1985; 106: 71-3.
7. Muto T, Tsuchiya H, Sato K, Kanazawa M: Tooth exfoliation and necrosis of the mandible—a rare complication following trigeminal herpes zoster. *J Oral Maxillofac Surg* 1990; 48: 1000-3.
8. Bernhard S, Anton V: Osteomyelitis of the mandible. *Neuroimag Clin N Am* 2003; 13: 605-18.
9. Harris JC, Caesar DH, Davison C, Phibbs R, Than MP: Review article: How useful are laboratory investigations in the Emergency Department evaluation of possible osteomyelitis? *Emergency Medicine Australasia* 2011; 23: 317-30.
10. Fukumitsu N, Ujigawa K, Mori Y, Auchi K, Miida K, Tatsuno S, et al: What can be identified by three-phase bone scintigraphy in patients with chronic osteomyelitis of the mandible? *Ann Nucl Med* 2010; 24: 287-93.