

CASE REPORT

Urachal cyst presenting with huge abscess formation in adults

Sung Hwan Lee, Hyang Im Lee¹, Dong Gue Shin²Department of Surgery, Migrant Worker's Hospital, Seoul, Departments of ¹Pathology and ²Surgery, Seoul Medical Center, Seoul, Korea

Urachal disease, a disorder where embryonic remnant of the cloaca and the allantois present after birth as a midline fibrous cord, is usually detected in infancy and childhood. But urachal disease in adults is rare. We report a case of a huge abscess derived from a urachal cyst in an adult. A 52-year-old man presented with peri-umbilical distension and abdominal pain for 2 weeks. Ultrasonography and abdominal computed tomography scan demonstrated a huge abscess derived from the abdominal wall. After prompt incision and drainage, the remaining abscess cavity was removed completely under general anesthesia. Pathologic report was consistent with urachal duct cyst, and the patient was discharged in a week without complication.

Key Words: Urachal cyst, Adult

INTRODUCTION

The urachus is a fibrous cord structure formed after the obliteration of the urogenital sinus and allantois during the embryologic process. Abnormal remnants of the urachus can present as patent urachus, vesicourachal diverticulum, urachal sinus or urachal cyst. Urachal abscess is an uncommon manifestation of urachal disease and rare in adults. We present one case of a huge urachal abscess in an adult derived from a urachal cyst.

CASE REPORT

A 52-year-old man presented with weight loss of 10 kg with lethargy and periumbilical distension with erythema after picking his umbilicus with his finger. He also complained of decreased appetite and intermittent abdominal pain localized to the periumbilical region for 2 weeks. There was no personal history of any systemic diseases and major operations. On physical examination, vital signs were stable except rapid pulse rate of 110 beats/min. The abdomen was rigid and distended, and there was erythema around the umbilicus with tenderness and focal rigidity.

Laboratory data revealed a white blood cell count of

Received January 19, 2012, Revised May 17, 2012, Accepted May 31, 2012

Correspondence to: Dong Gue Shin
Department of Surgery, Seoul Medical Center, 156 Sinnae-ro, Jungnang-gu, Seoul 131-130, Korea
Tel: +82-2-2276-7871, Fax: +82-2-2276-7880, E-mail: shindongue@naver.com

© Journal of the Korean Surgical Society is an Open Access Journal. All articles are distributed under the terms of the Creative Commons Attribution Non-Commercial License (<http://creativecommons.org/licenses/by-nc/3.0/>) which permits unrestricted non-commercial use, distribution, and reproduction in any medium, provided the original work is properly cited.

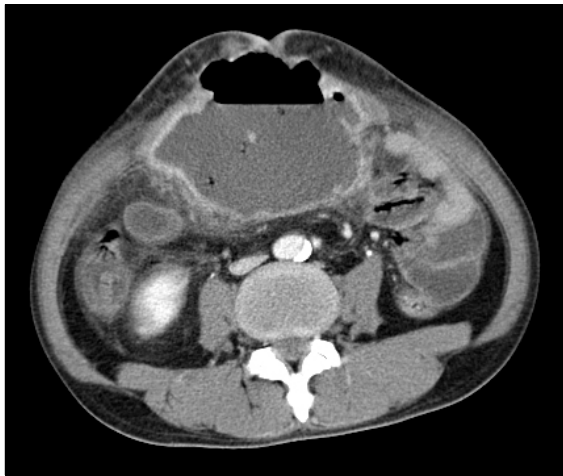


Fig. 1. Computed tomography showed huge abscess containing fluid and gas below umbilicus.

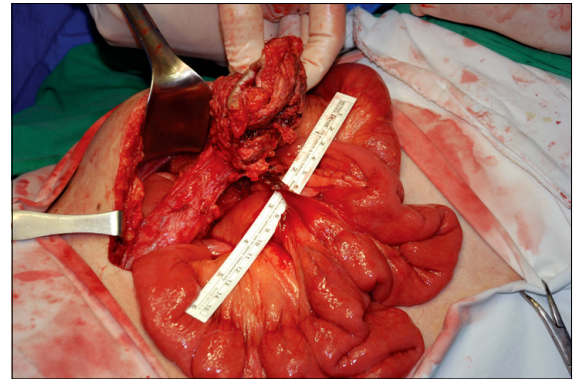


Fig. 2. The operative findings. Abscess cavity and urachus was completely removed. Thin fibrous band was observed between abscess cavity and the middle of mesentery, but there was no communication with small bowel.

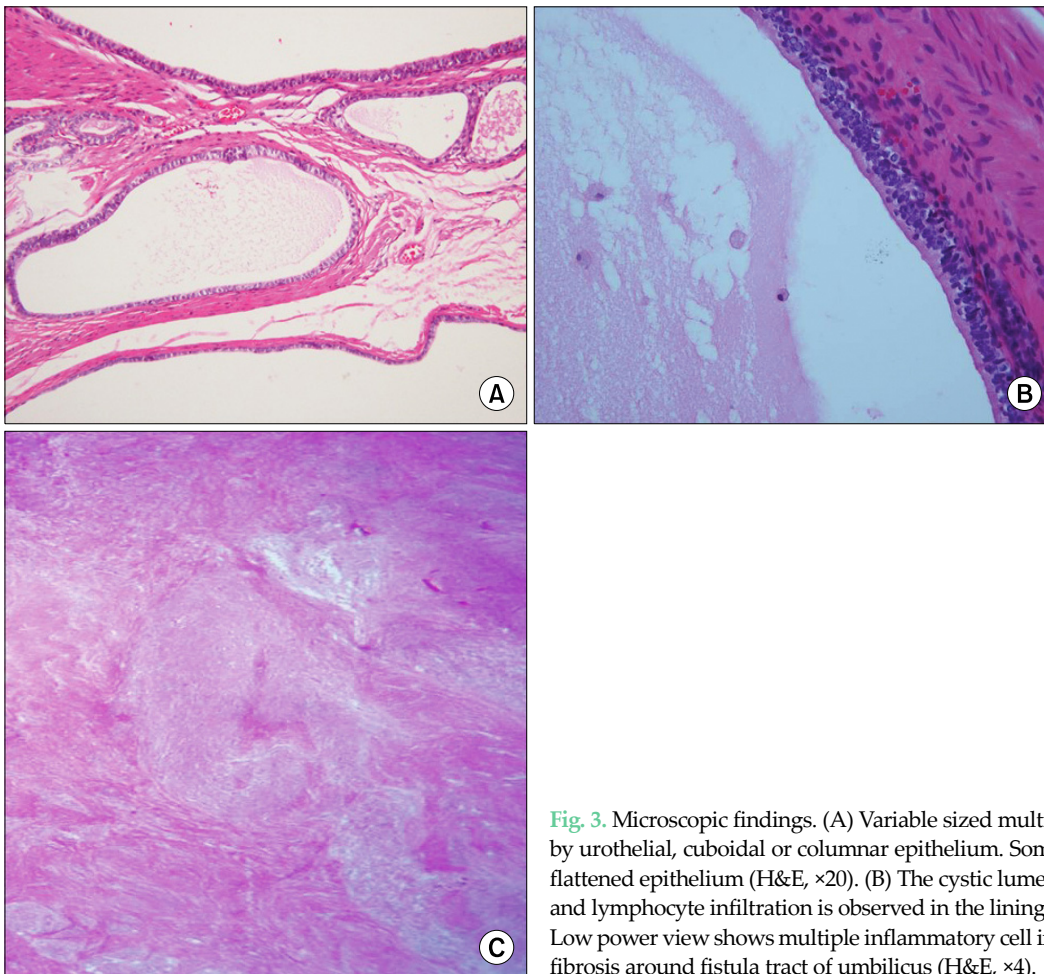


Fig. 3. Microscopic findings. (A) Variable sized multilocular cysts or ducts lined by urothelial, cuboidal or columnar epithelium. Some large cysts were lined by flattened epithelium (H&E, $\times 20$). (B) The cystic lumen contains some histiocytes and lymphocyte infiltration is observed in the lining epithelium (H&E, $\times 40$). (C) Low power view shows multiple inflammatory cell infiltration and surrounding fibrosis around fistula tract of umbilicus (H&E, $\times 4$).

13,000/uL, hemoglobin level of 12.5 g/dL; others were within the normal limit. An abdominal ultrasonograph study revealed a huge mass showing mixed echogenicity and arising from the umbilicus. He was referred for abdominal computed tomography scan revealing a 14 × 11.3 × 8.6 cm abscess cavity arising from the umbilicus and extending to the superior surface of the bladder along the urachus tract (Fig. 1). There was no evidence of communication between the abscess cavity and the bladder.

Incision and drainage were performed promptly under local anesthesia and then, intravenous antibiotics and wound dressing were maintained for a week. After the umbilical lesion and general conditions improved, a laparotomy under general anesthesia was performed in order to remove the abscess cavity. The operative finding revealed that the abscess was derived from a urachal duct cyst (Fig. 2). The patient was discharged at postoperative day #7 without any complications. The pathologic report was consistent with urachal duct cyst (Fig. 3).

DISCUSSION

The urachus is an embryonic remnant of the cloaca and the allantois which is present after birth as a midline fibrous cord extending from the anterior dome of the urinary bladder to the umbilicus [1]. If the obliteration of the urachal patency does not proceed normally after birth, the persistent urachal remnant may result in various clinical problems. The congenital urachal anomalies are more common in males and have 4 types including patent urachus (about 50% of cases), urachal cyst (about 30%), urachal sinus (about 15%), and urachal diverticulum (about 5%) [2]. The incidence of urachal anomalies in infancy and childhood has been reported at about 1 in 5,000 with 3:1 male to female ratio [3]. Because urachal disease is usually detected in infancy and childhood, it is rare in adults. Yiee et al. [4] reported that there were approximately two cases of urachal abnormality per 100,000 hospital admissions in adults.

Clinical presentation is usually associated with super-added infection of the urachal cyst. Infected urachal cysts present with various symptoms; low abdominal mass,

umbilical discharge, tenderness with erythema, fever, urinary tract infection, hematuria, and peritonitis. Infected urachal cyst can occasionally lead to urachal abscess and can develop to systemic septic condition. With a severe urachal cyst infection, pyourachus can form a fistula with bladder, bowel or umbilicus. Abscess rupture due to expansion of infected urachal cyst can cause acute abdomen requiring emergency operation [5].

Diagnosis of urachal cyst is usually made with either ultrasonography or computed tomography. Cystography or cystoscopy can be useful to define the full extent of the cyst wall and delineate the urachal sinus [6]. Initial administering of IV antibiotics and definitive surgical excision is recommended in the treatment of urachal abscess. Simple drainage of the cyst is not recommended due to high recurrence rates (approximately 30%) [7]. If the patient has a huge size of abscess with poor general condition, it is better to perform percutaneous drainage of the urachal abscess before surgical excision [8]. Because of the high recurrence rate and possibility of developing carcinoma in the urachal remnant, it is a key point to complete resection of the cyst wall throughout its length during operation [9]. Operation may include removal of cuff of the bladder if there is communication between the urachal cyst and the bladder. Open excision has been performed as the treatment of choice, traditionally. However, recently, the laparoscopic method has been accepted as an alternative option because of faster recovery, less postoperative pain and better cosmetic results [10].

In summary, urachal abscess is rare in adulthood but should be considered as differential diagnosis of abdominal pain, because it may require emergency surgical management. This case demonstrates that urachal abscesses are a rare but critical disease presenting with abdominal pain in adults.

CONFLICTS OF INTEREST

No potential conflict of interest relevant to this article was reported.

REFERENCES

1. Moore KL. The urogenital system. In: Moore KL, editor. *The developing human: clinically oriented embryology*. 3rd ed. Philadelphia: Saunders; 1982. p.255-97.
2. Mesrobian HG, Zacharias A, Balcom AH, Cohen RD. Ten years of experience with isolated urachal anomalies in children. *J Urol* 1997;158(3 Pt 2):1316-8.
3. Spataro RF, Davis RS, McLachlan MS, Linke CA, Barbaric ZL. Urachal abnormalities in the adult. *Radiology* 1983;149:659-63.
4. Yiee JH, Garcia N, Baker LA, Barber R, Snodgrass WT, Wilcox DT. A diagnostic algorithm for urachal anomalies. *J Pediatr Urol* 2007;3:500-4.
5. Goldman IL, Caldamone AA, Gauderer M, Hampel N, Wesselhoeft CW, Elder JS. Infected urachal cysts: a review of 10 cases. *J Urol* 1988;140:375-8.
6. Berman SM, Tolia BM, Laor E, Reid RE, Schweizerhof SP, Freed SZ. Urachal remnants in adults. *Urology* 1988;31:17-21.
7. Walsh SA, Weiss RM. Case report: persistent dysuria and a suprapubic mass in a 3-year-old boy. *Curr Opin Pediatr* 2002;14:647-8.
8. Pesce C, Costa L, Musi L, Campobasso P, Zimbardo L. Relevance of infection in children with urachal cysts. *Eur Urol* 2000;38:457-60.
9. Mesrobian HG, Zacharias A, Balcom AH, Cohen RD. Ten years of experience with isolated urachal anomalies in children. *J Urol* 1997;158(3 Pt 2):1316-8.
10. Lee SI, Kim SS, Moon HY. Laparoscopic extraperitoneal resection of urachal cyst. *J Korean Surg Soc* 2010;78:267-9.