

ORIGINAL ARTICLE

Hip Pelvis 27(4): 209-215, 2015

<http://dx.doi.org/10.5371/hp.2015.27.4.209>**Hip & Pelvis**

The Results of Long-term Follow-up of Total Hip Arthroplasty Using Hydroxyapatite-coated Cups

Chang-Dong Han, MD, Keun-Young Shin, MD, Hyun-Hee Lee, MD,
Kwan-Kyu Park, MD, Ick-Hwan Yang, MD, Woo-Suk Lee, MD

Department of Orthopaedic Surgery, Yonsei University College of Medicine, Seoul, Korea

Purpose: The aim of this study was to report the long-term outcome and the failure mechanism of cementless total hip arthroplasty (THA) using hydroxyapatite (HA)-coated acetabular cup.

Materials and Methods: From January 1992 to May 1994, a total of 123 consecutive cementless primary THAs were performed using a HA-coated acetabular cup with metal-on-polyethylene articulation. We retrospectively evaluated 66 hips available for follow-up at a mean 18.3 years (range, 10.4-23.6 years). The survival analysis was performed by the Kaplan-Meier method. We defined end point as any failure that required a reoperation of acetabular component.

Results: Thirty-nine of 66 hips (59.1%) were defined as a failure for progressive acetabular osteolysis or aseptic loosening of the cup. Acetabular osteolysis was observed in 47 hips (71.2%) and 33 hips (50.0%) were revised because of cup loosening. The Kaplan-Meier method showed the survival rate of the acetabular cup to be 46.3% at 15 years and 34.8% at 20 years for any failure that required a reoperation of acetabular component.

Conclusion: The long-term survival rate of THA using HA-coated acetabular cup was unsatisfactory, and it was attributed to vulnerable property of HA coating and progressive osteolysis.

Key Words: Total hip arthroplasty, Hydroxyapatite-coated, Acetabular cup, Long-term outcome

INTRODUCTION

Hydroxyapatite (HA) coating has been advocated to improve osteointegration due to its osteoconductive

potential and to achieve early stability between the prosthesis and the bone^{1,2)}. It has been reported that total hip arthroplasty (THA) using HA-coated prosthesis shows excellent clinical and radiological results including the presence of good osteointegration with regard to short-term result³⁾. Some midterm follow-up studies have also shown good clinical and radiological results with THA using HA-coated acetabular cup⁴⁻⁶⁾. The authors stated that the rates of polyethylene (PE) wear and acetabular osteolysis were relatively low in contrast to other studies.

However, high failure rate of the HA-coated acetabular cups has been reported in a number of midterm series⁷⁻¹⁴⁾. Numerous authors described a series of cup failures attributable to osteolysis, PE liner wear, and aseptic loosening¹⁵⁻¹⁷⁾. Retrieved cup studies and animal experiments indicated that the HA coating

Submitted: October 14, 2015 **1st revision:** November 9, 2015

Final acceptance: November 16, 2015

Address reprint request to

Woo-Suk Lee, MD, PhD

Department of Orthopaedic Surgery, Gangnam Severance Hospital, 211 Eonju-ro, Gangnam-gu, Seoul 06273, Korea

TEL: +82-2-2019-3417 **FAX:** +82-2-573-5393

E-mail: wsleeos@yuhs.ac

This is an Open Access article distributed under the terms of the Creative Commons Attribution Non-Commercial License (<http://creativecommons.org/licenses/by-nc/4.0>) which permits unrestricted non-commercial use, distribution, and reproduction in any medium, provided the original work is properly cited.

resorbs as time passes after implantation¹⁸⁻²¹).

There are few long-term clinical studies that report more than 20 years of follow-up about HA-coated acetabular cup, and the mechanisms of failure remain uncertain.

The purpose of this study was to report the long-term outcome and the failure mechanism of cementless THA using HA-coated acetabular cup.

MATERIALS AND METHODS

We obtained the approval from institutional review board of Yonsei University College of Medicine to search surgical database of our institution to identify cases for the current study. From January 1992 to May 1994, 123 consecutive primary cementless THAs using the HA-coated acetabular cup (Atoll[®]; Landos, Villeurbanne, France) were performed by one of the authors. Twenty-two hips over 65 years old in index operation were not included in this study. Thirty-five hips were not included because of follow-up loss or incomplete radiographic records. Consequently, 66 hips in 58 patients were included in this study and reviewed retrospectively. The preoperative diagnosis was osteonecrosis of the femoral head in 52 hips (78.8%); femoral neck fracture in 7 hips (10.6%); secondary osteoarthritis in 5 hips (7.6%); and fused hip in 2 hips (3.0%). There were 44 males and 22 females. The patients' age ranged from 20 to 65 years at the time of index operation (average 43 years). The mean height was 164 cm (140-182 cm) and the mean weight was 62 kg (49-82 kg). The mean body mass index (BMI) was 23.1 kg/m² (18.6-28.7 kg/m²). The average duration of follow-up was 18.3 years (10.4-23.6 years) (Table 1).

The acetabular cup was a titanium-alloy hemispherical prosthesis and it had smooth surface coated with HA.

Multiple ports within the hemisphere allowed of fixation with titanium-alloy screws. A conventional PE liner and 28 mm chrome-cobalt head were used for articulation in all cases. The femoral stem is an anatomical titanium-alloy prosthesis (Euroform[®] anatomical femoral prosthesis; Landos).

All procedures were performed by standard posterolateral approach. The acetabular component was inserted using press-fit technique; the diameter of the implant was 1-2 mm larger than the diameter of the last reamer used in preparation of the acetabular bed. Additionally, 2 or 3 screws were inserted in superolateral or superoposterior screw holes. The femoral stem was also inserted using press-fit technique without cement. The range of motion was checked in the operation field and the wound was closed with suction drain. The patients were allowed weight bearing on the affected limb as tolerated, and they generally used 2 crutches for the first 6 weeks after the operation.

All patients were requested to visit at the hospital at 6 weeks, 3, 6, and 12 months postoperatively and yearly thereafter, according to a predetermined protocol. Clinical and radiographic assessments were done at each visit. Clinical assessment was done using Harris hip score and it is determined by an individual other than the operating surgeon²². Standardized radiographs including anteroposterior and lateral hip radiographs were obtained at each follow-up.

Each acetabular component was evaluated for the presence and progression of radiolucent lines and osteolysis at the bone-implant interface according to DeLee and Charnley²³. A continuous radiolucent line above 2 mm in width at the bone-implant interface was accepted as radiographic evidence of impending failure according to the criteria of Dorr et al²⁴. Evidence of acetabular migration was measured on serial radiographs according to Massin's criteria²⁵. Acetabular migration was considered as movement >2 mm in the horizontal or vertical directions and change of inclination angle >5°. The acetabular cup loosening was defined if migration could be demonstrated. Osteolysis was defined as a localized or cystic-like scalloped radiolucent lesion adjacent to the prostheses and distinguished from bone resorption by stress-shielding in the serial radiographs. The most recent follow-up radiograph and the one taken shortly after index operation were examined to determine PE wear by the modified technique of Livermore et al²⁶.

Table 1. Patients' Demographics

Variable	Value
Age (yr)	43 (20-65)
Sex (%)	
Male	44 (66.7)
Female	22 (33.3)
Height (cm)	164 (140-182)
Weight (kg)	62 (49-82)
Body mass index (kg/m ²)	23.1 (18.6-28.7)
Follow-up (yr)	18.3 (10.4-23.6)

Values are shown as mean (range) or number (%).

Statistical analysis was performed using the SPSS software (version 18.0; SPSS Inc, Chicago, IL, USA). The survival analysis was performed by the Kaplan-Meier method. We defined end point as any failure that required a reoperation of acetabular component due to progressive osteolysis, PE wear or loosening.

RESULTS

The mean Harris hip score was 54.7 (range, 0-77) preoperatively, and it was 94.1 (range, 66-100) at the final follow-up. In the patients undergoing reoperation, the mean Harris hip score just before the reoperation was 81.8 (range, 47-100).

Six hips (9.1%) had a radiolucent line in DeLee and Charnley zone 1, 7 hips (10.6%) in zone 2, and 10 hips (15.2%) in zone 3. Five hips (7.6%) had a radiolucent

line in all three zones: less than 2 mm at all zones. Forty-seven hips (71.2%) showed evidence of acetabular osteolysis. With regard to the location of osteolysis, 28 hips (42.4%) was in zone 1, 33 hips (50.0%) in zone 2, and 19 hips (28.8%) in zone 3. For the extent of osteolytic lesions, 14 hips (21.2%) had an osteolytic lesion in two zones and 11 hips (16.7%) in three zones. PE wear was measurable on the most recent anteroposterior radiographs. The mean linear PE wear was 0.29 mm/year (range, 0.07-0.75 mm/year) in all cases. In cases requiring reoperation, the mean linear PE wear was 0.34 mm/year (range, 0.14-0.75 mm/year).

Two hips required circumferential wiring due to a calcar crack, but were healed without subsidence of the stem. One hip had event of dislocation at postoperative 3 months, and there was no more dislocation in further follow-up. Heterotopic bone formation was observed in

Table 2. Etiology of Failure Requiring Reoperation

Etiology	Reoperation	Re-reoperation	Number of the hip
Acetabular osteolysis			21 (31.8%)
	Cup revision		11
	Curettage and bone graft		10
		Cup revision	7
Cup loosening			18 (27.3%)
	Cup revision		15
	Follow-up loss		3

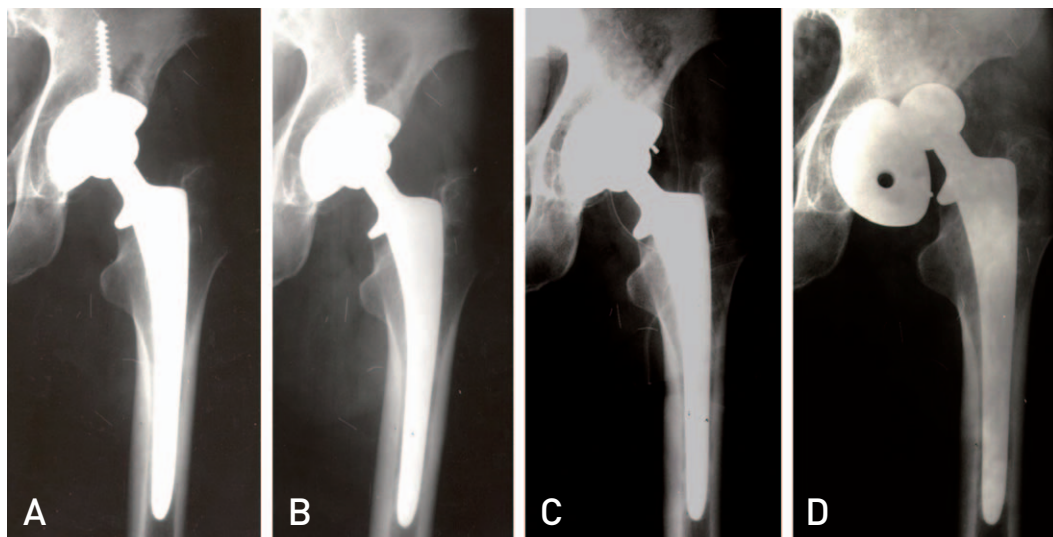


Fig. 1. (A) Radiograph of a 36 year old patient at 4 years of follow-up. A focal acetabular osteolysis was seen in zone 1. (B) The osteolysis was progressive at 6 years of follow-up. (C) Curettage and allobone grafting was done for progressive acetabular osteolysis. The polyethylene liner was changed and screws were removed. (D) Radiograph shows that the acetabular cup has moved to a more vertical position at 4 months after the reoperation.

6 hips (9.1%), assessed by Brooker's criteria²⁷, but anyone had pain or showed limitation of motion.

Thirty-nine hips (59.1%) defined as a failure that required a reoperation of acetabular component for any

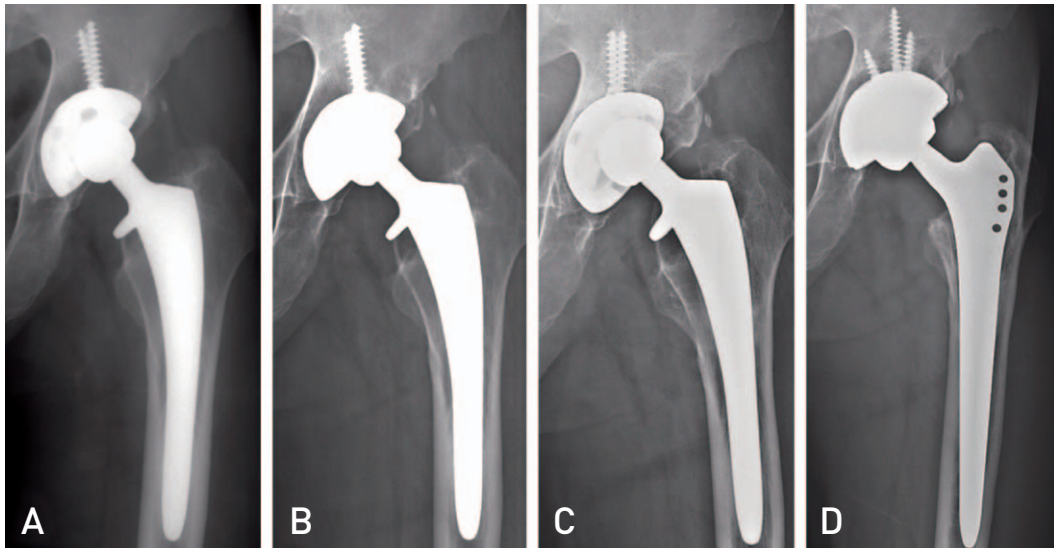


Fig. 2. (A) Radiograph of a 51 year old patient at 10 years of follow-up. (B) A focal acetabular osteolysis was seen in zone 1 at 13 years of follow-up. (C) Progression of the osteolysis and cup migration were seen at 19 years of follow-up. (D) Revision total hip arthroplasty was performed.

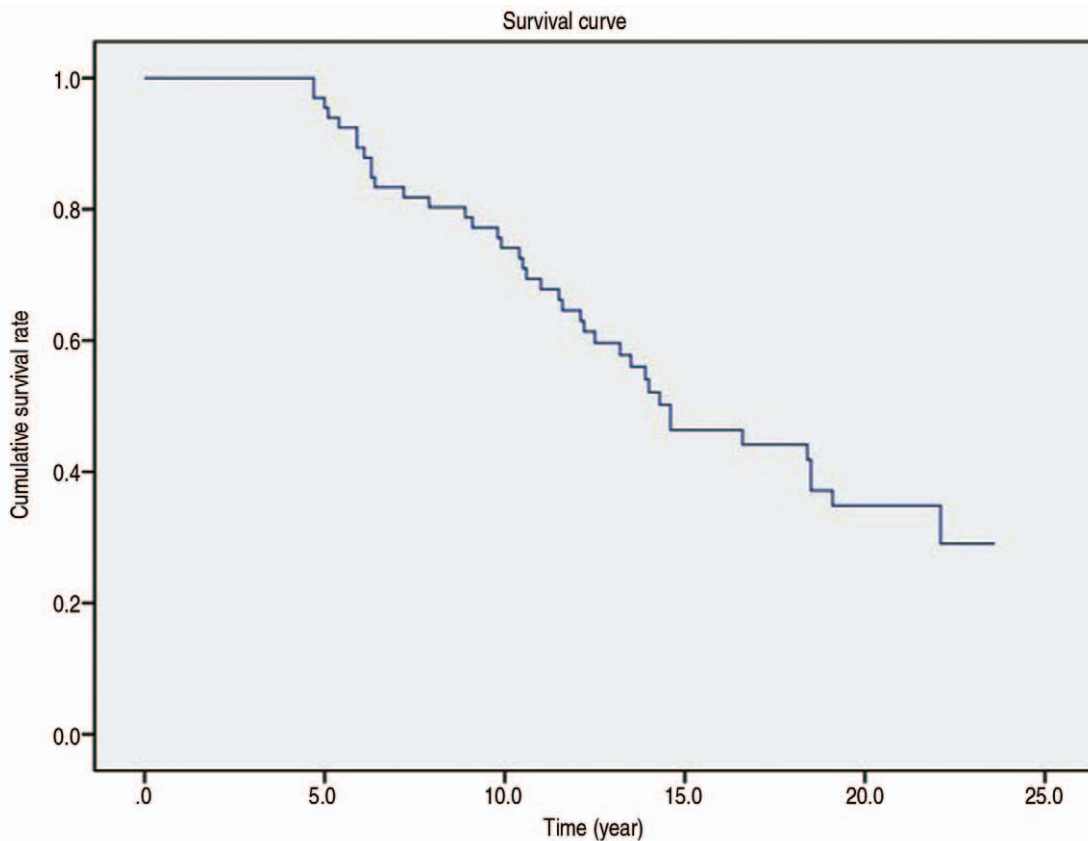


Fig. 3. Kaplan-Meier survivorship curve of the hydroxyapatite-coated acetabular cup. End-point criteria: any failure that required a reoperation of acetabular component.

reason. Acetabular cup loosening was implicated in 18 hips (27.3%) radiographically. Fifteen cups (22.7%) were exchanged and 3 patients were lost at the follow-up (Table 2). Reoperation was performed in 21 hips (31.8%) for progressive osteolysis and PE wear. Eleven cups (16.7%) were exchanged because loosening was confirmed at operation field. Ten hips (15.2%) were performed only curettage and allograft without cup exchange because there was no evidence of loosening. But out of these cases, 7 hips (10.6%) required reoperation due to delayed cup migration after reoperation (Fig. 1). Finally, 33 cups of 66 hips (50.0%) were exchanged because of loose cup (Fig. 2). The Kaplan-Meier method showed the survival rate of the acetabular cup to be 97.0% at 5 years, 74.1% at 10 years, 46.3% at 15 years and 34.8% at 20 years for any failure that required a reoperation of acetabular component (Fig. 3).

DISCUSSION

The survival rate of the smooth HA-coated press-fit acetabular cup decreased dramatically from 97.0% at 5 years to 46.3% at 15 years in our study (Fig. 3). The results are similar to other series of reports that the smooth HA-coated acetabular cup usually failed^{7,14}. The effect of HA coating on long-term bone ongrowth is not known. However, retrieved cup studies or animal experiments indicated that the coated HA was resorbs as time passes and the loss of HA could be caused by several mechanisms, such as osteoclast activity during bone remodeling, abrasion, chemical dissolution or

delamination¹⁸⁻²¹.

On radiographic review of our cases, it appears that both mechanical and biological factors were important in the development of acetabular cup loosening as the failure mechanisms of HA-coated prostheses. In the cases of early acetabular loosening within ten years, radiographs showed radiolucent line less than 1 mm before migration of cup. And these patients have experienced sudden pain suggesting cup migration as the ultimate failure mechanism. In retrieved cups at revision surgery, HA coating was limited on small portion on smooth surface of cups and the extensive loss was occurred on cup-HA junction (Fig. 4). This finding is different to porous coated cups. In the porous coated cup, radiolucent line more than 2 mm in all zones was evidence of cup loosening. This means that HA-coated cup loosening could abruptly occurred by mechanical force on weak bone-implant integration. In addition, abrasion by HA particles separated from the surface of cup could lead to increased wear of the PE liner, periprosthetic osteolysis and early loosening. This mechanism might be responsible for the inferior survival of HA-coated cup seen in other studies¹⁵⁻²⁰.

A great number of studies have reported excellent long-term survival about the HA-coated stems^{7,11,14}. For the femoral component, focal periprosthetic osteolysis could be overcome because the cone-shaped geometry of the proximal femur might encourage osteointegration. However, the acetabular geometry is hemispherical shape and it is known to have little resistance to mechanical loads and shear force¹⁸⁻²⁰. Ten hips were performed only curettage and allograft during



Fig. 4. The acetabular cup, which was retrieved at 4 years after index operation, showed extensive loss of hydroxyapatite coating.

reoperation because there was no evidence of loosening. However, 7 hips out of these had re-reoperation for delayed cup migration, especially in the cases of removal of screws. Because the fixation was not enough to stabilize the cup into the bone, the acetabular cup might depend solely on the screws to resist the shear stress^{28,29}. This means that the stability of HA-coated cup in vivo has been incomplete.

Our cases of late loosening over ten years might be associated with development of osteolysis (Fig. 2). This pattern was similar to porous coated cup. In this study, acetabular osteolysis was seen in 47 hips (71.2%). In Blacha's study¹⁵ about 65 hips, he observed acetabular osteolysis in 18 hips (27.7%) and 15 hips (23.1%) were revised because of loosening or progressive osteolysis. The report showed the 9-year survival was only 59%. Several authors have raised concerns regarding the high frequency of acetabular osteolysis^{15,17}. In contrast, Oosterbos et al.³⁰ reported 10-year survival rates in excess of 95% with the ABG I prosthesis. Baker et al.³¹ demonstrated that only 17% of hips in their series of 69 hips with ABG I prostheses had shown acetabular osteolysis at a mean of 15 years. In our series, the acetabular osteolysis occurred less in patients with long-term survival. It is not clear why frequency of acetabular osteolysis varies so widely among these series. In reports showing excellent results, the wear rate and the degree of osteolysis was relatively low. Because many factors including mechanical and biological elements could be cause of periprosthetic osteolysis, the difference might be related to the difference of patient's factor, surgical procedure, and design of prosthesis. A PE wear rate as threshold of osteolysis is known 0.1 mm/year³², and numerous authors have reported acetabular PE wear rates between 0.24 and 0.32 mm/year in studies suggesting the failure of HA coated cup¹⁵⁻¹⁷. The mean annual PE wear rate was 0.29 mm/year in our study, and it might also have contributed to the high frequency of osteolysis.

This study has several limitations. First, it is a retrospective study which is dependent on past documentation completely. Second, the sample size was relatively small and the rate of follow-up loss was relatively high. Third, there was no control group for direct comparison. Nevertheless, the strengths of the study include a long-term follow-up over 20 years and consistent surgical method which was performed by one surgeon.

CONCLUSION

We conclude that the long-term survival rate of THA using HA coated acetabular cup was unsatisfactory, and it was attributed to vulnerable property of HA coating and osteolysis.

REFERENCES

1. Capello WN, D'Antonio JA, Manley MT, Feinberg JR. *Hydroxyapatite in total hip arthroplasty. Clinical results and critical issues. Clin Orthop Relat Res. 1998;(355): 200-11.*
2. Geesink RG, de Groot K, Klein CP. *Chemical implant fixation using hydroxyl-apatite coatings. The development of a human total hip prosthesis for chemical fixation to bone using hydroxyl-apatite coatings on titanium substrates. Clin Orthop Relat Res. 1987;(225):147-70.*
3. Rossi P, Sibelli P, Fumero S, Crua E. *Short-term results of hydroxyapatite-coated primary total hip arthroplasty. Clin Orthop Relat Res. 1995;(310):98-102.*
4. Tonino AJ, Rahmy AI. *The hydroxyapatite-ABG hip system: 5- to 7-year results from an international multicentre study. The International ABG Study Group. J Arthroplasty. 2000;15:274-82.*
5. Castoldi F, Rossi R, La Russa M, Sibelli P, Rossi P, Ranawat AS. *Ten-year survivorship of the Anatomique Benoist Girard I total hip arthroplasty. J Arthroplasty. 2007;22:363-8.*
6. Rogers A, Kulkarni R, Downes EM. *The ABG hydroxyapatite-coated hip prosthesis: one hundred consecutive operations with average 6-year follow-up. J Arthroplasty. 2003;18: 619-25.*
7. Bidar R, Kouyoumdjian P, Munini E, Asencio G. *Long-term results of the ABG-I hydroxyapatite coated total hip arthroplasty: analysis of 111 cases with a minimum follow-up of 10 years. Orthop Traumatol Surg Res. 2009;95:579-87.*
8. Chung YY, Ki SC, So KY, Kim DH, Park KH, Lee YS. *High revision rate of hydroxyapatite-coated ABG-I prosthesis. J Orthop Sci. 2009;14:543-7.*
9. Coathup MJ, Blackburn J, Goodship AE, Cunningham JL, Smith T, Blunn GW. *Role of hydroxyapatite coating in resisting wear particle migration and osteolysis around acetabular components. Biomaterials. 2005;26:4161-9.*
10. Kim SY, Kim DH, Kim YG, Oh CW, Ihn JC. *Early failure of hemispheric hydroxyapatite-coated acetabular cups. Clin Orthop Relat Res. 2006;446:233-8.*
11. Lai KA, Shen WJ, Chen CH, Yang CY, Hu WP, Chang GL. *Failure of hydroxyapatite-coated acetabular cups. Ten-year follow-up of 85 Landos Atoll arthroplasties. J Bone Joint Surg Br. 2002;84:641-6.*
12. Lazarinis S, Kärrholm J, Hailer NP. *Increased risk of revision of acetabular cups coated with hydroxyapatite. Acta Orthop. 2010;81:53-9.*
13. Paulsen A, Pedersen AB, Johnsen SP, Riis A, Lucht U, Overgaard S. *Effect of hydroxyapatite coating on risk of*

- revision after primary total hip arthroplasty in younger patients: findings from the Danish Hip Arthroplasty Registry. *Acta Orthop.* 2007;78:622-8.
14. Stilling M, Rahbek O, Søballe K. *Inferior survival of hydroxyapatite versus titanium-coated cups at 15 years.* *Clin Orthop Relat Res.* 2009;467:2872-9.
 15. Blacha J. *High osteolysis and revision rate with the hydroxyapatite-coated ABG hip prostheses: 65 hips in 56 young patients followed for 5-9 years.* *Acta Orthop Scand.* 2004;75:276-82.
 16. Delank KS, Drees P, Menzel N, Hansen T, Duschner H, Eckardt A. *Increased polyethylene wear after cementless ABG I total hip arthroplasty.* *Arch Orthop Trauma Surg.* 2006;126:509-16.
 17. Duffy P, Sher JL, Partington PF. *Premature wear and osteolysis in an HA-coated, uncemented total hip arthroplasty.* *J Bone Joint Surg Br.* 2004;86:34-8.
 18. Røkkum M, Reigstad A, Johansson CB. *HA particles can be released from well-fixed HA-coated stems: histopathology of biopsies from 20 hips 2-8 years after implantation.* *Acta Orthop Scand.* 2002;73:298-306.
 19. Røkkum M, Reigstad A, Johansson CB, Albrektsson T. *Tissue reactions adjacent to well-fixed hydroxyapatite-coated acetabular cups. Histopathology of ten specimens retrieved at reoperation after 0.3 to 5.8 years.* *J Bone Joint Surg Br.* 2003;85:440-7.
 20. Tonino A, Oosterbos C, Rahmy A, Thèrin M, Doyle C. *Hydroxyapatite-coated acetabular components. Histological and histomorphometric analysis of six cups retrieved at autopsy between three and seven years after successful implantation.* *J Bone Joint Surg Am.* 2001;83-A:817-25.
 21. Tonino AJ, van der Wal BC, Heyligers IC, Grimm B. *Bone remodeling and hydroxyapatite resorption in coated primary hip prostheses.* *Clin Orthop Relat Res.* 2009;467:478-84.
 22. Harris WH. *Traumatic arthritis of the hip after dislocation and acetabular fractures: treatment by mold arthroplasty. An end-result study using a new method of result evaluation.* *J Bone Joint Surg Am.* 1969;51:737-55.
 23. DeLee JG, Charnley J. *Radiological demarcation of cemented sockets in total hip replacement.* *Clin Orthop Relat Res.* 1976;(121):20-32.
 24. Dorr LD, Absatz M, Gruen TA, Saberi MT, Doerzbacher JF. *Anatomic Porous Replacement hip arthroplasty: first 100 consecutive cases.* *Semin Arthroplasty.* 1990;1:77-86.
 25. Massin P, Schmidt L, Engh CA. *Evaluation of cementless acetabular component migration. An experimental study.* *J Arthroplasty.* 1989;4:245-51.
 26. Livermore J, Ilstrup D, Morrey B. *Effect of femoral head size on wear of the polyethylene acetabular component.* *J Bone Joint Surg Am.* 1990;72:518-28.
 27. Brooker AF, Bowerman JW, Robinson RA, Riley LH Jr. *Ectopic ossification following total hip replacement. Incidence and a method of classification.* *J Bone Joint Surg Am.* 1973;55:1629-32.
 28. Cheung KW, Yung SH, Wong KC, Chiu KH. *Early failure of smooth hydroxyapatite-coated press-fit acetabular cup--7 years of follow-up.* *J Arthroplasty.* 2005;20:627-31.
 29. Reikerås O, Gunderson RB. *Long-term results of HA coated threaded versus HA coated hemispheric press fit cups: 287 hips followed for 11 to 16 years.* *Arch Orthop Trauma Surg.* 2006;126:503-8.
 30. Oosterbos CJ, Rahmy AI, Tonino AJ, Witpeerd W. *High survival rate of hydroxyapatite-coated hip prostheses: 100 consecutive hips followed for 10 years.* *Acta Orthop Scand.* 2004;75:127-33.
 31. Baker PN, McMurtry IA, Chuter G, Port A, Anderson J. *THA with the ABG I prosthesis at 15 years. Excellent survival with minimal osteolysis.* *Clin Orthop Relat Res.* 2010;468:1855-61.
 32. Dumbleton JH, Manley MT. *"The lysis threshold": an erroneous and perhaps misleading concept? By Harris WH.* *J Arthroplasty.* 2003;18:537-8.