

Cadaveric Study

Ultrasound-Guided Injection of the Adductor Longus and Pectineus in a Cadaver Model

Dong-wook Rha, MD, PhD¹, Sang-Hee Lee, DDS², Hyung-Jin Lee², You-Jin Choi, BSDH², Hee-Jin Kim, DDS, PhD², and Sang Chul Lee, MD, PhD¹

From: ¹Department and Research Institute of Rehabilitation Medicine, Yonsei University College of Medicine, South Korea; ²Division in Anatomy and Developmental Biology, Department of Oral Biology, Human Identification Research Center, Yonsei University College of Dentistry, South Korea.

Address Correspondence:
Sang Chul Lee, MD, PhD,
Department and Research Institute of
Rehabilitation Medicine
Yonsei University
College of Medicine
50-1 Yonsei-ro, Seodaemun-gu, Seoul
120-752, South Korea
E-mail:
bettertomo@yuhs.ac

Disclaimer: There was no external funding in the preparation of this manuscript.

Conflict of interest: Each author certifies that he or she, or a member of his or her immediate family, has no commercial association (i.e., consultancies, stock ownership, equity interest, patent/licensing arrangements, etc.) that might pose a conflict of interest in connection with the submitted manuscript.

Manuscript received: 02-28-2015
Revised manuscript received:
04-20-2015
Accepted for publication:
04-27-2015

Free full manuscript:
www.painphysicianjournal.com

Background: The close anatomic and functional relationship between the proximal parts of the adductor longus and pectineus muscles produce considerable overlap in symptoms and signs in the inguinal region. To our knowledge, there have been no publications of ultrasound (US)-guided injection techniques into the 2 muscles.

Objective: This study sought to describe US-guided injection techniques in the proximal part of the adductor longus and pectineus muscles and to validate whether these techniques deliver injections appropriately to their target muscles in unembalmed cadavers.

Study Design: Cadaveric study.

Methods: A preliminary trial with 2 unembalmed cadavers provided information on the target sonographic structures of proximal adductor longus and pectineus muscles. Bilateral US-guided intramuscular injections in the proximal adductor longus and pectineus were performed using the remaining 5 unembalmed male cadavers. To avoid confusion of dye location, we did not inject into both the adductor longus and pectineus muscle in the same side. After injections, each specimen was dissected to evaluate the accuracy of injection.

Results: Ten injections (5 for the adductor longus muscle and 5 for the pectineus muscle) were performed targeting the proximal parts of muscles in 5 cadaveric specimens. All injections were successful and blue dye was injected accurately at the target area within the adductor longus and the pectineus muscles. No other muscles were injected unintentionally. There were no accidental penetrations and/or injuries at adjacent neurovascular structures as well.

Limitation: Despite successful injection of the proximal parts of adductor longus and pectineus, this study did not verify the usefulness of this technique in clinical practice.

Conclusions: The results of this study may play a role in the diagnosis and management of patients presenting with chronic pelvic pain syndrome and sports hernia.

Key words: Inguinal, injections, ultrasonography, pain, cadaver, pectineus, adductor, pelvis

Pain Physician 2015; 18:E1111-E1117

Inguinal pain can present a difficult therapeutic and diagnostic dilemma. The sources of pain in the inguinal region range from urologic problems to musculoskeletal abnormalities. Chronic pelvic pain syndrome (CPPS) or National Institutes of Health (NIH) category III prostatitis (nonbacterial prostatitis) is a common clinical syndrome with multiple potential etiologies including infection, autoimmunity, and

neuromuscular problems (1). No biomarkers have been validated to help guide classification and treatment for CPPS (2). For most men with CPPS referred to urologists, traditional therapeutic modalities like antibiotics, analgesics, and alpha-blockers fail to relieve symptoms, and only 17% of patients reported significantly improved symptoms (3). Some investigators have evaluated and attempted to treat

the associated muscular tenderness of CPPS, particularly painful myofascial trigger points (MTrPs) (4). Zermann et al (5) found that 88% of men with CPPS had tenderness in the myofascial area on palpation.

While MTrPs are considered one of the possible causes for CPPS, most previous studies focused on the pelvic floor muscles, such as the levator ani (6,7). However, Anderson et al (4) reported that the most prevalent pain sites were the penis (91.7% of men with CPPS) and the inguinal area (47.2% of men with CPPS); the pain may have originated from the abdominal and hip adductor muscles. Based on the anatomical proximity and our clinical experience, direct tenderness and associated inguinal pain might originate from the proximal parts of the adductor longus and/or pectineus muscles (Fig. 1).

The adductor longus muscle attaches proximally to the relatively small spot on the outer surface of the pelvis between the symphysis pubis and obturator foramen through a narrow flat tendon (2). MTrPs at the adductor longus, especially its proximal portion, may be the most common cause of inguinal pain (8). MTrPs in the adductor longus may result from sitting in a fixed position while on a prolonged driving trip, sitting for long periods in a chair with the hips acutely flexed, sitting with one thigh or leg crossed over the other knee, as well as sports activity (2).

The pectineus muscle attaches proximally to the superior ramus of the pubic bone beside the pubic tubercle. The attachment site is caudal and deep to the inguinal ligament, and medial to the pubic tubercle (9). The MTrPs in the pectineus muscle are mostly located just distal to the superior ramus of the pubis, and referred pain projects over the pectineus muscle just below the inguinal ligament and extends deep into the inguinal area (2).

Because of the close anatomic and functional relationship between the proximal parts of the adductor longus and pectineus muscles, symptoms and signs from these 2 muscles' pathology considerably overlap in the inguinal region. Trigger point injection or diagnostic local anesthetic block can assist in the accurate diagnosis of muscle-related pathology and also relieve the symptoms in affected patients. Sometimes, precise diagnostic intra-muscular injections are more important since the physical examinations lack specificity for identifying these muscles-related pains and MTrPs usually appear normal even by an advanced imaging technique like magnetic resonance imaging. When performing the injection at the inguinal area, atten-

tion is needed to avoid neurovascular injury. The large femoral neurovascular structures, superficial and deep branches of obturator nerve, and long and accessory saphenous vein run immediately adjacent to the adductor longus and pectineus muscles. Even for trigger point injection, the needle is inserted several times in various directions to provoke local twitch responses. Therefore, there are risks of injection-related vascular and neural injuries. In addition, most patients are afraid of getting an injection around their inguinal area and most physicians are reluctant to do an injection near patients' external genitalia.

Ultrasound (US) guidance has gained popularity as an effective technique to perform a variety of diagnostic and therapeutic injections throughout the musculoskeletal system due to exquisite soft tissue resolution, availability, and lack of ionizing radiation (10,11). Based on potential hazards of inserting a needle into the inguinal region, the use of US-guidance appears warranted. To our knowledge, there have been no publications of US-guided injection techniques into the proximal part of the adductor longus and pectineus muscles. Therefore, the purposes of this study were to describe US-guided injection techniques into the proximal part of the adductor longus and pectineus muscles, and to validate whether these techniques deliver injections appropriately to their target muscles using unembalmed cadavers.

METHODS

Preparation of Cadavers

Seven unembalmed male cadaveric specimens were used for this investigation. The average age \pm SD at death was 68.8 ± 6.9 years (range, 59 – 80 years). The average \pm SD body mass index (BMI) was 23.9 ± 2.0 kg/m² (range, 20.8 – 27.6). There was no evidence of previous injury or surgical procedure around the pelvis. None of the recorded causes of death were deemed to have affected the results of this study with regard to needle placement or dissection.

Preliminary Injection and Dissection

B-mode, real-time ultrasonography at 5 – 12 MHz was performed using the UGEO HM70A system (Samsung Medison, Seoul, South Korea) interfaced with a linear array transducer. An investigator (SCL) with more than 7 years experience in musculoskeletal ultrasonography carried out these procedures. All photographs and diagrams in this article are of structures viewed

from the left side of the specimen.

Based on our clinical experience, the proximal parts of the adductor longus and pectineus muscles where we frequently observed the tenderness in patients were targeted (Fig. 1). First, an expert anatomist (HJK) dissected 2 unembalmed male cadavers to identify the proximal adductor longus, pectineus, and significant neurovascular structures near the muscles in one side of the hip and pelvis. Then, in the contralateral hip and pelvis, sonographic images corresponding to the dissected structures were taken and test injections with dye were performed to localize the target structures. After injections, the anatomist dissected the inguinal area to confirm where the injected dye was located. The preliminary trial informed the sonographic structures of proximal adductor longus and pectineus muscles that should be targeted.

Injection for Accuracy and Safety Test

After preliminary injection and dissection, bilateral US-guided intramuscular injections to the proximal adductor longus and pectineus were performed using the remaining 5 unembalmed male cadavers. To avoid confusion of dye location, we did not inject in the adductor longus and pectineus muscle in the same side. After the injections, the same anatomist dissected each specimen to evaluate the accuracy of US-guided injection into the target structures.

Assessment

Through anatomical dissection, needle passage and dye location were explored to evaluate the accuracy of the injections and any unintended penetration of non-target structures. Parameters recorded for each injection were whether dye was accurately injected at the target muscle, and whether the nearby neurovascular structures including femoral neurovascular structures and obturator nerves were penetrated and/or injected.

RESULTS

Preliminary Dissection

Preliminary dissection revealed the contiguous nature of the proximal regions of the adductor longus and pectineus muscles, and the immediate adjacent location of the femoral neurovascular bundle (Fig. 2). The lateral border of the adductor longus formed the medial border of the femoral triangle, and the pectineus muscle formed the floor of the femoral triangle accompanying the femoral nerve, artery, and vein. The

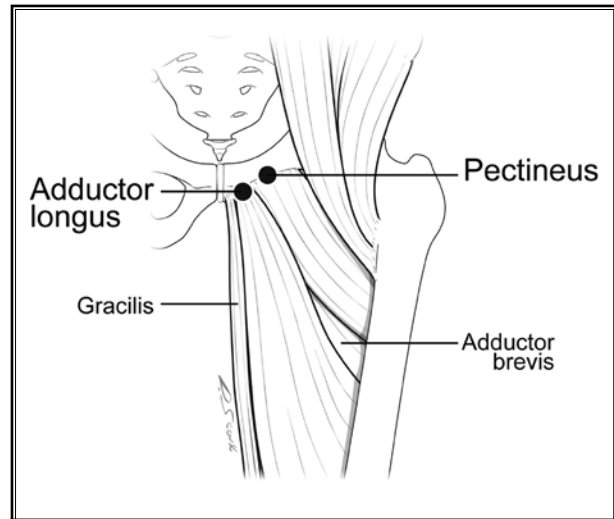


Fig. 1. Illustration of the target area of the adductor longus and pectineus. The black circle denotes the target area for injection.

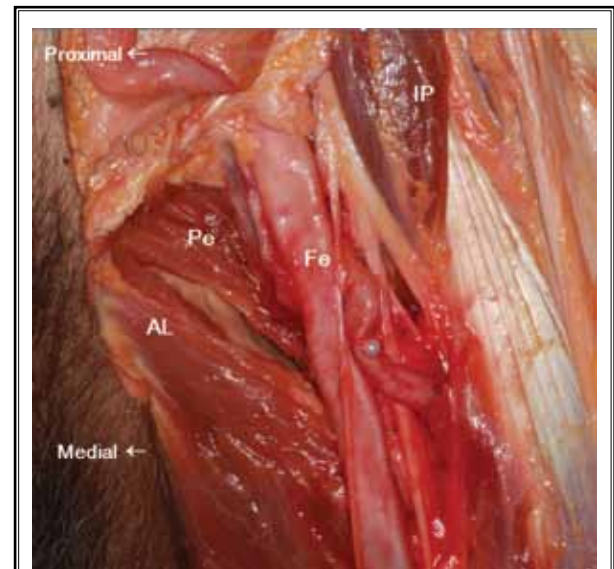


Fig. 2. Neurovascular structures near the proximal parts of the adductor longus and pectineus. Abbreviations are: AL, adductor longus; Pe, pectineus; Fe, femoral neurovascular structures; IP, iliopsoas.

preliminary dye injections trials identified the proper probe position for the corresponding US images for the proximal parts of targeted muscles. Ten injections (5 for adductor the longus muscle and 5 for the pectineus muscle) were performed targeting the proximal parts of muscles in 5 cadavers.

Ultrasound-guided Injection of the Adductor Longus Muscle

The cadavers were positioned supine with both hips externally rotated and slightly abducted. For the adductor longus muscle, the superior ramus of the pubis was manually palpated and the probe was placed transversely over the hip adductor muscle belly distal from the superior ramus. After identifying the adductor longus on an US image, the US probe was rotated longitudinally to obtain a long-axis view and enable discernment of 3 muscle layers in this plane (Fig. 3a). The adductor longus muscle was located most superficially. In real-time, the probe was placed in close proximity to the proximal target site and a 3.8 cm, 19-gauge needle was advanced under direct US guidance using an in-plane approach (Fig. 3b). When the needle was posi-

tioned in the targeted muscle, 0.5 mL of blue dye was injected. All 5 adductor longus muscles were injected.

Ultrasound-guided Injection of the Pectineus Muscle

At the superior ramus of the pubis, the pectineus was located lateral to the adductor longus. It was difficult to discriminate between the adductor longus and pectineus muscles proximally due to their contiguity. Therefore, we could differentiate them by scanning 2 muscles transversely at a more distal portion and tracing the pectineus muscle proximally. The injection procedure for the pectineus muscle was similar to the aforementioned procedure for the adductor longus muscle (Fig. 4). Dye injection was done in the same manner as described above for 5 pectineus muscles.

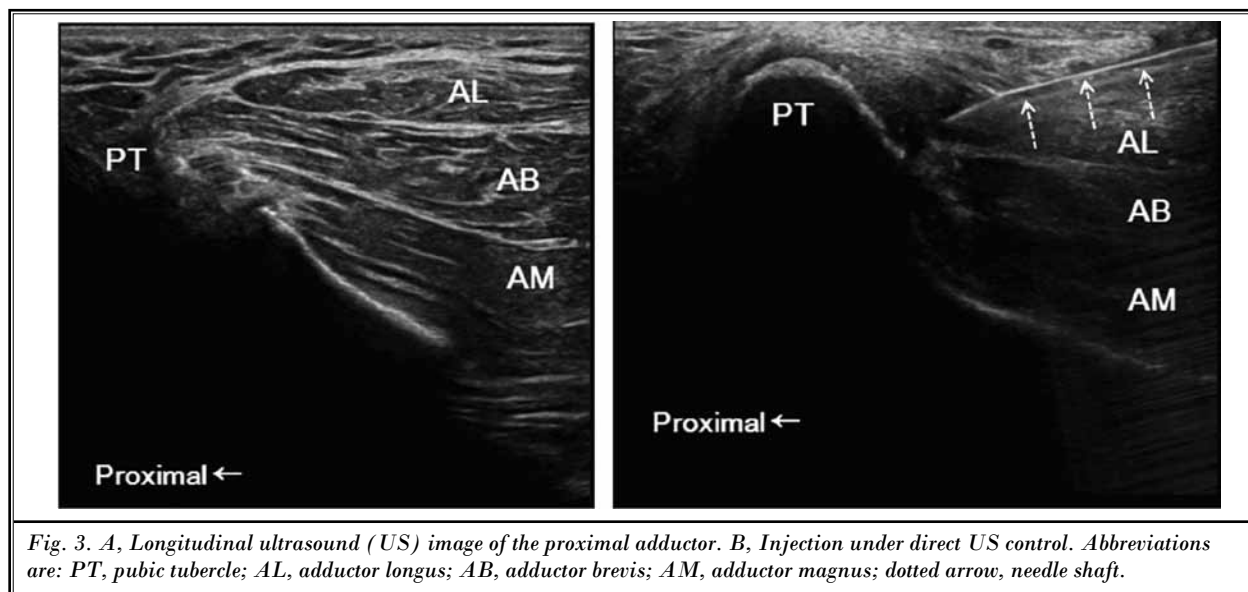


Fig. 3. A, Longitudinal ultrasound (US) image of the proximal adductor. B, Injection under direct US control. Abbreviations are: PT, pubic tubercle; AL, adductor longus; AB, adductor brevis; AM, adductor magnus; dotted arrow, needle shaft.

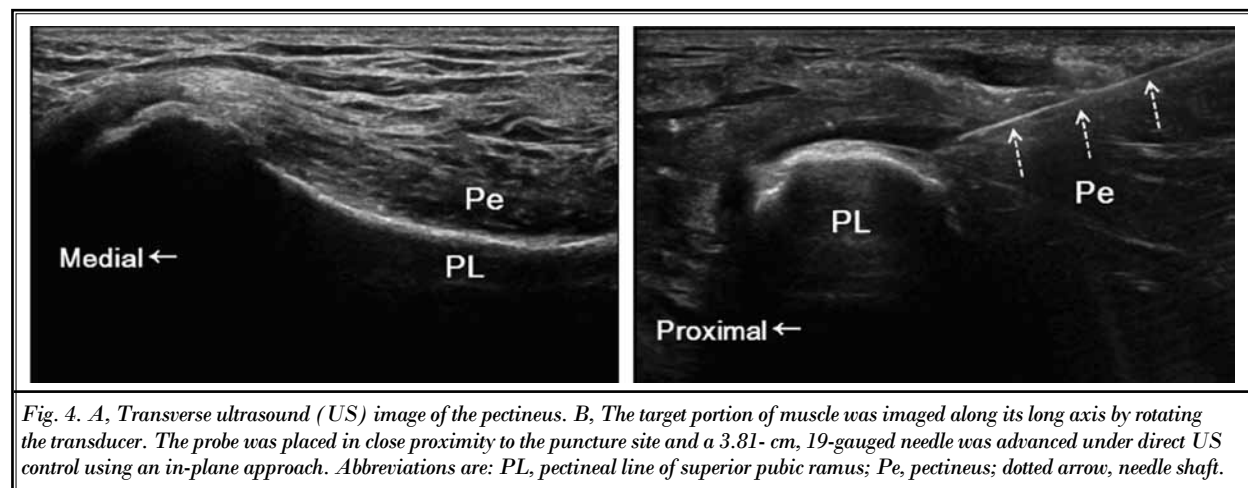
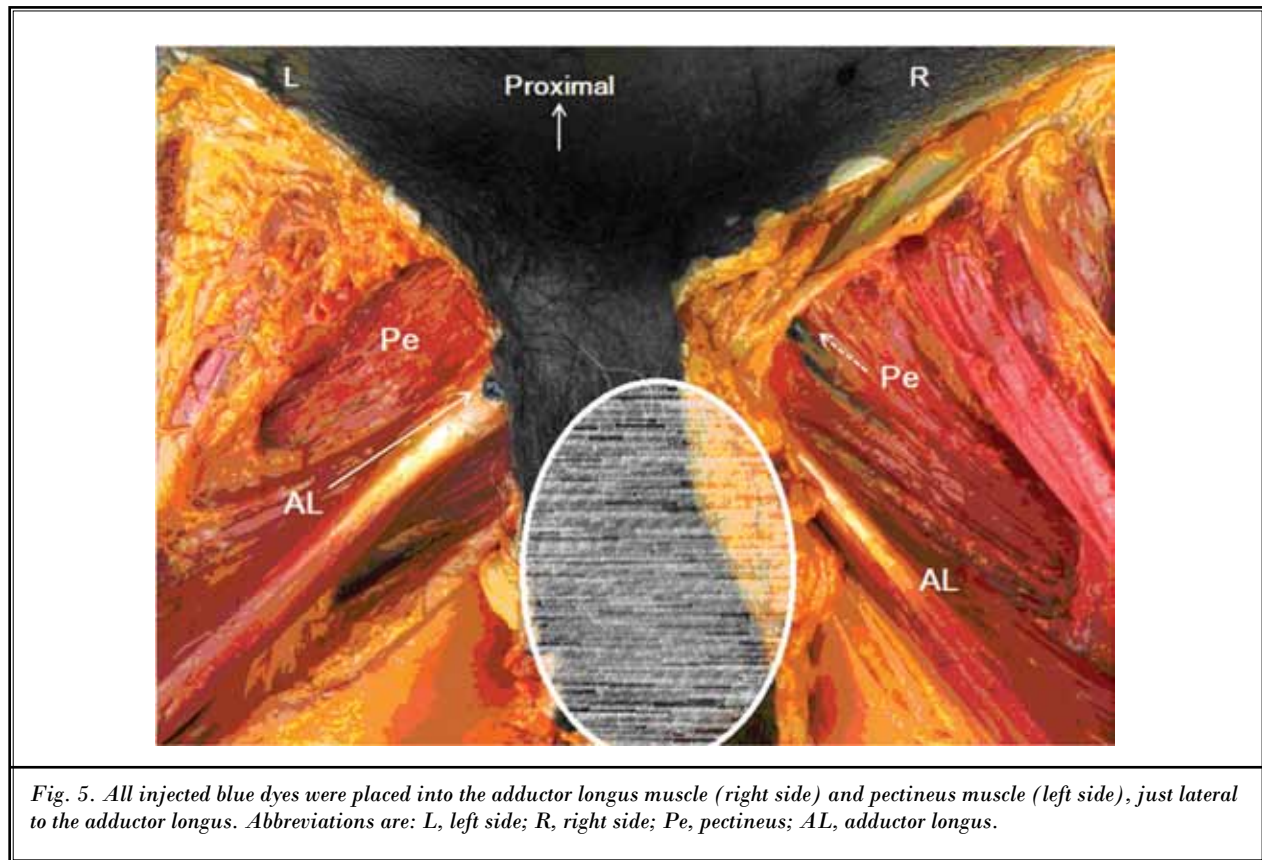


Fig. 4. A, Transverse ultrasound (US) image of the pectineus. B, The target portion of muscle was imaged along its long axis by rotating the transducer. The probe was placed in close proximity to the puncture site and a 3.81-cm, 19-gauged needle was advanced under direct US control using an in-plane approach. Abbreviations are: PL, pectineal line of superior pubic ramus; Pe, pectineus; dotted arrow, needle shaft.



All injections were successful and blue dye was injected accurately at the target area within the adductor longus and the pectineus muscles (Fig. 5). No other muscles were injected unintentionally. There were no accidental penetrations at adjacent neurovascular structures.

Discussion

The evaluation and management of patients presenting with inguinal pain is challenging because of the complex anatomy, broad differential diagnoses, and lack of specific physical examination findings. A clue that led us to believe the proximal part of the adductor and pectineus muscles might be involved or responsible for localized pain in patients with CPPS was the tenderness noted upon the application of pressure on these muscles near the suprapubic ramus (12,13). One of the possible causes of tenderness in these muscles is MTrP. Repetitive microtrauma by overuse injury, prolonged sitting, bad posture, or unnatural gait may give rise to MTrPs on the adductor longus and pectineus (2,9). Anatomical structures supporting both thigh and pelvis work together as a functional unit (14). In this function-

al unit, the adductor longus and pectineus participate as stabilizers of the hip joint (15). Therefore, it seems possible that the adductor longus and the pectineus can be a primary or secondary cause of inguinal pain, and that these muscle dysfunctions might be often misdiagnosed as a CPPS.

The proximal parts of the adductor longus and pectineus are also important as a cause of sports-related hernia. Inguinal pain related with sports activity is a common complaint with diverse causes including musculoskeletal problems (16). Especially, sports hernia is an activity-related lower abdominal and proximal adductor-related pain seen in athletes (17). The term sports hernia is a misnomer, because it is not a true hernia but a weakness in or injury to the pelvic floor caused by the weak flexion of the abdomen and the strong adduction of the hip (18). Up to 40% of patients diagnosed with sports hernias have torn adductor muscles (19). Weakness in the rectus insertions may lead to an overcompensation of the adductor muscles that in turn can lead to a compartment-like syndrome as the pelvis tilts more anteriorly and compresses the adductor compartment (20). Hence, US-guided injection might also

be used for diagnostic and therapeutic purposes in the adductor longus and pectineus-originated pain in men and women with suspected sports hernia.

The purpose of this study was to demonstrate the feasibility of US-guided injection into the proximal part of the adductor longus and pectineus muscles by observing whether the dye was injected accurately into the target regions in fresh cadavers. Our results support the hypothesis that the proximal adductor longus and pectineus can be injected precisely and safely under US guidance. All injections delivered dye to the primary target portions in both adductor longus and pectineus muscles. Any adjacent neurovascular structures were not damaged and injected dye did not overflow into nearby muscles or other structures with clinical importance.

To our knowledge, this is the first study to evaluate the accuracy of US-guided needle insertion into the proximal part of the adductor longus and pectineus muscles using cadaver dissection. To maximize the therapeutic effect of trigger point injection for myofascial pain syndrome, needling the proper pathologic muscle and eliciting the local twitch responses are very important. To stretch the muscle effectively after trigger point injection, it is also important to know which muscle is causing the pain (9). The action of adductor longus and pectineus muscles is same as adducting and flexing the thigh at the hip joint, and tilting the pelvis anteriorly at the hip joint. Therefore, the typical referred-pain pattern and local twitch-response elicited by snapping could not be differentiated clearly between these 2 muscles. A precise palpation of MTrPs in the proximal part of the adductor and pectineus muscles is also difficult because of their contiguity. Additionally, the adductor longus muscle overlaps other hip adductor muscles (brevis and magnus) and tapers to a pubic origin, and the pectineus muscle is too thin to perform precise intramuscular injection. This makes it difficult to inject precisely to the proximal adductor longus muscle (Fig. 3a). US-guided intra-muscular injection improves therapeutic efficacy compared with blind

injection, especially for injections into deeply located musculature (12,21). Color Doppler imaging also can help to avoid neurovascular structures in patients, since these muscles are closely located to the femoral neurovascular bundle. In our clinical experience, US helps to reassure the patient because most patients are afraid of the injection near the inguinal area. The tendinous part of proximal origin is longer and thicker in adductor longus muscle compared to pectineus muscle and difficult to discriminate from the muscular part by palpation. US-guidance can help to demarcate the muscular part from tendinous part and perform the precise intramuscular injection (Fig. 5).

There are some limitations to our study. First, the primary focus of this investigation was technical and not clinical. Despite successful injection of the proximal parts of adductor longus and pectineus, this study did not verify the usefulness of this technique in clinical practice. Further studies are needed to evaluate the therapeutic efficacy of injection into these muscles using this US-guided approach in managing muscle-originated inguinal pain. Second, we defined complications of the injection as needle passage through unintended neurovascular structures. Although there were no complications, we failed to identify all branches of the obturator and femoral nerves, especially intra-muscular portions, during dissection. Third, a relatively small number of cadaveric specimens within a narrow range of body mass indexes were used. The ability to execute injections of these muscles might be influenced by both a patients' body habitus and equipment.

CONCLUSION

The new US-guided injection technique allowed accurate insertion of a needle into the proximal parts of the adductor longus and pectineus muscles in adult male cadavers. This US-guided method is a more precise approach to these muscles and differentiates conditions or symptoms caused by other structures. The results may play a role in the diagnosis and management of patients presenting with CPPS and sports hernia.

REFERENCES

1. Schaeffer AJ. Clinical practice. Chronic prostatitis and the chronic pelvic pain syndrome. *N Engl J Med* 2006; 355:1690-1698.
2. Travell J, Simons D. *Myofascial Pain and Dysfunction: The Trigger Point Manual*. 2nd ed., Vol. 2. Lippincott Williams & Wilkins, Philadelphia, 1998.
3. Schaeffer AJ, Landis JR, Knauss JS, ProPERT KJ, Alexander RB, Litwin MS, Nickel JC, O'Leary MP, Nadler RB, Pontari MA, Shoskes DA, Zeitlin SI, Fowler JE Jr, Mazurick CA, Kishel L, Kusek JW, Nyberg LM; Chronic Prostatitis Collaborative Research Network Group. Demographic and clinical characteristics of men with chronic prostatitis: The National Institutes of Health Chronic Prostatitis Cohort Study. *J Urol* 2002; 168:593-598.
4. Anderson RU, Sawyer T, Wise D, Morey A, Nathanson BH. Painful myofascial trigger points and pain sites in men with chronic prostatitis/chronic pelvic pain syndrome. *J Urol* 2009; 182:2753-2758.
5. Zermann DH, Ishigooka M, Doggweiler-Wiygul R, Schubert J, Schmidt RA. The male chronic pelvic pain syndrome. *World J Urol* 2001; 19:173-179.
6. Shoskes DA, Berger R, Elmi A, Landis JR, ProPERT KJ, Zeitlin S; Chronic Prostatitis Collaborative Research Network Study Group. Muscle tenderness in men with chronic prostatitis/chronic pelvic pain syndrome: The Chronic Prostatitis Cohort Study. *J Urol* 2008; 179:556-560.
7. Clemens JQ, Nadler RB, Schaeffer AJ, Belani J, Albaugh J, Bushman W. Biofeedback, pelvic floor reeducation, and bladder training for male chronic pelvic pain syndrome. *Urology* 2000; 56:951-955.
8. Travell J, Rinzler SH. The myofascial genesis of pain. *Postgrad Med* 1952; 11:425-434.
9. Muscolino JE. *The Muscle and Bone Palpation Manual with Trigger Points, Referral Patterns, and Stretching*. Mosby, St. Louis, 2009.
10. Peng PW, Tumber PS. Ultrasound-guided interventional procedures for patients with chronic pelvic pain: A description of techniques and review of literature. *Pain Physician* 2008; 11:215-224.
11. Smith J, Hurdle MF, Lockett AJ, Wisniewski SJ. Ultrasound-guided piriformis injection: Technique description and verification. *Arch Phys Med Rehabil* 2006; 12:1664-1667.
12. Kim DS, Jeong TY, Kim YK, Chang WH, Yoon JG, Lee SC. Usefulness of a myofascial trigger point injection for groin pain in patients with CP/CPPS: A pilot study. *Arch Phys Med Rehabil* 2013; 94:930-936.
13. Lee SC, Rha DW, Kim HJ, Yang H, Lee SH. Ultrasound-guided injection of the intra-pelvic portion of the obturator internus in a cadaver model. *Reg Anesth Pain Med* 2014; 39:347-350.
14. Kim SH, Kim DH, Yoon DM, Yoon KB. Clinical effectiveness of the obturator externus muscle injection in chronic pelvic pain patients. *Pain Pract* 2015; 15:40-46.
15. Solomon LB, Lee YC, Callary SA, Beck M, Howie DW. Anatomy of piriformis, obturator internus and obturator externus: Implications for the posterior surgical approach to the hip. *J Bone Joint Surg Br* 2010; 92:1317-1324.
16. Hackney RG. The sports hernia: A cause of chronic groin pain. *Br J Sports Med* 1993; 27:58-62.
17. Larson CM. Sports hernia/athletic pubalgia: Evaluation and management. *Sports Health* 2014; 6:139-144.
18. Diesen DL, Pappas TN. Sports hernias. *Adv Surg* 2007; 41:177-187.
19. Gilmore O. Gilmore's groin: Ten years experience of groin disruption—a previously unsolved problem in sportsmen. *Sports Med Soft Tissue Trauma* 1991; 3:12-14.
20. Meyers WC, Foley DP, Garrett WE, Lohnes JH, Mandlebaum BR. Management of severe lower abdominal or inguinal pain in high-performance athletes. PAIN (Performing Athletes with Abdominal or Inguinal Neuromuscular Pain Study Group). *Am J Sports Med* 2000; 28:2-8.
21. Rha DW, Shin JC, Kim YK, Jung JH, Kim YU, Lee SC. Detecting local twitch responses of myofascial trigger points in the lower-back muscles using ultrasonography. *Arch Phys Med Rehabil* 2011; 92:1576-1580.

