

A randomized comparison of volume- and pressure-controlled ventilation in children with the i-gel

Effects on peak inspiratory pressure, oropharyngeal leak pressure, and gastric insufflation

Jin Ha Park, MD, Ji Young Kim, MD, PhD, Kyoungun Park, MD, Hae Keum Kil, MD*

Abstract

Background: The i-gel provides good airway sealing but gastric insufflation may occur when peak inspiratory pressure (PIP) exceeds the sealing pressure of the i-gel without a gastric tube. Pressure-controlled ventilation (PCV) provides lower PIP compared with volume-controlled ventilation (VCV) and low PIP may reduce the incidence of gastric insufflation in children during positive pressure ventilation. This study was designed to evaluate PIP, oropharyngeal leak pressure, and gastric insufflation during VCV or PCV in children undergoing general anesthesia with i-gel without a gastric tube in situ.

Methods: A prospective, randomized-controlled study was conducted. Thirty-four children, aged 6 to 84 months, were randomly allocated into the VCV or PCV group. Fiberoptic bronchoscopy was performed to confirm appropriate position of i-gel. Oropharyngeal leak pressure and PIP were measured after i-gel insertion, after caudal block, and after surgery. Ultrasonography was performed to detect gastric insufflation. Gastric tube was not inserted.

Results: PIP in cm H₂O was significantly lower in the PCV group than in the VCV group after i-gel insertion (10 [9–12] vs 12 [11–15], $P = .021$), after caudal block (11 [10–12] vs 13 [11–15], $P = .014$), and after surgery (10 [10–12] vs 13 [11–14], $P = .002$). There was no difference in the incidence of gastric insufflation between the 2 groups (4/17 in the VCV group and 3/17 in the PCV group) ($P > .999$).

Conclusion: When i-gel was used without a gastric tube, gastric insufflation occurred regardless of the ventilation modes, which provided different PIP.

Abbreviations: GAA = gastric antral area, PCV = pressure-controlled ventilation, PIP = peak inspiratory pressure, PPV = positive pressure ventilation, RR = respiratory rate, SD = standard deviation, SGAs = supraglottic airways, SpO₂ = oxygen saturation, US = ultrasonography, VCV = volume-controlled ventilation.

Keywords: airway pressure, gastric insufflation, i-gel, pediatrics, ventilation

1. Introduction

Supraglottic airways (SGAs) have the advantage of being less invasive than endotracheal intubation while providing a relatively definitive airway during anesthesia. SGAs can be used

for either spontaneous breathing or positive pressure ventilation (PPV),^[1] but the employment of PPV is gradually increasing because spontaneous breathing is frequently associated with significant hypercarbia, reduced functional residual capacity, and the increased work of breathing.^[2,3] However, high inspiratory pressure obtained with PPV can cause high gas leakage around the SGAs that may increase the risk of gastric insufflation in children.^[2–6] During PPV with SGAs, excessively increased PIP which exceeds the oropharyngeal leak pressure may lead to gastric insufflation or gas leakage through the mouth.^[4,6–8] Although conventional volume-controlled ventilation (VCV) provides a constant tidal volume, it may also provide a higher peak inspiratory pressure (PIP) compared with pressure-controlled ventilation (PCV) because PIP obtained with VCV varies depending on the patient's airway resistance, compliance, and inspiratory flow rate. PCV can provide approximately 10% to 16% less PIP than VCV while maintaining equal ventilation and may reduce the risk of gastric insufflation during anesthesia with laryngeal mask airway in children.^[5,9,10] Nevertheless, gastric insufflation is still a concern in any modes of PPV with SGAs.^[4,9] Moreover, SGA disposition or fold-over malposition may facilitate gastric insufflation.^[4,7]

The pediatric i-gel (Intersurgical Ltd, Wokingham, Berkshire, UK), one of the second generation SGAs, is a latex-free device with a noninflatable cuff and a channel for gastric tube (except size 1).

Editor: Kazuo Hanaoka.

Funding: This research did not receive any specific grant from funding agencies in the public, commercial, or not-for-profit sectors.

The authors have no conflicts of interest to disclose.

Department of Anesthesiology and Pain Medicine, Anesthesia and Pain Research Institute, Yonsei University College of Medicine, Seodaemun-gu, Seoul, Republic of Korea.

* Correspondence: Hae Keum Kil, Department of Anesthesiology and Pain Medicine, Anesthesia and Pain Research Institute, Yonsei University College of Medicine, 50 Yonsei-ro, Seodaemun-gu, Seoul 03722, Republic of Korea (e-mail: hkkil@yuhs.ac).

Copyright © 2017 the Author(s). Published by Wolters Kluwer Health, Inc. This is an open access article distributed under the Creative Commons Attribution-NoDerivatives License 4.0, which allows for redistribution, commercial and non-commercial, as long as it is passed along unchanged and in whole, with credit to the author.

Medicine (2017) 96:18(e6772)

Received: 16 March 2017 / Received in final form: 28 March 2017 / Accepted: 30 March 2017

<http://dx.doi.org/10.1097/MD.0000000000006772>

The i-gel, including the cuff, is made of a gel-like thermoplastic elastomer, which provides a perilaryngeal seal with a slight pressure on the pharyngolaryngeal structure. A meta-analysis demonstrated that the i-gel provides higher oropharyngeal leak pressure than classic laryngeal mask airway or ProSeal, which is the most important determinant of the efficacy and safety of the SGA.^[11] The i-gel has high oropharyngeal leak pressure and a gastric channel to protect against gastric insufflation. However, high PIP during PPV with i-gel may result in gastric insufflation, especially if the gastric tube was not placed. In several studies, the incidence of gastric insufflation varied from 0% to 30% depending on the PIP and the presence of a gastric tube.^[12–14]

We hypothesized that PIP would be significantly lower in the PCV group compared with the VCV group during anesthesia with i-gel. The primary aim of this prospective, randomized-controlled study was to compare PIP between ventilatory modes of VCV and PCV in children undergoing general anesthesia with the i-gel without a gastric tube. The secondary aims of this study were to evaluate the oropharyngeal leak pressure and the incidence of gastric insufflation.

2. Methods

This prospective, randomized-controlled study was approved by the Institutional Review Board of Yonsei University Health System (IRB number, 4-2014-0594) and was registered at www.ClinicalTrials.gov (ref. number: NCT02259569). Informed consent was obtained from the parents of all the children. This study was conducted between October 2014 and February 2015 in Severance Hospital in Seoul, Republic of Korea.

2.1. Study population

Thirty-four children, aged 6 to 84 months, ASA physical status I or II, undergoing elective urologic surgery requiring general anesthesia were enrolled. Children with congenital oropharyngeal or facial anomalies, current respiratory disease, or risk of aspiration (gastrointestinal stenosis or gastroesophageal reflux disease) were excluded.

2.2. Study protocol

The enrolled patients were randomly allocated into the PCV group (n=17) or the VCV group (n=17) using a computerized randomization table by an investigator not involved in patient care. No premedication was administered. The children were transferred to the operating room under light sedation with intravenous thiopental sodium. After routine monitors were applied, anesthesia was induced with 4 to 5 mg/kg of thiopental sodium, while the oxygen and sevoflurane 3.5% was administered with facemask ventilation. After the patients lost their eyelash reflex, rocuronium 0.3 mg/kg was administered for neuromuscular blockade, and the i-gel was inserted using a standard method according to the manufacturer's recommendation. Each i-gel was inserted by an anesthesiologist who has performed >100 i-gel insertion, and was not involved in this study.

The ease of insertion of the i-gel was assessed using a 4-graded scale (1=no resistance, 2=mild resistance, 3=moderate resistance, 4=inability to place the device). The number of insertion attempts was also recorded. After confirmation of successful i-gel insertion with a clinical test (square wave of capnogram, bilateral chest expansion, and reservoir bag movement), a polyethylene catheter was inserted through a side channel of the i-gel to remove

possible gastric insufflation during facemask ventilation, and then the catheter was removed. The position of the i-gel was evaluated with fiberoptic bronchoscopy (Olympus Optical Co., Tokyo, Japan) through the device and the i-gel position was graded using a scale between 1 and 4 (1=larynx only seen, 2=larynx and epiglottis seen, 3=epiglottis impinging on grille, but larynx seen, 4=epiglottis down-folded, and larynx not seen).^[15] If the grade was ≥ 3 , the i-gel was repositioned to grade 1 or 2 and secured with a tape. Oropharyngeal leak pressure was measured in both groups.

For the VCV group, the tidal volume was set at 10 mL kg⁻¹. For the PCV group, the inspiratory pressure was set to obtain the same tidal volume. The respiratory rate (RR) was set at 20/minutes with an inspiratory-to-expiratory ratio of 1:2. The RR was adjusted to maintain the end tidal CO₂ between 35 to 40 mm Hg in both groups. Anesthesia was maintained with sevoflurane (2–3%) in 50% oxygen.

Ultrasonography (US) was performed on the upper abdomen to ensure an empty gastric antrum by a highly experienced anesthesiologist using a LOGIQ^c (GE Healthcare, Wauwatosa, WI). For the standardization of the scanning level on the sagittal plane, the gastric antrum was identified with a 4-MHz convex transducer along the length of the abdominal aorta at the level of the superior mesenteric artery as described in previous studies.^[16–18] A high-frequency linear probe was applied at the same point, and the image was acquired 5 times between the antral contractions for the accuracy of the outcome variables. Three measurements, excluding the smallest and largest values, were selected for mean values.

Before surgery, caudal block was performed in all children in the lateral decubitus position. After the children were placed in the supine position, fiberoptic bronchoscopy was repeated, and the i-gel was repositioned to grade 1/2, if the grade was ≥ 3 . At the end of the surgery, all the measurements were repeated (PIP, US, oropharyngeal leak pressure, and fiberoptic bronchoscopy).

Oropharyngeal leak pressure was measured by closing the adjustable pressure-limiting valve of the pediatric circle system to 30 cm H₂O at a fixed gas flow of 3 L/min and noting the steady-state airway pressure on the monitor.^[19,20]

US examinations were performed after the initial fixation of the i-gel, and after the end of surgery. On the 2nd US examination, acoustic shadows with comet-tail artifacts or ring-down artifacts were defined as gastric insufflation (Fig. 1A).^[18,21] When the acoustic shadows with comet-tail artifacts or ring-down artifacts were detected, gastric catheter was inserted via side channel of the i-gel and gastric insufflation was confirmed with the “gurgle” sound. On US images, gastric antral area (GAA) was calculated from 2 orthogonal diameters of the antrum (D1 and D2) including the gastric wall (distances between bilateral hypoechoic muscularis propria of the outer gastric walls) measured by US, using the following formula, as previously described (Fig. 1B).^[16–18]

$$GAA = \pi \times D1 \times D2/4$$

The mean arterial pressure and heart rate were recorded every 10 minutes. Any adverse events such as oxygen saturation (SpO₂) < 93% or laryngospasm, and blood stains on the i-gel at removal were evaluated. Patients were awakened in the usual manner and transferred to the recovery room.

2.3. Sample size

In previous studies in children, there were no differences in PIP between classic laryngeal mask airway group and i-gel group

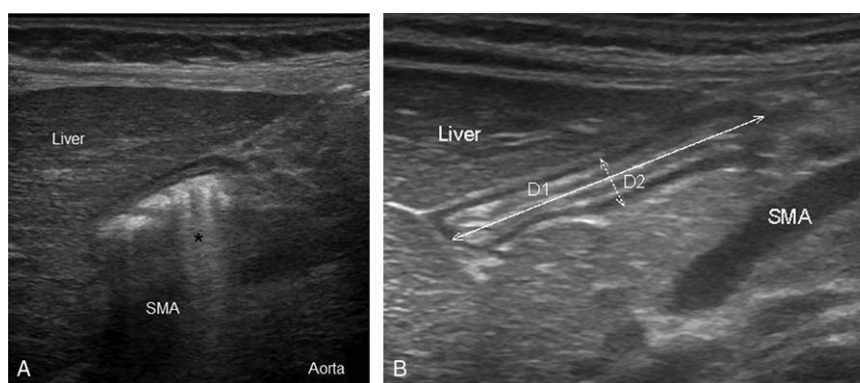


Figure 1. (A) Ultrasound images of gastric antrum after gastric insufflation showing acoustic shadows with comet-tail artifacts (asterisk). (B) Ultrasound images of the gastric antrum. On ultrasonography images, gastric antral area (GAA) was calculated from 2 orthogonal diameters of the antrum (D1 and D2). SMA=superior mesenteric artery.

during VCV.^[14,22] Since there was no PIP data available for i-gel, sample size was calculated based on a previous study using classic laryngeal mask airway in children.^[10] In their study, the mean (standard deviation, SD) PIP of the PCV and VCV mode with a classic laryngeal mask airway were 14.1 (1.6) cm H₂O and 16.7 (2.3) cm H₂O, respectively. The mean difference (pooled SD) in PIP was 2.6 (1.98) cm H₂O. Considering a type-1 error (α) of 5% and a power (1- β) of 90%, 14 patients were required in each group for statistical significance. Allowing for a 20% drop-out rate, 17 patients in each group were included.

2.4. Statistical analysis

Statistical analyses were performed using IBM SPSS Statistics 21 (SPSS, Inc., Chicago, IL). Categorical variables were analyzed using Chi-square test or Fisher exact test and were presented as numbers and percentages. Continuous variables were expressed as mean \pm SD or median [interquartile range] according to the normality, using Student *t* test, Mann-Whitney *U* test, or repeated measures ANOVA as appropriate. For the analysis of GAA, we excluded the maximum and minimum values of the 5 values and the average of 3 measurements was calculated. *P* values less than .05 were considered statistically significant.

3. Results

All children completed the study (Fig. 2). The i-gel was inserted successfully at the 1st attempt in all children. The patients' characteristics and operative data were not different between the groups (Table 1).

PIP in cm H₂O was significantly lower in the PCV group than in the VCV group after i-gel insertion (10 [9–12] vs 12 [11–15], *P* = .021), after caudal block (11 [10–12] vs 13 [11–15], *P* = .014), and after surgery (10 [10–12] vs 13 [11–14], *P* = .002) (Table 2). After the 1st fiberoptic bronchoscopy, the i-gel position was corrected to grade 1/2 in 5 children who showed grade 3 (3 in the VCV group and 2 in the PCV group, *P* > .999). After caudal block, the i-gel position was changed to grade 3 in 8 patients (5 in the VCV group and 3 in the PCV group, *P* = .688). At the 3rd evaluation after the end of surgery, 8 cases showed grade 3 of i-gel position (6 of the VCV group and 2 of the PCV group, *P* = .225) (Table 3).

On the 1st US examination, an empty gastric antrum was observed as a “Bull’s eyes” target shape (25) or a flat shape (9). A

comet-tail appearance was found in 7 children (4 of 17 in the VCV group and 3 of 17 in the PCV group, *P* > .999) by US performed at the end of surgery (Table 4). In these cases, gastric insufflation was reconfirmed based on air coming out (“gurgling sound”) the gastric tube inserted through the side channel of the i-gel. GAA was significantly larger on the 2nd US than on the 1st US in both groups (Table 4).

The hemodynamic status was stable in both groups throughout the study period. There were no adverse events such as desaturation or laryngospasm, or blood stains on the removed device.

4. Discussion

In this study, we found that PIP was lower in the PCV group than in the VCV group but gastric insufflation was detected in 3 cases of PCV and 4 cases of VCV (total 20.6%) on US examination. In 7 cases with gastric insufflation detected on US, gastric insufflation was confirmed by the “gurgle” sound through a gastric tube inserted in the side channel of the i-gel in all cases showing comet-tail appearance on US. Actually, US had a higher sensitivity and specificity for the detection of gastric insufflation.^[18,23] And also, on the 2nd US examinations after the completion of surgery, GAA was significantly increased compared with the GAA of the 1st US in both groups. But we cannot be sure that the increased GAA definitely reflects the occurrence of gastric insufflation. Several researchers reported that enlarged GAA indicates gastric insufflation.^[16–18] However, as Schmitz et al. suggested,^[17] several anatomical and functional variations make it difficult to confirm gastric insufflation with simple measurement of GAA on US. Nevertheless, it should be considered that gastric insufflation may occur frequently in patients with i-gel during PPV if a gastric tube is not inserted.

The i-gel has a potential for preventing gastric insufflation with its higher oropharyngeal leak pressure and its specific design of the noninflatable cuff for laryngeal sealing and a side channel for gastric decompression.^[6] However, clinically undetected malpositioning of SGAs is a significant risk factor for gastric insufflation in children.^[4] In several studies investigating the fiberoptic bronchoscopy position of the i-gel, grade 3 (only visible epiglottis) or 4 (vocal cords were not visible) was found in 10% to 40% of subjects.^[13,14,20] Although it is considered that the flattened stem of i-gel improves its stabilization and prohibits its malposition, a manipulation could be required often to

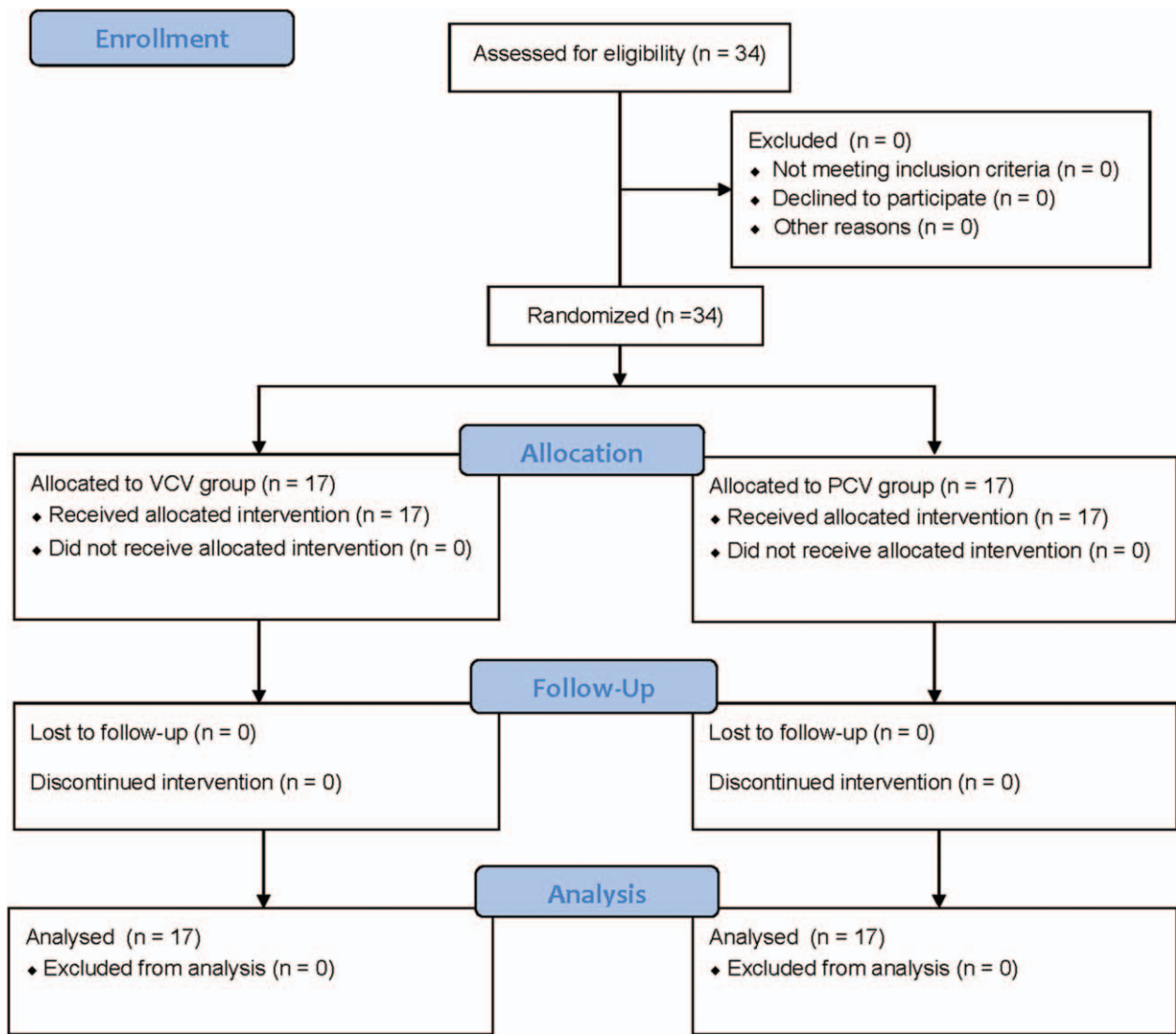


Figure 2. Consort flow diagram. PCV=pressure-controlled ventilation, VCV=volume-controlled ventilation.

Table 1
Baseline characteristics surgical and operative data of patients.

Variables	VCV (n=17)	PCV (n=17)
Age, mo	23 [12–42]	26 [20–39]
Male	16 (94.1%)	17 (100%)
Height, cm	78 [74–94]	86 [76–92]
Weight, kg	11 [10–14]	12 [11–14]
BMI, kg/m ²	18 [17–19]	16 [15–35]
ASA (I/II)	17/0	16/1
Insertion attempt (1/2)	17/0	17/0
Ease of insertion (1/2/3/4)*	17/0/0/0	17/0/0/0
i-gel size 1.5/2	9/8	11/6
Operation time, min	29 [22–41]	28 [44–75]
Anesthesia time, min	62 [53–70]	75 [60–103]

Values indicate median [IQR] and number (%).

ASA=American Society of Anesthesiologists Physical Status, BMI=body mass index, PCV=pressure-controlled ventilation, VCV=volume-controlled ventilation.

*Ease of insertion of i-gel was assessed using a 4-graded scale (1=no resistance, 2=mild resistance, 3=moderate resistance, 4=inability to place the device).

maintain stability of this device.^[24] And also, i-gel can be displaced after postural change as in a caudal block. In our study, the i-gel position was changed to grade 3 in 8 of 34 children (23.5%) after caudal block. After the end of surgery, 8 of 34 cases (including some previously displaced cases) showed the grade 3 again. Gastric insufflation was detected on US in 3 of that 8 cases. In most studies, including our study,^[13,14,20] ventilation was acceptable in grade 3/4, but increased PIP following grade worsening may induce gastric insufflation and oropharyngeal leakage during PPV.^[4,6] If there is no room for the escape of air outside the oral cavity, leaked oropharyngeal gas can be forced into the stomach.^[25] In our study, the median oropharyngeal leak pressure was not different between both groups (20–23 cm H₂O in the VCV group and 20–21 cm H₂O in the PCV group) despite the PIP difference. The oropharyngeal leak pressure is consistent with previous studies reporting 21 to 26 cm H₂O.^[12–14] In comparison, gastric insufflation was presented in 20.6% of patients in our study, which is higher than in a study by Kim et al (9%)^[13] but lower than observed in another study by Kim et al

Table 2
Peak inspiratory pressure, oropharyngeal leak pressure.

Variables	VCV (n = 17)	PCV (n = 17)	P
Peak inspiratory pressure (cm H ₂ O)			
After insertion	12 [11–15]	10 [9–12]	.021
After caudal block	13 [11–15]	11 [10–12]	.014
End of surgery	13 [11–14]	10 [10–12]	.002
Oropharyngeal leak pressure (cm H ₂ O)			
After insertion	20 [17–25]	20 [17–24]	.890
After caudal block	23 [21–26]	21 [18–27]	.623
End of surgery	23 [18–26]	20 [17–28]	.972

Values indicate median [IQR].
PCV = pressure-controlled ventilation, VCV = volume-controlled ventilation.

(30%).^[14] This discrepancy might be related to the detection period. In these previous studies using i-gel without a gastric tube,^[13,14] gastric insufflation was detected by auscultation at the time of leak pressure measurement. In most studies measuring oropharyngeal leak pressure of the SGAs in children, the adjustable pressure-limiting valve was set at 30 to 40 cm H₂O with a gas flow of 3 L/min.^[8,12–14] Thus, transient high airway pressure and gas leakage are produced during a measurement. If there is any malpositioning of SGA, leaked gas will be forced into the stomach if there is no room for the escape of the leaked gas due to the taped stalk of the SGA.^[6,7] Although we performed a second US examination just before the measurement of oropharyngeal leak pressure after the end of surgery, we cannot exclude the possibility of gastric insufflation occurrence during the 1st leak pressure measurements. Infancy is a vulnerable period for gastric insufflation during PPV because of the immature lower esophageal sphincter tone, the short length of the intraabdominal esophagus, and the blunt angle of His.^[25,26] As reported by Theiler et al,^[19] oropharyngeal leak pressure was higher in younger children weighing 5 to 9.9 kg than older children with i-gel. Thus, gastric insufflation also can occur more easily during leak pressure measurement as well as during PPV in infants.

PCV is considered a safer ventilation mode than VCV with SGA in children to reduce lower inspiratory pressure, ventilator leakage, and gastric insufflation. Maintaining PIP below 15 cm H₂O is recommended to prevent gastric insufflation during PCV in children.^[25] However, in a study by Sinha et al,^[9] gastric

Table 3
Fiberoptic bronoscopic view and number of patients with change of i-gel position.

Variables	VCV (n = 17)	PCV (n = 17)	P
Fiberoptic bronchoscopy view (1/2/3/4)*			
After insertion (1st fiberoptic bronchoscopy)	11/3/3/0	6/9/2/0	.122
Correction after insertion	13/4/0/0	8/9/0/0	.078
After caudal block (2nd fiberoptic bronchoscopy)	9/3/5/0	7/7/3/0	.410
Correction after caudal block	10/7/0/0	7/10/0/0	.303
End of surgery	6/5/6/0	7/8/2/0	.371
Number of patients with change of i-gel position			
After caudal block	5	3	.688
End of the surgery	6	2	.225

Values indicate number.
PCV = pressure-controlled ventilation, VCV = volume-controlled ventilation.
* Fiberoptic bronchoscopy view was graded as 4 (1 = larynx only seen, 2 = larynx and epiglottis seen, 3 = epiglottis impinging on grille, but larynx seen, 4 = epiglottis down-folded, and larynx not seen).

Table 4
Ultrasonography.

Variables	VCV (n = 17)	PCV (n = 17)	P
Shape of gastric antrum			
1st US examination (Bull's eye/flat shape)	12/5	13/4	>.999
2nd US examination (comet-tail appearance, n, %)	4 (24%)	3 (18%)	>.999
Gastric antrum areas, cm ²			
1st US examination	1.27 [1.10–1.56]	1.57 [1.20–1.93]	.174
2nd US examination	1.52 [1.13–1.76]	2.00 [1.69–2.26]	.026
P	.005	.004	

Values indicate median [IQR] and number (%).
PCV = pressure-controlled ventilation, US = ultrasonography, VCV = volume-controlled ventilation.

insufflation occurred in PCV with PIP below 13 cm H₂O in infants, although they suggested that PCV should be the preferred mode compared to VCV. In our study, gastric insufflation was presented similarly in both the VCV and PCV groups despite the low PIP under 15 cm H₂O in both groups. Thus, the upper limit of PIP of 15 cm H₂O may not prevent gastric insufflation in infants and small children whether the ventilator mode is PCV or VCV in small children.

In our study, 23.5% of children showed grade 3 fiberoptic bronchoscopic position of i-gel after the end of surgery despite the repositioning of the i-gel after caudal block. As we mentioned before, a risk of gastric insufflation might be increased in malposition of SGA during anesthesia. Therefore, careful monitoring is needed throughout the anesthesia.

This study has several limitations. First, we enrolled cases using size 1.5 and 2 of i-gel, this result may not exactly apply to every size if i-gel for children. Second, because US examination was performed in the supine position, the collected air in the antrum might not be detected in some parts on portable US. And also, the gastric antral image may be affected by anatomical and functional variations by patients. Third, since the most of children enrolled to this study were male patients, the result of this study may not be extrapolated to female pediatric population.

In conclusion, although PCV provided lower PIP compared with VCV, the incidence of gastric insufflation was similar in the 2 groups during anesthesia using i-gel without a gastric tube. Although i-gel resulted in a high oropharyngeal gas leak pressure, gastric insufflation can occur frequently if the gastric tube is not placed through a side channel during anesthesia.

Acknowledgments

This study was presented in part as an abstract at American Society of Anesthesiologists Annual Meeting 2015, San Diego, CA, USA, October 24–28, 2015.

References

- [1] Efrat R, Kadari A, Katz S. The laryngeal mask airway in pediatric anesthesia: experience with 120 patients undergoing elective groin surgery. *J Pediatr Surg* 1994;29:206–8.
- [2] Keidan I, Fine GF, Kagawa T, et al. Work of breathing during spontaneous ventilation in anesthetized children: a comparative study among the face mask, laryngeal mask airway and endotracheal tube. *Anesth Analg* 2000;91:1381–8.

- [3] Hoshi K, Ejima Y, Hasegawa R, et al. Differences in respiratory parameters during continuous positive airway pressure and pressure support ventilation in infants and children. *Tohoku J Exp Med* 2001;194:45–54.
- [4] Wahlen BM, Heinrichs W, Latorre F. Gastric insufflation pressure, air leakage and respiratory mechanics in the use of the laryngeal mask airway (LMA) in children. *Paediatr Anaesth* 2004;14:313–7.
- [5] Bordes M, Semjen F, Degryse C, et al. Pressure-controlled ventilation is superior to volume-controlled ventilation with a laryngeal mask airway in children. *Acta Anaesthesiol Scand* 2007;51:82–5.
- [6] Weiler N, Latorre F, Eberle B, et al. Respiratory mechanics, gastric insufflation pressure, and air leakage of the laryngeal mask airway. *Anesth Analg* 1997;84:1025–8.
- [7] Latorre F, Eberle B, Weiler N, et al. Laryngeal mask airway position and the risk of gastric insufflation. *Anesth Analg* 1998;86:867–71.
- [8] Lopez-Gil M, Brimacombe J, Garcia G. A randomized non-crossover study comparing the ProSeal and Classic laryngeal mask airway in anaesthetized children. *Br J Anaesth* 2005;95:827–30.
- [9] Sinha A, Sharma B, Sood J. Pressure vs. volume control ventilation: effects on gastric insufflation with size-1 LMA. *Paediatr Anaesth* 2010;20:1111–7.
- [10] Keidan I, Berkenstadt H, Segal E, et al. Pressure versus volume-controlled ventilation with a laryngeal mask airway in paediatric patients. *Paediatr Anaesth* 2001;11:691–4.
- [11] Maitra S, Baidya DK, Bhattacharjee S, et al. Evaluation of i-gelTM airway in children: a meta-analysis. *Paediatr Anaesth* 2014;24:1072–9.
- [12] Beylacq L, Bordes M, Semjen F, et al. The I-gel, a single-use supraglottic airway device with a non-inflatable cuff and an esophageal vent: an observational study in children. *Acta Anaesthesiol Scand* 2009;53: 376–9.
- [13] Kim MS, Lee JH, Han SW, et al. A randomized comparison of the i-gel with the self-pressurized air-Q intubating laryngeal airway in children. *Paediatr Anaesth* 2015;25:405–12.
- [14] Kim MS, Oh JT, Min JY, et al. A randomised comparison of the i-gel and the Laryngeal Mask Airway Classic in infants. *Anaesthesia* 2014;69: 362–7.
- [15] Ghai B, Ram J, Makkar JK, et al. Fiber-optic assessment of LMA position in children: a randomized crossover comparison of two techniques. *Paediatr Anaesth* 2011;21:1142–7.
- [16] Cubillos J, Tse C, Chan VW, et al. Bedside ultrasound assessment of gastric content: an observational study. *Can J Anaesth* 2012;59:416–23.
- [17] Schmitz A, Thomas S, Melanie F, et al. Ultrasonographic gastric antral area and gastric contents volume in children. *Paediatr Anaesth* 2012;22:144–9.
- [18] Bouvet L, Albert ML, Augris C, et al. Real-time detection of gastric insufflation related to facemask pressure-controlled ventilation using ultrasonography of the antrum and epigastric auscultation in non-paralyzed patients: a prospective, randomized, double-blind study. *Anesthesiology* 2014;120:326–34.
- [19] Theiler LG, Kleine-Brueggeny M, Luepold B, et al. Performance of the pediatric-sized i-gel compared with the Ambu AuraOnce laryngeal mask in anesthetized and ventilated children. *Anesthesiology* 2011;115: 102–10.
- [20] Kim H, Lee JY, Lee SY, et al. A comparison of i-gel and LMA Supreme in anesthetized and paralyzed children. *Korean J Anesthesiol* 2014;67:317–22.
- [21] Feldman MK, Katyal S, Blackwood MS. US artifacts. *Radiographics* 2009;29:1179–89.
- [22] Lee JR, Kim MS, Kim JT, et al. A randomised trial comparing the i-gelTM with the LMA ClassicTM in children. *Anaesthesia* 2012;67:606–11.
- [23] Brun PM, Chenaitia H, Lablanche C, et al. 2-point ultrasonography to confirm correct position of the gastric tube in prehospital setting. *Mil Med* 2014;179:959–63.
- [24] Jagannathan N, Sommers K, Sohn LE, et al. A randomized equivalence trial comparing the i-gel and laryngeal mask airway Supreme in children. *Paediatr Anaesth* 2013;23:127–33.
- [25] Lagarde S, Semjen F, Nouette-Gaulain K, et al. Facemask pressure-controlled ventilation in children: what is the pressure limit? *Anesth Analg* 2010;110:1676–9.
- [26] Spitz L, McLeod E. Gastroesophageal reflux. *Semin Pediatr Surg* 2003;12:237–40.