

Original Article

<http://dx.doi.org/10.3350/cmh.2016.22.1.140>
Clinical and Molecular Hepatology 2016;22:140-145

Magnetization-tagged MRI is a simple method for predicting liver fibrosis

Kyung-Eun Kim¹, Mi-Suk Park¹, Sohae Chung², Chansik An¹, Leon Axel², and Rakhmonova Gulbahor Ergashovna³

¹Department of Radiology and Research Institute of Radiological Science, Yonsei University College of Medicine, Seoul; ²Center for Biomedical Imaging, Department of Radiology, New York University Langone Medical Center, New York, USA; ³Tachkent Medical Academy, Tachkent, Uzbekistan

Background/Aims: To assess the usefulness of magnetization-tagged magnetic resonance imaging (MRI) in quantifying cardiac-induced liver motion and deformation in order to predict liver fibrosis.

Methods: This retrospective study included 85 patients who underwent liver MRI including magnetization-tagged sequences from April 2010 to August 2010. Tagged images were acquired in three coronal and three sagittal planes encompassing both the liver and heart. A Gabor filter bank was used to measure the maximum value of displacement (MaxDisp) and the maximum and minimum values of principal strains (MaxP1 and MinP2, respectively). Patients were divided into three groups (no fibrosis, mild-to-moderate fibrosis, and significant fibrosis) based on their aspartate-aminotransferase-to-platelet ratio index (APRI) score. Group comparisons were made using ANOVA tests.

Results: The patients were divided into three groups according to APRI scores: no fibrosis (≤ 0.5 ; $n=41$), moderate fibrosis ($0.5-1.5$; $n=23$), and significant fibrosis (>1.5 ; $n=21$). The values of MaxDisp were 2.9 ± 0.9 (mean \pm SD), 2.3 ± 0.7 , and 2.1 ± 0.6 in the no fibrosis, moderate fibrosis, and significant fibrosis groups, respectively ($P<0.001$); the corresponding values of MaxP1 were 0.05 ± 0.2 , 0.04 ± 0.02 , and 0.03 ± 0.01 , respectively ($P=0.002$), while those of MinP2 were -0.07 ± 0.02 , -0.05 ± 0.02 , and -0.04 ± 0.01 , respectively ($P<0.001$).

Conclusions: Tagged MRI to quantify cardiac-induced liver motion can be easily incorporated in routine liver MRI and may represent a helpful complementary tool in the diagnosis of early liver fibrosis. (*Clin Mol Hepatol* 2016;22:140-145)

Keywords: Liver cirrhosis; Fibrosis; Magnetic resonance imaging

INTRODUCTION

Liver fibrosis is a common response to chronic liver injury and is known to arise from a variety of viral, alcohol and drug-induced causes. As significant fibrosis may progress to cirrhosis with or without hepatocellular carcinoma, antiviral treatment is recommended for patients with significant fibrosis. Accordingly, liver fi-

bro sis grading is essential for proper management of patient as mild fibrosis needs to be monitored and those with significant fibrosis must be treated.¹⁻³ Although liver biopsy has remained as a gold standard for diagnosing liver fibrosis and cirrhosis, It is an invasive procedure and poses a risk of severe complications. In addition, biopsy results are subject to sampling error related to the heterogeneity of the distribution of liver fibrosis.^{4,5} On the other

Abbreviations:

APRI, AST to platelet ratio index; AST, aspartate aminotransferase; MaxDisp, local maximum displacement; MaxP1, local maximum P1 strain; MinP2, local minimum P2 strain

Corresponding author : Mi-Suk Park

Department of Radiology, Severance Hospital, Yonsei University College of Medicine, 50 Yonsei-ro, Seodaemun-gu, Seoul 03722, Korea
Tel: +82-2-2228-7400, Fax: +82-2-393-3035
E-mail: radpms@yuhs.ac

Received : Jun. 11, 2015 / Revised : Jan. 18, 2016 / Accepted : Jan. 25, 2016

hand, non-invasive methods are being investigated for the diagnosis of liver fibrosis including ultrasound-based transient elastography and magnetic resonance imaging (MRI)-based studies using MR elastography.⁶⁻⁹ Ultrasound-based transient elastography is simple, but involves measurement limitations in regards to depth and in patients with obesity.¹⁰ Although MR elastography is known to be accurate, it requires special-purpose hardware in order to generate an externally induced vibration wave.¹¹ Alternatively, recent studies on magnetization-tagged MRI have shown that cardiac-induced liver motion can be measured to noninvasively assess liver stiffness.¹² Therewith, pulsations of the heart as an intrinsic motion source are transmitted to the adjacent portion of the liver during the cardiac cycle, resulting in relatively localized motion and deformation of the liver. This motion of the liver can be imaged using tagged MRI.

Among the serologic markers for liver fibrosis, AST to platelet ratio index (APRI) is a simple index that can be calculated using readily available laboratory results, and is reported to demonstrate a high degree of accuracy in the diagnosis of significant liver fibrosis.¹³⁻¹⁷

The purpose of this study was to assess the usefulness of tagged MRI of cardiac-induced liver motion in staging liver fibrosis compared to the simple serologic marker APRI, and to test for its potential use as a routine MRI sequence.

MATERIAL AND METHODS

The institutional review board of our institution approved this retrospective study, and informed consent was waived. We retrospectively reviewed magnetization-tagged MRI of the patients who were prospectively enrolled for another research (IRB #4-2010-0303), where it was addressed whether magnetization-tagged MRI is correlated with Child-Pugh scores.¹⁸

Subjects

From April 2010 to August 2010, 175 patients underwent liver MRI with magnetization-tagged sequence at our institution for various diagnostic purposes. Ninety patients were excluded from this study due to a history of underlying heart disease (n=6); a history of treatment for liver disease, such as hepatic resection, transarterial chemo-embolization or radio-frequency ablation (n=30); a history of systemic chemotherapy (n=28); the presence of space occupying lesions in the left hepatic lobe larger than 2 cm (n=17); and suboptimal quality MR images for which to ana-

lyze liver fibrosis because of respiratory motion artifacts, atrophic change in the left hepatic lobe, or a large amount of ascites (n=9). The failure rate of this sequence is about 5.1% (9/175). Consequently, a total of 85 patients with tagged MRI were included in this study. Of the 85 patients (57.6±10.0 years old, 57 males and 28 females), 62 (72.9%) patients had chronic liver disease [hepatitis B (n=47), hepatitis C (n=12), alcoholic liver disease (n=6)] and 23 patients had small (<2 cm) focal liver lesions without parenchymal abnormality [liver metastasis (n=13) and other benign focal liver lesions (n=10)].

Clinical analysis

Medical records of the patients were retrospectively reviewed for clinical information. All patients underwent routine complete blood count (CBC) tests with platelet count and serum biochemical tests including aspartate aminotransferase (AST) within 1 week of undergoing tagged MRI. AST to platelet ratio index (APRI) was calculated using the following formula.^{13,14} $APRI = \text{AST level (upper limit of normal)/platelet counts (10}^9\text{/L)} \times 100$. An APRI score below the lower cut-off value (0.50) was defined as no fibrosis, while an APRI score above the higher cut-off value (1.50) was defined as significant fibrosis.¹³ An APRI score between the lower and higher cut-off values was defined as moderate fibrosis.

MRI protocol

Subjects were scanned using 3T MRI systems (Tim Trio, Siemens Medical Solutions, Erlangen, Germany) with standard phase-array coils. An electrocardiogram-gated tagged MR sequence was performed while the subjects held their breath and using the following imaging parameters¹²: echo time=3.9 msec, pulse repetition time=8.0 msec, temporal resolution=48.2 msec, flip angle=10°, receiver bandwidth=201 Hz/pixel, generalized autocalibrating partially parallel acquisitions acceleration factor 2 with 24 reference k-space lines, field of view=300×300 mm, matrix=256×174, in-plane resolution=1.2×1.7 mm, slice thickness=6 mm, tag thickness=1.5 mm, tag spacing=7 mm, tag orientation=±45°. Two different views including both the heart and adjacent portions of the liver (three coronal and three sagittal planes) were acquired in each subject. The total acquisition time per slice was approximately 15–20 sec.

Image analysis

A Gabor filter bank was used to extract the tag position, after which displacement and strains were calculated within the liver using custom software developed in MATLAB R2010b (The Math-

Works Inc., MA, USA).¹² Briefly, two families of orthogonally oriented phase images were generated from the filtered grid-tagged images, and the associated displacement results were calculated from the two sets of phase images. The corresponding principal strains, representing tissue deformation, were also calculated from the displacement fields.¹⁹ The local displacement and corresponding strains were measured in regions of interest (ROI) (approximately 18 mm × 18 mm or 240 pixels) chosen at liver regions just below the diaphragm, where the greatest values occurred. The local maximum displacement (MaxDisp), the local maximum P1 strain (MaxP1) and the local minimum P2 strain were found

over the cardiac cycle. The local maximum P1 strain (MaxP1) represents the amount of greatest elongation or stretch of the tissue (always larger than zero), and the local minimum P2 strain (MinP2) represents the amount of the greatest compression or shortening (always smaller than zero). The analysis was performed in a blinded fashion by a trained expert.

Statistical Analysis

The one-way analysis and variance (ANOVA) test was used to compare the means of MaxDisp, MaxP1 and MinP2 among the groups of no fibrosis, moderate fibrosis and significant fibrosis

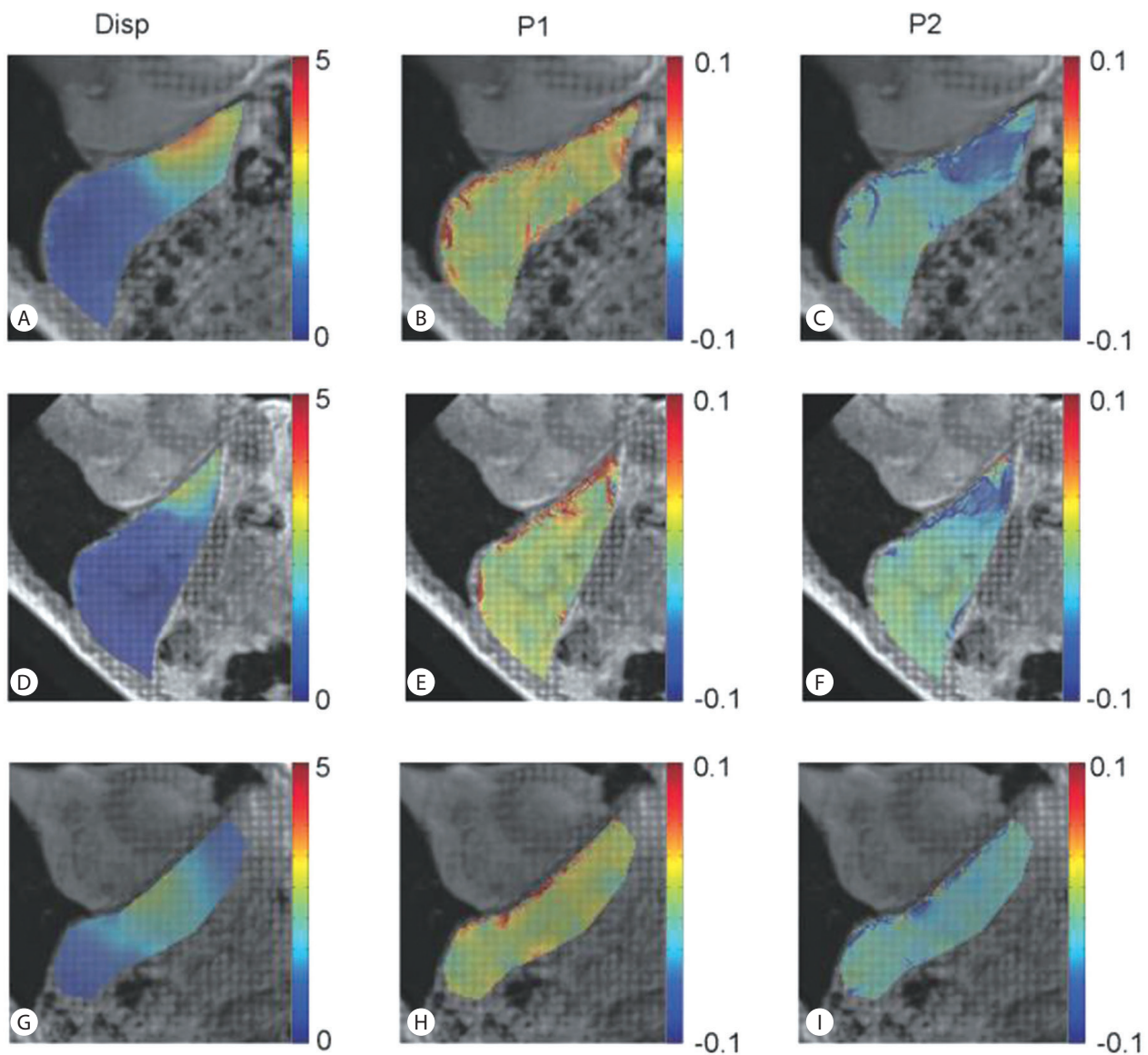


Figure 1. Representative grid-tagged MRI images with the superimposed color-coded corresponding displacement, P1 strain, and P2 strain maps of no fibrosis (A–C), moderate fibrosis (D–F), and significant fibrosis (G–I) patients relative to APRI scores, respectively. APRI, AST to platelet ratio index.

based on APRI. A p-value of less than 0.05 was considered to indicate statistical significance. However, to account for the multiple comparisons performed, a Bonferroni correction was applied so that results were defined as significant if $P < 0.05/3$ ($P < 0.017$). Data are expressed as mean \pm standard deviation.

RESULTS

With respect to APRI score, the patients were divided into three groups: no fibrosis (≤ 0.5 ; $n=41$), moderate fibrosis (0.5-1.5; $n=23$), and significant fibrosis (>1.5 ; $n=21$). Figure 1 shows reformatted oblique coronal tagged MR images obtained from a representative subject from each of these three groups, with the corresponding absolute displacement and P1/P2 strain color-maps superimposed over the liver. In the no fibrosis subject, relatively high deformation is seen localized below the heart in comparison to the moderate and significant fibrosis subjects. This reflects a higher resistance to deformation in the significant fibrosis group.

The mean values of MaxDisp were 2.9 ± 0.9 mm, 2.3 ± 0.7 mm and 2.1 ± 0.6 mm in the no fibrosis, moderate fibrosis and significant fibrosis groups, respectively, with statistically significant differences ($P < 0.001$). After Bonferroni correction, there were statistically significant differences between no fibrosis and moderate fibrosis groups ($P < 0.001$) as well as no fibrosis and significant fibrosis groups ($P = 0.001$), but there was no statistical significance between moderate fibrosis and significant fibrosis groups ($P = 0.556$) in regards to maximum displacement.

The mean values of MaxP1 were 0.05 ± 0.02 , 0.04 ± 0.02 and 0.03 ± 0.01 in the no fibrosis, moderate fibrosis and significant fibrosis groups, respectively, with statistically significant difference ($P = 0.002$). After the Bonferroni correction, there were also statis-

tically significant differences between no fibrosis and moderate fibrosis groups ($P = 0.006$) and no fibrosis and significant fibrosis groups ($P = 0.001$); however, there was no significant difference between moderate fibrosis and significant fibrosis groups ($P = 0.600$) in regards to MaxP1.

The mean values of MinP2 were -0.07 ± 0.02 , -0.05 ± 0.02 and -0.04 ± 0.01 in the no fibrosis, moderate fibrosis and significant fibrosis groups, respectively, with statistically significant difference ($P < 0.001$). After the Bonferroni correction, there were also statistically significant differences between no fibrosis and moderate fibrosis groups ($P = 0.001$) as well as no fibrosis and significant fibrosis groups ($P = 0.001$), but there was no significant difference between moderate fibrosis and significant fibrosis groups ($P = 0.484$) in regards to MinP2 (Table 1). The boxplots of the three groups are presented in Figure 2.

DISCUSSION

The basic principle of tagged MRI is the creation of localized perturbation of the magnetization. This can be done selectively, similarly to the selective excitation process used for image slice location, using spatial modulation of magnetization.²⁰ Tagged MRI has been mainly used for the evaluation of regional cardiac function. Recently, its application in the evaluation of the liver fibrosis has been reported, and involves measuring cardiac-induced motion in the liver¹² or respiratory-induced motion in the liver.²¹ In this study, we evaluated the usefulness of tagged MRI in assessing liver fibrosis by measuring cardiac-induced liver motion in three patient groups divided by APRI score. This study showed that displacement changes occur early during fibrosis and can be detected with tagged MRI using cardiac-induced liver motion. The

Table 1. Summary of the results for all three groups

| | | Mean \pm SD | P-value |
|--------------|----------------------|------------------|---------|
| MaxDisp (mm) | No fibrosis | 2.9 ± 0.9 | <0.001 |
| | Moderate fibrosis | 2.3 ± 0.7 | |
| | Significant fibrosis | 2.1 ± 0.6 | |
| MaxP1 | No fibrosis | 0.05 ± 0.2 | 0.002 |
| | Moderate fibrosis | 0.04 ± 0.02 | |
| | Significant fibrosis | 0.03 ± 0.01 | |
| MinP2 | No fibrosis | -0.07 ± 0.02 | <0.001 |
| | Moderate fibrosis | -0.05 ± 0.02 | |
| | Significant fibrosis | -0.04 ± 0.01 | |

MaxDisp, local maximum displacement; MaxP1, local maximum P1 strain; MinP2, local minimum P2 strain.

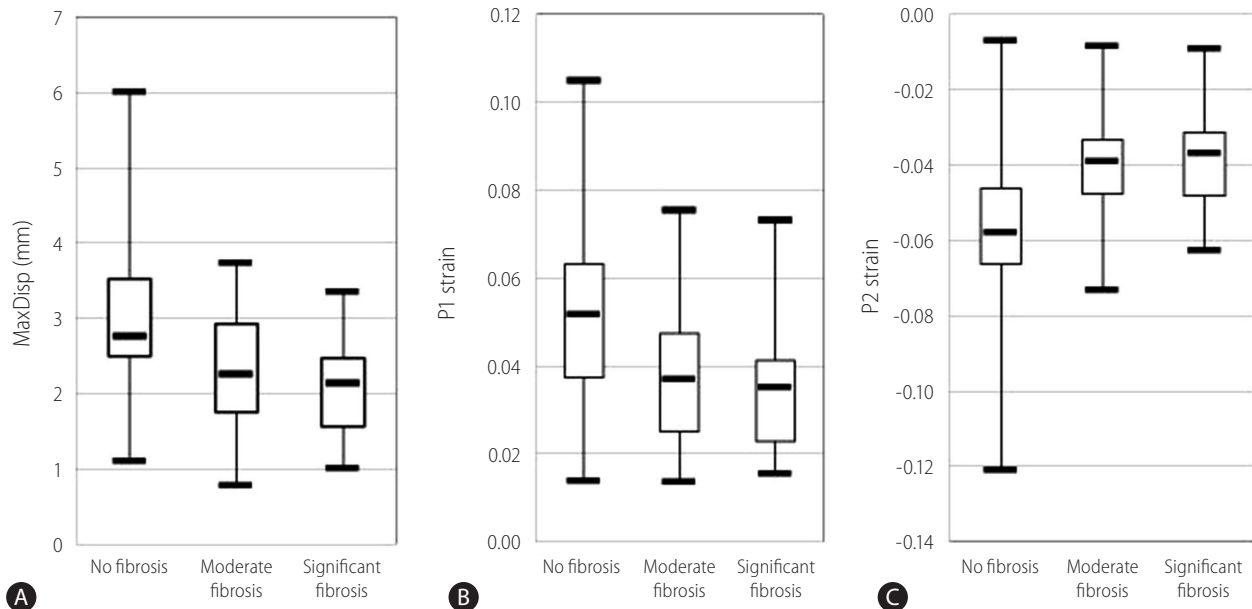


Figure 2. Boxplots of MaxDisp (A, mm), MaxP1 (B), and MinP2 (C) during the cardiac cycle divided by APRI ($P < 0.001$, $P = 0.002$, and $P < 0.001$, respectively). APRI, AST to platelet ratio index.

mean values of maximum displacement, maximum P1 (the amount of greatest elongation or stretch of the tissue) and minimum P2 (the amount of greatest compression or shortening of the tissue) were significantly different among the patients with no fibrosis, moderate fibrosis, and significant fibrosis. After Bonferroni correction, there was significant difference in maximum displacement, maximum P1 and minimum P2 between no fibrosis and moderate fibrosis, but not between moderate and significant fibrosis. Therefore, this method may help in the diagnosis of early liver fibrosis rather than advanced fibrosis, which may be useful to find the candidate for antiviral treatment.

Tagged MRI using cardiac-induced liver motion can be implemented on any conventional MRI systems without the need for any additional hardware, and involves only a short scan time of less than one minute. Therefore, it can be readily and easily incorporated in routine liver MRI examinations to obtain additional information on liver fibrosis. However, this method has some limitations in patients with heart disease or a large amount of ascites or pleural disease. Because it uses intrinsic heart motion as the motion source of the liver, the cardiac motion cannot be well transmitted to the liver in such cases.

As a limitation of this study, we could not obtain histopathologic fibrosis grade as the reference standard. Instead of pathologic grade, we used the serologic grade of fibrosis, APRI, as the reference standard. APRI is a simple and objective index with a very

high degree of accuracy in predicting fibrosis grade.¹³ Further study is needed to correlate with histopathologic fibrosis grade. The second limitation is that the methods of measuring local displacement and corresponding strains potentially include measurement errors including reproducibility issues. Therefore a further study on reproducibility issues is necessary. The third one is that the study population in this study was heterogeneous, including the patients with hepatitis B, hepatitis C, and alcoholic liver disease.

In conclusion, tagged MRI using cardiac-induced liver motion can be readily and easily incorporated in routine liver MRI examinations to obtain additional information on liver fibrosis. As a complementary tool, tagged MRI using cardiac-induced liver motion may help in the diagnosis of early liver fibrosis.

Acknowledgements

This research was supported by Basic Science Research Program through the National Research Foundation of Korea (NRF) funded by the Ministry of Education, Science and Technology (7-2012-0290).

Conflicts of Interest

The authors have no conflicts to disclose.

REFERENCES

1. Dufour JF, DeLellis R, Kaplan MM. Regression of hepatic fibrosis in hepatitis C with long-term interferon treatment. *Dig Dis Sci* 1998;43:2573-2576.
2. Wanless IR, Nakashima E, Sherman M. Regression of human cirrhosis. Morphologic features and the genesis of incomplete septal cirrhosis. *Arch Pathol Lab Med* 2000;124:1599-1607.
3. Malekzadeh R, Mohamadnejad M, Nasseri-Moghaddam S, Rakhshani N, Tavangar SM, Sohrabpour AA, et al. Reversibility of cirrhosis in autoimmune hepatitis. *Am J Med* 2004;117:125-129.
4. Afdhal NH, Nunes D. Evaluation of liver fibrosis: a concise review. *Am J Gastroenterol* 2004;99:1160-1174.
5. Hølund B, Poulsen H, Schlichting P. Reproducibility of liver biopsy diagnosis in relation to the size of the specimen. *Scand J Gastroenterol* 1980;15:329-335.
6. Sandrin L, Fourquet B, Hasquenoph JM, Yon S, Fournier C, Mal F, et al. Transient elastography: a new noninvasive method for assessment of hepatic fibrosis. *Ultrasound Med Biol* 2003;29:1705-1713.
7. Foucher J, Chanteloup E, Vergniol J, Castéra L, Le Bail B, Adhoute X, et al. Diagnosis of cirrhosis by transient elastography (FibroScan): a prospective study. *Gut* 2006;55:403-408.
8. Cobbold JF, Morin S, Taylor-Robinson SD. Transient elastography for the assessment of chronic liver disease: ready for the clinic? *World J Gastroenterol* 2007;13:4791-4797.
9. Asbach P, Klatt D, Schlosser B, Biermer M, Muehe M, Rieger A, et al. Viscoelasticity-based staging of hepatic fibrosis with multifrequency MR elastography. *Radiology* 2010;257:80-86.
10. Foucher J, Castéra L, Bernard PH, Adhoute X, Laharie D, Bertet J, et al. Prevalence and factors associated with failure of liver stiffness measurement using FibroScan in a prospective study of 2114 examinations. *Eur J Gastroenterol Hepatol* 2006;18:411-412.
11. Muthupillai R, Lomas DJ, Rossman PJ, Greenleaf JF, Manduca A, Ehman RL. Magnetic resonance elastography by direct visualization of propagating acoustic strain waves. *Science* 1995;269:1854-1857.
12. Chung S, Breton E, Mannelli L, Axel L. Liver stiffness assessment by tagged MRI of cardiac-induced liver motion. *Magn Reson Med* 2011;65:949-955.
13. Wai CT, Greenson JK, Fontana RJ, Kalbfleisch JD, Marrero JA, Conjeevaram HS, et al. A simple noninvasive index can predict both significant fibrosis and cirrhosis in patients with chronic hepatitis C. *Hepatology* 2003;38:518-526.
14. Snyder N, Gajula L, Xiao SY, Grady J, Luxon B, Lau DT, et al. APRI: an easy and validated predictor of hepatic fibrosis in chronic hepatitis C. *J Clin Gastroenterol* 2006;40:535-542.
15. Huwart L, Sempoux C, Salameh N, Jamart J, Annet L, Sinkus R, et al. Liver fibrosis: noninvasive assessment with MR elastography versus aspartate aminotransferase-to-platelet ratio index. *Radiology* 2007;245:458-466.
16. Castéra L, Vergniol J, Foucher J, Le Bail B, Chanteloup E, Haaser M, et al. Prospective comparison of transient elastography, Fibrotest, APRI, and liver biopsy for the assessment of fibrosis in chronic hepatitis C. *Gastroenterology* 2005;128:343-350.
17. Chang PE, Lui HF, Chau YP, Lim KH, Yap WM, Tan CK, et al. Prospective evaluation of transient elastography for the diagnosis of hepatic fibrosis in Asians: comparison with liver biopsy and aspartate transaminase platelet ratio index. *Aliment Pharmacol Ther* 2008;28:51-61.
18. Chung S, Kim KE, Park MS, Bhagavatula S, Babb J, Axel L. Liver stiffness assessment with tagged MRI of cardiac-induced liver motion in cirrhosis patients. *J Magn Reson Imaging* 2014;39:1301-1307.
19. Merboldt KD, Uecker M, Voit D, Frahm J. Spatially encoded phase-contrast MRI-3D MRI movies of 1D and 2D structures at millisecond resolution. *Magn Reson Med* 2011;66:950-956.
20. Axel L, Dougherty L. MR imaging of motion with spatial modulation of magnetization. *Radiology* 1989;171:841-845.
21. Watanabe H, Kanematsu M, Kitagawa T, Suzuki Y, Kondo H, Goshima S, et al. MR elastography of the liver at 3 T with cine-tagging and bending energy analysis: preliminary results. *Eur Radiol* 2010;20:2381-2389.