

Minimally Invasive Repair of Pectus Carinatum in Patients Unsuitable to Bracing Therapy

Jee-Won Suh, M.D., Seok Joo, M.D., Geun Dong Lee, M.D., Seok Jin Haam, M.D., Sungsoo Lee, M.D., Ph.D.

Background: We used an Abramson technique for minimally invasive repair of pectus carinatum in patients who preferred surgery to brace therapy, had been unsuccessfully treated via brace therapy, or were unsuitable for brace therapy because of a rigid chest wall. **Methods:** Between July 2011 and May 2015, 16 patients with pectus carinatum underwent minimally invasive surgery. **Results:** The mean age of the patients was 24.35 ± 13.20 years (range, 14–57 years), and all patients were male. The percentage of excellent aesthetic results, as rated by the patients, was 37.5%, and the percentage of good results was 56.25%. The preoperative and postoperative Haller Index values were 2.01 ± 0.19 (range, 1.60–2.31), and 2.22 ± 0.19 (range, 1.87–2.50), respectively (p -value=0.01), and the median hospital stay was 7.09 ± 2.91 days (range, 5–15 days). Only one patient experienced postoperative complications. **Conclusion:** Minimally invasive repair is effective for the treatment of pectus carinatum, even in adult patients.

Key words: 1. Minimally invasive surgery
2. Pectus carinatum
3. Adult
4. Chest wall deformity
5. Nuss operation

INTRODUCTION

Pectus carinatum and pectus excavatum are the most common morphological chest wall abnormalities. Pectus carinatum is characterized by anterior protrusion of the sternum and adjacent cartilage, and its reported incidence is 0.2%, with higher frequency in men than women [1].

Surgical and nonsurgical methods are available for treatment of pectus carinatum. The nonsurgical method involves external compression of the sternum using a brace. Bracing is generally the first option for treatment; if it fails, surgical correction can be considered [2]. The classic method for sur-

gical repair of chest deformities was described by Ravitch [3]. A modification of the Nuss procedure for pectus carinatum repair presented by Abramson [4] involves presternal placement of a metal bar attached to both sides of the chest wall, with metal plates for compressing the sternum. This minimally invasive surgical technique has proved to be very effective in children [5,6], and we have used it in patients who were not candidates for bracing therapy or for whom bracing therapy was ineffective. In the present study, we describe the outcomes achieved using a new minimally invasive technique for treatment of pectus carinatum.

Department of Thoracic and Cardiovascular Surgery, Gangnam Severance Hospital, Yonsei University College of Medicine

Received: July 21, 2015, Revised: September 27, 2015, Accepted: September 30, 2015, Published online: April 5, 2016

Corresponding author: Sungsoo Lee, Department of Thoracic and Cardiovascular Surgery, Gangnam Severance Hospital, 211 Eonju-ro, Gangnam-gu, Seoul 06273, Korea

(Tel) 82-2-2019-3381 (Fax) 82-2-3461-8282 (E-mail) CHESTLEE@yuhs.ac

© The Korean Society for Thoracic and Cardiovascular Surgery. 2016. All right reserved.

© This is an open access article distributed under the terms of the Creative Commons Attribution Non-Commercial License (<http://creativecommons.org/licenses/by-nc/4.0>) which permits unrestricted non-commercial use, distribution, and reproduction in any medium, provided the original work is properly cited.

METHODS

1) Patients

Since 2011, we have used a new minimally invasive surgical method for the treatment of pectus carinatum that includes a pectus bar and a stabilizing system (Hongseon Medical, Seoul, Korea). In this study, we applied this technique to 16 patients with pectus carinatum who were treated at Ajou University Hospital and Gangnam Severance Hospital between July 2011 and May 2015. Both symmetric and asymmetric types of pectus carinatum were included in the study. Because of the retrospective nature of the study, the need for informed patient consent was waived by the institutional review board.

2) Surgical technique

Surgery was performed under general anesthesia with single lumen intubation with muscular relaxation. The patient was placed in a supine position with both arms abducted.

(1) Incisions: To choose the location for the incisions, a horizontal line is drawn through the region with the greatest protrusion of the thoracic wall. The ribs most advantageous for placement of the pericostal wires are chosen. Bilateral transverse lateral thoracic incisions of approximately 2 cm are made at the midaxillary line.

(2) Pericostal wiring: The ribs are encircled subperiosteally with a Doyen rib raspator and then with an IV line to serve as a sheath for the steel wires to avoid a pneumothorax. Following the placement of the steel wires, the sheath is removed (Fig. 1A, B).

(3) Compressor bar: The appropriate length of the compressor bar is determined by measuring the distance between the two lateral regions where the fixation plates are secured after compressing the protruded sternum (Fig. 2). Once the pericostal wires have been passed around the ribs and the plates loosely fixed at the appropriate costal level, the compressor bar is bent into a convex configuration to adapt it to the thoracic wall. The introducer should be passed posterior to and then through the pectoralis major close to its origin near the sternum. This is the most difficult passage because the pectoralis major is in front of the sternum, and it may be necessary to tunnel from both the right and left. The bar is then

passed subcutaneously from one incision to the other in a complete extrathoracic route. The following steps facilitate safe passage of the bar: (1) careful insertion of the dissecting introducer, avoiding the pleural cavity (Fig. 1C); (2) passage of the chest tube over the introducer from one side to the other to guide the bar (Fig. 1D); (3) removal of the introducer from and subsequent insertion of the end of the compressor bar in the lumen of the chest tube; and (4) guidance of the curved bar from the lateral incision under the pectoralis major, through the muscle medially, into the subcutaneous space anterior to the sternum, back through the contralateral muscle to the space under the contralateral pectoralis major, and finally out the other lateral incision. Simultaneous with the passage of the bar, the protruded region is compressed to reduce resistance to the implant as it moves.

(4) Fixation plates: The fixation plates, which secure the compressor bar to the ribs, are placed in both midaxillary lines before inserting the compressor bar. The plates must be perpendicular to the horizontal line that connects both lateral incisions to align the compressor bar with the mounds of the plates. The compressor bar has three threaded holes at each end, and the fixation plates have two threaded holes in a central groove that enables sliding. Metal screws are guided into the holes and tightened with a screwdriver to secure the compressor bar to the fixation plates on each side (Fig. 1E).

(5) Docking the compressor bar with the fixation plates: Once the bar is correctly positioned, with the concavity facing posteriorly, the sternum is manually compressed. The three tip holes at the end of the compressor bar are matched with the two threaded holes on each side of the fixation plate, and both components are anchored using stainless steel screws (Fig. 1F). This attachment process is performed on both the lateral and contralateral sides, and the degree of compression is gradually increased on alternating sides. The pericostal wires are then firmly tightened at the appropriate costal level, along with manual compression of anterior chest wall.

The On-Q Pain Relief System with a fixed flow rate pump (Halyard Health, Alpharetta, GA, USA) was applied to the patient, and ropivacaine was additionally administered to most patients. The wounds were closed in layers using absorbable sutures. Chest radiography was then performed to check for a pneumothorax.

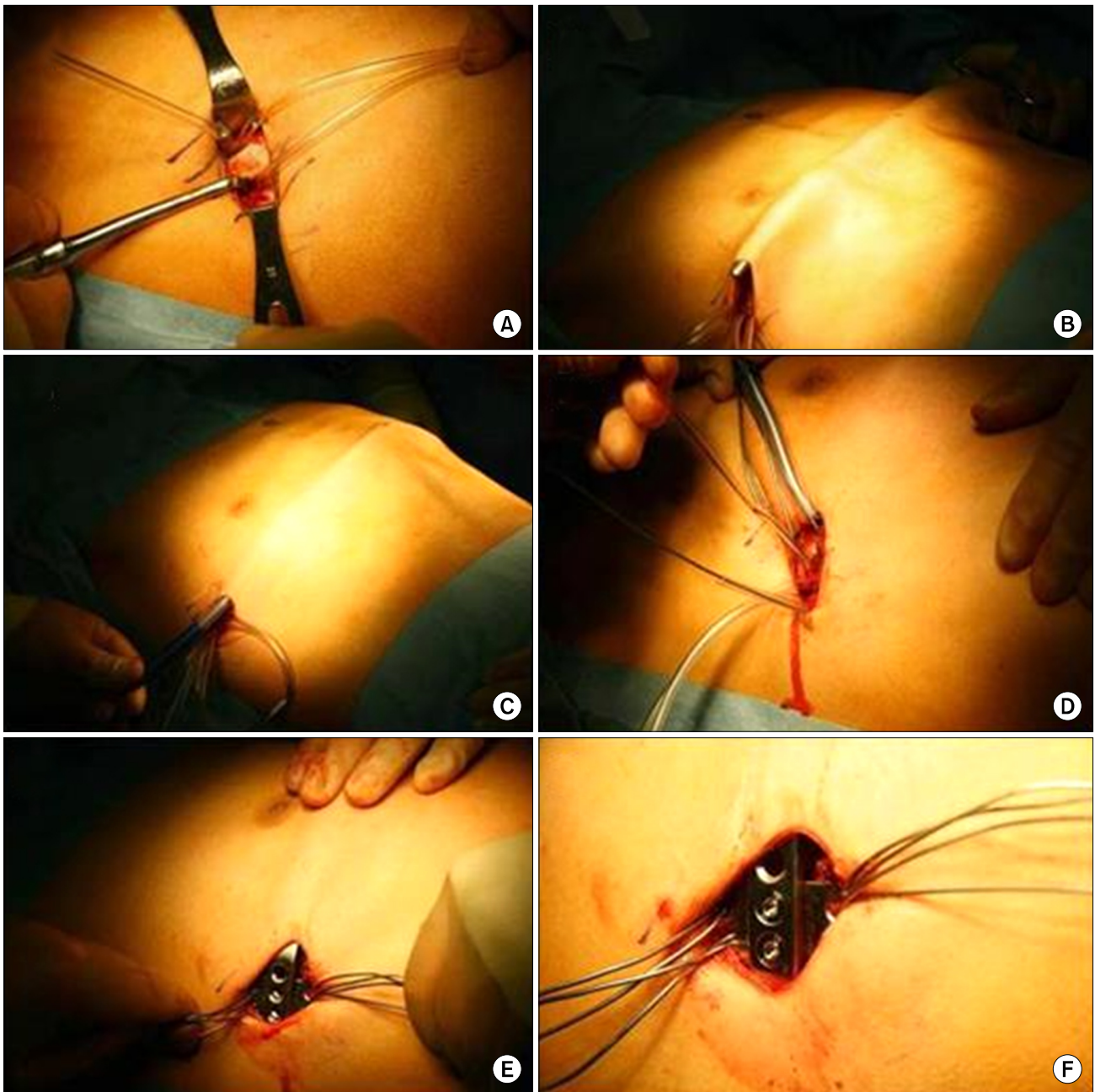


Fig. 1. Operative procedures. (A) Pericostal wiring using a Doyen rib raspator and an IV line. (B) The steel wires were placed through the IV line. (C) The introducer was passed posteriorly to the pectoralis major. (D) A chest tube was passed over the introducer. (E) Metal screws were used to secure the compressor bar to the fixation plates. (F) Before wire fixation.

3) Outcome

The length of the operation and hospital stay, postoperative pain score, and aesthetics were assessed. Postoperative pain was evaluated using a visual analog scale; patients were

asked by a nurse three times a day for the first two days postoperatively to rate their pain level from 0 to 10 (0=no pain, 10=worst pain). The patients also rated the aesthetic results as excellent, good, fair, or poor using a satisfaction questionnaire. All patients were evaluated every six months.




Fig. 2. The compressor bar and fixation plates. The compressor bar has three threaded holes at each end, and the fixation plates have two threaded holes in a central groove that enables sliding. (A) The anterior side of the compressor bar and fixation plate. (B) The posterior side of the compressor bar and the anterior side of the fixation plate. (C, D) Metal screws are guided into the holes and tightened with a screwdriver to secure the compressor bar to the fixation plate. (C) Anterior side. (D) Posterior side.

The implants were removed after 24 months.

4) Statistical analysis

Data were analyzed using IBM SPSS Statistics for Windows ver. 20.0 (IBM Co., Armonk, NY, USA). We used the Wilcoxon signed rank test to evaluate the statistical significance of the differences between the preoperative Haller Index and postoperative Haller Index. A p-value of less than 0.05 was considered statistically significant.

RESULTS

1) Patient characteristics

The study included 16 male patients, 11 with symmetric protrusions and 5 with asymmetric protrusions (Table 1). The mean age of the patients was 24.35 ± 13.20 years (range, 14 to

57 years). Of the 16 patients, 3 (18.75%) had been unsuccessfully treated using an orthotic brace, 4 (25%) preferred surgery to wearing a brace, and 9 (56.25%) chose surgery because of chest wall rigidity (three of these patients had previously received a brace). The reverse Nuss bar was removed from 11 patients (68.7%) at a mean time of 20.10 ± 6.70 months (range, 2.5 to 24.5 months) after surgery. The mean follow-up period was 23.50 ± 9.08 months (range, 10 to 39 months).

2) Outcome

The mean hospital stay duration was 7.09 ± 2.91 days (range, 5 to 15 days), the mean operation time was 111.27 ± 36.60 minutes (range, 62 to 188 minutes), and the mean postoperative pain score was 4.45 ± 1.03 (range, 4 to 6) on postoperative day 2 (Table 2). One patient developed a wound

seroma and an infection. The mean preoperative and postoperative Haller Index values were 1.97 and 2.35, respectively. Good aesthetic results were obtained overall, with 6 patients (37.5%), 9 patients (56.25%), 0 patients, and 1 pa-

tient (6.25%) rating the results as excellent, good, fair, and poor, respectively (Fig. 3).

The mean preoperative Haller Index value was 2.01 ± 0.19 (range, 1.60 to 2.31), and the mean postoperative Haller

Table 1. Patient characteristics (N=16)

Characteristic	Value
Age (yr)	24.35±13.20 (range, 14-57)
Sex	
Male	16
Female	0
Type of protrusion	
Symmetric	11 (68.80)
Asymmetric	5 (31.20)
Reason for surgery	
Brace failure	3 (18.80)
Preferred treatment	4 (25.00)
Rigid chest wall	6 (37.40)
Brace failure + rigid chest wall	3 (18.80)

Values are presented as mean±standard deviation or number (%).

Table 2. Perioperative data (N=16)

Operative procedure	Value
Reverse Nuss operation	16
Operative time (min)	111.27±36.60 (range, 62-188)
Operative complication	
Pneumothorax	-
Wound complication	-
Seroma	-
Skin erosion	-
Infection	1 (6.25)
Other	-
Pain score	4.45±1.03 (range, 3-6)
Length of hospital stay (day)	7.09±2.91 (range, 5-15)

Values are presented as mean±standard deviation or number (%).

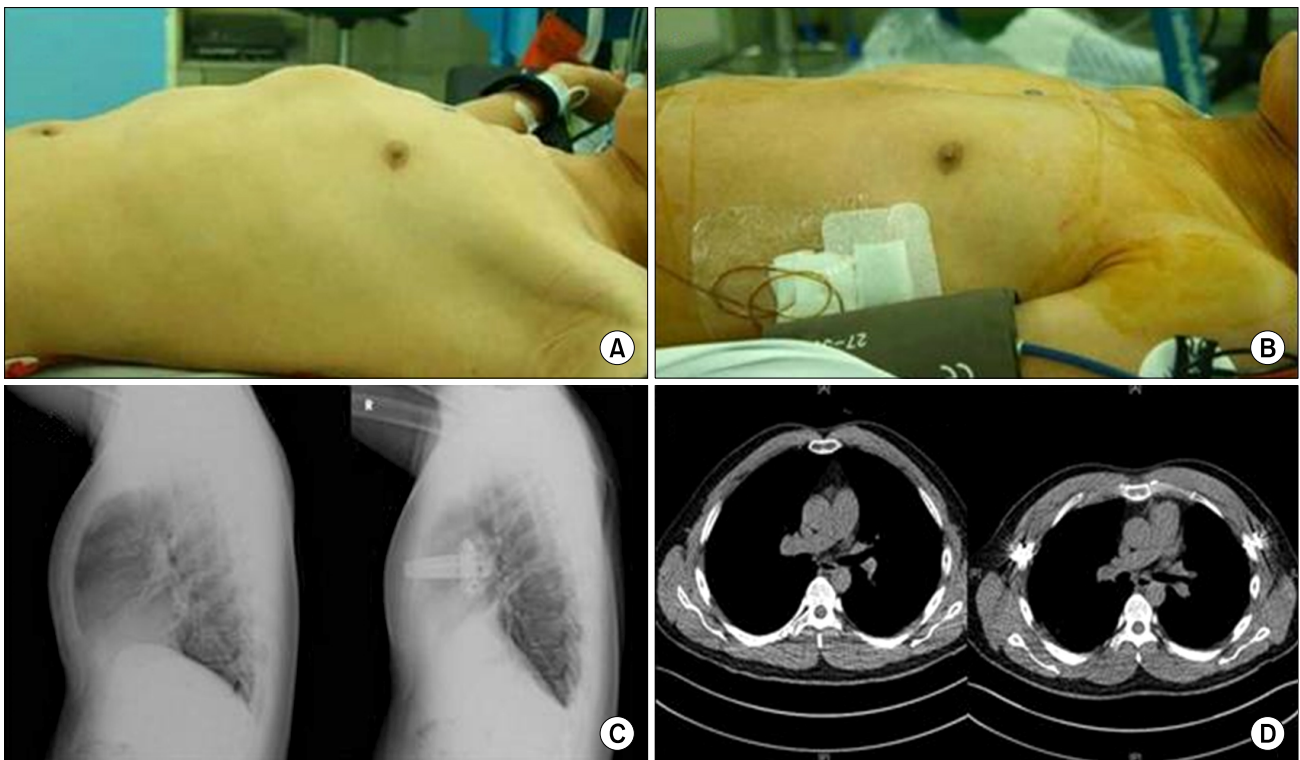


Fig. 3. Preoperative and postoperative findings. (A) A photograph of the anterior chest wall before surgery. (B) A photograph of the anterior chest after bar insertion. (C, D) Imaging shows improvement of the anterior protrusion of the chest wall after surgery. (C) Postoperative chest radiograph, lateral view. (D) Postoperative computed tomography.

Table 3. Preoperative and postoperative Haller Index

No.	Age (yr)/sex	Preoperative Haller Index	Postoperative Haller Index
1	22/M	2.08	2.17
2	17/M	2.00	2.34
3	14.5/M	1.90	2.05
4	14.2/M	2.29	2.36
5	19/M	2.00	2.23
6	21/M	1.88	2.05
7	14/M	1.60	1.87
8	15/M	2.31	2.48
9	25/M	2.12	2.36
10	53/M	1.96	2.05
11	34/M	2.14	2.50
12	57/M	2.03	2.26
13	30/M	1.84	2.11
Mean±standard deviation		2.01±0.19 (range 1.60–2.31)	2.22±0.19 (range 1.87–2.50)

M, male.

Index was 2.22 ± 0.19 (range, 1.87 to 2.50), which were significant different ($p=0.01$) (Table 3). We had missing data from three patients who did not undergo chest computed tomography or lateral X-ray.

DISCUSSION

Wearing a compression brace is a valid nonsurgical treatment for pectus carinatum and is generally the first option considered. For patients who have difficulties with brace compliance, surgical correction may be offered [7]. Lee et al. [8] reported that patient compliance influenced the success of brace therapy, and the causes of poor compliance included pain, embarrassment, and discomfort. Moreover, nonsurgical correction of chest wall deformity is not easy after puberty, and brace therapy often fails in older children [9].

Previous studies of minimally invasive surgical methods for treatment of pectus carinatum have yielded favorable results. Abramson [4] and Abramson et al. [5] presented a minimally invasive surgical method for treatment of pectus carinatum, which was feasible in children due to short operation and recovery times, reduced duration of hospitalization, and minimal blood loss. Improvements in the thoracic contour were evident, and the long-term outcome was reported to be very

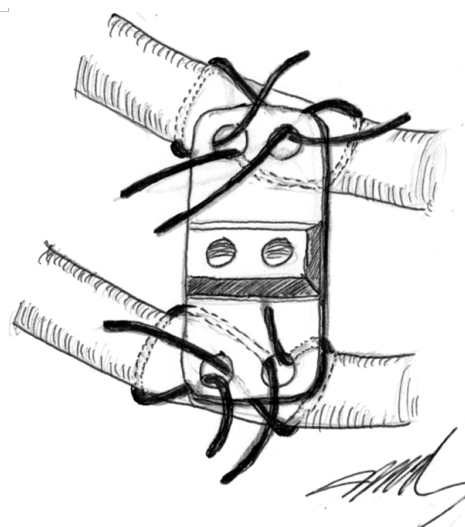


Fig. 4. A schematic drawing showing the attachment of the plate to the ribs. We used two wires for each rib (four wires per side) for more secure fixation.

good [5]. Yuksel et al. [6] also reported excellent aesthetic results using this method.

The mean age of the patients of 24.35 ± 13.20 years in the present study was higher than those reported in similar studies: 14.30 years [4], 14 years [6], and 15.70 years [10]. Nonetheless, our outcomes and results are similar to those of previous studies. After the growth spurt in adolescents, the chest wall cannot be easily modified via nonsurgical procedures, and these procedures therefore have a poor outcome in adults, as well as poor patient compliance. According to Yuksel et al. [6], the optimum age range for minimally invasive surgery is between 12 and 18 years, because the deformity is more prominent during the rapid growth phase of puberty and the chest wall is still flexible. In our study, only six patients were between 12 and 18 years; however, we were able to successfully treat adult patients with pectus carinatum and rigid chest walls via minimally invasive surgery. This finding is noteworthy because pectus carinatum is often not recognized until adolescent skeletal growth occurs, and many patients do not undergo treatment during childhood [11].

In the procedures described by Abramson et al. [5] and Yuksel et al. [6], the stabilizers containing the grooves for bar attachment and the two screw holes were placed perpendicularly on the ribs and secured with a total of four wires

for both sides. We used our own stabilizer and bar system and a total of eight wires to maintain fixation force on the rigid chest (i.e., two wires for each rib, four wires per side; Fig. 4). We consider our method to be effective in terms of preventing plate dislocation and wire breaks. Abramson et al. [5] reported wire breakage in three patients, as did Yuksel et al. [6], while Lee et al. [10] reported wire breakage in all patients in their study. In our study, there were no plate dislocation or wire problems.

We usually keep the bar in place for at least 2–3 years. In the present study, the reverse compression bar was removed in 11 patients (68.7%) at a mean time of 20.10±6.70 months (range, 2.5 to 24.5 months) after surgery. Because adult patients have more rigid chest walls than adolescents and poor chest wall compliance, Yuksel et al. [6] also tended to keep the bar in place for at least two years for better results. For patients older than 18 years, bar removal can be postponed until the end of the third or fourth year [6].

One patient experienced wound seroma and infection in our study. This patient received betadine-soaked dressing every day and was connected to a negative pressure pump unit (Curasys; CGBio, Seoul, Korea), and the compression bar was eventually removed at 75 days after surgery.

Our study has several limitations. First, the study sample size was too small to generalize the results. Second, we have only immediate and intermediate follow-up data, and long term follow-up data is needed.

In conclusion, minimally invasive surgery in adult patients was at least as effective as in children. Minimally invasive surgery for pectus carinatum should be considered as an alternative to invasive methods in appropriately selected adult patients.

CONFLICT OF INTEREST

No potential conflict of interest relevant to this article was reported.

ACKNOWLEDGMENTS

The authors would like to thank Nayoung Kim, RN and Hannah Na, RN (Nurse Practitioner, Department of Thoracic and Cardiovascular Surgery, Gangnam Severance Hospital, Seoul, Korea) for data analysis and data collection.

This study was supported by a Grant of the Samsung Vein Clinic Network (Daejeon, Anyang, Cheongju, Cheonan; Fund No. KTCS04-043).

REFERENCES

1. Cobben JM, Oostra RJ, van Dijk FS. *Pectus excavatum and carinatum*. Eur J Med Genet 2014;57:414-7.
2. Frey AS, Garcia VF, Brown RL, et al. *Nonoperative management of pectus carinatum*. J Pediatr Surg 2006;41:40-5.
3. Ravitch MM. *Unusual sternal deformity with cardiac symptoms operative correction*. J Thorac Surg 1952;23:138-44.
4. Abramson H. *A minimally invasive technique to repair pectus carinatum: preliminary report*. Arch Bronconeumol 2005;41:349-51.
5. Abramson H, D'Agostino J, Wuscovi S. *A 5-year experience with a minimally invasive technique for pectus carinatum repair*. J Pediatr Surg 2009;44:118-23.
6. Yuksel M, Bostanci K, Evman S. *Minimally invasive repair of pectus carinatum using a newly designed bar and stabilizer: a single-institution experience*. Eur J Cardiothorac Surg 2011;40:339-42.
7. Lakoma A, Kim ES. *Current readings: surgical repair experience of congenital chest wall deformities*. Semin Thorac Cardiovasc Surg 2013;25:317-22.
8. Lee RT, Moorman S, Schneider M, Sigalet DL. *Bracing is an effective therapy for pectus carinatum: interim results*. J Pediatr Surg 2013;48:184-90.
9. Desmarais TJ, Keller MS. *Pectus carinatum*. Curr Opin Pediatr 2013;25:375-81.
10. Lee SY, Song IH, Lee SJ. *Minimal invasive extrathoracic presternal compression using a metal bar for correction of pectus carinatum*. Pediatr Surg Int 2014;30:25-30.
11. Jaroszewski DE, Fonkalsrud EW. *Repair of pectus chest deformities in 320 adult patients: 21 year experience*. Ann Thorac Surg 2007;84:429-33.