



저작자표시-비영리-변경금지 2.0 대한민국

이용자는 아래의 조건을 따르는 경우에 한하여 자유롭게

- 이 저작물을 복제, 배포, 전송, 전시, 공연 및 방송할 수 있습니다.


다음과 같은 조건을 따라야 합니다:



저작자표시. 귀하는 원저작자를 표시하여야 합니다.



비영리. 귀하는 이 저작물을 영리 목적으로 이용할 수 없습니다.



변경금지. 귀하는 이 저작물을 개작, 변형 또는 가공할 수 없습니다.


- 귀하는, 이 저작물의 재이용이나 배포의 경우, 이 저작물에 적용된 이용허락조건을 명확하게 나타내어야 합니다.
- 저작권자로부터 별도의 허가를 받으면 이러한 조건들은 적용되지 않습니다.

저작권법에 따른 이용자의 권리는 위의 내용에 의하여 영향을 받지 않습니다.

이것은 [이용허락규약\(Legal Code\)](#)을 이해하기 쉽게 요약한 것입니다.

[Disclaimer](#) 

**The correlation between mandibular
repositioning and relapse of incisor inclination
after Class II surgical-orthodontic treatment**



Tae Young Kim

The Graduate School

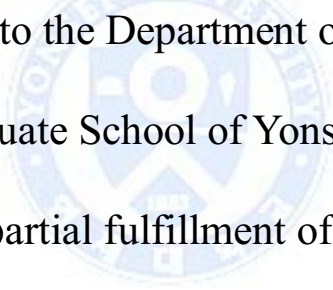
Yonsei University

Department of Dentistry

**The correlation between mandibular
repositioning and relapse of incisor inclination
after Class II surgical-orthodontic treatment**

A Masters Thesis

Submitted to the Department of Dentistry
and the Graduate School of Yonsei University
in partial fulfillment of the
requirements for the degree of
Master of Dental Science



Tae Young Kim

July 2015

This certifies that the masters thesis
of Tae Young Kim is approved.

Thesis Supervisor: Hyung-Seog Yu



Kee-Joon Lee

Jung-Yul Cha

The Graduate School

Yonsei University

July 2015

감사의 글

많은 분들의 격려와 도움이 있었기에 이번 논문을 완성할 수 있었습니다. 가장 먼저 부족한 저에게 아낌 없는 조언을 해주시고 전심으로 도움을 주신 지도 교수님, 유형석 교수님께 깊은 감사 드립니다. 교수님의 자상한 지도와 배려가 있었기에 여기까지 올 수 있었습니다. 또한, 날카로운 지적을 아낌없이 해주신 이기준 교수님과 꼼꼼히 지도 해주신 차정열 교수님께도 감사의 마음을 표합니다.

대학원과 더불어 일까지 함께 병행하며 시간에 쫓기던 저를 배려해주고 기다려준 가족과 친구들에게 감사합니다. 특히, 심적으로 힘들어할 때 옆에서 지지해주고 기둥이 되어준 남편에게 사랑하고 고맙다는 말을 꼭 전하고 싶습니다. 마지막으로 논문이 끝나기까지 잘 기다려주고 별다른 태교를 해주지 못 했는데도 건강하고 예쁜 모습으로 제 곁에 와준 딸에게도 사랑하고 고마운 마음을 전하고 싶습니다.

2015년 7월

김 태 영

Table of Contents

List of Tables and Figures	ii
Abstract (English)	iii
I. Introduction	1
II. Materials and Methods	5
1. Subjects.....	5
2. Cephalometric Analysis	6
3. Statistical Analysis	8
III. Results	9
1. Intraexaminer reliability.....	9
2. Key cephalometric measurements.....	10
3. Correlation evaluation	12
IV. Discussion	14
V. Conclusion	17
VI. References	18
Abstract (Korean)	20

List of Tables and Figures

Table 1. Mean and standard deviation for cephalometric measurements at each time point	10
Table 2. The changes between each time point from T1 through T4	11
Table 3. Correlation between; 1) counterclockwise rotation of the mandible (OP-SN T2-T1) and the incisor inclination relapse after deband (IMPA T4-T3 and U1-SN T4-T3), and 2) the amount of mandibular advancement (TVL-L1 T2-T1 and TVL-B T2-T1) and the incisor inclination relapse	12
Table 4. Correlation between; 1) post-surgical relapse of the mandibular rotation (FH-MP T4-T2) and the incisor inclination relapse after deband (IMPA T4-T3 and U1-SN T4-T3), and 2) the post-surgical relapse of the mandibular advancement (TVL-B T4-T2) and the incisor inclination relapse	12
Figure 1. Linear regression graph showing the correlation between post-surgical relapse of mandibular advancement (TVL-B T4-T2) and mandibular incisor inclination relapse after deband (IMPA T4-T3)	13
Figure 2. Linear regression graph showing the correlation between post-surgical relapse of mandibular advancement (TVL-B T4-T2) and maxillary incisor inclination relapse after deband (U1-SN T4-T3)	13

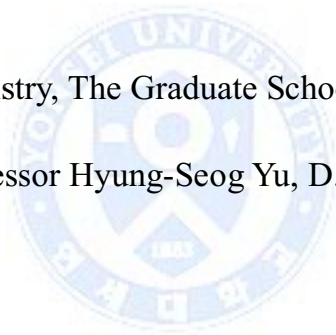
ABSTRACT

The correlation between mandibular repositioning and relapse of incisor inclination after Class II surgical-orthodontic treatment

Tae Young Kim, D.D.S

Department of Dentistry, The Graduate School, Yonsei University

(Directed by Professor Hyung-Seog Yu, D.D.S., M.S., Ph.D.)



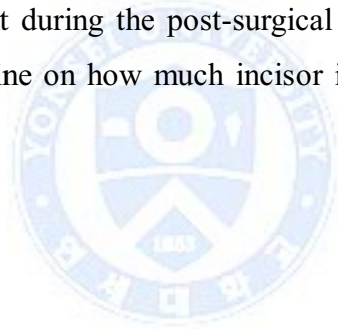
The objective of this study was to find the correlation between mandibular repositioning (mandibular counterclockwise rotation and mandibular advancement) and incisor inclination relapse observed after Class II surgical-orthodontic treatment during their six to twelve month follow-up. In addition, post-surgical skeletal relapse of the mandible was evaluated for its correlation with the following incisor inclination relapse after deband.

Twelve patients who underwent surgical-orthodontic treatment and bimaxillary orthognathic surgery, with either B-SSRO or B-VNSO, after being diagnosed as Class II malocclusion with mandibular retrognathism were evaluated.

Lateral cephalograms were measured at five time points; initial (T0), pre-surgery (T1), post-surgery (T2), deband (T3), and six to twelve month follow-up (T4).

Significant changes between each time points were evaluated using paired t-test. From this evaluation, it was noticeable that the skeletal and dental changes occurred mainly between time points T2 and T3, the post-surgical orthodontic treatment stage.

The correlation evaluation between the skeletal changes made during surgery and dental relapse showed no correlation. However, post-surgical skeletal relapse of mandibular advancement and dental relapse displayed significant correlation with each other. Based on such result, careful observation of the skeletal relapse of mandibular advancement during the post-surgical orthodontic treatment stage could provide some guideline on how much incisor inclination relapse to expect after deband.



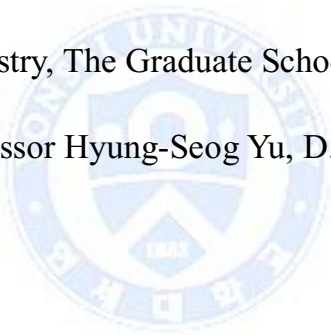
Key words: counterclockwise rotation, Class II orthognathic surgery, skeletal relapse, incisor relapse

The correlation between mandibular repositioning and relapse of incisor inclination after Class II surgical-orthodontics

Tae Young Kim, D.D.S

Department of Dentistry, The Graduate School, Yonsei University

(Directed by Professor Hyung-Seog Yu, D.D.S., M.S., Ph.D.)



I. Introduction

For those patients displaying mandibular deficiencies, contemporary orthodontics provides various treatment options, such as growth modification, camouflage orthodontic treatment, and orthognathic surgery. Skeletal Class II patients who are still in their growth stage may benefit from growth modification, which is a minimally invasive treatment. However, those past their growth spurt(s) can no longer expect correction of the mandibular deficiency using this technique. Camouflage orthodontic treatment can be an alternative in such cases, however,

camouflage orthodontic treatment results in limited improvement of esthetics and may possibly worsen function as dental conditions may need to be compensated even more. Hence, functional and esthetically fulfilling results for those past their adolescence mainly result from orthognathic surgery. Along with the fact that there is a higher demand for improved esthetics in the modern society, it is not unusual to find a greater number of patients desiring Class II orthognathic surgery, and thus, an increase in need of successful Class II surgical-orthodontic treatment.

Previously, Burden et al³ reported their study on investigating the treatment outcomes in Class II malocclusion cases treated with mandibular advancement surgery and identifying the predictors of favorable outcomes using multiple logistic regression. They found that good final overjet was found more likely in patients with larger initial ANB angles. Also, an ideal post-treatment ANB angle was achieved in female patients and those with larger initial ANB angles. Ideal soft tissue esthetics resulted from female patients with smaller initial SNA angles, and 28% of the total patients displayed incomplete mandibular incisor decompensation appearing mainly in females and patients with greater pretreatment mandibular incisor proclination. They also concluded that the use of mandibular surgery to correct anterior open bite was associated with poor outcomes.

Potts et al¹ examined the mean skeletal and dental cephalometric measurements and the treatment efficacy as a percentage of the ideal goal achieved in Class II subjects who underwent surgical-orthodontic treatment. Results showed that maxillary incisors were over-retracted pre-surgically and then returned to normal position post-surgically, while the mandibular incisors were proclined and protruded pre-surgically and remained so post-treatment. They also reported that the incisors were not ideally decompensated in many patients, coinciding with the previous findings by Proffit et al⁷ and Burden et al³.

Keeling et al² focused their study on the skeletal and dental stability in mandibular advancement surgery for up to two years follow-up, comparing conditions between rigid and wire fixation. They found that dental compensation occurred to maintain the ideal occlusion, where the mandibular incisor moved anteriorly in the wire group and posteriorly in the rigid group. However, at two years after surgery, the overjet and molar discrepancy had relapsed similarly in most subjects, regardless of the method of fixation.

The majority of the previous studies on the stability of Class II orthognathic surgery tended to focus on either the skeletal relapse following the skeletal changes made during surgery or the dental relapse following surgical-orthodontic treatment changes. However, a question aroused as to whether the skeletal change can serially influence not only the skeletal stability but also relapse in the dentition. If this is to be true, it would be meaningful to provide a guideline to act as a predictor for the future relapse to occur, making it possible for the orthodontist to prevent or be prepared for the expected relapse.

To correct a Class II mandibular deficiency, the mandible needs to be rotated in a counterclockwise direction and/or be advanced; the reason why these surgical procedures were studied in this research. In detecting the relapse of the dentition, the change in incisor inclination was used, since inclination change could be detected in a lateral cephalogram and can express dental relapse without the influence of skeletal displacement. Overjet, for example, is a dental change which could act as an indicator of dental relapse but is also influenced by skeletal displacement.

The purpose of this study was to find the correlation between mandibular repositioning carried out during Class II orthognathic surgery and incisor inclination relapse observed after Class II surgical-orthodontic treatment during

their six to twelve month follow-up, along with the correlation between post-surgical skeletal relapse of these mandibular changes and incisor inclination relapse.



II. Materials and Methods

1. Subjects

The study group consisted of twelve patients (two male, ten female) who were diagnosed as Class II malocclusion with mandibular retrognathism at the Department of Orthodontics, Dental College Hospital, Yonsei University, and had undergone bimaxillary orthognathic surgery using either B-SSRO (Bilateral Sagittal Split Ramus Osteotomy) or B-VNSO (Bilateral Vertical and Sagittal Osteotomy; a modification of B-SSRO), including counterclockwise rotation of the mandible between the years 2005-2013. Advancement genioplasty was carried out in nine of the twelve subjects. All subjects were non-growing adults past their cervical vertebrae maturation stage of 5 or 6. Their mean initial age was 21.58 years (SD 3.60 years). The subjects were selected according to the following inclusion criteria:

- (1) Had standardized lateral cephalograms at all five time points
- (2) Absent of any craniofacial anomalies, syndromes, or severe asymmetry
- (3) Undergone bimaxillary orthognathic surgery using either B-SSRO or B-VNSO, including counterclockwise rotation of the mandible, by the same surgeon
- (4) Undergone pre-surgical orthodontics with no extractions in the maxilla and premolar extractions in the mandible

The subjects displayed normal skeletal maxillary cephalometric values (SNA) with a sagittal mandibular deficiency (small SNB), resulting in a large ANB value.

The study group was restricted to those who had undergone mandibular counterclockwise rotation so the initial average mandibular plane angle (FH-MP) was much greater than the normal value. The large anterior facial height and small posterior facial height led to a smaller facial height ratio. The mean maxillary and mandibular incisor inclinations were close to their normal values, with the maxillary incisor inclination slightly smaller and the mandibular incisor inclination slightly larger than their normal values. Thus, the interincisal angle was found to be smaller than the normal value. The mean overjet was large (4.93 ± 1.65 mm), coinciding with the findings of many high angle Class II patients, and the mean overbite was small (1.55 ± 1.81 mm), with one subject displaying negative overbite (openbite).

2. Cephalometric Analysis

Lateral cephalograms were taken with the same cephalostat (CRANEX® 3+ CEPH, Soredex Orion Corporation, Helsinki, Finland) in natural head position, under the same exposure conditions of 10mA, 75kV, and varying exposure time of 0.8 seconds and 0.6 seconds for male and female subjects, respectively. These lateral cephalograms were traced by one trained person, identifying 54 landmarks using V-Ceph™ 5.5 (OSSTEM Inc., Seoul, Korea).

All subjects had lateral cephalometric radiographs at five time points; initial (T0), pre-surgery (T1), post-surgery (T2), deband (T3), and six to twelve month follow-up (T4).

The amount of counterclockwise rotation of the mandible carried out during the surgery was measured at the level of occlusal plane (OP-SN: the angle between the mandibular occlusal plane and SN line), as did many previous

studies^{6,8}. This was preferred over the mandibular plane angle since genioplasty was carried out during surgery in nine of the subjects, hence, the mandibular plane was no longer considered to be reproducible. The occlusal plane was constructed as the horizontal line connecting the mandibular incisal tip and distal cusp tip of the mandibular second molar, a method used by Hwang et al⁶. Although the occlusal plane is also bound to change during orthodontic treatment, the patient charts were reviewed to confirm that no major changes were made to the occlusion that may affect the occlusal plane between time points T1 and T2, the two time points at which the occlusal plane needed to act as a reference plane. The mandibular plane angle (FH-MP) was used to measure the post-surgical skeletal relapse since the landmarks were no longer bound to change. A true vertical line (TVL) was drawn to act as a vertical reference line, formed as a vertical line through sella, perpendicular to a true horizontal line which was constructed at SN minus 7°. The amount of mandibular advancement was measured using two methods; 1) perpendicular distance from TVL to mandibular incisal tip (L1: a dental reference point), and 2) perpendicular distance from TVL to B point (B: a skeletal reference point). TVL to B point is considered to be more reliable in terms of measuring skeletal changes, as the B point is a stable skeletal reference point which is not affected by the genioplasty. However, the plate and screw used to stabilize the fragment in genioplasty was, in some cases, placed over the B point, making it difficult to replicate the same reference point. Hence, for additional reliability of the measurement, a dental reference point, mandibular incisal tip, was used in addition to back up the measurement.

To verify intraexaminer reliability, all cephalometric radiographs were re-traced and re-measured with a two-week interval by the same person.

3. Statistical Analysis

All statistical analysis was evaluated using the IBM SPSS Statistics ver. 21 (IBM Corp., New York, United States) with the significance assessed at $P < 0.05$.

Intraclass correlation coefficient was used to verify the intraexaminer reliability of the measured cephalometric values. Paired t-tests were performed to evaluate the surgical changes (T2-T1), post-surgical orthodontic changes (T3-T2), and relapse (T4-T3). The correlations between measurements were evaluated using the linear regression analysis.



III. Results

The intraclass correlation coefficient was greater than 0.95 for all the values measured.

The mean and standard deviation for certain cephalometric measurements were selected to show the skeletal and dental characteristics of the subjects at each time point (Table 1).

The result of the paired t-test carried out to evaluate the significance of the mean changes for the cephalometric measurements between each time point from T1 through to T4 is shown in Table 2.




Table 1. Mean and standard deviation for cephalometric measurements at each time point.

	T0		T1		T2		T3		T4	
	Mean	SD	Mean	SD	Mean	SD	Mean	SD	Mean	SD
Skeletal										
SNA (°)	79.00	3.75	79.34	3.38	77.91	3.50	78.04	3.49	78.04	3.49
SNB (°)	71.95	3.74	72.82	3.74	76.82	3.93	75.50	3.96	74.62	3.69
ANB (°)	7.05	1.15	6.52	1.49	1.09	2.14	2.63	2.89	3.41	2.52
FH-MP (°)	39.66	3.98	39.49	4.10	34.46	4.13	37.22	4.48	37.27	4.37
AFH (mm)	136.70	5.71	137.96	9.63	135.69	9.83	133.42	5.86	134.71	9.94
PFH (mm)	76.38	6.24	77.78	8.99	80.34	7.56	76.07	7.27	76.75	8.94
Facial height ratio	0.56	0.04	0.56	0.04	0.59	0.04	0.57	0.05	0.57	0.05
TVL-L1 (mm)	66.19	6.61	63.83	7.24	69.32	7.11	66.36	6.25	71.93	3.99
TVL-B (mm)	49.86	7.98	50.78	8.49	58.86	8.95	56.88	8.31	55.38	8.19
Dental										
IMPA (°)	97.37	6.35	88.28	11.45	78.02	7.10	84.46	8.58	86.38	9.12
U1-SN (°)	100.26	5.07	100.12	4.89	102.84	6.56	98.88	9.34	97.74	7.90
Interincisal angle (°)	113.50	6.76	123.23	9.97	126.77	6.33	130.05	5.43	129.85	7.01
OP-SN (°)	27.30	3.62	25.94	3.99	19.89	5.93	21.80	7.09	22.75	6.48
Overjet (mm)	4.93	1.65	9.44	2.70	2.32	0.84	4.01	1.30	4.49	1.17
Overbite (mm)	1.55	1.81	2.25	2.83	1.38	1.11	2.88	1.33	2.79	1.85

Table 2. The changes between each time point from T1 through T4.

	T2-T1 During surgery		T3-T2 Post-surgical orthodontic treatment		T4-T3 Post-treatment retention	
	Mean	SD	Mean	SD	Mean	SD
Skeletal						
SNA (°)	-1.43 *	1.86	0.13 *	0.18	0.00	1.19
SNB (°)	4.00	0.84	-1.31 **	1.42	-0.88 **	0.94
ANB (°)	-5.43	1.77	1.54 **	1.32	0.78 **	0.80
FH-MP (°)	-5.03 **	3.78	2.76 **	2.69	0.05	1.63
AFH (mm)	-2.27 **	2.16	-2.27	5.10	1.29	5.26
PFH (mm)	2.56 *	3.34	-4.27 **	4.24	0.68	3.73
Facial Height ratio	0.03 **	0.02	-0.02 **	2.61	-0.09	1.24
TVL-L1 (mm)	5.48	2.48	-2.96 **	3.64	5.57	4.13
TVL-B (mm)	8.08	1.35	-1.98 *	3.51	-1.49 *	2.01
Dental						
IMPA (°)	-0.33	8.03	-2.56	5.10	1.91 *	3.33
U1-SN (°)	2.72 *	4.84	-3.96 **	4.94	-1.14	2.93
Interincisal angle (°)	3.54	7.79	3.28 *	5.46	-0.20	4.34
OP-SN (°)	-6.05	2.98	1.77 *	3.47	0.95 *	1.62
Overjet (mm)	-7.13	2.75	1.69 **	1.50	0.48	1.28
Overbite (mm)	-0.88	2.78	1.50 **	1.62	-0.08	1.06

* p<0.05

** p<0.01

The correlation between the counterclockwise rotation of the mandible (OP-SN T2-T1) carried out during the surgery and the incisor inclination relapse (IMPA T4-T3 and U1-SN T4-T3) was evaluated, as shown in Table 8. No statistically significant correlation was found between these parameters. The amount of mandibular advancement measured using two different measurements (TVL L1 T2-T1 and TVL-B T2-T1) and their correlation with the incisor inclination relapse was also found to have no statistical significance (Table 3).

Table 3. Correlation between; 1) counterclockwise rotation of the mandible (OP-SN T2-T1) and the incisor inclination relapse after deband (IMPA T4-T3 and U1-SN T4-T3), and 2) the amount of mandibular advancement (TVL-L1 T2-T1 and TVL-B T2-T1) and the incisor inclination relapse.

	IMPA T4-T3		U1-SN T4-T3	
	<i>P value</i>	<i>r²</i>	<i>P value</i>	<i>r²</i>
OP-SN T2-T1	0.17	0.174	0.88	0.002
TVL-L1 T2-T1	0.12	0.223	0.18	0.169
TVL-B T2-T1	0.07	0.286	0.69	0.017

* **p<0.05**

In order to successfully relate and observe the correlation between skeletal changes and dental relapse, it was also necessary to observe the correlation between the post-surgical skeletal relapse in mandibular rotation and advancement and the incisor inclination relapse after deband. This is shown in table 4. The post-surgical relapse of mandibular rotation had no correlation with the incisor inclination relapse. However, relapse in mandibular advancement was significantly correlated with both maxillary and mandibular incisor inclination relapse, with the p-value of 0.02 and 0.005, respectively.

Table 4. Correlation between; 1) post-surgical relapse of the mandibular rotation (FH-MP T4-T2) and the incisor inclination relapse after deband (IMPA T4-T3 and U1-SN T4-T3), and 2) the post-surgical relapse of the mandibular advancement (TVL-B T4-T2) and the incisor inclination relapse.

	IMPA T4-T3		U1-SN T4-T3	
	<i>P-value</i>	<i>r²</i>	<i>P-value</i>	<i>r²</i>
FH-MP T4-T2	0.61	0.026	0.69	0.016
TVL-B T4-T2	0.005 **	0.547	0.02 *	0.413

* **p<0.05**

** **p<0.01**

The figures 1 and 2 are the linear regression graphs of the correlation between post-surgical relapse of mandibular advancement (TVL-B T4-T2) and the mandibular and maxillary incisor inclination relapse, respectively.

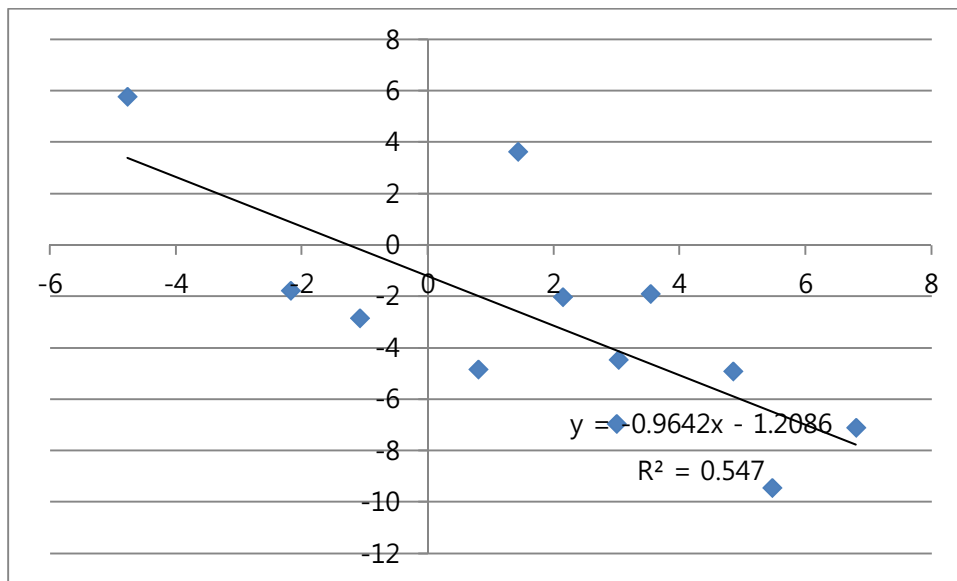


Figure 1. Linear regression graph showing the correlation between post-surgical relapse of mandibular advancement (TVL-B T4-T2) and relapse of mandibular incisor inclination after deband (IMPA T4-T3). * X-axis : mandibular incisor inclination relapse (°), Y-axis : post-surgical relapse of mandibular advancement (mm).

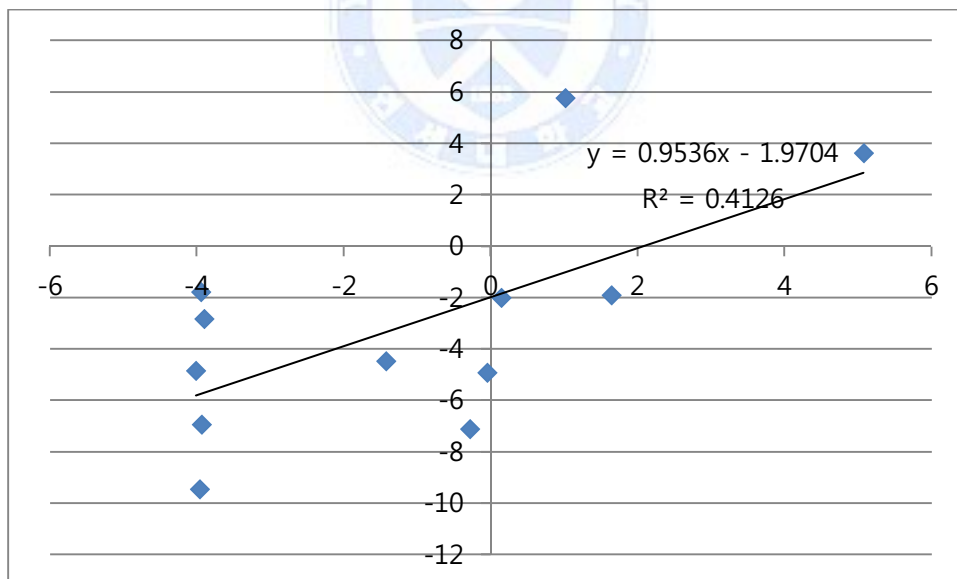


Figure 2. Linear regression graph showing the correlation between post-surgical relapse of mandibular advancement (TVL-B T4-T2) and relapse of maxillary incisor inclination after deband (U1-SN T4-T3). * X-axis : maxillary incisor inclination relapse (°), Y-axis : post-surgical relapse of mandibular advancement (mm).

IV. Discussion

Conventional cephalometric radiograph was the means for measurement used in this study. However, newer radiographic images such as conebeam CT, or perhaps an additional means of measurement for a more precise detection of the changes could have been a good alternative. Due to the restricted nature of this study being carried out retrospectively, the widely used diagnostic data, the cephalometric radiograph, was the available image for use.

Class II division 2 subjects displaying retroclined upper incisors and low mandibular plane angles were excluded from this study to maintain the homogeneity of the subjects, as they had undergone clockwise rotation of the mandible during surgery. Comparable studies^{2,3,5} generally used subjects of both Class II division 1 and 2 subjects, which may well have affected the study results.

The majority of the subjects displayed initial skeletal cephalometric measurements that coincided with that of skeletal Class II patients. However, the mean maxillary and mandibular incisor inclination at T0 was close within normal range. This meant that the subjects had a large initial overjet, a general phenomenon that would also be evident in many Class II division 1 subjects and a good condition for maximum skeletal correction during the orthognathic surgery. Since the initial incisor inclination was already closely in the normal range, there was going to be less need for pre-surgical incisor inclination correction. Less dental movement would be favorable as it would reduce relapse from these orthodontic movements, allowing more expression of dental relapse caused by factors other than orthodontic movements, such as the influence of skeletal changes.

Using the occlusal plane angle to detect the amount of mandibular rotation that is carried out during the surgery is a method often chosen in many studies^{6,8}. In this study, the occlusal plane was constructed as the horizontal line connecting the mandibular incisal tip and distal cusp tip of the mandibular second molar, a method used by Hwang et al⁶. This was more reliable, than studies that used the occlusal plane as a bisecting line between maxillary and mandibular incisal tips and molars, in terms of detecting the mandibular rotation, as the reference points lay on the mandibular structures. However, when using the occlusal plane angle, it would be wiser to reduce the term between the pre-surgical and post-surgical records, making sure that no vast changes are made to the dentition that may affect the occlusal plane angle. The mean period between the pre-surgical record (T1) and post-surgical record (T2) was 50 days \pm 11 days for this study, where all of the post-surgical records were taken the day after surgery. Even though the patient charts were reviewed to make sure that no orthodontic movements were actively done within this period, some changes could still have occurred to alter the occlusal plane angle during this period.

Counterclockwise rotation of the mandible during orthognathic surgery is generally known to be more unstable, especially for those with temporomandibular joint diseases⁸. In 1969, Welch⁹ also stated that the greater the amount of mandibular advancement, the greater the magnitude of mandibular relapse. In addition, counterclockwise surgical rotation of the mandibular plane angle is stated to be associated with increased risk for long-term relapse among patients undergoing mandibular advancement¹⁰. The hypothesis that surgical changes could show correlation with the relapse of incisor inclination was denied. However, the post-surgical skeletal relapse of the mandibular advancement was found to have a significant correlation with both the maxillary and mandibular incisor inclination relapse after deband.

There was less correlation between the skeletal changes and the maxillary incisor inclination relapse, possibly because of two reasons; 1) the skeletal change in the maxilla was excluded from the study because a pilot study revealed that the surgical change in rotation and impaction of the maxilla was too small in most of the subjects, and 2) maxillary incisor inclination change was minor since maxillary premolars were not extracted.

Many of the previous studies^{1,3,7} focused on the insufficiency of presurgical decompensation leading to limited surgical correction of the skeletal discrepancy and hence, the skeletal relapse post-surgery. As orthodontists, the importance of considering the predictable skeletal changes cannot be denied, but more importantly, should be able to predict and prevent orthodontic relapse, where possible. This puts weight on the value of this study.

Further studies on orthodontic relapse in Class II surgical-orthodontic treatment using more advanced technologies, such as the cone beam CT and 3D printers, may be a good addition to the previous studies, further extending our knowledge on what dental changes are to be expected during and after Class II surgical-orthodontic treatment.

V. Conclusion


1. The counterclockwise rotation of the mandible and mandibular advancement showed no significant correlation with the incisor inclination relapse after Class II surgical-orthodontic treatment.
2. Post-surgical skeletal relapse of mandibular rotation had no correlation with incisor inclination relapse. However, post-surgical skeletal relapse of mandibular advancement showed significant correlation with both maxillary and mandibular incisor inclination relapse after deband.



VI. References

1. Potts B., Shanker S., Fields H., Vig K., Michael Beck F. Dental and Skeletal changes associated with Class II surgical-orthodontic treatment. *Am J Orthod Dentofacial Orthop* 2009; 135: 566.e1-566.e7.
2. Keeling S., Dolce C., Van Sickles J., Bays R., Clark G., Rugh J. A comparative study of skeletal and dental stability between rigid and wire fixation for mandibular advancement. *Am J Orthod Dentofacial Orthop* 2000; 117: 638-49.
3. Burden D., Johnston C., Kennedy D., Harradine N., Stevenson M. A cephalometric study of Class II malocclusion treated with mandibular surgery. *Am J Orthod Dentofacial Orthop* 2007; 131: 7.e1-7.e8.
4. Potts B., Fields H., Shanker S., Vig K., Michael Beck F. Dental and skeletal outcomes for Class II surgical-orthodontic treatment : A comparison between novice and experienced clinicians. *Am J Orthod Dentofacial Orthop* 2011; 139: 305-15.
5. Mobarak K., Espeland L., Krogstad O., Lyberg T. Mandibular advancement surgery in high-angle and low-angle Class II patients: different long-term skeletal responses. *Am J Orthod Dentofacial Orthop* 2001; 119: 368-81.
6. Hwang S., Haers P., Zimmermann A., Oechslin C., Siefert B., Sailer H. Surgical risk factors for condylar resorption after orthognathic surgery. *Oral Surg Oral Med Oral Pathol Oral Radiol Endod* 2000; 89: 542-52.

7. Proffit WR, Phillips C, Douvartzidis N. A comparison of outcomes of orthodontic and surgical orthodontic treatment of Class II malocclusion in adults. *Am J Orthod Dentofacial Orthop* 1992; 101: 556-65.
8. Gonçalves JR, Cassano DS, Wolford LM, Santos-Pinto A, Márquez IM. Post-surgical stability of counterclockwise maxillomandibular advancement surgery: affect of articular disc repositioning. *American association of oral and maxillofacial surgeons. J Oral Maxillofac Surg* 2008; 66: 724-738.
9. Welch TB. Stability in the correction of dentofacial deformities: A comprehensive review. *J Oral Maxillofac Surg* 1989; 47: 1142-1149.
10. Frey DR, Hatch JP, Van-Sickels JE, Dolce C, Rugh JD. Alteration of the mandibular plane during sagittal split advancement: short- and long-term stability. *Oral Surg Oral Med Oral Pathol Oral Radiol Endod* 2007; 104: 160-9.



국문요약

제 II급 수술 교정 시 하악골의 위치 변화와 전치 치축 각도의 재발 간의 상관관계 분석

연세대학교 대학원 치의학과

(지도 유형석 교수)

김 태 영

본 연구의 목적은 제 II급 부정교합 환자의 악교정수술 시 시행된 하악골의 반시계 방향 회전 및 하악골 전진술과 제 II급 수술교정 후 6-12개월 추적 관찰 시 나타난 상하악 전치 치축 재발 간의 상관관계를 분석하는 것이다. 그리고, 수술 중에 이루어진 변화뿐만 아니라 수술 후에 나타나는 골격적 변화와 상하악 전치 치축 재발 간의 상관관계를 보기 위해 하악골의 회전이나 전진의 재발과 상하악 전치 치축 재발 간의 상관관계를 분석하였다.

하악골 후퇴증을 동반한 제 II급 부정교합으로 진단된 후 수술 교정 및 악교정수술을 받은 12명의 환자들을 대상으로, 초기 교정 치료 전 (T0), 수술 전 (T1), 수술 후 (T2), 교정 치료 완료 (T3), 그리고 6-12개월 추적관찰 (T4)

시점으로 총 다섯 시점에서 측모 두부방사선 사진을 계측하여 다음과 같은 결과를 얻었다.

1. T1에서 T4까지 각 시점 사이에 나타난 주요 계측치들의 변화량을 분석한 결과 골격적, 그리고 치성 변화는 주로 T2와 T3 사이인 술 후 교정 치료 중에 많이 나타났다.
2. 선형 회귀분석을 통한 분석결과, 제 II급 부정교합 환자의 악교정수술 시 시행된 하악골의 반시계 방향 회전이나 하악골의 전진은 교정 후 6-12개월 추적관찰 시 나타난 전치 치축 재발과 유의한 상관관계를 보이지 않았다. 하지만, 수술 후에 나타난 하악골 전진의 재발은 상하악 전치 치축 재발과 유의한 상관관계를 나타내었다.

따라서, 위와 같은 결과에 입각하여 교정 치료 후에 나타날 것으로 예상되는 상하악 전치 치축의 재발은 수술 중에 이루어진 골격적 변화보다는 수술 후 교정 치료 중에 나타나는 하악골 전진의 재발을 유심히 관찰하는 것으로 예측할 수 있을 것으로 사료된다.

핵심 되는 말: 반시계 회전, 제 II급 악교정수술, 수술 후 재발, 전치 재발