

말초동맥 폐쇄 환자에서 경피적 경혈관 중재술 시행 후 발생한 구획 증후군 2예

정재현 · 민필기 · 구분권 · 권기환 · 고영국 · 변영섭 · 최동훈

Two Cases of Compartment Syndrome Complicating Percutaneous Transluminal Peripheral Arterial Intervention

Jae Hun Jung, MD, Pil-Ki Min, MD, Bon Kwon Koo, MD, Kihwan Kwon, MD, Young Guk Ko, MD, Young Sub Byun, MD and Donghoon Choi, MD

Yonsei Cardiovascular Center and Cardiovascular Research Institute, Yonsei University College of Medicine, Seoul, Korea

ABSTRACT

Compartment syndrome is the term used to describe the constellation of clinical symptoms and signs associated with pathophysiologically elevated intracompartmental pressure. It is an infrequent but serious complication of the revascularization of peripheral arterial disease, encountered in surgical bypass and thrombolytic procedures. We present two cases of intraarterial thrombolysis and percutaneous transluminal intervention of the lower extremity arteries, complicated by the development of compartment syndrome. (**Korean Circulation J 2002;32(5):442-446**)

KEY WORDS : Peripheral vascular diseases ; Angioplasty, balloon ; Compartment syndromes.

서 론

가

가 가 가 2

: 2002 2 14

: 2002 4 3

: , 120 - 752

134

증 례

증 례 1 :

59 가 11

150 m

: (02) 361 - 7259 · : (02) 393 - 2041
E - mail : cdhlyj@yumc.yonsei.ac.kr

(Fig. 1).

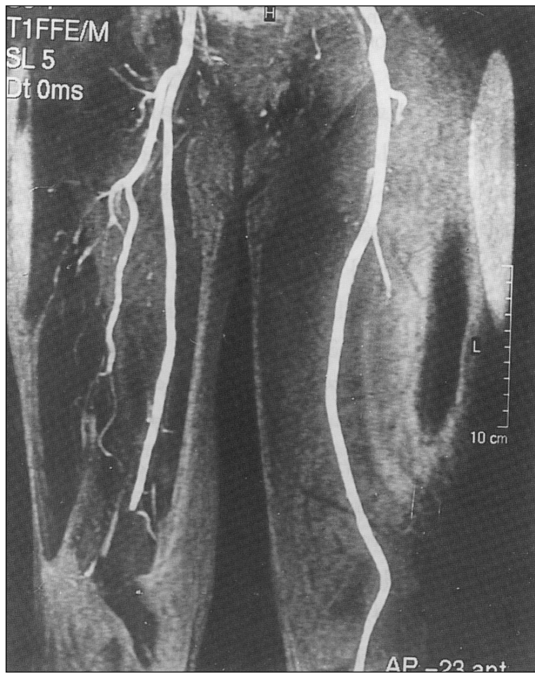


Fig. 1. MR angiography revealed total occlusion of right popliteal artery.

40

50%

60%

40%

7

10

18

10% 40%

(7 × 60 mm, SMART®, Cordis Co., Miami, FL, USA)

(Fig. 2).

20

40.6 cm,

35.6 cm)

4

creatinine kinase가 8,499 IU/L 가

creatinine kinase가

18

3

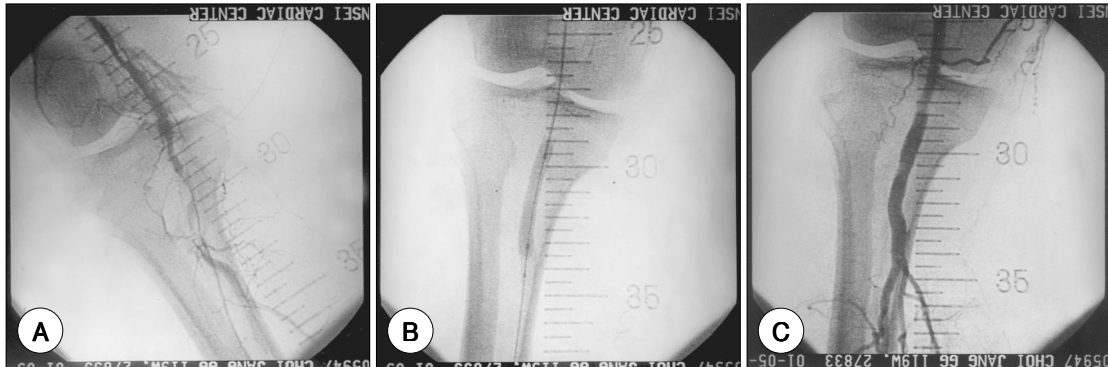

Fig. 2. After balloon angioplasty, peripheral angiography revealed residual stenosis at right (A). Smart stent 7 × 60 mm was deployed at distal popliteal artery to posterior tibial artery (B). Follow up angiography revealed no residual stenosis and good distal flow (C).

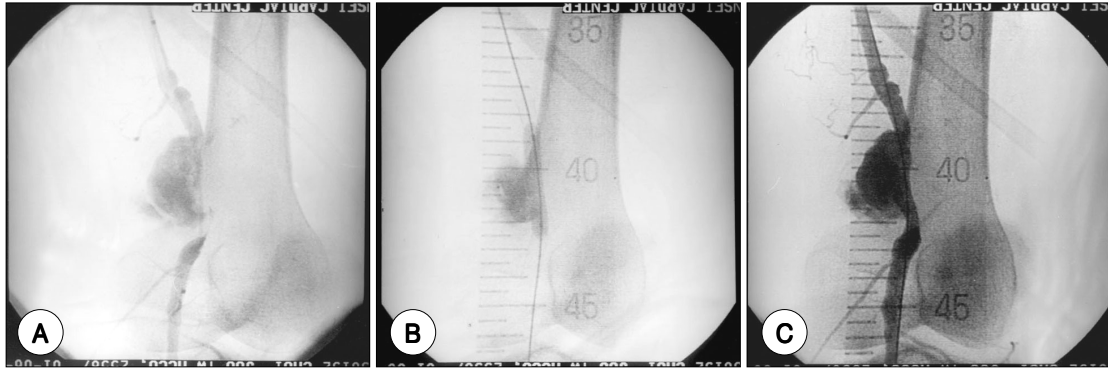


Fig. 3. Peripheral angiography revealed much thrombi burden in the aneurysm and subtotal occlusion at distal superficial femoral artery (A). Smart stent 7 × 80 mm was deployed at distal superficial femoral artery (B). Follow up angiography revealed no residual stenosis and good distal flow (C).

plethysmography ankle-brachial index (ABI) 1.24 1.27

stent graft

5 1, 2, 3, 4 checkrein

deformity talar coalition 8 10 24

(right flexor digitorum longus Z-plasty lengthening flow

) Checkrein de-

formity (7 × 80 mm, SMART[®], Cordis Co., Miami, FL, USA)

(Fig. 3).

증례 2 :

35 가 4 1

2 가 41 cm 가 cre-

atinine kinase 8,419 IU/L 가

11 34

가

6

가

3 34.7 cm , creatinine kinase 436

가 IU/L

가 st-

ent graft(Passager 12 × 100 mm, Meadox[®], Boston Scientific Co., Watertown, Massachusetts, USA)

고찰

peripheral arterial disease

, 1964 Dotter

Judkins¹⁾ 가 rdiner⁸⁾ 가⁶⁾⁷⁾ Ga-

(revascularization)

2)3) 0% 4.1% 9)10)

4) (re- anterior ti-

perfusion syndrome) bial, lateral tibial, deep posterior, superficial post-
erior 4 가

가 가 가

(Table 1).

가 가

가 가 가⁵⁾ 가

Table 1. Contents of the fascial compartments of the leg and associated symptoms of compartment syndrome affecting each compartments¹⁾

Anterior tibial	Lateral tibial	Deep posterior	Superficial posterior
Muscles			
Tibialis anterior	Peroneus longus	Flexor digitorum longus	Gastrocnemius
Extensor digitorum longus	Peroneus brevis	Tibialis posterior	Soleus
Extensor hallucis longus		Flexor hallucis longus	Plantaris
Peroneus tertius		Popliteus	
Vessels			
Anterior tibial artery		Peroneal artery	
		Posterior tibial artery	
Nerves			
Deep peroneal	Superficial peroneal	Tibial	Medial sural cutaneous
Signs and Symptoms			
Pain on passive motion of above muscles "Foot drop"	Pain on passive motion of above muscles Weakness of erosion, abduction of the foot	Pain on passive motion of above muscles Mild weakness of plantar flexion, graet toe flexion	Pain on passive motion of above muscles Weakness of plantar flexion with inability to raise on ties
Hypoesthesia in dorsal web space between first and second toes	Hypoesthesia over dorsum of foot	Anterior displacement of femur on tibia while standing with knee flexed Hypoesthesia over plantar aspect of foot	the sural nerve lies outside the fascial envelope of the superficial posterior compartment, and there is no sensory loss in its distribution with compartment syndrome

Sheridan ¹²⁾
66 (,)

12
12
12 (5.3)
22 68%

15
, 32% 7
, 12
2 (8%)
, 22 (92%)

12
, 12
21%

1 critical limb ischemia

가 ¹³⁾ 2

요 약

중심 단어 : ; ;

REFERENCES

- 1) Dotter CT, Judkins MP. *Transluminal treatment of arteriosclerotic obstruction: description of a new technic and a preliminary report of its application. Radiology 1989; 172:904-20.*
- 2) Capek P, McLean GK, Berkowitz HD. *Femoropopliteal angio-plasty: factors influencing long-term success. Circulation 1991;83(Suppl):170-80.*
- 3) Tunis SR, Bass EB, Steinberg EP. *The use of angioplasty, bypass surgery, and amputation in the management of peripheral vascular disease. N Engl J Med 1991;325: 556-62.*
- 4) Varty K, Nydahl S, Butterworth P, Errington M, Bolia A, Bell PR, London NJ. *Changes in the management of critical limb ischemia. Br J Surg 1996;83:953-6.*
- 5) Perry MO. *Compartment syndromes and reperfusion injury. Surg Clin North Am 1988;68:853-64.*
- 6) Matsen FA 3rd, Winquist RA, Krugmire RB Jr. *Diagnosis and management of compartmental syndromes. J Bone Joint Surg 1980;62:286-91.*
- 7) Johansen K, Watson J. *Compartment syndrome: new insights. Semin Vasc Surg 1998;11:294-301.*
- 8) Gardiner GA Jr, Koltun W, Kandarpa K, Whittemore A, Meyerovitz MF, Bettmann MA, Levin DC, Harrington DP. *Thrombolysis of occluded femoropopliteal grafts. AJR 1986;147:621-6.*
- 9) McNamara TO, Bomberger RA, Merchant RF. *Intra-arterial urokinase as the initial therapy for acutely ischemic lower limbs. Circulation 1991;83(Suppl): 106-19.*
- 10) Durham JD, Geller SC, Abbott WH, Shapiro H, Waltman AC, Walker TG, Brewster DC, Athanasoulis CA. *Regional infusion of urokinase into occluded lower extremity bypass grafts: long-term clinical results. Radiology 1989; 172:83-7.*
- 11) Reuss PM, Rosen RJ, Adelman M. *Compartment syndrome complicating lower extremity thrombolysis. J Vasc Interv Radiol 1999;10:1075-82.*
- 12) Sheridan GW, Matsen FA 3rd. *Fasciotomy in the treatment of the acute compartment syndrome. J Bone Joint Surg 1976;58:112-5.*
- 13) Dormandy JA, Rutherford RB. *Management of peripheral arterial disease (PAD). J Vasc Surg 2000;31:S1-296.*