

# 후측방으로 탈출된 경추 디스크의 후방 미세간공천개절제술의 치료결과

김영수 · 구성욱 · 진병호 · 조용은 · 진동규

= Abstract =

## The Result of Posterior Microforaminotomy for Posterolateral Herniation of Cervical Discs

Young Soo Kim, M.D., Sung Uk Kuh, M.D., Byung Ho Jin, M.D.,  
Young Eun Cho, M.D., Dong Kyu Chin, M.D.

Department of Neurosurgery, Yonsei University College of Medicine, Seoul, Korea

**Objective** : To evaluate the effectiveness of posterior microforaminotomy in treatment of posterolateral cervical disc herniation, the authors retrospectively analyzed the result of posterior microforaminotomy in our institute.

**Patients and Methods** : Ten patients with radiculopathy due to posterolateral cervical disc herniation have been treated with posterior microforaminotomy from August 1996 to July 2000. We analyzed clinical results in all patients who were followed up for an average of 10 months.

**Results** : The mean age was 47.2 years and all patients were treated with posterior microforaminotomy as primary treatment. one patient was received anterior cervical interbody fusion with iliac bone 12 years before. Clinical improvement in the last follow - up were seen in all patients and there were no complications.

**Conclusion** : Microcervical foraminotomy is considered useful operative method for posterolateral soft disc herniation. We conclude that the posterior microforaminotomy for radiculopathy due to soft posterolateral cervical disc herniation seems to be safe and effective in selective patients.

**KEY WORDS** : Posterior microforaminotomy · Posterolateral cervical disc herniation.

서론

1)3)4)8)9)

1996 8 2000 7

10

(posterior microforaminotomy),

대상 및 방법

1996 8 2000

7 290

226

가

7

47

10  
10  
Prolo's scale 가  
8 , 2  
47.8 1.7 , 15  
6 가  
8 가  
positive wave가 가  
1 가 12

### 수술방법

Ma-  
yfield head pin  
(paraspinal muscle)  
Midas Rex high speed drill  
(disc extrusion or sequestration)  
5mm , 5mm  
50%  
6).

### 수술후 처치

5  
7 , 9  
3

### 결 과

#### 1. 연령 및 성별 분포

30 3 , 40 3 , 50 2 , 60 2 30,

40 가 가 5.5

#### 2. 임상 증상 및 증후의 변화

10  
(posterior neck pain) , 7  
가 7 , 가 3  
7 ,  
가 4 , 1  
2  
(dermatome) 6 2 , 7  
1

#### 3. 근전도검사

10 8  
가

#### 4. 수술부위 및 수술소견 분석

5 가 6 , 6  
가 4 , 가 5 ,  
가 5 , 5  
6 10  
5 가 , 4  
가 1  
(uncinate process hypertrophy)

#### 5. 수술후 경과 및 합병증

3  
6 , 4  
6  
5 , 가  
1  
Prolo's scale 10 Excellent(9 10 )<sup>9)</sup>

### 고 찰

Spurling Scoville 가  
7),  
1)8).

Williams  
 disc) 가 (high cervical  
 가  
 8). 가 가 8).

235  
 3 96.5% 3  
 6

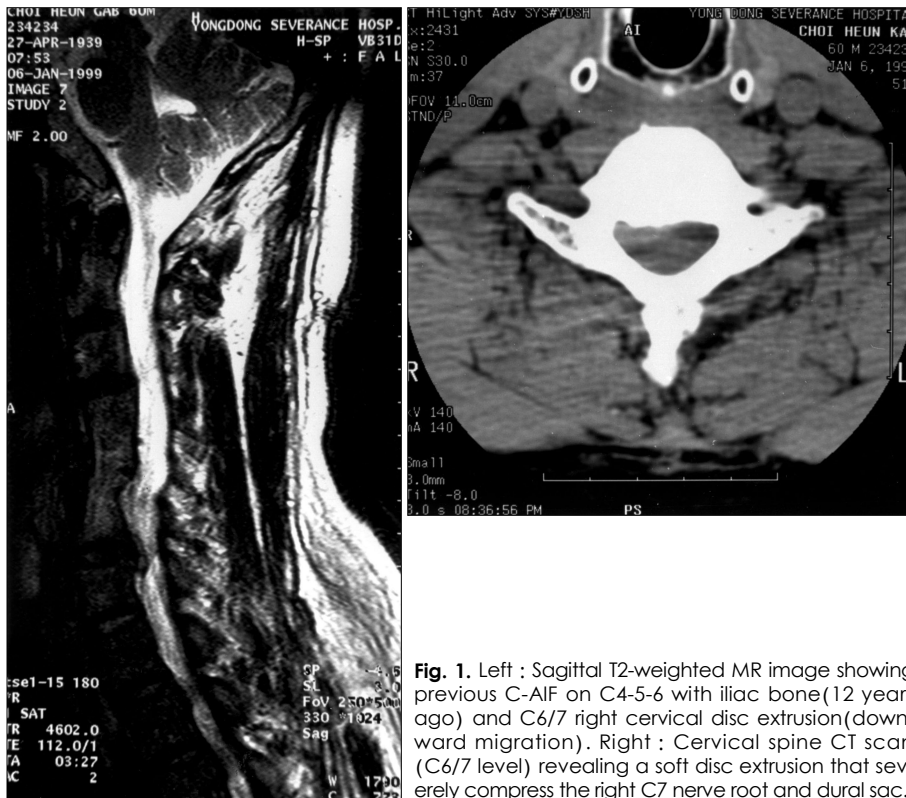
Woertgen 54  
 48% 가 가  
 (sequestered disc fragment) , 52% Aldrich  
 가 (disc prolapse) central, paracentral, posterolateral  
 9). 10 9 posterolateral sequestration  
 가 , 1

Daniels 4 (normal volunteer) 가 53 36  
 45 (oblique view) , 2 3cm  
 45 (axial image) , (sagittal im-  
 age) 가 , 6  
 1).

45 290 가 10 가  
 2). , 9 가  
 (retraction)

가  
 8). Aldrich  
 (surgical instrument) ,  
 가 , 1).

가 (compression force) 1). 가 (com- Woertgen 54 Prolo's scale 8 10 가 , 8 가 가 , 2 3 가 가 9). (facetectomy) , Prolo's scale 10 가 3 , 7 9 , Raynor 70% 8 가 2 , 1 2 7 10mm 가 , 1 6 . 6). 50% , 3 5mm 1 2 , 1 2 7 4 50% , 50% , 1 가 (multiple cervical spondylosis) (hard disc)



**Fig. 1.** Left : Sagittal T2-weighted MR image showing previous C-AIF on C4-5-6 with iliac bone (12 years ago) and C6/7 right cervical disc extrusion (downward migration). Right : Cervical spine CT scan (C6/7 level) revealing a soft disc extrusion that severely compress the right C7 nerve root and dural sac.

가

가

Davis

170

Prolo's score 8 10

86%

(axillary nerve)

가

1 5

(deltoid muscle weakness) good

가

1

3)

10 9

, 1 12 4, 5,

6

가 1 6, 7 가

가

6, 7

가

(Fig. 1).

5, 6 가 6 2 7

Herkowitz

33 17

16

94%(17 16

)가 excellent - good

75%(16 12 )가 excellent -

(pseudoarthrosis) 3

fair good

(central disc herniation)

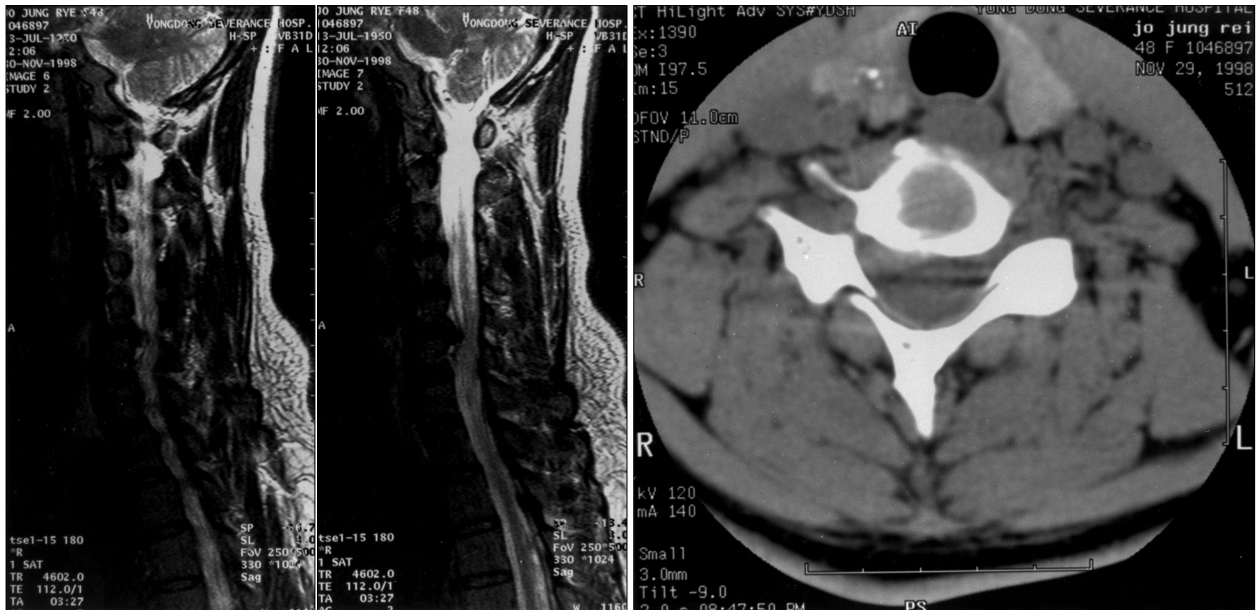(posterocentral)

11

90%(11

10 )가 excellent - good

4).



**Fig. 2.** Left : Sagittal T2-weighted MR image showing C5/6 right cervical disc extrusion. Right : Cervical CT scan(C5/6 level) revealing a soft disc extrusion that severely compresses the right C6 nerve root.

4).

가

,

,

,

,

,

,

,

,

,

,

,

,

,

,

,

,

,

,

,

,

,

,

,

,

,

,

,

,

,

,

,

,

,

,

### 결 론

가

,

,

,

,

,

,

,

,

,

,

,

,

,

,

,

,

,

,

,

,

,

,

,

,

,

,

,

,

,

,

,

,

,

,

,

### References

- 1) Aldrich F : *Posterolateral microdiscectomy for cervical monoradiculopathy caused by posterolateral soft cervical disc sequestration. J Neurosurg* 72 : 370-377, 1990
- 2) Daniels DL, Hyde JS, Kneeland JB, Jesmanowicz A, Froncisz W, Grist TM, et al : *The Cervical Nerves and Foramina : Local-Coil MR Imaging. Am J Neuroradiol* 7 (1) : 129-133, 1986
- 3) Davis RA : *A longterm outcome study of 170 surgically treated patients with compressive cervical radiculopathy. Surg Neurol* 46 (6) : 523-533, 1996
- 4) Herkowitz HN, Kurz LT, Overholt DP : *Surgical management of cervical soft disc herniation : A Comparison Between the Anterior and Posterior Approach. Spine* 15 : 1026-1030, 1990
- 5) Modic MT, Masaryk TJ, Ross JS, Mulopulos GP, Bundschuh CV, Bohlman H : *Cervical Radiculopathy : Value of Oblique MR Imaging. Radiology* 163 : 227-231, 1987
- 6) Raynor RB, Pugh J, Shapiro I : *Cervical facetectomy and its effect on spine strength. J Neurosurg* 63 (2) : 278-282, 1985
- 7) Spurling RG, Scoville WB : *Lateral rupture of the cervical intervertebral disc : A common cause of shoulder and arm pain. Surg Gynecol Obstet* 78 : 350-358, 1944
- 8) Williams RW : *Microcervical Foraminotomy : A Surgical Alternative for Intractable Radicular Pain. Spine* 8 (7) : 708-716, 1983
- 9) Woertgen C, Holzschuh M, Rothoerl RD, Haeusler E, Bra-wanski A : *Prognostic Factors of Posterior Cervical Disc Surgery : A Prospective, Consecutive Study of 54 Patients. Neurosurgery* 40 (4) : 724-729, 1997

• : 2000 11 7

• : 2001 6 7

• :

135 - 270

146 - 92

: 02) 3497 - 3390, : 02) 3461 - 9229

E - mail : kuhsu@yumc.yonsei.ac.kr