

## Structural Changes of Inferior Turbinate in Patients with Septal Deviation : Surgical Implication

Ju-Wan Kang, M.D., Jong Bum Yoo, M.D.,  
Chang-Hoon Kim, M.D. and Jeung-Gweon Lee, M.D.

### ABSTRACT

Septal deviation causes various nasal symptoms and other sinonasal disease. We evaluated the relationship between septal deviation and morphologic changes of the inferior turbinate. PNS CT of 31 patients (septal deviation group) and 20 normal subjects (normal control group) were reviewed. We measured the thickness of the inferior turbinate and the angle between the lateral nasal wall and the inferior turbinate in each group. Each measurements were analyzed using t-test and compared. The thickness of the inferior turbinate and the angle between the lateral nasal wall and the inferior turbinate showed no difference between the right and left side in the control group. The same measurement of the convex side in the septal deviation group were not different from those of the control group. However, the thickness of the inferior turbinate and the angle between the lateral nasal wall and the inferior turbinate differed significantly from the control group data. Changes of the inferior turbinate in septal deviation were caused not only by hypertrophy of the inferior turbinate, but also by the increased angle between the lateral nasal wall and the inferior turbinate.

KEY WORDS : Septal deviation · Inferior turbinate.

### INTRODUCTION

Septal deviation causes variable nasal symptoms including nasal obstruction and is also the causative factor of other sinonasal diseases such as chronic sinusitis. It also causes structural changes of other structures within the nasal cavity. There have especially been many researches carried out for a long period of time based on compensatory hypertrophy of the inferior turbinate in septal deviation patients and many results have been submitted. Until now, research was mainly focused on mucosal hypertrophy and bony hypertrophy. Research based on the angle between the inferior turbinate and lateral nasal wall has been close to nonexistent. There-

fore, methods such as removal of the mucosa or bony portion of the hypertrophied inferior turbinate have been used for improvement of symptoms. However, such methods can bring about postoperative complications such as atrophic rhinitis, bleeding, crust formation and so forth. Also, information based on the effect, indication of inferior turbinate surgery and effective methods is still insufficient.

Therefore the authors wish to provide a suitable background in order to choose an appropriate treatment modality for compensatory inferior turbinate hypertrophy accompanied with nasal septal deviation in accordance with research based on the changes of the inferior turbinate as a result of septal deviation.

### MATERIAL AND METHOD

This study is based on patients that visited the department of otorhinolaryngology at the Yonsei medical center from December 2001 to February 2003. 31 patients that complained of nasal obstruction and were diagnosed with nasal septal deviation by an anterior rhinoscopy whom agreed to participate in this expe-

---

*Department of Otorhinolaryngology, Yonsei University College of Medicine, Seoul, Korea*

*Address correspondences and reprint requests to Jeung-Gweon Lee, M.D., Ph.D. Department of Otorhinolaryngology, Yonsei University College of Medicine, 134 Shinchon-dong, Seodaemun-gu, Seoul 120-752, Korea*

*Tel : 82-2-361-8476, Fax : 82-2-393-0580*

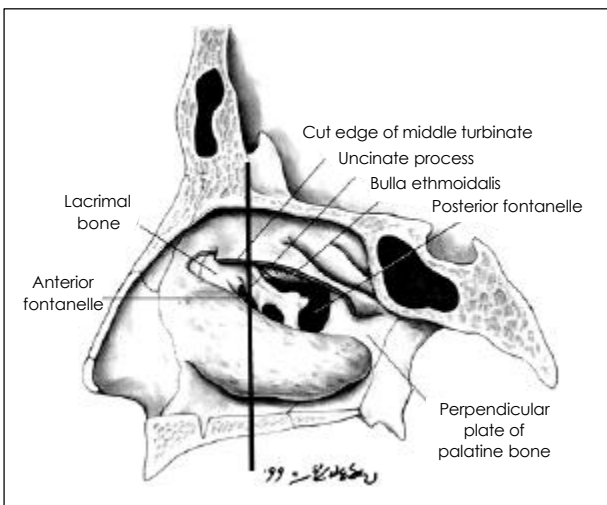
*E-mail : jglee@yumc.yonsei.ac.kr*

*Accepted for publication on August 4, 2004*

---

periment were recommended to undergo PNS CT scans and were chosen as the subjects for this study. The control group consisted of 20 patients who complained of olfactory disorders that did not show septal deviation according to an anterior rhinoscopy and acoustic rhinometry. These patients underwent PNS CT scans to exclude other causative factors, such as tumors when anatomical abnormalities or nasal polyps were not noticed either. Patients in neither group had a history of recent trauma or infection according to past medical histories. The age group was from 20 to 62 years old with an average age of 34.5 years old in the experimental group and 29 to 72 years old with an average age of 36.6 years old in the control group. There were 8 male and 12 female patients in the control group and 17 male and 14 female patients in the experimental group.

PNS CT of the axial and coronal view was carried out at a 5mm interval. The thickness and angel between the lateral nasal wall and the inferior turbinate was each measured using the PACS (picture archiving and communicating system) by General Electronics. For measurement from a fixed point, the front part of the vertical portion of the uncinate process was set up as the standard point (Fig. 1). In order to find the picture that is closest to the standard point among the coronal view of PNS CT, we chose the one that reveals the uncinate process as the longest and measured the thickness of the inferior turbinate and angel between



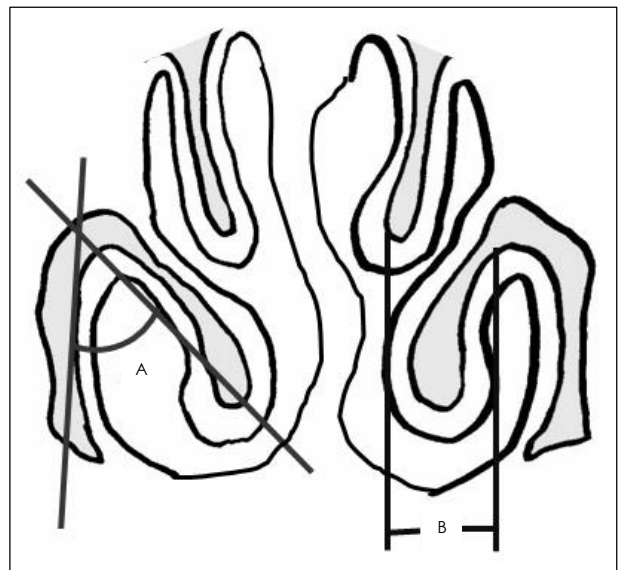
**Fig. 1.** In order to compare the value at an established point of the inferior turbinate, the beginning portion of the uncinate process is set as the standard point (This picture recorded in the "Clinical Anatomy of the Nose" is used under author's permission).

the inferior turbinate and the lateral nasal wall.

In the case of the measurement of the angel between the inferior turbinate and lateral nasal wall, the point where the inferior turbinate and lateral nasal wall meet was set as the vertical point. The standard point was set at the meeting point of the center point of the bony end of the inferior turbinate and the point where the lateral nasal wall meets with the nasal cavity floor. The angel established by these three points was measured. Also, for measurement of the thickness of the inferior turbinate, the thickness was measured at several different parts with the inferior turbinate at a horizontal plane with the nasal floor and the one with the highest value was chosen (Fig. 2). The experiment group was divided into a convex side and a concave side and each was measured separately. The control group was divided into a right side and a left side and each was measured separately. The data of the control group was first compared and evaluated using a paired t-test and the data of the experimental group was evaluated and compared with the control group using a two-sample t-test.

## RESULT

First, we will examine the results of the control group. The thickness of the right inferior turbinate was



**Fig. 2.** The thickness of the inferior turbinate and angle established by the inferior turbinate and lateral nasal wall is measured. The method of measurement is schematically shown. A : The angle established by the inferior turbinate and lateral nasal wall. B : Thickness of the inferior turbinate.

5.20 mm as the minimum and 13.6 as the maximum value with an average of 8.38 mm and standard deviation of 1.98 mm. The thickness of the left inferior turbinate was 4.9 mm as the minimum and 13.1 mm as the maximum value with an average of 9.82 mm and standard deviation of 1.82 mm. However, the difference between the two groups was not statistically significant according to a  $p$ -value of 0.15. The right angle established by the inferior turbinate and lateral nasal wall was 49.4 ° as the minimum and 86.1 ° as the maximum value with an average of 67.14 ° and standard deviation of 11.11 ° the left angle was 44.5 ° as the minimum and 85.7 ° as the maximum value with an average of 66.84 ° and standard deviation of 11.27 ° However, both values did not show a significant difference with a  $p$ -value of 0.78 (Table. 1).

The data of the control group that did not show a significant difference was added into one value and the average and standard deviation was obtained again. This value was compared with the measured value of the convex and concave side of the experimental group.

The average thickness of the inferior turbinate of the control group was 8.6 mm with a standard deviation of 1.91 mm. The concave side was 4.6 mm at minimum and 18.4 mm at maximum with an average of 11.47 mm and standard deviation of 3.29 mm. This showed a significant difference compared to the control group with a  $p$ -value of 0.0001. However, the convex side was 4.3 mm at minimum and 16.2 mm at maximum with an average of 9.46 mm and standard deviation of 2.59 mm, which were thicker compared to the control group, however, the difference was not significant with a  $p$ -value of 0.13.

The angle established between the inferior turbinate and lateral nasal wall of the control group showed an average of 66.99 ° and standard deviation of 11.19 ° The angle of the concave side was 44.5 ° as the mini-

**Table 1.** Result of thickness of inferior turbinate and angle between lateral nasal wall and inferior turbinate in control group

	Thickness of inferior turbinate (mm)	Angle between inferior turbinate and lateral nasal wall ( ° )
Right side	8.38 ± 1.98	67.14 ± 11.11
Left side	9.82 ± 1.82	66.84 ± 11.27
$p$ -value	0.15	0.78

um and 85.7 ° as the maximum value with an average of 80.95 ° and standard deviation of 16.19 ° This showed a significant difference compared to the control group with a  $p$ -value of 0.0001. The angle of the convex side was 44.5 ° as the minimum and 85.7 ° as the maximum value with an average of 64.27 ° and standard deviation of 15.82 ° which showed a somewhat low value compared to the control group, however there was no significant difference with a  $p$ -value of 0.43 (Table. 2).

## DISCUSSION

Septal deviation can cause symptoms such as nasal obstruction, postnasal drip, mouth breathing along with variable symptoms such as headache and olfactory disorders. Also, when deviation is severe, turbulent flow is formed which causes negative pressure that leads to edema or hypertrophy of the surrounding tissues. Such changes can cause abnormalities of the osteomeatal unit that can affect the development of sinusitis.

Among changes of the nasal cavity followed by septal deviation, studies based on the hypertrophy of the concave side of the inferior turbinate has been carried out the most. Through a histological study, it has stated that hypertrophy of the concave side is caused by increment of erectile tissue. 1) Besides compensatory hypertrophy, mucociliary transport disturbance can also occur. In the case of the convex side, increment of glands of the inferior turbinate mucosa can be observed along with increment of inflammatory cells of the opposite side. 2) Compensatory hypertrophy of the inferior turbinate has the effect of preventing crust formation or dryness caused by excess air flow. However, resistance to such air flow can, on the other hand, cause nasal obstruction. Haight *et al.*, stated that not only is hypertrophy of the inferior turbinate respon-

**Table 2.** Result of thickness of inferior turbinate and angle between lateral nasal wall and inferior turbinate in septal deviation group

	Thickness of inferior turbinate (mm)	Angle between inferior turbinate and lateral nasal wall ( ° )
Control	8.6 ± 1.91	66.99 ± 11.19
Concave	11.47 ± 3.29	80.95 ± 16.19
$p$ -value	0.0001	0.0001
Convex	9.46 ± 2.59	64.27 ± 15.82
$p$ -value	0.13	0.43

sible for resistance to air flow but protrusion of the inferior turbinate into the nasal cavity can also cause such resistance.<sup>2)</sup>

Therefore, the authors carried out this study based on changes of the inferior turbinate followed by septal deviation along with the angle established by the inferior turbinate and lateral nasal wall. First of all thickness of the inferior turbinate showed an increase in the concave side, which was similar to other results. In this study, the mucosa and bone were not separately measured. According to Ahn *et al.*,<sup>3)</sup> and Egeli *et al.*,<sup>4)</sup> not only does increase of glands effect inferior turbinate hypertrophy but also does increase of the bony portion. However according to a comparison study of a normal inferior turbinate and hypertrophied inferior turbinate carried out by Berger *et al.*,<sup>5)</sup> the bony portion of the hypertrophied inferior turbinate was twice as much hypertrophied compared to the normal inferior turbinate. However, the degree of hypertrophy of the external and internal mucosa was very insignificant, which suggests a very minimal effect in inferior turbinate hypertrophy. However, in this study, the tissue was used for the the normal inferior turbinate was from a dead body which suggests that this comparison study was not carried out in an identical condition for each group.

In the case of the angle established by the inferior turbinate and lateral nasal wall, it was confirmed that the angle increased at the concave side. Fairbanks *et al.*, also stated that at the time of bony and mucosal hypertrophy followed by septal deviation, internal protrusion also occurred simultaneously.<sup>6)</sup> Therefore, we believe that a breathing passage within the nasal cavity can be established by lessening the angle between the inferior turbinate and nasal lateral wall by a septoplasty that will help to obtain relief of symptoms as a result.

An outfracture is also another method used to lessen

the angle established by the inferior turbinate and nasal lateral wall that has many advantages compared to other methods. Firstly, it does not effect the mucosa therefore complications such as adhesion or crust formation do not develop. Secondly, the possibility of atrophic rhinitis occurring after surgery is very low.<sup>7)</sup> Thirdly, side effects such as bleeding rarely occur. However, there are reports that state that outfracture of the inferior turbinate returns to its normal position after a period of time and because the soft tissue itself of the hypertrophied inferior turbinate is not removed, it will not have many effect on the improvement of symptoms.<sup>8)</sup> Therefore, we believe that further evaluation based on the structural changes of the inferior turbinate along with additional research based on outfracture of the inferior turbinate and its effect on symptoms will be necessary.

## REFERENCES

- 1) Illum P. Septoplasty and compensatory inferior turbinate hypertrophy: Long term result after randomized turbinoplasty. *Eur Arch Otolaryngol* 1997;1:89-92.
- 2) Kim BH, Ryu JM, Cho YC, Lim DJ, Lee BY. Histopathology of the inferior turbinate showing compensatory hypertrophy in patients with deviated nasal septum. *Korean J Otolaryngol* 2003;46:230-3.
- 3) Ahn BH, Lee SY, Sohn SG, Shin HC, Kim ED, Nam SI. The relationship between nasal septal deviation and inferior turbinate hypertrophy. *Korean J Otolaryngol* 2003;46:950-4.
- 4) Egeli E, Demirci L, Yazyey B, Harputluoglu U. Evaluation of the inferior turbinate in patients with deviated nasal septum by using computed tomography. *Laryngoscope* 2004;114:113-7.
- 5) Berger G, Hammel I, Berger R, Avraham S, Ophir D. Histology of the inferior turbinate with compensatory hypertrophy in patients with deviated nasal septum. *Laryngoscope* 2000;110:2100-5.
- 6) Fairbanks DNF, Kaliner M. Nonallergic rhinitis and infection. In: Cummings CW, Fredrickson JM, Harker AL, Krause CJ, Richardson MA, Schuller DE. editor. *Otolaryngology Head and Neck Surgery*, vol 2, 3rd ed. St. Louis: Mosby;1998. p.910-20.
- 7) Haight JS, Cole P. The site and function of the nasal valve. *Laryngoscope* 1983;93:49-55.
- 8) Goode RL. Surgery of the turbinate. *J Otolaryngol* 1978;1:262-8.