

## The Use of Color Doppler Sonography to Avoid Misinterpretation of the Intrahepatic Portal Vein in Gray-Scale Sonographic Diagnosis of Cysts: Two Case Reports

Byong-Jong Youn, M.D., Mi-Suk Park, M.D.\*, Jeong-Sik Yu, M.D., Ki-Whang Kim, M.D.

Department of Diagnostic Radiology, YongDong Severance Hospital, \*Sinchon Severance Hospital

### = Abstract =

The Use of Color Doppler Sonography Avoids Misinterpretation of the Intrahepatic Portal Vein in the Gray-Scale Sonographic Diagnosis of Cysts. When gray-scale US shows an intrahepatic cystic lesion with weak or no posterior acoustic enhancement in close proximity to the portal vein, especially at the bifurcation area, a detailed color Doppler US should be subsequently performed to evaluate its vascular nature.

Index Words : Ultrasound (US)  
Ultrasound (US), Doppler studies

### Introduction

Ultrasonography (US) has become the initial imaging test of choice to evaluate focal lesions in the liver and has proven effective in differentiating between solid and cystic masses. The presence of an anechoic round lesion with posterior acoustic enhancement on gray-scale sonograms is usually believed to indicate only a simple cyst of the liver. Here, however, we present two cases which were initially diagnosed as hepatic cysts by gray-scale US, but which were then confirmed as intrahepatic portal vein aneurysms by Doppler US.

### Case Report

#### Case 1

A 75-year-old woman presenting with a headache

was admitted to our institution. She had been healthy without any significant medical history. Abdominal US showed a 2-cm-sized, anechoic round lesion with weak posterior acoustic enhancement attached to the right portal vein bifurcation area. We performed Doppler US to investigate the presence of communication between the lesion and the portal vein. There was no color flow in the anechoic cystic lesion, despite the presence of color flow in the right portal vein. This suggested a diagnosis of complicated cyst or localized Caroli's disease. As the next diagnostic work-up, we performed multi-phase, (Gd-BOPTA)-enhanced, dynamic MRI to differentiate between a vascular-communicating, bile duct-communicating lesion and a non-communicating one. On contrast-enhanced, dynamic MRI, the lesion showed the same enhancement as the adjacent portal vein did. Repeated Doppler US with increased color gain showed color flow and monophasic hepatopetal

: 2006 2 16 , : 2006 5 3 , : 2006 5 4 , : 2006 6 12

Address for reprints : Mi-Suk Park, M.D., Department of Diagnostic Radiology and Research Institute of Radiological Science,  
Yonsei University, College of Medicine, Sinchon Severance Hospital  
134 Shinchon-dong, Seodaemun-gu, Seoul 120-752, Korea.  
Tel. 82-2-2228-7400 Fax. 82-2-3462-5472 E-mail: radpms@yumc.yonsei.ac.kr

constant flow in the anechoic lesion.

*Case 2*

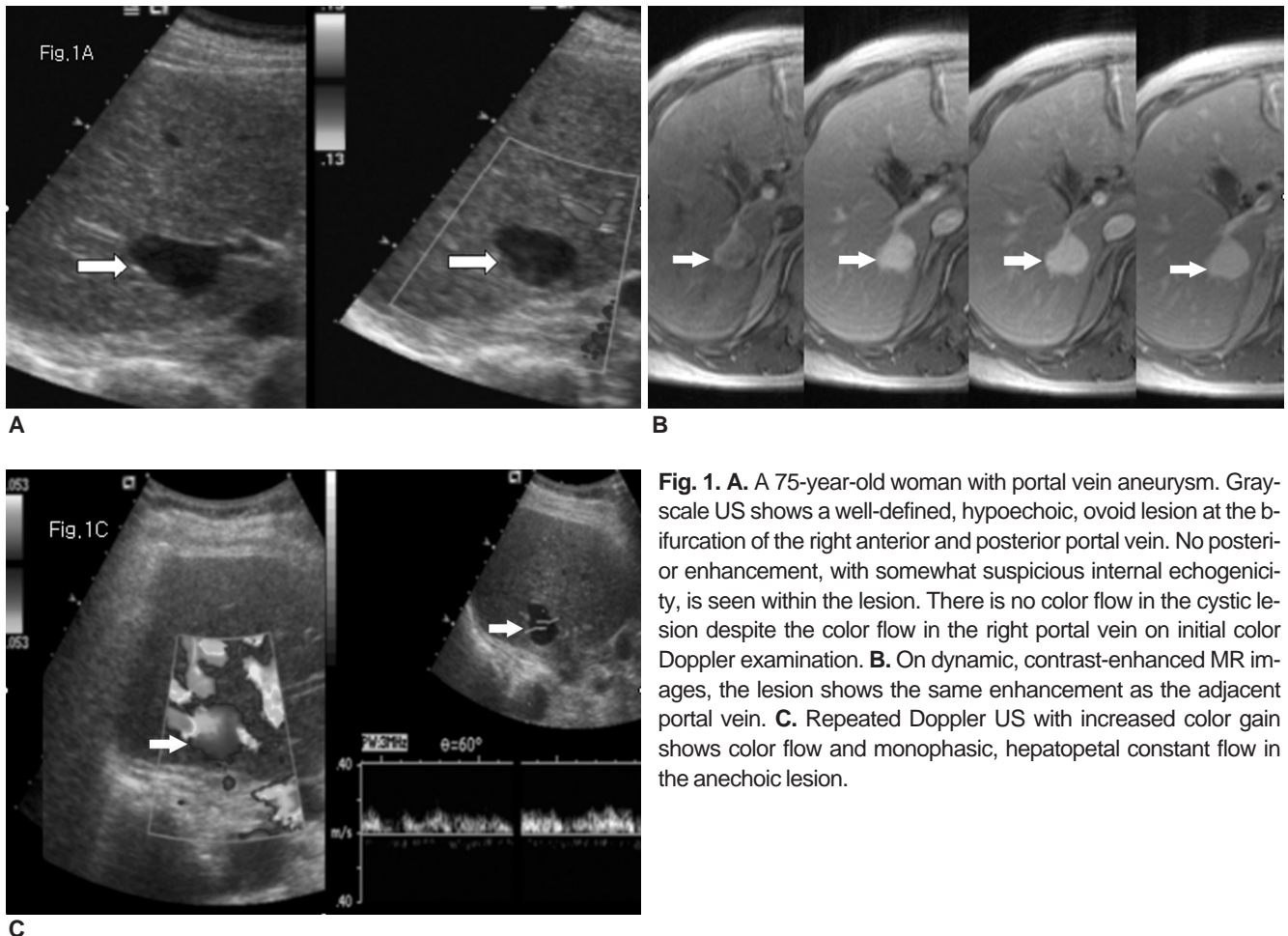
A 49-year-old man with no significant medical history showed an intrahepatic, anechoic, round lesion with weak, posterior, acoustic enhancement on gray-scale US during a work-up for pituitary adenoma. There was no large vessel adjacent to the lesion which we therefore considered to be a complicated cyst. On contrast-enhanced dynamic CT, however, the lesion showed the same enhancement as the adjacent vessel (portal vein branches). Repeated Doppler US showed color flow in the anechoic lesion.

**Discussion**

Aneurysm of the portal vein is a rare vascular anomaly. Previous studies have proposed a relationship between portal vein aneurysm and portal hypertension or

hepatocellular disease [1, 2]. Sometimes, however, portal vein aneurysm is incidentally detected in patients without portal hypertension or hepatic disease, as in both our cases. Although usually asymptomatic, portal vein aneurysm complications can include spontaneous rupture, portal vein thrombosis, complete occlusion of the portal vein, or biliary tree compression leading to jaundice [1, 3]. Therefore, close follow-up is needed and surgical treatment should be considered if the lesion grows larger.

A portal vein aneurysm is defined as a focal fusiform or saccular dilatation of the portal venous system. Ohnami et al. [4] reported that the majority of the portal vein aneurysms is located in the bifurcation or confluence area, while 80% of the intrahepatic portal vein aneurysms were reported to be localized at the bifurcation of the intrahepatic portal vein. In our study, the portal vein aneurysm in the first case was located at the bifurcation area of the right anterior and posterior portal



**Fig. 1.** A. A 75-year-old woman with portal vein aneurysm. Gray-scale US shows a well-defined, hypoechoic, ovoid lesion at the bifurcation of the right anterior and posterior portal vein. No posterior enhancement, with somewhat suspicious internal echogenicity, is seen within the lesion. There is no color flow in the cystic lesion despite the color flow in the right portal vein on initial color Doppler examination. B. On dynamic, contrast-enhanced MR images, the lesion shows the same enhancement as the adjacent portal vein. C. Repeated Doppler US with increased color gain shows color flow and monophasic, hepatopetal constant flow in the anechoic lesion.

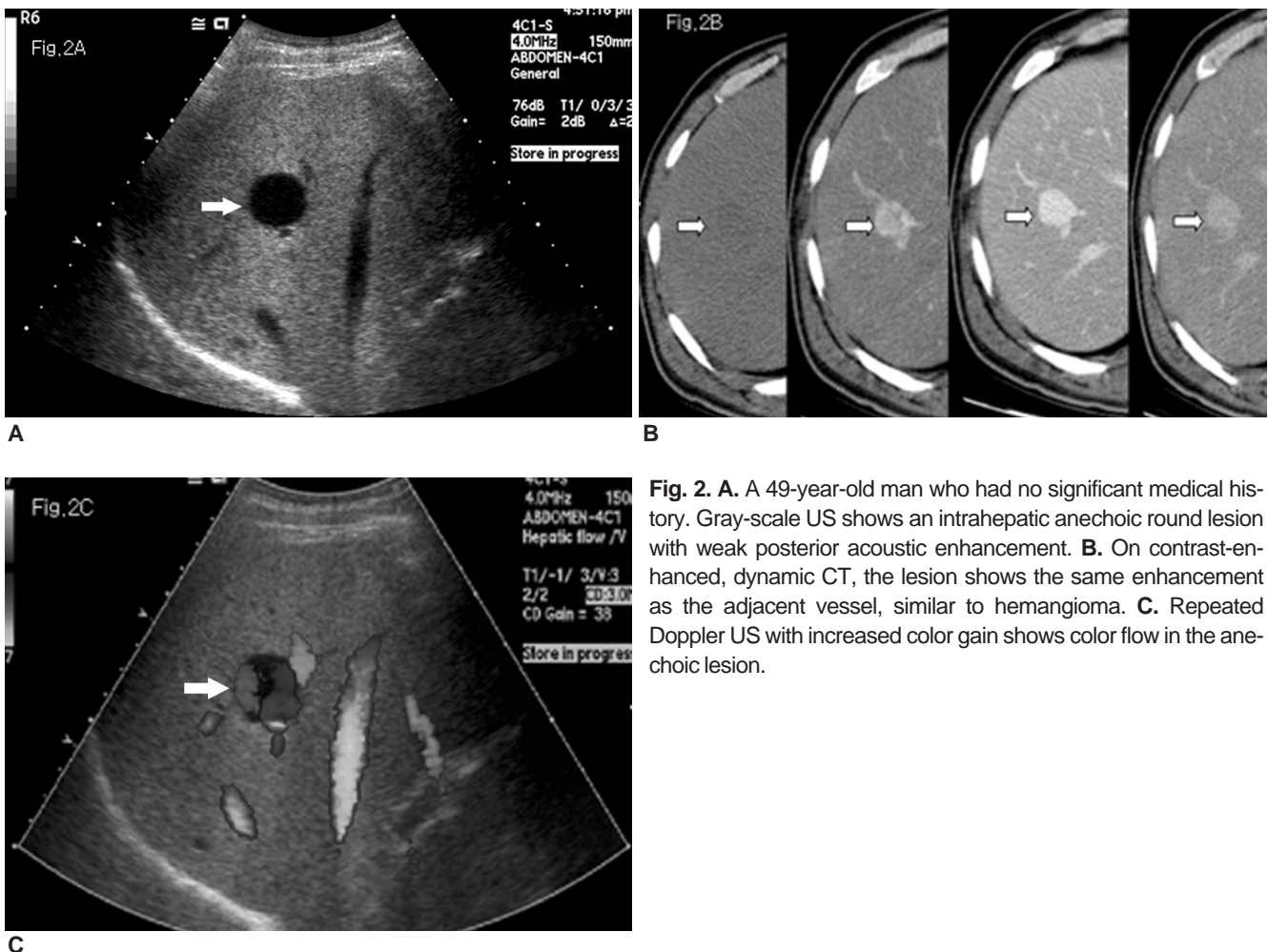
veins.

There are many types of cystic lesion found in the liver, especially in the periportal area, such as peribiliary cysts. Therefore, most radiologists are typically not as concerned with small cystic lesions. Tanaka et al. [5] reported that a portal vein aneurysm was treated by ultrasonically guided ethanol injection following its false diagnosis as a cyst. On gray-scale US, a portal vein aneurysm appeared as an anechoic cystic lesion [6]. In our study, we regarded the lesions as cysts on gray-scale US. Furthermore, with gray-scale US, it is not always easy to determine whether or not the intrahepatic cystic lesion is in communication with neighboring vessels. Therefore, it is extremely important to closely evaluate cystic lesions adjacent to vessels, especially at the bifurcation or confluence area, when they show weak or no posterior acoustic enhancement. It is well known that posterior acoustic enhancement in the vessel is much weaker than that in the cyst, because the at-

tenuation coefficient is much greater in blood than in water.

With detailed color Doppler examination, the presence or absence of blood flow within the cystic lesion can be clearly distinguished and an accurate diagnosis of the vascular anomaly can be made [7]. There are some pitfalls, however, of color Doppler examination in the evaluation of portal vein aneurysm. Ishida et al. [8] reported that color Doppler examination failed to detect an aneurysm in one case with a markedly calcified aneurismal wall because of sound attenuation at the calcified wall. In our study, there was no color flow in the portal vein aneurysm, despite the color flow in the right portal vein on initial color Doppler examination. The Doppler scale should be carefully adjusted because color flow in the portal vein aneurysm is much weaker than that in the normal portal vein.

In conclusion, when gray-scale US shows an intrahepatic cystic lesion with weak or no posterior acoustic



**Fig. 2. A.** A 49-year-old man who had no significant medical history. Gray-scale US shows an intrahepatic anechoic round lesion with weak posterior acoustic enhancement. **B.** On contrast-enhanced, dynamic CT, the lesion shows the same enhancement as the adjacent vessel, similar to hemangioma. **C.** Repeated Doppler US with increased color gain shows color flow in the anechoic lesion.

enhancement in close proximity to the portal vein, especially at the bifurcation area, a detailed color Doppler US should be subsequently performed to evaluate its vascular nature more carefully.

### References

1. Ascenti G, Zimbaro G, Mazziotti S, et al. Intrahepatic portal vein aneurysm: three-dimensional power Doppler demonstration in four cases. *Abdom Imaging* 2001;26(5): 520-523
2. Ohnami Y, Ishida H, Konno K, et al. Portal vein aneurysm: report of six cases and review of the literature. *Abdom Imaging* 1997; 22(3):281-286
3. Atasoy KC, Fitoz S, Akyar G, Aytac S, and Erden I. Aneurysms of the portal venous system. Gray-scale and color Doppler ultrasonographic findings with CT and MRI correlation. *Clin Imaging* 1998;

- 22(6):414-417
4. Ohnami Y, Ishida H, Konno K, Naganuma H, et al. Portal vein aneurysm: report of six cases and review of the literature. *Abdom Imaging* 1997;22(3):281-286
5. Tanaka S, Kitamura T, Fujita M, et al. Intrahepatic venous and portal venous aneurysms examined by color Doppler flow imaging. *J Clin Ultrasound* 1992;20(2):89-98
6. Fulcher A, Turner M. Aneurysms of the portal vein and superior mesenteric vein. *Abdom Imaging* 1997;22(3):287-292
7. Lopez-Machado E, Mallorquin-Jimenez F, Medina-Benitez A, Ruiz-Carazo E, Cubero-Garcia M. Aneurysms of the portal venous system: ultrasonography and CT findings. *Eur J Radiol* 1998; 26(2):210-214
8. Ishida H, Konno K, Hamashima Y, et al. Splenic artery aneurysm: value of color Doppler and the limitation of gray-scale ultrasonography. *Abdom Imaging* 1998;23(6):627-632

2006;25:73-76

