

성견 일벽성 치주 결손부에 이식한 biphasic calcium phosphate의 조직계측학적 평가

1, 1, 1, 1, 1, 2, 1, 1, 1*

- 1.
2. Dentium Co.

Histometrical evaluation of biphasic calcium phosphate in surgically created 1-wall periodontal intrabony defects in dogs

Je-Young Yon¹, Dong-Jin Kim¹, Sung-Bae Hong¹, Ji-Yeon Hong¹, Sung-Tae Kim¹, Yong-Ho Lee², Kyu-Sung Cho¹, Chong-Kwan Kim¹, Seong-Ho Choi^{1*}

1. Department of Periodontology, Research Institute for Periodontal Regeneration, College of Dentistry, Yonsei University
2. Dentium Co.

ABSTRACT

Purpose: The aim of this study was to evaluate biphasic calcium phosphate applied in surgically created 1-wall periodontal intrabony defects in dogs by histometrical analysis.

Material and Method: Critical sized (4 mm × 4 mm), one wall periodontal intrabony defects were surgically produced at the proximal aspect of mandibular premolars in either right and left jaw quadrants in four canines. The control group was treated with debridement alone, and experimental group was treated with debridement and biphasic calcium phosphate application. The healing processes were histologically and histometrically observed after 8 weeks.

Results: In biphasic calcium phosphate group, more new bone and cementum formation, less epithelium and connective tissue attachment were observed compared to other groups. But there was no statistical significance.

Conclusion: Though the statistically significant difference could not be found, it seemed that there was more new bone and cementum formation with applying biphasic calcium phosphate in 1 wall intrabony defects in dogs by preventing junctional epithelium migration. (*J Korean Acad Periodontol* 2008;38:171-178)

KEY WORDS: biphasic calcium phosphate, alloplastic materials, 1-wall defect.

4), 5), 6,7)

가

가

1-3),

8).

가 , , ,

가

Correspondence: Seong-Ho Choi
Department of Periodontology, School of Dentistry, Yonsei University,
134 Shin-chon Dong, Seodaemun-gu, Seoul, 120-752, Korea.
E-mail: shchoi726@yuhs.ac., Tel: 82-2-2228-3188, Fax: 82-2-392-0398

* 2005 () (R13-2003-013-02001-0).

: 2008 5 16 ; : 2008 5 26

가

가

가

가

, 가

9).

16,21,22)

10,11) , 가 ,
 . non-porous hydrox-
 yapatite, hydroxyapatite cement, porous hydrox-
 yapatite, beta-tricalcium phosphate, PMMA HEMA
 polymer, bioactive glass 가
 . Porous non-porous hydroxyapatite, PMMA
 HEMA polymer , -tricalcium
 phosphate bioactive glass . 가
 hydroxyapatite, calcium phosphate, calcium carbonate,
 calcium sulfate

12-14)

가
 (scaffold) ,

15)

Hydroxyapatite beta-tricalcium phosphate(-TCP)

가 16) -TCP

17)

가 . Hydroxyapatite

4

18)

-TCP가

12 ,

6~8

19,20)

Hydroxyapatite 가 가

(filler) , 가
 . hydroxyapatite 가

phate ,
 가 tricalcium phos-

가
 가 21,22)

yapatite tricalcium phosphate

Biphasic calcium phosphate
 hydroxyapatite(HA) -tricalcium phosphate(
 -TCP)

HA가 ,
 -TCP가 77%
 . 3 300~500 μm

1 2, 3

23)

1 biphasic calcium phosphate
 가 .

biphasic calcium phosphate

가 가

1.

12 , 15 kg 4
 (Mongrel Dog)

(Prescription Diet Canine i/d,
 Hill's Pet Nutrition, Inc. USA)

biphasic calcium phos-
 phate(OSTEON, Genoss, Korea) 가 500

μm~1000 μm , hydroxyapatite -tricalcium phos-
 phate가 70:30 . 300 μm~500 μm

3 77%

2.
(1)
2 4
1 biphasic cal-
cium phosphate

(2)
Atropin(0.04 mg/kg; Kwangmyung Pharmaceutical Ind.
Co. Ltd., Seoul, Korea) (IV), xylazine
(Rompun, Bayer Korea Co., Seoul, Korea) ketamin
(Ketara, Yuhan Co., Seoul, Korea)

(Gerolan, Choongwae
Pharmaceutical Co., Seoul, Korea)

lidocaine(2% , 1.8 mm,
Yuhan Co., Seoul, Korea)

3 8
2 4 CEJ
4 mm 4 mm

가 2
4
4 mm

(reference point) ¼ round bur
biphasic calcium phosphate

(Vicryl 5.0 Polyglactin
910, Ethicon. Johnson & Johnson)

가

(3)
8 Sodium pentobarbital

block section

10% buffered formalin 10
5% nitric acid 2
paraffin

4 µm
, 80 µm

Hematoxylin-Eosin

(Olympus Multi-view microscope BH2
Japan)

(Image-Pro Plus™, Media Cybernetic, Silver
Springs, MD, USA)

(Fig. 1).

- (defect height):
- (notch) - (CEJ)
- (Bone regeneration):
- (cementum regeneration):
- (epithelial attachment): CEJ
- (connective tissue attachment):

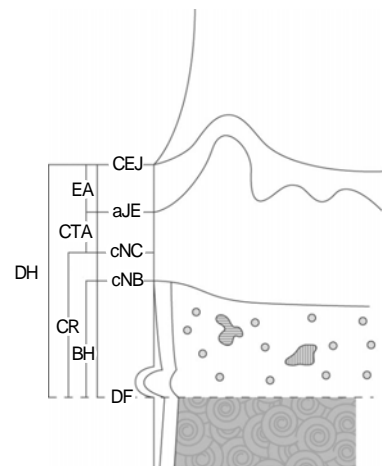


Figure 1. Schematic diagram depicting the landmarks and parameters used in the histometric analysis.

CEJ : cemento-enamel junction, aJE : apical extent of junctional epithelium, cNC : coronal extent of newly formed cementum, cNB : coronal extent of newly formed bone, DF : defect floor, EA : epithelial attachment, CTA : connective tissue attachment, BH : bone height, CR : cementum regeneration, DH : defect height.

(4)

(SPSS 12.0, SPSS Inc., Chicago, IL, USA)

Mann-Whitney U test

0.05

1.

2.

(1) ()

(2) (biphasic calcium phosphate)

biphasic calcium phosphate

(woven bone)

가

biphasic cal -



Figure 2. Control 8 weeks($\times 40$, H-E).

cium phosphate

calcium phosphate

(osteoid)

biphasic calcium phos -

phate

(Fig. 2, 3).

3.

Table 1

(\pm)

3.77 ± 0.34 mm, 4.70 ± 0.62 mm

(p

$=0.309$).

1.40 ± 0.72

0.94 ± 0.66

($p=0.773$).

$1.63 \pm$

0.54

0.79 ± 0.65

($p=0.149$).

1.30 ± 0.55 ,

1.65 ± 0.21

($p=0.386$).

0.65 ± 0.29 ,

1.83 ± 1.27

($p=0.149$).

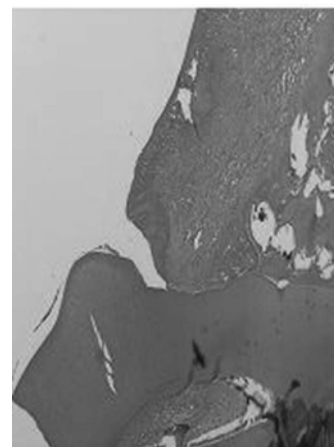


Figure 3. Biphasic calcium phosphate 8 weeks($\times 40$, H-E).

22)	(trabecular bone)	Nery	hy - droxyapatite(HA) tricalcium phosphate(TCP) biphasic calcium phosphate , HA가	2.3±0.5 mm, . 3 43~66%,	2.8±0.5 mm , 1 (12,36) 가
16)	phosphate	7:3(HA:TCP)	biphasic calcium phosphate가	가	(dehiscence defect) 37) Calcium 38)
	phosphate가	가	biphasic calcium phosphate	2, 3	가
	biphasic calcium phosphate	가	1 calcium phosphate (32.92%) 가(49.16~52.26%) 33-35)	가	biphasic calcium phosphate
	가	biphasic calcium phosphate	가	2, 3	가
	osteoid	가	biphasic calcium phosphate	가	가
1, 2, 3	1.5±0.5 mm,	1.2±0.6 mm	Kim 28)	1, 3	가

1. Bowers GM, Chadroff B, Carnevale R, et al. Histologic evaluation of new attachment apparatus formation in humans. Part II. J Periodontol 1989;60:675-682.
2. Bowers GM, Chadroff B, Carnevale R, et al. Histologic evaluation of new attachment apparatus formation in humans. Part III. J Periodontol 1989;60:683-693.
3. Gottlow J, Nyman S, Lindhe J, Karring T, Wennstrom J. New attachment formation in the human periodontium by guided tissue regeneration. Case reports. J Clin Periodontol 1986;13:604-616.
4. Yukna RA. Clinical human comparison of expanded polytetrafluoroethylene barrier membrane and freeze-dried dura mater allografts for guided tissue regeneration of lost perio-

- dontal support. I. Mandibular molar Class II furcations. *J Periodontol* 1992;63:431-442.
5. Urist MR. Bone: formation by autoinduction. *Science* 1965;150:893-899.
 6. Isidor F, Attstrom R, Karring T. Regeneration of alveolar bone following surgical and non-surgical periodontal treatment. *J Clin Periodontol* 1985;12:687-696.
 7. Isidor F, Karring T, Nyman S, Lindhe J. New attachment formation on citric acid treated roots. *J Periodontal Res* 1985;20:421-430.
 8. Taba M, Jr., Jin Q, Sugai JV, Giannobile WV. Current concepts in periodontal bioengineering. *Orthod Craniofac Res* 2005;8:292-302.
 9. Aukhil I, Simpson DM, Schaberg TV. An experimental study of new attachment procedure in beagle dogs. *J Periodontal Res* 1983;18:643-654.
 10. Mellonig JT, Bowers GM. Regenerating bone in clinical periodontics. *J Am Dent Assoc* 1990;121:497-502.
 11. Reynolds MA, Bowers GM. Fate of demineralized freeze-dried bone allografts in human intrabony defects. *J Periodontol* 1996;67:150-157.
 12. Kim CK, Chai JK, Cho KS, et al. Periodontal repair in intrabony defects treated with a calcium sulfate implant and calcium sulfate barrier. *J Periodontol* 1998;69:1317-1324.
 13. Kim CK, Kim HY, Chai JK, et al. Effect of a calcium sulfate implant with calcium sulfate barrier on periodontal healing in 3-wall intrabony defects in dogs. *J Periodontol* 1998;69:982-988.
 14. Kim CK, Choi EJ, Cho KS, Chai JK, Wikesjo UM. Periodontal repair in intrabony defects treated with a calcium carbonate implant and guided tissue regeneration. *J Periodontol* 1996;67:1301-1306.
 15. Schendel S, Bresnick S, Cholon A. Preliminary report: a ceramic containing crosslinked collagen as a new cranial onlay and inlay material. *Ann Plast Surg* 1997;38:158-162.
 16. Nery EB, LeGeros RZ, Lynch KL, Lee K. Tissue response to biphasic calcium phosphate ceramic with different ratios of HA/beta TCP in periodontal osseous defects. *J Periodontol* 1992;63:729-735.
 17. Trisi P, Rao W, Rebaudi A, Fiore P. Histologic effect of pure-phase beta-tricalcium phosphate on bone regeneration in human artificial jawbone defects. *Int J Periodontics Restorative Dent* 2003;23:69-77.
 18. Draper HH. Bone loss in animals. *Adv Nutr Res* 1994;9:53-71.
 19. Suba Z, Takacs D, Gyulai-Gaal S, Kovacs K. Facilitation of beta-tricalcium phosphate-induced alveolar bone regeneration by platelet-rich plasma in beagle dogs: a histologic and histomorphometric study. *Int J Oral Maxillofac Implants* 2004;19:832-838.
 20. Wiltfang J, Schlegel KA, Schultze-Mosgau S, et al. Sinus floor augmentation with beta-tricalciumphosphate (beta-TCP): does platelet-rich plasma promote its osseous integration and degradation? *Clin Oral Implants Res* 2003;14:213-218.
 21. Daculsi G, LeGeros RZ, Nery E, Lynch K, Kerebel B. Transformation of biphasic calcium phosphate ceramics in vivo: ultrastructural and physicochemical characterization. *J Biomed Mater Res* 1989;23:883-894.
 22. Daculsi G, Passuti N, Martin S, et al. Macroporous calcium phosphate ceramic for long bone surgery in humans and dogs. Clinical and histological study. *J Biomed Mater Res* 1990;24:379-396.
 23. Quintero G, Mellonig JT, Gambill VM, Pelleu GB, Jr. A six-month clinical evaluation of decalcified freeze-dried boneallografts in periodontal osseous defects. *J Periodontol* 1982;53:726-730.
 24. Dragoo MR, Kaldahl WB. Clinical and histological evaluation of alloplasts and allografts in regenerative periodontal surgery in humans. *Int J Periodontics Restorative Dent* 1983;3:8-29.
 25. Renvert S, Nilveus R, Egelberg J. Healing after treatment of periodontal intraosseous defects. V. Effect of root planing versus flap surgery. *J Clin Periodontol* 1985;12:619-629.
 26. Froum SJ, Tarnow DP, Wallace SS, Rohrer MD, Cho SC. Sinus floor elevation using anorganic bovine bone matrix (OsteoGraf/N) with and without autogenous bone: a clinical, histologic, radiographic, and histomorphometric analysis--Part 2 of an ongoing prospective study. *Int J Periodontics Restorative Dent* 1998;18:528-543.
 27. Hallman M, Sennerby L, Lundgren S. A clinical and histologic evaluation of implant integration in the posterior maxilla after sinus floor augmentation with autogenous bone, bovine hydroxyapatite, or a 20:80 mixture. *Int J Oral Maxillofac Implants* 2002;17:635-643.
 28. Kim CS, Choi SH, Chai JK, et al. Periodontal repair in surgically created intrabony defects in dogs: influence of

- the number of bone walls on healing response. *J Periodontol* 2004;75:229-235.
29. Nery EB, Eslami A, Van Swol RL. Biphasic calcium phosphate ceramic combined with fibrillar collagen with and without citric acid conditioning in the treatment of periodontal osseous defects. *J Periodontol* 1990;61:166-172.
 30. Hashimoto-Uoshima M, Ishikawa I, Kinoshita A, Weng HT, Oda S. Clinical and histologic observation of replacement of biphasic calcium phosphate by bone tissue in monkeys. *Int J Periodontics Restorative Dent* 1995;15:205-213.
 31. Ellinger RF, Nery EB, Lynch KL. Histological assessment of periodontal osseous defects following implantation of hydroxyapatite and biphasic calcium phosphate ceramics: a case report. *Int J Periodontics Restorative Dent* 1986;6:22-33.
 32. Manjubala I, Sastry TP, Kumar RV. Bone in-growth induced by biphasic calcium phosphate ceramic in femoral defect of dogs. *J Biomater Appl* 2005;19:341-360.
 33. Lee YK, Kim HS, Cho KS, Kim KN, Choi SH. Investigation of bone formation using non-crystalline calcium phosphate glass in beagle dogs. *Key Engineering Materials* 2003;240-242:391-394.
 34. Baik DH, Hwang SJ, Kim CS, et al. The effects of non-crystalline calcium phosphate glass on the healing of 1-wall intrabony defects in beagle dogs. *J Korean Acad Periodontol* 2004;34:113-126.
 35. Choi SH, Baik DH, Kim CS, et al. Bone formation of intrabony defects in beagle dogs using calcium phosphate glass and glass-ceramics. *Key Engineering Materials* 2005; 284-286:957-960.
 36. Hyun SJ, Kim CS, Choi SH, Cho KS, Kim CK. The effects of paste type calcium sulfate on the periodontal healing of 3-wall intrabony defects in dogs. *J Korean Acad Periodontol* 2002;32:429-443.
 37. Cho KS, Choi SH, Han KH, et al. Alveolar bone formation at dental implant dehiscence defects following guided bone regeneration and xenogeneic freeze-dried demineralized bone matrix. *Clin Oral Implants Res* 1998;9:419-428.
 38. Min DH, Kim MJ, Yun JH, et al. Effects of calcium phosphate glass scaffold with chitosan membrane on the healing of alveolar bone in 1 wall intrabony defect in the beagle dogs. *Key Engineering Materials* 2005;284-286:851-854.