

The effects of Hydroxyapatite nano-coating implants on healing of surgically created circumferential gap in dogs

Gyung-Joon Chae¹, Hyun-Chang Lim¹, Jung-Yoo Choi¹, Sung-Min Chung², In-Seop Lee³,
Kyoo-Sung Cho¹, Chong-Kwan Kim¹, Seong-Ho Choi^{1*}

1. Department of Periodontology, Research Institute for Periodontal Regeneration, College of Dentistry, Yonsei University

2. Dentium[®]

3. Institute of Physics & Applied Physics, and Atomic-scale Surface Science Research Center, Yonsei University

ABSTRACT

Purpose: The aim of this study is to compare the healing response of various Hydroxyapatite(HA) coated dental implants by Ion-Beam Assisted Deposition(IBAD) placed in the surgically created circumferential gap in dogs.

Materials and methods: In four mongrel dogs, all mandibular premolars and the first molar were extracted. After an 8weeks healing period, six submerged type implants were placed and the circumferential cylindrical 2mm coronal defects around the implants were made surgically with customized step drills. Groups were divided into six groups : anodized surface, anodized surface with 150nm HA and heat treatment, anodized surface with 300nm HA and heat treatment, anodized surface with 150nm HA and no heat treatment, and anodized surface with 150nm HA, heat treatment and bone graft, anodized surface with bone graft. The dogs were sacrificed following 12 weeks healing period. Specimens were analyzed histologically and histomorphometrically.

Results: During the healing period, healing was uneventful and implants were well maintained. Anodized surface with HA coating and 430 °C heat treatment showed an improved regenerative characteristics. Most of the gaps were filled with newly regenerated bone. The implant surface was covered with bone layer as base for intensive bone formation and remodeling. In case that graft the alloplastic material to the gaps, most of the coronal gaps were filled with newly formed bone and remaining graft particles. The bone-implant contact and bone density parameters showed similar results with the histological findings. The bone graft group presented the best bone-implant contact value which had statistical significance.

Conclusion: Within the scope of this study, nano-scale HA coated dental implants appeared to have significant effect on the development of new bone formation. And additional bone graft is an effective method in overcoming the gaps around the implants. (*J Korean Acad Periodontol 2008;38:373-384*)

KEY WORDS: Hydroxyapatite; dental implant; surface coating; coronal gap.

Introduction

Dental implants are used to replace the missing tooth, and have been used for more than 50 years¹⁾. And now, dental implant treatment has obtained general consent by most clinicians worldwide. Implant

stability and osseointegration are most important factors in the success of implant treatment. The stability of an implant is determined by the mechanical properties of the implant-bone interface, and the osseointegration of the interface has been commonly evaluated by histomorphometric analysis²⁾. Many attempts have been made over the past years to improve bone anchorage of dental implants. Implants placed in non compromised conditions presented similar success rate irrespective of its own system. However, the placement of implant in compromised sites need the better and the faster osseointegration. Several studies presented that occurrence of dehiscence defect or co-

Correspondence: Dr. Seong-Ho Choi

Department of Periodontology, College of Dentistry, Yonsei University, Shinchon-dong 134, Seodaemun-gu, Seoul, 120-752, Korea.

e-mail: shchoi726@yuhs.ac, Tel: 82-2-2228-8825, FAX: 82-2-392-0398

* The research was supported by a grant (code #: 08K1501-01210) from 'Center for Nanostructured Materials Technology' under '21st Century Frontier R & D Program' of the Ministry of Education, Science and Technology, Korea.

Received: May 26, 2008; Accepted: Jun 28, 2008

ronal defect after implant placement results in poor osseointegration and increase the risk of implant failure. Nowadays, many implant systems are available and each system uses several types of surface treatment, aiming for optimal bone-implant contact. Several studies have shown that the existence of surface roughness increase bone-implant contact^{3,4}. The roughness seems to favor the migration of undifferentiated mesenchymal cells, which cover the implant surface and maximize new bone formation⁵. Many types of surface treatment have been proposed for increasing implant roughness. These include acid etching of the pure titanium surface, application of titanium plasma spray, blasting with different substances, oxidizing the TiO₂ surface, and incorporating hydroxyapatite (HA). Experimental studies using various rough surface implants demonstrated significantly higher removal torques, and a higher percentage of direct bone-implant contact³ than smooth surface titanium implants.

HA coated dental implants have shown excellent bone-to-implant contact and clinical survival rate⁶. HA is an osteoconductive and osteoinductive ceramic and it promotes strong biological bonding between implants and bone tissue. HA ceramics have biocompatibility, which induces superficial topographic irregularities. Laboratory animal studies and experiences with human suggested that HA coated dental implants could induce a chemical bond with bone and achieve biological fixation. Several studies have shown an increase of new bone formation in the initial stage of osseointegration with the development of osteophilic surface⁷. But controversy still persists over the long-term clinical effectiveness of HA-coated dental implants, because some reports suggest that the HA coating may separate from the substructure, undergo dissolution in tissue fluids, and contribute to rapid breakdown around the implants⁸⁻¹⁰. This failure may be due to the differences in chemical composition of the HA on the implant surface and the structural

changes of the coating, which dependent on coating method. HA coating on the dental implant can be applied by numerous methods. This includes electrophoretic deposition, dip coating, hot isostatic pressing, flame spraying, plasma spraying, and pulsed laser deposition. The most commonly used plasma spraying methods have some problems, ie, chemical non-uniformity of the coating layer and degradation in the physiologic human fluid. Also low adhesion strength between metal and HA coating still remains a problem⁶. Recently, nano coating of HA to the currently used implants or application of growth factors such as BMP have been developed for successful and better osseointegration. Of the several coating methods, ion beam-assisted deposition (IBAD) being recently developed to resolve these problems, has shown the favorable result¹¹. The aim of this study was to compare the healing response of various nano size HA coated dental implants by IBAD placed in the surgically created circumferential gap in dogs.

Materials and Methods

1. Animals

Four male Mongrel dogs, 18 to 24 months old and weighing about 30kg, were chosen. The animals had intact dentition and healthy periodontium. Animal selection, management, preparation and surgical protocol followed the routine procedure approved by the Animal Care and Use Committee, Yonsei Medical Center, Seoul, Korea.

2. Experimental design

Groups were divided according to implant surface characteristics and defect treatment methods. Gap defect width around all implants was 2mm. The anodized surface implants without any modification were placed in the Control group. The anodized surface implants

with HA coating (150nm thickness of HA layer and 430 °C heat treatment) were placed in the Experimental group 1 and the anodized surface implants with HA coating (300nm thickness of HA layer and 430 °C heat treatment) were placed in the Experimental group 2. The anodized surface implants with HA coating (150nm thickness of HA layer and no heat treatment) were placed in the Experimental group 3. Bone graft material was used in the Experimental group 4, 5. In the Experimental group 4, anodized surface implants were placed and bone graft material (Osteon[®], Dentium, KOREA) was applied in gap defect. In the Experimental group 5, anodized surface with HA coating (150nm thickness of HA layer and 430 °C heat treatment) was placed and bone graft material was applied in the gap defect.

3. Surgical procedures

Teeth were extracted under general anesthesia under sterile conditions in an operating room using Atropine 0.05mg/kg SQ, xylazine (Rompun[®], Bayer Korea, Seoul, Korea.) 2mg/kg, and ketamine hydrochloride (Ketalar[®], Yuhan Co., Seoul, Korea) 10mg/kg IV. Dogs were placed on a heating pad, intubated, administered 2% enflurane, and monitored with an electrocardiogram. After disinfecting the surgical sites, 2% lidocaine HCl with epinephrine 1:100,000 (Kwangmyung Pharm., Seoul, Korea) was administered by infiltration at the surgical sites. Crevicular incisions were made and all premolars (P1-P4) and the first molar (M1) were carefully extracted. Prior to extraction, P2-P4 and M1 were sectioned to avoid tooth fracture. Flaps were sutured with 5-0 resorbable su-

ture material (Polyglactin 910, braided absorbable suture, Ethicon, Johnson & Johnson Int., Edinburgh, U.K.) by the vertical mattress suture technique. On the day of the surgery, the dogs received 10mg/kg IV of the antibiotic Cefazoline (Yuhan Co., Seoul, Korea).

The implants (Implantium[®], Dentium, KOREA) were placed after a healing period of 8 weeks using the same surgical conditions as those for tooth extraction. A crestal incision was made to preserve keratinized tissue, and mucoperiosteal flaps were carefully reflected on the buccal and lingual aspects. The edentulous ridge was carefully flattened with a ridge contouring bur and irrigated with sterile saline. Three submerged type implants (3.4mm diameter, 10.0mm length) were placed on each side of the mandible. Implant osteotomy was performed at 800rpm under chilled saline irrigation. And circumferential defects of 2.0mm gaps were created surgically with a customized paralleled step drill. Implant placement was made without tapping to obtain good initial stability. In two groups (anodized surface implant, anodized surface coated 150nm HA with 430 °C heat treatment), additional bone graft (Osteon[®], Dentium, KOREA) was performed around the fixtures (Fig. 1, 2). Flaps were closed with a 5-0 resorbable suture material and implants were submerged. Post-operative care was similar as that for tooth extraction. Sutures were removed after 7 to 10 days and soft diet was provided throughout the study period.

Dogs were sacrificed after 12 weeks after. Euthanasia was performed by anesthesia drug overdose. Block sections including segments with implants were preserved and fixed in 10% neutral buffered formalin.




Figure 1. Clinical photograph representing the experiment site.

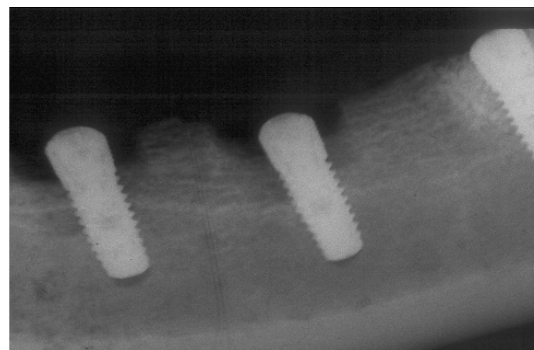


Figure 2. Radiographic view of the experimental site.

4. Histologic and histometric analysis

The specimens were dehydrated in ethanol, embedded in methacrylate, and sectioned in the mesio-distal plane using a diamond saw (Exakt®, Apparatebau, Norderstedt, Germany). From each implant site, the central section was reduced to a final thickness of about 20 μ m by micro-grinding and polishing with a cutting-grinding device (Exakt®). The sections were stained in hematoxiline-eosine.

General histological findings were observed with a stereoscope (LEICA MZFLIII, LEICA, WETZLAR, Germany) and microscope. After conventional microscopic examinations, computer-assisted histometric measurements were obtained using an automated image analysis system (Image-Pro Plus®, Media Cybernetics, Silver Spring, M.D.) coupled with a video camera mounted on a light microscope (LEICA DM-LB, LEICA, WETZLAR, Germany). The measuring parameters were as follows.

- 1) Bone to implant contact percentage(BIC%) in the coronal 5mm of the implant.
- 2) Newly formed bone density(%) within the threads in the coronal 5mm of the implant.

5. Statistical Analysis

The means and the standard deviation for each of the 6 groups were calculated. The significance of the difference for the groups was determined by the Kruskal-Wallis test ($P < 0.05$).

Results

1. Clinical findings

During the postoperative period, healing was uneventful and implants were well-maintained. There were no signs of inflammation observed in the mucosa adjacent to the implants.

2. Histologic analysis

Histologic analysis of the implants demonstrated newly formed, compact, mature bone with nearby marrow space, but there were volumetric differences between groups (Fig. 1~6). In the control-anodized surface group, most of the coronal gaps were not filled with bone, and minimal new bone formation was shown (Fig. 3). Coronal gaps were filled with loose connective tissues, and apical migration of epithelium was observed. The microthreads portion of the implant in the control groups did not show osseointegration.

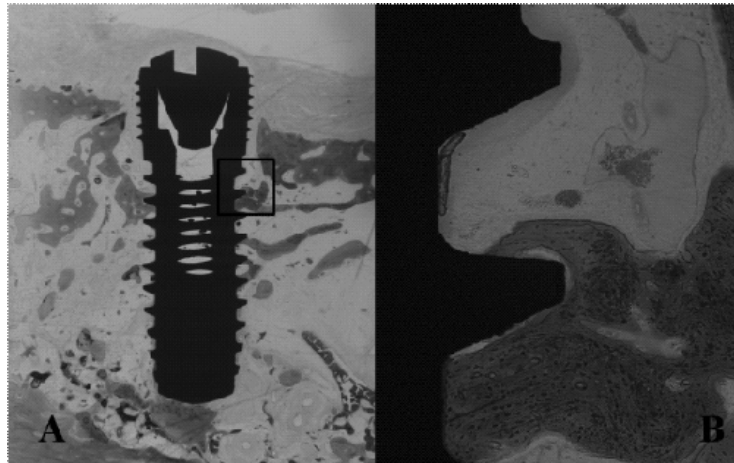


Figure 3. Histologic view of control group. (Anodized surface implant) A: magnification ($\times 10$), B: H-E staining ($\times 100$).

The Experimental group 1, 2 –anodized surface with HA coating and 430°C heat treatment showed an improved regenerative characteristics (Fig. 4, 5). Most of the gaps were filled with newly regenerated bone. The implant surface was covered with bone layer as base for intensive bone formation and remodeling. Osteoblasts were lined with the implant surface and showed favorable contact osteogenesis. Especially experimental group 1–150nm coating and 430°C heat treatment– showed more favorable bone formation. Most of the newly formed bone was compact and

mature. The coronal microthread portion showed no connective tissue invagination and epithelial migration (Fig. 2). In experimental group 2–300nm coating and 430°C heat treatment, there was also good bone filling around the implant surface, but there were some bony resorption in the coronal microthreads portion (Fig. 3). The two or three microthreads of the most coronal part did not show bone fill and osseointegration, but the other part of the implant was lined with newly formed bone just as the experimental group 1.

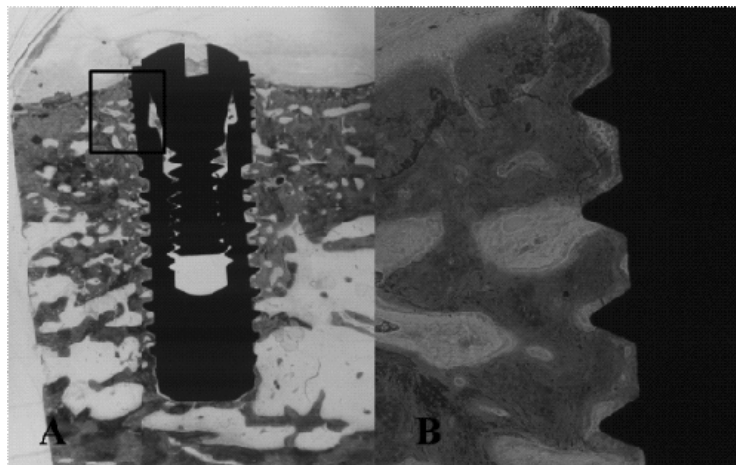


Figure 4. Histologic view of experimental group 1. (Anodized surface + HA 150nm coating + 430°C heat treatment implant) A: magnification ($\times 10$), B: H-E staining ($\times 100$).

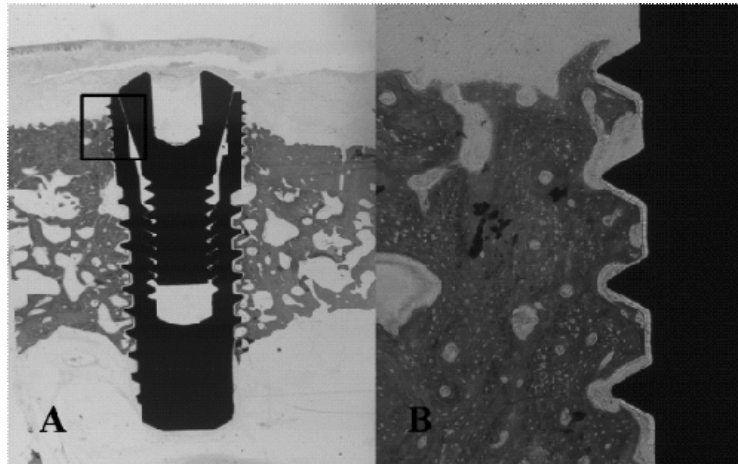


Figure 5. Histologic view of experimental group 2, (Anodized surface + HA 300nm coating +430 °C heat treatment implant) A: magnification ($\times 10$), B: H-E staining ($\times 100$).

Experimental group 3 –anodized surface with 150nm HA coating and no heat treatment–showed minimal bone fill and less osteointegration as that of the con-

trol (Fig. 6). There was connective tissue invasion and bony resorption in the coronal microthreads.

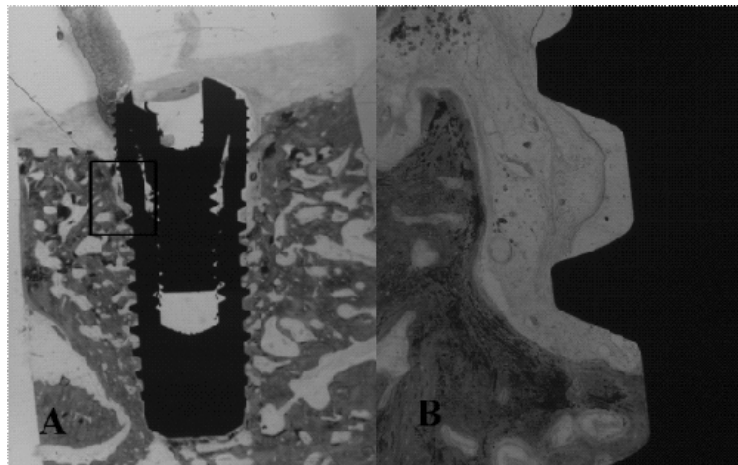


Figure 6. Histologic view of experimental group 3, (Anodized surface + HA 150nm coating no heat treatment implant) A: magnification ($\times 10$), B: H-E staining ($\times 100$).

In grafted case, the alloplastic material to the gaps–experimental group 4, 5–, most of the coronal gaps were filled with newly formed bone and the remaining graft particles (Fig. 7, 8). The newly formed bone was observed above the implant top and favorable bone to implant contact was also seen. Some

grafted materials were remained without resorption and were surrounded by the new bone. The newly formed bone trabeculae were present, which were composed mostly of woven bone. New bone was in direct apposition to the HA particles and implant titanium surface.

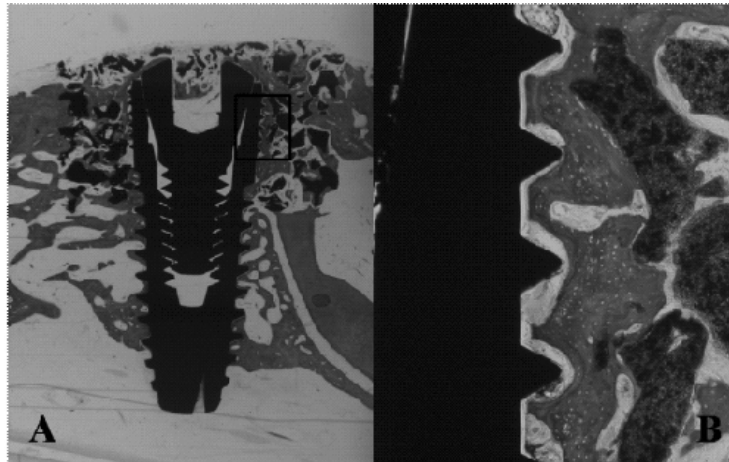


Figure 7. Histologic view of experimental group 4, {Anodized surface implant + Bone (Osteon[®]: HA+TCP) graft} A: magnification (×10), B: H-E staining (×100).

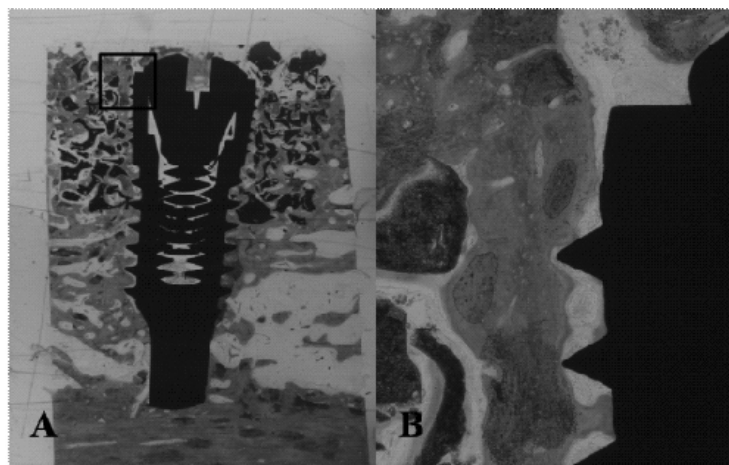


Figure 8. Histologic view of experimental group 5, {Anodized surface + HA 150nm coating +430°C heat treatment implant + Bone(Osteon[®]: HA+TCP) graft} A: magnification (×10), B: H-E staining (×100).

3. Histometric analysis

The results from the histometric analysis are presented in Table 1, 2.

The BIC and bone density parameters showed similar results with the histological findings. The bone graft group presented the best BIC value which had statistical significance. Experimental group 1 pre-

sented the highest mean value in bone density, which was statistically significant. The anodized surface with HA coatings and 430°C heat treatment showed favorable results in terms of BIC and the bone density compared to the control and no heat treatment groups. But there was no statistical significance between those groups

Table 1. Bone to Implant Contact Percentage(BIC %) in the Coronal 5mm of the Implant

	Mean (n=4)
Control(Anodized surface)	28.8±9.9
Experimental 1(Anodized HA 150nm, 430 °C)	49.6±11.2
Experimental 2(Anodized HA 300nm, 430 °C)	36.8±10.8
Experimental 3(Anodized HA 150nm, no heat)	27.6±10.6
Experimental 4(Anodized+Bone graft)	57.1 †±11.6
Experimental 5(Anodized HA 150nm, 430 °C+bone graft)	50.5 †±12.1

† statistical significance P<0.05.

Table 2. Newly Formed Bone Density(%) within the Threads in the Coronal 5mm of the Implant

	Mean (n=4)
Control(Anodized surface)	33.8±12.4
Experimental 1(Anodized HA 150nm, 430 °C)	59.9 †±11.6
Experimental 2(Anodized HA 300nm, 430 °C)	43.1±12.9
Experimental 3(Anodized HA 150nm, no heat)	30.6±15.2
Experimental 4(Anodized+Bone graft)	53.1±11.8
Experimental 5(Anodized HA 150nm, 430 °C+bone graft)	47.5±13.5

† statistical significance P<0.05.

Discussion

In the late 1950s, Brånemark predictably achieved an intimate bone-to-implant apposition that offered sufficient strength to cope with load transfer. This phenomenon is called "osseointegration" and after that a series of screw-shaped, commercially pure titanium implants were inserted in the edentulous area. Since that time, millions of patients have been treated worldwide using dental implant, and now, dental implant treatment has obtained general consent by most of the clinicians. A key element in the reaction of hard and soft tissues to an implant involves the implants surface characteristics—the chemical and physical properties. It is generally believed that the rough surfaces accelerate the initial healing phase and enhance bone formation at the implant surface^{4,12,13}. Roughening the topography of the implant surface by applying a porous coating or surface treatments may promote osteogenesis by enhancing osteoblast metabolic activity and cellular adhesion, increasing surface area, and stabilizing the fibrin scaffold. Thus faster

bone apposition can be achieved with roughened surfaces compared to machined surfaces¹⁴. The chemical nature of the implant surface can be modified by surface coating. Some materials, as well as various surface characteristics, enhance bone apposition at the implant surface in an osteoconductive manner. Calcium phosphate, especially HA have been a popular coating material because of its resemblance to bone tissue. HA is an osteoconductive and osteoinductive ceramic and it promotes strong biological bonding between implants and bone tissue. Although long-term clinical studies have presented highly successful results for HA-coated implants^{6,7,15}, some researchers have expressed concerns about the potential for dissolution, resorption, and detachment of the coating, which may promote the loss of osseointegration⁸⁻¹⁰. Usually this may be due to the macroscopically visible surface roughness. Macroscopically rough surfaces have the tendency of progressive bone loss, susceptibility to the contamination of oral bacteria and leading ultimately to implant loss.

In the present study, nano scaled HA coated im-

plants were used. Basically used implants had an anodized surface. This surface used titanium oxide (TiO_2) layers to enhance or accelerate the bone formation. In our study, we hypothesized that combining the anodized surface and HA deposition would have synergistic effect, and used 150nm or 300nm thickness HA coated implants to evaluate the effects of HA coatings on the anodized surface of endosseous dental implants whether osseointegration of implants with such HA coating occurs earlier. In analyzing the results of the histologic and histometric analysis, HA coated dental implant showed favorable results compared to the control anodized surface implant. Anodized surface implant group showed minimal bone fill of the surgically created gaps, low BIC and bone density value. The HA coated implant groups presented almost double sized value in BIC and bone density and the gaps were almost filled with newly regenerated bone. Especially 150nm HA coated implants showed more favorable results than 300nm coated implants. In bone density parameter, 150nm HA coated implant group showed statistically different value compared to 300nm coated implant group. Anodized implants have its own micropores on the surface and average roughness is about $0.37\mu\text{m}$. When very thick layer of HA is coated on the anodized implant, the micropores are blocked by HA particles¹⁶⁾. Our results may be due to these characteristics of oxidized implant. And HA must be resorbed according to the bone healing time and must be replaced with bone. However, it is unfavorable for the bone to be replaced and takes more time to resorb as the layer gets thicker.

In terms of heat treatment, we compared the same thickness HA coated implant with or without of 430°C heat treatment. Oonishi et. al¹⁷⁾ suggested that the amorphous phase of the coatings, which has a greater resorption in vivo than crystalline HA coating, can accelerate the early fixation of the implant with bony tissue and promote fast bone remodeling and attachment. However, it is also known that a high

concentration of amorphous phase in the coating layer can cause excessive dissolution and consequently reduce the coating integrity of the implants. In addition, in vitro and vivo research also suggested that the crystallinity of HA coatings is essential to their biocompatibility and early performance compared to machined implants^{18,19)}. In our results, anodized surface with HA coating, no heat treatment showed minimal bone fill and less osseointegration as that of the control group. The reason for this being is that there is fast melting characteristic with amorphous HA layer when there is no heat treatment, in consequent, there is an unfavorable effect in terms of osseointegration and there happens to be a gap between the implant surface and the bone surface.

In this study, circumferential parallel 2mm defect was created surgically. Several studies suggested that gaps larger than 2mm resulted in a smaller amount of direct bone to implant contact^{20,21)}. Clinically many methods have been introduced to overcome the coronal gap associated with immediate implant²²⁻²⁴⁾. Additionally, bone particles were grafted into the surgically created gaps for evaluating the synergistic effects of bone materials and HA surface of implants. Bone material (Osteon[®]) is the mixture of HA and beta-tricalcium phosphate (β -TCP). HA provides a good scaffold for the new bone to growth, but has poor regeneration potential. β -TCP has good bone regeneration potential, but is not able to provide sufficient space for bone growth. Mixing HA and β -TCP permits the association between the physic-chemical properties of each compound. Recent studies have suggested the stability and effectiveness of the mixture of HA and β -TCP^{25,26)}. The present study showed the superior results in histologic and histometric analysis. Most of the gap areas were filled with newly formed bone. In some histologic view, we can see that the new bone was formed above the implant top. In BIC and bone density parameters, it also showed also favorable values compared to the other groups.

The object of this study was to evaluate the effects of HA coating to the anodized surface of dental implant, and the synergistic effects of bone graft. As a result, the thin coating of HA to the implant surface enhanced the osseointegration even in the surgically created gaps. And additional bone graft synergistically promoted the new bone formation in HA coated dental implants.

In conclusion, even if more researches are necessary on the long term effects of HA coated implants, HA coated dental implants appeared to have significant effects on the development of new bone formation. And additional bone graft is an effective method in overcoming the gaps around the implants.

References

- Albrektsson T, Jansson T, Lekholm U. Osseointegrated dental implants. *Dent Clin North Am* 1986;30:151-74.
- Johansson CB, Albrektsson T. A removal torque and histomorphometric study of commercially pure niobium and titanium implants in rabbit bone. *Clin Oral Implants Res* 1991;2:24-29.
- Buser D, Schenk RK, Steinemann S, *et al.* Influence of surface characteristics on bone integration of titanium implants. A histomorphometric study in miniature pigs. *J Biomed Mater Res* 1991;25:889-902.
- Buser D, Nydegger T, Hirt HP, *et al.* Removal torque values of titanium implants in the maxilla of miniature pigs. *Int J Oral Maxillofac Implants* 1998;13:611-619.
- Cochran DL, Simpson J, Weber HP, Buser D. Attachment and growth of periodontal cells on smooth and rough titanium. *Int J Oral Maxillofac Implants* 1994;9:289-297.
- McGlumphy EA, Peterson LJ, Larsen PE, Jeffcoat MK. Prospective study of 429 hydroxyapatite-coated cylindrical omniloc implants placed in 121 patients. *Int J Oral Maxillofac Implants* 2003;18:82-92.
- Thomas KA, Kay JF, Cook SD, Jarcho M. The effect of surface macrotexture and hydroxylapatite coating on the mechanical strengths and histologic profiles of titanium implant materials. *J Biomed Mater Res* 1987;21:1395-1414.
- Biesbrock AR, Edgerton M. Evaluation of the clinical predictability of hydroxyapatite-coated endosseous dental implants: a review of the literature. *Int J Oral Maxillofac Implants* 1995;10:712-720.
- Hanisch O, Cortella CA, Boskovic MM, *et al.* Experimental peri-implant tissue breakdown around hydroxyapatite-coated implants. *J Periodontol* 1997;68:59-66.
- Liao H, Fartash B, Li J. Stability of hydroxyapatite-coatings on titanium oral implants (IMZ). 2 retrieved cases. *Clin Oral Implants Res* 1997;8:68-72.
- Jeffcoat MK, McGlumphy EA, Reddy MS, *et al.* A comparison of hydroxyapatite (HA) -coated threaded, HA-coated cylindrical, and titanium threaded endosseous dental implants. *Int J Oral Maxillofac Implants* 2003;18:406-410.
- Ericsson I, Johansson CB, Bystedt H, Norton MR. A histomorphometric evaluation of bone-to-implant contact on machine-prepared and roughened titanium dental implants. A pilot study in the dog. *Clin Oral Implants Res* 1994;5:202-206.
- Klokkevold PR, Nishimura RD, Adachi M, Caputo A. Osseointegration enhanced by chemical etching of the titanium surface. A torque removal study in the rabbit. *Clin Oral Implants Res* 1997;8:442-447.
- Wong M, Eulenberger J, Schenk R, Hunziker E. Effect of surface topology on the osseointegration of implant materials in trabecular bone. *J Biomed Mater Res* 1995;29:1567-1575.
- Block MS, Gardiner D, Kent JN, *et al.* Hydroxyapatite-coated cylindrical implants in the posterior mandible: 10-year observations. *Int J Oral Maxillofac Implants* 1996;11:626-633.
- Sul YT, Johansson C, Wennerberg A, *et al.* Optimum surface properties of oxidized implants for reinforcement of osseointegration: surface chemistry, oxide thickness, porosity, roughness, and crystal structure. *Int J Oral Maxillofac Implants* 2005;20:349-359.
- Oonishi H, Hench LL, Wilson J, *et al.* Comparative bone growth behavior in granules of bioceramic materials of various sizes. *J Biomed Mater Res* 1999;44:31-43.
- Ong JL, Bessho K, Cavin R, Carnes DL. Bone response to radio frequency sputtered calcium phosphate implants and titanium implants in vivo. *J Biomed Mater Res* 2002;59:184-190.
- ter Brugge PJ, Jansen JA. Initial interaction of rat bone marrow cells with non-coated and calcium phosphate coated titanium substrates. *Biomaterials* 2002;23:269-277.

20. Akimoto K, Becker W, Persson R, et al. Evaluation of titanium implants placed into simulated extraction sockets: a study in dogs. *Int J Oral Maxillofac Implants* 1999;14:351-360.
21. Knox R, Caudill R, Meffert R. Histologic evaluation of dental endosseous implants placed in surgically created extraction defects. *Int J Periodontics Restorative Dent* 1991;11:364-375.
22. Werbitt MJ, Goldberg PV. The immediate implant: bone preservation and bone regeneration. *Int J Periodontics Restorative Dent* 1992;12:206-217.
23. Becker W, Dahlin C, Becker BE, et al. The use of e-PTFE barrier membranes for bone promotion around titanium implants placed into extraction sockets: a prospective multicenter study. *Int J Oral Maxillofac Implants* 1994;9:31-40.
24. Lang NP, Bragger U, Hammerle CH, Sutter F. Immediate transmucosal implants using the principle of guided tissue regeneration. I. Rationale, clinical procedures and 30-month results. *Clin Oral Implants Res* 1994;5:154-163.
25. Cornell CN, Lane JM. Current understanding of osteoconduction in bone regeneration. *Clin Orthop Relat Res* 1998:S267-273.
26. Schopper C, Ziya-Ghazvini F, Goriwoda W, et al. HA/TCP compounding of a porous CaP biomaterial improves bone formation and scaffold degradation--a long-term histological study. *J Biomed Mater Res B Appl Biomater* 2005;74:458-467.

