

Sonographic Features of Axillary Lymphadenopathy Caused by Kikuchi Disease

Ji Hyun Youk, MD, Eun-Kyung Kim, MD,
Kyung Hee Ko, MD, Min Jung Kim, MD

Objective. The purpose of this study was to document the sonographic findings of axillary lymphadenopathy in Kikuchi disease. **Methods.** The medical records and sonographic findings of 7 patients with a pathologic diagnosis of Kikuchi disease in the axillary lymph node by sonographically guided core needle biopsy (n = 6) or excisional biopsy (n = 1) were reviewed. On sonograms, lymph nodes were assessed for their distribution, size, shape, border, echogenicity, and internal architecture, and those sonographic features of each node were evaluated to determine whether the findings favored malignant or benign lymphadenopathy. **Results.** Of the 7 patients (1 man and 6 women; mean age \pm SD, 34.3 \pm 7.7 years), 29 affected lymph nodes (5–38 mm; mean, 14.8 \pm 7.2 mm) were identified on sonograms. The sonographic characteristics were as follows: the shortest axis/longest axis ratio of the node (mean, 0.595) was 0.5 or greater in 22 nodes (76%); the border was sharp in 16 (55%); the cortex was hypoechoic in 20 (69%) and isoechoic in 9 (31%); the hilum was narrow in 1 (4%) and absent in 16 (55%); and cortical thickening was found in 13 (45%, concentric in 6 and eccentric in 7). Nineteen lymph nodes (66%) were classified as having malignant-favoring features, and 10 (34%) were classified as having benign-favoring features. **Conclusions.** Many axillary lymph nodes in Kikuchi disease look suspicious sonographically. When lymph nodes in the axilla show suspicious findings on sonograms of relatively young patients, Kikuchi disease can be considered a possible differential diagnosis, and image-guided percutaneous biopsy should be done. **Key words:** axilla; Kikuchi disease; lymph node; sonography.

Abbreviations

S/L, shortest axis/longest axis

Received January 31, 2008, from the Department of Radiology, Bundang CHA Hospital, Pochon CHA University, Sungnam, Korea (J.H.Y., K.H.K.); and Department of Radiology, Research Institute of Radiological Science, Yonsei University College of Medicine, Seoul, Korea (E.-K.K., M.J.K.). Revision requested February 28, 2008. Revised manuscript accepted for publication March 6, 2008.

Address correspondence to Eun-Kyung Kim, MD, Department of Radiology, Yonsei University College of Medicine, Seodaemun-ku, Shinchondong 134, Seoul 120-752, Korea.
E-mail: ekkim@yuhs.ac

Kikuchi disease, also known as Kikuchi-Fujimoto disease or histiocytic necrotizing lymphadenitis, is an uncommon cause of benign lymphadenopathy that was first described independently by Kikuchi¹ and Fujimoto et al² in 1972. They described the distinctive histologic appearance of the lymph nodes as “lymphadenitis showing reticulum cell hyperplasia with nuclear debris and phagocytosis” and “cervical subacute necrotizing lymphadenitis,” respectively. It is a self-limiting disease that revolves spontaneously, generally within 1 to 4 months, although in rare cases lymphadenopathy may persist for up to 1 year after diagnosis.^{3–5}

Initially regarded as a unique type of lymphadenitis occurring predominantly in cervical lymph nodes of young Southeast Asian women, it is now recognized that this disease can affect patients regardless of age, sex, or ethnic background and can involve any anatomic site, including nodal and extranodal locations such as the skin, bone marrow, liver, spleen, and gastrointestinal

tract.³ Involvement of nodal areas other than cervical has been described, including axillary, thoracic, abdominal, and pelvic.⁶

There have been a few reports about radiologic findings of Kikuchi disease, which described cervical lymph node involvement and were primarily focused on computed tomographic findings.⁷⁻¹¹ To our knowledge, however, there has been no published study of the sonographic findings of axillary lymph node involvement in Kikuchi disease, although the sonographic findings of cervical lymph node involvement have been reported in a few studies.¹³ We found only scarce mention of axillary lymph node involvement in a few case reports.¹⁴⁻¹⁸ In this study, we retrospectively analyzed the sonographic findings of axillary lymphadenopathy in Kikuchi disease.

Materials and Methods

We conducted a database search of pathologic records from February 2000 through August 2007 and found 7 patients with a histologically proven diagnosis of Kikuchi disease in axillary lymph nodes. We retrospectively reviewed the medical records and the radiologic examinations of these patients. The Institutional Review Board approved this retrospective study, and informed consent was not required.

All patients underwent gray scale sonographic examinations of the axilla, which were performed with high-resolution sonography units with 7.5- or 12-MHz linear array transducers (HDI 3500 and iU22 systems, Philips Medical Systems, Bothell, WA). The diagnosis of Kikuchi disease was reached by means of sonographically guided core needle biopsy in 6 patients and excisional biopsy in 1 patient. Sonographically guided biopsy was performed on the largest node by a freehand technique using a 14- or 16-gauge spring-loaded Tru-Cut needle with a 22-mm throw (Pro-Mag 2.2, Manan Medical Products, Inc, Northbrook, IL; Magnum, C. R. Bard, Inc, Tempe, AZ; and SACN biopsy needle, Medical Device Technologies, Gainesville, FL). We assumed that other nodes in the axilla with gray scale appearances similar to those of the sampled node would be the same pathologically, and these nodes were also included in the study. All sonographic examinations and biopsy procedures were performed by the 1 of 4

radiologists with extensive clinical experience in sonography and biopsy.

On sonography, lymph nodes were assessed for their distribution, size, shape, border demarcation, echogenicity, and internal architecture. The distribution of lymphadenopathy in the axilla was classified into 3 levels relative to the pectoralis minor muscle¹⁹: level I consisted of nodes below the lateral border of the muscle; level II consisted of nodes behind the muscle; and level III consisted of nodes above the medial border of the muscle. The size of the lymph node was defined as its length along the longest axis as measured on the images. The shape of the lymph node was assessed by its shortest axis/longest axis (S/L) ratio. An S/L ratio of less than 0.5 indicated a long or an elliptical node, whereas an S/L ratio of 0.5 or greater indicated a round node.^{20,21} The nodal border was classified as sharp or unsharp compared with surrounding fatty tissue. The echogenicity of the lymph node was compared with that of adjacent muscles and was categorized as hypoechoic, isoechoic, or hyperechoic. The internal architecture of the node was evaluated for the echogenic fatty hilum (wide, narrow, or absent) and cortical thickening (concentric or eccentric).²¹ When the hilum appeared elliptical in the longitudinal plane, generally conforming to the shape of the whole node, it was classified as wide. A flat, slitlike hilum was considered narrowed. Those nodes that showed no central zone of hyperechogenicity were classified as having no hilum. For evaluation of cortical thickening, the cortex was considered thickened when the thickness at its broadest point was half the transverse diameter of the hilum or greater in the longitudinal plane. Those nodes that showed focal cortical widening of at least 100% (ie, the thickness of the cortex at one site was at least double that at its narrowest point) were classified as having eccentric cortical thickening. If the nodal hilum (the reference structure) was absent, cortical thickening could not be assessed.²¹ In addition, the sonographic findings of each axillary lymph node were analyzed to determine whether the findings favored malignant or benign lymphadenopathy. Abnormal sonographic findings favoring malignant axillary lymph nodes were a round shape, a sharp border, an abnormal sonographic

appearance of the cortex, which included diffuse or focal thickening of the cortex or hypoechogenicity, and a narrow or absent fatty hilum. If at least 3 of those findings were shown, the lymph node was classified as having malignant-favoring features.²²⁻²⁴ All images were analyzed by 2 experienced radiologists with consensus.

Results

Patient Characteristics

The patients' clinical characteristics are summarized in Table 1. The patients' ages ranged from 22 to 42 years (mean \pm SD, 34.3 \pm 7.7 years), and 6 of them were women. All patients had swelling in the axilla (4 right, 2 left, and 1 bilateral). The duration of symptoms ranged from 5 days to 3 months (mean, 24.6 \pm 31.1 days). Physical examinations revealed palpable axillary masses in all 7 patients and a low-grade fever in 1. On laboratory evaluation, the patient with the fever had leukopenia (white blood cell count, 2600/mm³), but the others had nonspecific results. For all patients, there was no clinical or radiologic evidence of Kikuchi disease involvement in other organs, and their clinical symptoms resolved without any specific treatment by follow-up.

Sonographic Characteristics of Lymph Nodes

In the 7 patients, 29 affected lymph nodes (size, 5–38 mm; mean, 14.8 \pm 7.2 mm) identified on sonograms were included in this study. For the distribution of lymphadenopathy in the axilla, in 4 patients, the lymphadenopathy was confined to level I, and in the other 3, it was detected from level I through level II or III (Table 1).

Table 2 shows the results of sonographic assessment in each node. The S/L ratio ranged from 0.15 to 1 (mean, 0.60 \pm 0.22). In 7 (24%) of 29

lymph nodes, the S/L ratio (mean, 0.595) was less than 0.5 (Figures 1 and 2), and in 22 (76%), the S/L ratio was 0.5 or greater (Figures 3 and 4). The nodal border was sharp in 16 nodes (55%) and unsharp in 13 (45%; Figure 2). The nodal cortex was hypoechoic in 20 nodes (69%) and isoechoic in 9 (31%). The hilum was wide in 12 nodes (41%; Figures 1 and 2), narrow in 1 (4%; Figure 3), and absent in 16 (55%; Figure 4). Cortical thickening was found in 13 nodes (45%), and the thickening was concentric in 6 (46%; Figures 1 and 3) and eccentric in 7 (54%; Figure 2). In the combined evaluation of abnormal sonographic findings, 19 lymph nodes (66%) were classified as having malignant-favoring features, and 10 (34%) were classified as having benign-favoring features.

Discussion

Kikuchi disease classically presents as painful cervical lymphadenopathy in young adults, usually female. Cervical lymph nodes are the primary sites of this disease in 70% to 98% of cases.¹⁴ However, virtually any nodal chain can be involved, and axillary, supraclavicular, mediastinal, celiac, peripancreatic, and inguinal locations have been reported.⁹ Most reports about radiologic findings of Kikuchi disease described cervical lymph node involvement. Fulcher⁸ reported the sonographic findings of Kikuchi disease in the neck, consisting of multiple enlarged lymph nodes that were homogeneous and surrounded by a hyperechoic rim. These sonographic findings were similar to those described by Ogawa et al,¹³ except for the heterogeneous texture found in the latter study. Ying et al¹² reported the sonographic findings of 6 cervical lymph nodes in Kikuchi disease. They were hypoechoic (6 [100%]), were predominantly

Table 1. Characteristics of 7 Patients With Kikuchi Disease in the Axillary Lymph Nodes

Patient	1	2	3	4	5	6	7
Sex	M	F	F	F	F	F	F
Age, y	38	28	30	38	42	22	42
Site*	R, I	B, I	R, I-III	L, I, II	R, I	L, I-III	R, I
Palpation	Yes	Yes	Yes	Yes	Yes	Yes	Yes
Duration of symptoms, d	5	5	7	5	30	30	90
Involved lymph nodes, n	4	5	5	4	3	6	2

B indicates bilateral; F, female; L, left; M, male; and R, right.

*The axillary lymph nodes were classified into levels I to III according to their proximity to a pectoralis minor muscle.

elliptical or oval with an S/L ratio of less than 0.5 (5 [83.3%]), tended to have an echogenic hilum (4 [66.7%]) and an unsharp border (4 [66.7%]), and were found to be similar to reactive nodes, for which there was no significant difference in sonographic findings compared with Kikuchi disease. Of axillary lymph node involvement in Kikuchi disease, only a few case reports or series have been published, and the information about the radiologic findings has been limited. The sonographic findings of a conglomerate of a few enlarged hypoechoic lymph nodes¹⁶ and an oval predominantly hypoechoic lymph node with cortical thickening¹⁴ were described in 2 case reports.

According to Esen²³ and Lernevall,²⁵ there are several sonographic characteristics of malignant lymph nodes in the axilla. Pathologic nodes tend to become more rounded; therefore, a high S/L ratio (>0.5) increases suspicion of malignancy,

whereas a low S/L ratio (<0.5) indicates that a node is benign. Malignant lymph nodes usually have sharp borders, and their cortex tends to become markedly hypoechoic compared with adjacent muscles. Eccentric enlargement with focal thickening of the cortex, at least doubling, is a strong indicator of malignant transformation. Compression of the hilum and especially absence of the hilum are highly suggestive of malignancy. In this study, the sonographic findings of axillary lymph nodes in Kikuchi disease were a predominantly round shape with an S/L ratio of 0.5 or greater (22 [76%] of 29), a tendency to show a hypoechoic cortex (20 [69%] of 29), a sharp border (16 [55%] of 29), a narrow or an absent echogenic hilum (17 [59%] of 29), and eccentric cortical thickening (7 [54%] of 13). All lymph nodes showed at least 1 malignant-favoring feature, and approximately two-thirds of them (66%) had 3 or more suspicious malignant findings. These results,

Table 2. Sonographic Characteristics of Axillary Lymph Nodes in Kikuchi Disease

Node	Size, mm	S/L Ratio	Border	Echogenicity	Hilum	Cortical Widening	Favoring Features
1	38	0.36	Sharp	Hypoechoic	Narrow	Concentric	Malignant
2	25	0.73	Sharp	Hypoechoic	Narrow	Concentric	Malignant
3	18	0.73	Sharp	Hypoechoic	Wide	Eccentric	Malignant
4	20	0.57	Sharp	Hypoechoic	Wide	Eccentric	Malignant
5	21	0.43	Sharp	Hypoechoic	Wide	Eccentric	Benign
6	18	0.38	Sharp	Hypoechoic	Wide	Concentric	Benign
7	18	0.59	Sharp	Hypoechoic	Wide	Concentric	Malignant
8	17	0.68	Sharp	Hypoechoic	Wide	Concentric	Malignant
9	12	0.57	Unsharp	Isoechoic	Wide	Concentric	Benign
10	21	0.5	Sharp	Hypoechoic	Absent	NA	Malignant
11	8	0.81	Unsharp	Hypoechoic	Absent	NA	Malignant
12	9	0.9	Unsharp	Hypoechoic	Absent	NA	Malignant
13	7	0.71	Sharp	Isoechoic	Absent	NA	Malignant
14	5	0.52	Sharp	Isoechoic	Absent	NA	Malignant
15	17	0.15	Sharp	Hypoechoic	Absent	NA	Benign
16	12	0.78	Unsharp	Hypoechoic	Absent	NA	Malignant
17	10	0.88	Sharp	Hypoechoic	Absent	NA	Malignant
18	7	0.52	Unsharp	Hypoechoic	Absent	NA	Malignant
19	15	0.56	Sharp	Isoechoic	Absent	NA	Malignant
20	7	0.9	Unsharp	Isoechoic	Absent	NA	Malignant
21	6	0.8	Unsharp	Isoechoic	Absent	NA	Malignant
22	17	0.24	Unsharp	Hypoechoic	Wide	Eccentric	Benign
23	12	0.57	Unsharp	Hypoechoic	Wide	Eccentric	Benign
24	12	0.5	Unsharp	Isoechoic	Absent	NA	Benign
25	11	1	Unsharp	Hypoechoic	Absent	NA	Malignant
26	10	0.7	Sharp	Hypoechoic	Absent	NA	Malignant
27	12	0.59	Unsharp	Isoechoic	Absent	NA	Benign
28	25	0.18	Unsharp	Hypoechoic	Wide	Eccentric	Benign
29	20	0.43	Sharp	Isoechoic	Wide	Eccentric	Benign

NA indicates not applicable.

considered to favor the appearance of malignant lymphadenopathy, are contrary to those of Ying et al¹² mentioned above. Such a discrepancy may be attributable to the small sample size and differences in the anatomic location, study population, methods, and radiologic details from which to draw conclusions. Also, the malignant-favoring sonographic features of Kikuchi disease found in this study could not have been distinct because more than a few lymph nodes showed benign-favoring features, and there was an overlap between reactive and malignant nodes in the sonographic criteria described above.²⁵ The results did not show any specific sonographic features of Kikuchi disease in the axilla; therefore, further investigation with a larger patient database is necessary to validate these results.

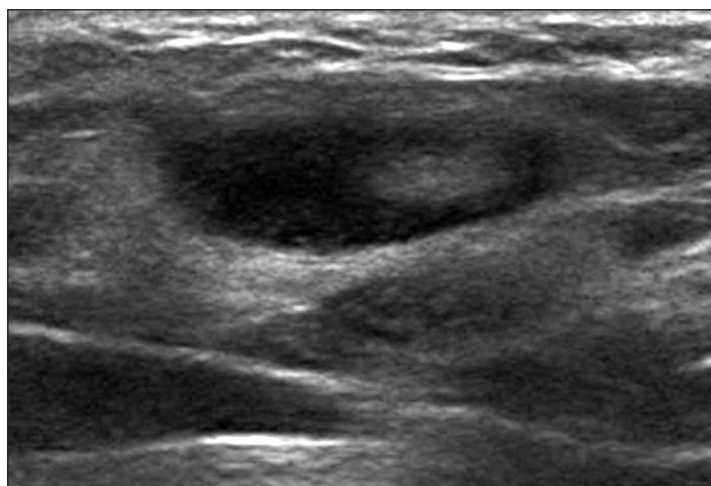
In the axilla, lymph node enlargement is undoubtedly the most common pathologic finding.²⁶ Most cases in which lymphadenopathy is associated with visible breast cancer represent metastatic breast disease. In those with no visible breast disease, such as this study population, various conditions such as connective tissue disease (commonly rheumatoid arthritis), infections, benign reactive nodes, hematologic malignancies, occult carcinomas, and metastatic tumors other than breast cancer can be considered as differential diagnoses.^{27,28} However, even these conditions usually present as sonographically nonspecific lymphadenopathy. Therefore, it would be a challenge to differentiate the cause of axillary lymphadenopathy by imaging studies alone, prompting histopathologic examinations. Sonographically guided fine-needle aspiration biopsy of lymph nodes is common and has been an accurate method for diagnosing malignancy. For the diagnosis of Kikuchi disease, this procedure may show the characteristic pathologic features, but it is frequently nonspecific or non-diagnostic, and excisional biopsy is needed for a definitive diagnosis.^{5,29} In this study, 1 patient who had undergone excisional biopsy initially underwent sonographically guided fine-needle aspiration biopsy, which yielded a nonspecific diagnosis negative for malignancy. For sonographically guided core needle biopsy, Kim et al³⁰ reported that Kikuchi disease in cervical lymph nodes was definitely diagnosed by that procedure in all 25 of their patients, which prevented most

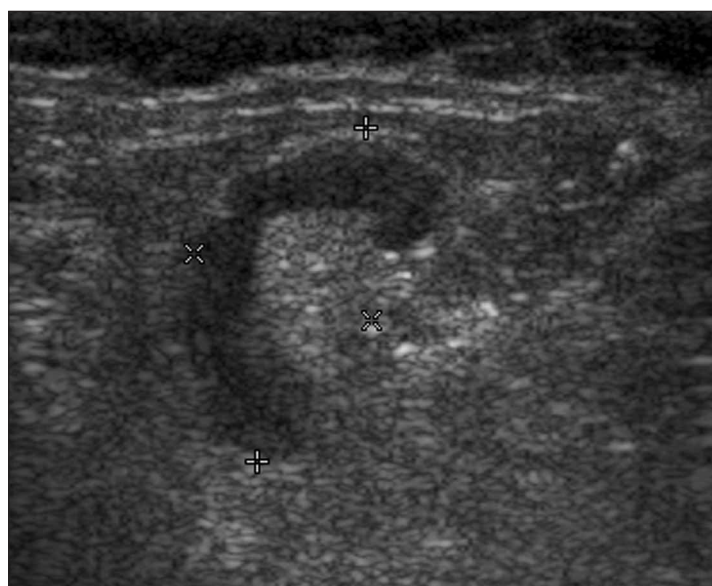

Figure 1. Gray scale sonogram of an axillary lymph node classified as benign in a 28-year-old woman showing a sharp margin, a hypoechoic cortex, a wide hilum, concentric cortical thickening, and an S/L ratio of 0.38.

of the patients from undergoing unnecessary excision biopsy. Also, in this study, 6 patients who underwent sonographically guided core biopsy had definitive diagnoses. Therefore, sonographically guided core needle biopsy may be efficient for diagnosing Kikuchi disease in the axilla and could be used as an alternative to excisional biopsy.

Figure 2. Gray scale sonogram of an axillary lymph node classified as benign in a 42-year-old woman showing an unsharp margin, a hypoechoic cortex, a wide hilum, eccentric cortical thickening, and an S/L ratio of 0.18.



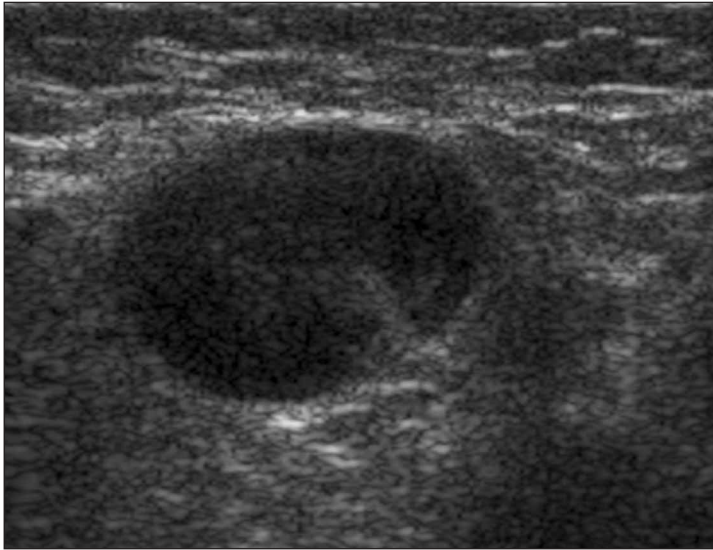
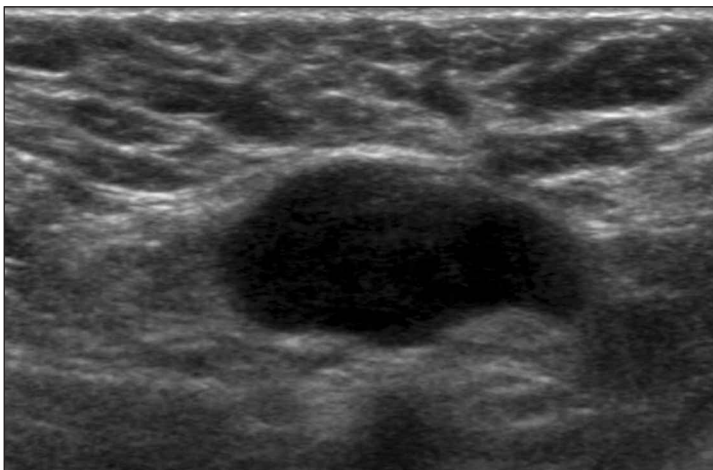


Figure 3. Gray scale sonogram of an axillary lymph node classified as malignant in a 38-year-old man showing a sharp margin, a hypoechoic cortex, a narrow hilum, concentric cortical thickening, and an S/L ratio of 0.73.

Our study had some limitations. First, this retrospective analysis was limited by the small sample size. A larger study would be helpful to characterize the sonographic findings of this disease. Second, there could have been a selection bias because only cases that had undergone sonographic evaluation and biopsy were included; patients who did not undergo biopsy were not included. Most cases with biopsy tend to have imaging findings suspicious for malignancy;

Figure 4. Gray scale sonogram of an axillary lymph node assessed as malignant in a 30-year-old woman showing a sharp margin, a hypoechoic cortex, absence of an echogenic fatty hilum, and an S/L ratio of 0.5.



therefore, more malignant-favoring cases could have been included in this study. Third, not all lymph nodes underwent biopsy, and even among those that did, all but 1 had a diagnosis by core biopsy and not excisional biopsy.

Kikuchi disease in the axilla can be challenging to diagnose, and the differential diagnoses are quite broad. Moreover, the sonographic findings of Kikuchi disease in the axilla were nonspecific and could not be differentiated sonographically from those of malignant lymphadenopathy. When lymph nodes in the axilla show suspicious findings sonographically, Kikuchi disease can be considered one of several possible differential diagnoses, and pathologic examination should be done. To avoid an incorrect diagnosis and prevent resulting unnecessary interventions and subsequent patient morbidity and mortality, it is important to be aware of the characteristic clinical and morphologic findings.

References

1. Kikuchi M. Lymphadenitis showing focal reticulum cell hyperplasia with nuclear debris and phagocytosis. *Nippon Ketsueki Gakkai Zasshi* 1972; 35:379–380.
2. Fujimoto Y, Kozima Y, Yamaguchi K. Cervical subacute necrotizing lymphadenitis: a new clinicopathologic entity. *Naika* 1972; 20:920–927.
3. Onciu M, Medeiros LJ. Kikuchi-Fujimoto lymphadenitis. *Adv Anat Pathol* 2003; 10:204–211.
4. Lin HC, Su CY, Huang CC, Hwang CF, Chien CY. Kikuchi's disease: a review and analysis of 61 cases. *Otolaryngol Head Neck Surg* 2003; 128:650–653.
5. Poulouse V, Chiam P, Poh WT. Kikuchi's disease: a Singapore case series. *Singapore Med J* 2005; 46:229–232.
6. Bennie MJ, Bowles KM, Rankin SC. Necrotizing cervical lymphadenopathy caused by Kikuchi-Fujimoto disease. *Br J Radiol* 2003; 76:656–658.
7. Kwon SY, Kim TK, Kim YS, Lee KY, Lee NJ, Seol HY. CT findings in Kikuchi disease: analysis of 96 cases. *AJNR Am J Neuroradiol* 2004; 25:1099–1102.
8. Fulcher AS. Cervical lymphadenopathy due to Kikuchi disease: US and CT appearance. *J Comput Assist Tomogr* 1993; 17:131–133.
9. Miller WT Jr, Perez-Jaffe LA. Cross-sectional imaging of Kikuchi disease. *J Comput Assist Tomogr* 1999; 23:548–551.
10. Kim TA, Lupetin AR, Graham C. CT appearance of Kikuchi-Fujimoto disease. *Clin Imaging* 1995; 19:1–3.
11. Na DG, Chung TS, Byun HS, Kim HD, Ko YH, Yoon JH. Kikuchi disease: CT and MR findings. *AJNR Am J Neuroradiol* 1997; 18:1729–1732.

12. Ying M, Ahuja AT, Yuen HY. Grey-scale and power Doppler sonography of unusual cervical lymphadenopathy. *Ultrasound Med Biol* 2004; 30:449–454.
13. Ogawa M, Ueda S, Ohto M, Fujita M, Kubosawa T. Ultrasonography of cervical lymphadenopathy in a patient with Kikuchi's disease. *Acta Radiol* 1991; 32:260–261.
14. Kovacs S, Friedman PD, Kuehn A. Unilateral axillary adenopathy caused by Kikuchi-Fujimoto disease. *Breast J* 2006; 12:77–79.
15. Ziegler T, Robiller F, Schau A, Winkler C. Unidirectional axillary lymph node swelling in a 31-year-old woman [in German]. *Med Klin (Munich)* 2002; 97:624–627.
16. Madle-Samardzija N, Turkulov V, Vukadinov J, Stajnic S, Canak G. Histiocytic necrotizing lymphadenitis (Kikuchi-Fujimoto disease) [in Croatian]. *Med Pregl* 2000; 53:513–516.
17. Heldenberg D, Amar M, Ben-Arie Y, Luchtman M. Axillary involvement in pediatric Kikuchi's disease. *Eur J Pediatr Surg* 1996; 6:32–34.
18. Aqel NM, Peters EE. Kikuchi's disease in axillary lymph nodes draining breast carcinoma. *Histopathology* 2000; 36:280–281.
19. Berg JW. The significance of axillary node levels in the study of breast carcinoma. *Cancer* 1955; 8:776–778.
20. Tohnosu N, Onoda S, Isono K. Ultrasonographic evaluation of cervical lymph node metastases in esophageal cancer with special reference to the relationship between the short to long axis ratio (S/L) and the cancer content. *J Clin Ultrasound* 1989; 17:101–106.
21. Vassallo P, Wernecke K, Roos N, Peters PE. Differentiation of benign from malignant superficial lymphadenopathy: the role of high-resolution US. *Radiology* 1992; 183:215–220.
22. Shetty MK, Carpenter WS. Sonographic evaluation of isolated abnormal axillary lymph nodes identified on mammograms. *J Ultrasound Med* 2004; 23:63–71.
23. Esen G. Ultrasound of superficial lymph nodes. *Eur J Radiol* 2006; 58:345–359.
24. Tateishi T, Machi J, Feleppa EJ, et al. In vitro B-mode ultrasonographic criteria for diagnosing axillary lymph node metastasis of breast cancer. *J Ultrasound Med* 1999; 18:349–356.
25. Lernevall A. Imaging of axillary lymph nodes. *Acta Oncol* 2000; 39:277–281.
26. Abdsaleh S, Azavedo E, Lindgren PG. Ultrasound-guided large needle core biopsy of the axilla. *Acta Radiol* 2004; 45:193–196.
27. Patel T, Given-Wilson RM, Thomas V. The clinical importance of axillary lymphadenopathy detected on screening mammography: revisited. *Clin Radiol* 2005; 60:64–71.
28. Ikeda DB. Clinical breast problems and unusual breast conditions. In: *Breast Imaging: The Requisites*. 1st ed. Philadelphia, PA: Elsevier Mosby; 2004; 303–305.
29. Dorfman RF, Berry GJ. Kikuchi's histiocytic necrotizing lymphadenitis: an analysis of 108 cases with emphasis on differential diagnosis. *Semin Diagn Pathol* 1988; 5:329–345.
30. Kim BM, Kim EK, Kim MJ, Yang WI, Park CS, Park SI. Sonographically guided core needle biopsy of cervical lymphadenopathy in patients without known malignancy. *J Ultrasound Med* 2007; 26:585–591.