



Considerations and Protocols in Virtual Surgical Planning of Reconstructive Surgery for More Accurate and Esthetic Neomandible with Deep Circumflex Iliac Artery Free Flap

Nam-Kyoo Kim¹, Hyun Young Kim¹, Hyung Jun Kim^{1,2}, In-Ho Cha^{1,2}, Woong Nam^{1,2}

¹Department of Oral and Maxillofacial Surgery, ²Oral Cancer Research Institute, College of Dentistry, Yonsei University

Abstract

Purpose: The reconstruction of mandibular defects poses many difficulties due to the unique, complex shape of the mandible and the temporomandibular joints. With development of microvascular anastomosis, free tissue transplantation techniques, such as deep circumflex iliac artery (DCIA) flap and fibular free flap (FFF), were developed. The DCIA offers good quality and quantity of bone tissue for mandibular segmental defect and implant for dental rehabilitation. Virtual surgical planning (VSP) and stereolithography-guided osteotomy are currently successfully applied in three-dimensional mandibular reconstruction, but most use FFF. There are only a few articles on reconstruction with the DCIA that assess the postoperative results.

Methods: Three patients admitted during a five month period (April of 2013 to August of 2013) underwent resection of mandible and DCIA musculo-osseous reconstruction using a VSP and stereolithographic modeling and assessment of outcomes included technical accuracy, esthetic contour, and functional outcomes.

Results: This technique yielded iliac bone segment with excellent apposition and duplication of the preoperative plan. Flap survival was 100 percent and all patients maintained preoperative occlusion and contour.

Conclusion: Based on our experience, we offer considerations and logically consistent protocols by classification of mandibular defects, and demonstrate the benefits in VSP and stereolithographic modeling of mandibular reconstructive surgery with DCIA flap.

Key words: Mandibular reconstruction, Deep circumflex iliac artery flap, Virtual surgical planning, Stereolithographic models, Cutting guides

Introduction

Unlike common long bones, mandible reconstruction presents many difficulties due to its unique shape and relation with dental occlusion and the temporomandibular joint

(TMJ). Historically, many methods were suggested for mandibular reconstruction. In the early days, reconstruction plate or non-vascularized autogenous bone graft were used, but were prone to infection and radiation exposure, often resulting in exposure of metal plate and resorption

RECEIVED April 15, 2014, ACCEPTED July 24, 2014

Correspondence to Woong Nam

Department of Oral and Maxillofacial Surgery, Oral Cancer Research Institute, College of Dentistry, Yonsei University
50 Yonsei-ro, Seodaemun-gu, Seoul 120-752, Korea
Tel: 82-2-2228-2971, Fax: 82-2-2227-8022, E-mail: omsnam@yuhs.ac

Copyright © 2014 by The Korean Association of Maxillofacial Plastic and Reconstructive Surgeons. All rights reserved.

© This is an open access article distributed under the terms of the Creative Commons Attribution Non-Commercial License (<http://creativecommons.org/licenses/by-nc/3.0>) which permits unrestricted non-commercial use, distribution, and reproduction in any medium, provided the original work is properly cited.

of grafted bone[1-3]. Later, a pedicled osteomyocutaneous flap was used with improved results. However, there were still difficulties in handling soft tissue and lack of blood supply to grafted bone[4]. With the development of microvascular surgery, free tissue transplantation (i.e., deep circumflex iliac artery [DCIA], fibular free flap [FFF]) transferred sufficient bone and soft tissue with localized blood flow, with greater success in patients previously treated with surgery or radiation[5]. DCIA flap offers large volume and quality of bone tissue for mandibular segmental defects, excellent esthetic shape for reestablishing mandibular continuity, and sufficient height for implant placement[6]. DCIA could be the first choice for reconstruction of segmental mandibular defects of intermediate length; however, both mandibular resection and iliac crest osteotomy are dependent on the surgeon's experience, intraoperative judgment and technical speed. Achieving satisfactory results for contouring the grafted bone and recovering the occlusion and TMJ function has challenged the use of free tissue transfer. To overcome these problems, three-dimensional (3D) computed tomography (CT) and computer image processing software are being used for virtual surgical planning (VSP) with resection of lesion and reconstruction of defects, in conjunction with stereolithographic fabrication of surgical guides[7-10]. This results in easier, faster, more accurate and esthetic outcomes. The majority of computer simulations are used to help restore the neomandible in mandibular reconstruction with FFF. However, the technique is seldom applied in mandibular reconstruction with vascularized iliac crest flap. The literature is sparse on application of surgery planning and stereomodeling with a DCIA flap, and assessing the postoperative results. Thus, a consistent protocol that approaches the challenging limitations encountered by either by young or experienced surgeons has not been established. Herein, the authors suggest a practical protocol for mandible reconstruction based on literature review and our experi-

ences in acquiring satisfactory results using VSP and stereolithographic surgical guides. We achieved satisfactory results with DCIA flap with virtual surgery planning and stereolithographic surgical guides.

Materials and Methods

1. Patients

Three patients underwent resection of mandible and accurate mandibular reconstruction with DCIA flap using computer simulation and stereomodeling between April 2013 to August 2013 at a single institution. These patients were three men with an average age of 50 years (range 39~56 years). Follow-up ranged from one to five months. The patient characteristics are listed in Table 1. All patients underwent immediate reconstruction after ablative surgery. Aesthetic contour, functional outcomes were assessed by dental occlusion, postoperative imaging, and clinical examination.

2. Virtual surgical planning

Planning commenced with preoperative high-resolution CT scans from both maxillofacial and pelvic area. The data was stored as digital imaging communication in medicine format and imported to an image processing software (Mimics software; Materialise, Leuven, Belgium) for segmentation of CT images and 3D visualization and planning of lesion safe resection margins, segmental mandibulectomy and design of the reconstructed mandible (neomandible) within the iliac bone (Fig. 1). Separately, the DCIA were 3-dimensionally reconstructed, analyzed with MeVisLab (MeVis Research, Bremen, Germany) and used as surgical reference (Fig. 2).

3. Stereolithographic modeling

Computer-aided design was used to plan the mandibular

Table 1. Patients undergoing DCIA flap reconstruction using VSP and stereolithographic guide

Patient No.	Age (yr)	Diagnosis	Resection site	Donor site	Location of pedicle	Follow-up (mo)
1	56	Ameloblastoma	Symphysis, body (LC ^a)	Contralateral	Posterior	5
2	39	Ameloblastoma	Body, ramus (L ^a)	Contralateral	Anterior	3
3	55	Ameloblastoma	Body, ramus (L ^a)	Contralateral	Anterior	1

DCIA, deep circumflex iliac artery; VSP, virtual surgical planning. ^aJewer's 'L', 'C', 'LC' classification with immediate reconstruction.

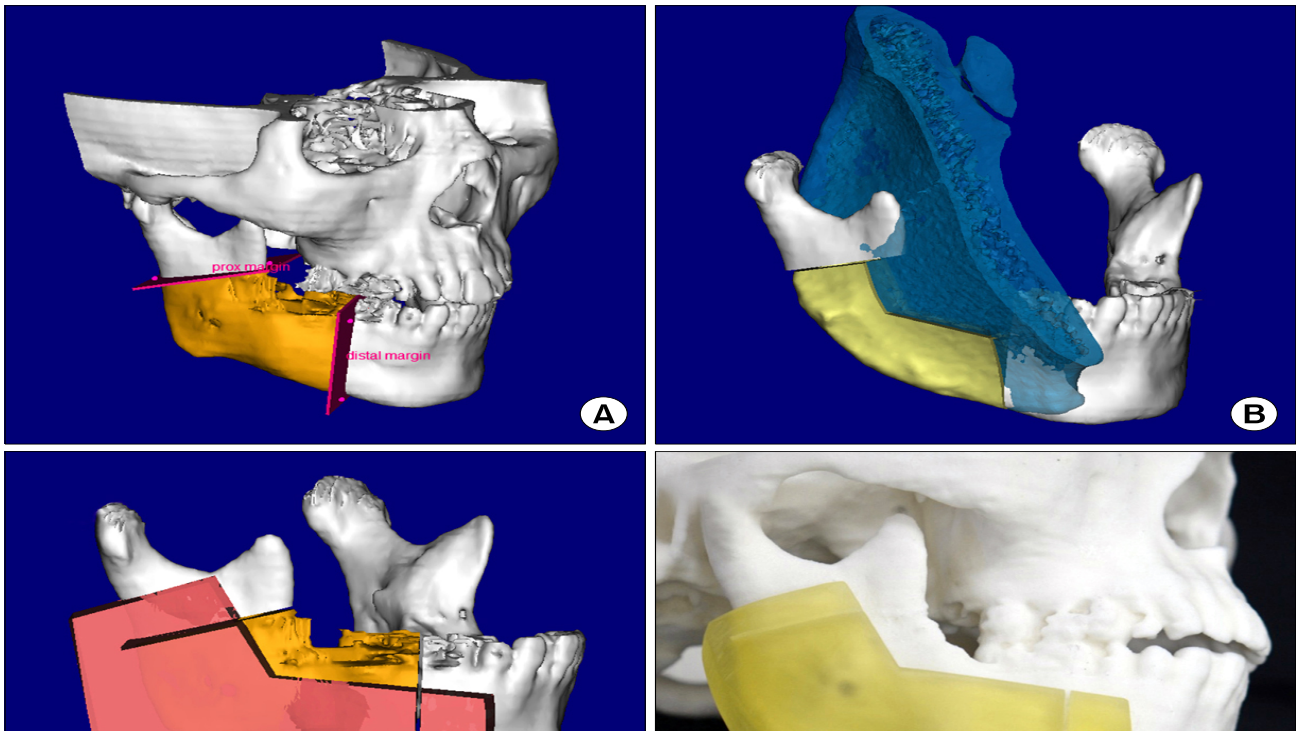


Fig. 1. Virtual surgical planning and stereolithography surgical guide. (A) Preoperative 3-dimensional reconstruction computed tomography and establishment of resection plane for segmental mandibulectomy. (B) Contralateral iliac crest excluding the anterior superior iliac spine (ASIS) is automatically chosen and osteotomized for segmental defect. (C) Planned resection margin with mandibular resection guide containing angle region for segmental mandibulectomy. (D) Stereolithographic model of mandibular resection guide and preoperative patient's skull. (E) Planned cutting margin with iliac crest cutting guide containing ASIS area. (F) Stereolithographic model of mandibular resection guide and iliac crest cutting guide.

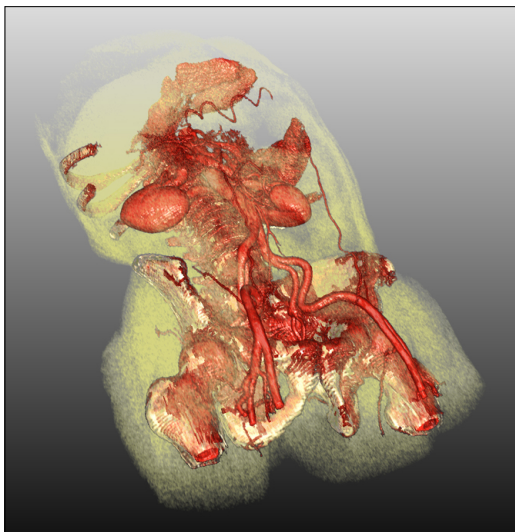


Fig. 2. Using MeVisLab program 3-dimensional reconstructed images were used to analyze the course and thickness of the deep circumflex iliac artery for selection of the vascular pedicle to be used.

resection and iliac bone cutting guides with the negative form of the mandibular inferior border (including the angle area) and the lateral aspect of the iliac crest (including the anterior superior iliac spine, ASIS) without considering fixation with screws. The resulting data was saved in STL format for stereolithographic fabrication of the cutting guides and neomandible (Fig. 1C~1F), which was used to preoperatively bend the reconstruction plate (Fig. 3A) and assist the double plating technique for preservation of both occlusion and condyle position during surgery.

4. Surgical technique

Surgery proceeded in a two-team approach. After adequate mandibular exposure, the reconstruction plate was temporarily positioned in the native mandible to maintain the occlusion and condyles in position. As the mandibular resection guide was secured in place, osteotomies were performed following the cutting slots, replicating the virtually planned mandibular resection. The iliac crest was dissected through a lateral approach and a DCIA flap was

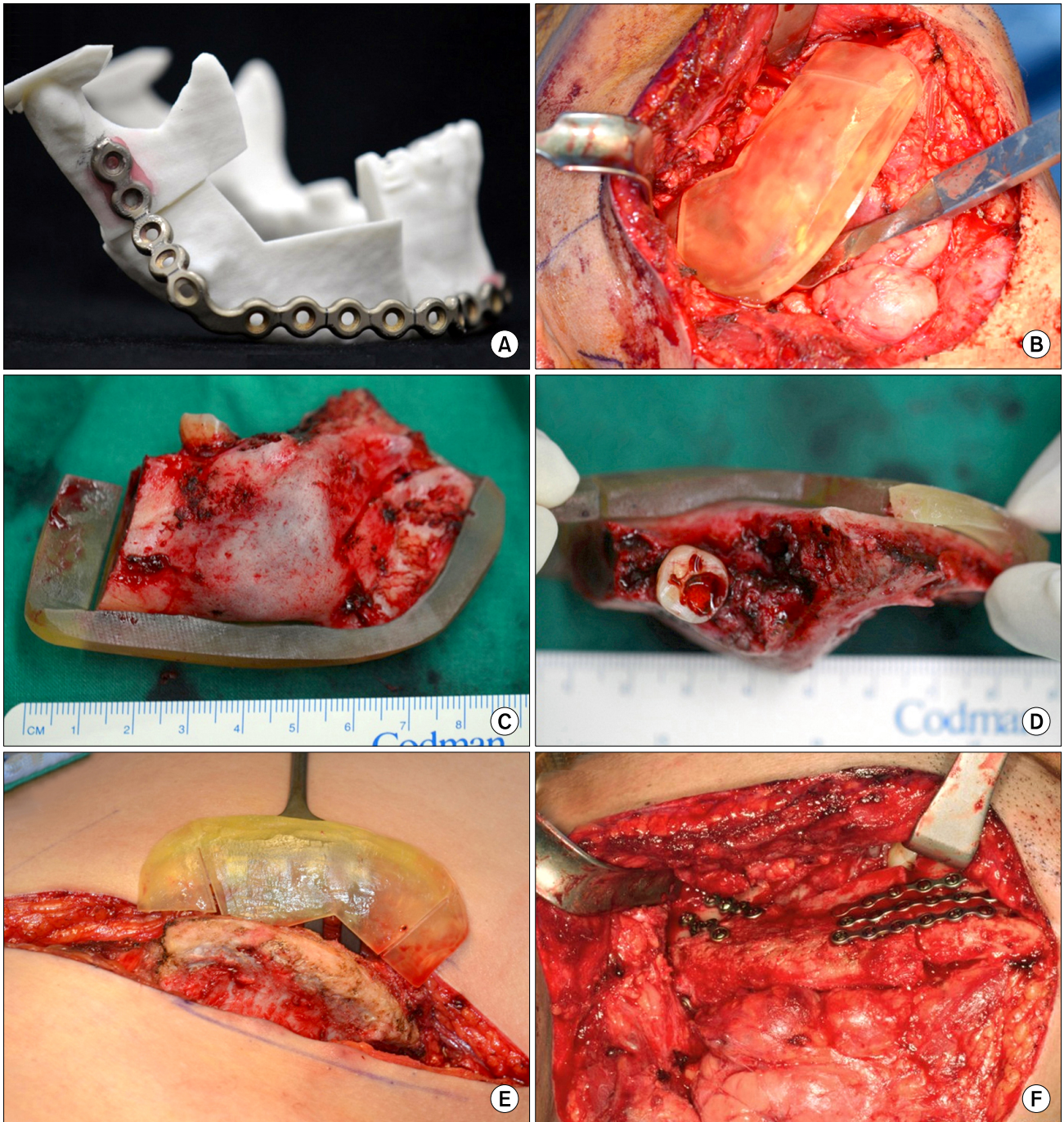


Fig. 3. (A) Prebending of the reconstruction plate on the neomandibular model assisted the double plating technique in preservation of both preoperative occlusion and condyle position. (B) Adaptation mandibular resection guide for segmental mandibulectomy. (C, D) Main mass and resection guide after segmental mandibulectomy. (E) Iliac cutting guide designed from anterior superior iliac spine (ASIS) to iliac crest for flap harvesting. Note the guides designed to contain the curved area such as mandibular angle and ASIS area for aiding reproducible adaptation and stable location. (F) Intraoperative view after mandibular reconstruction with deep circumflex iliac artery flap was completed. The iliac crest bone graft fitted perfectly into the mandibular defect. Plane-to-plane approximation of the grafted bone was acquired with minimal adjustments.

successfully harvested after securing the cutting guide to the lateral aspect of the iliac crest (Fig. 3). The iliac bone segment was fixed into the mandible defect while the neo-

mandible shape and contour was confirmed. After microvascular anastomosis all surgical sites were closed in a standard fashion (Fig. 3F).

Results

Using mandibular resection and iliac cutting guides, the need for intraoperative measurement was eliminated, al-

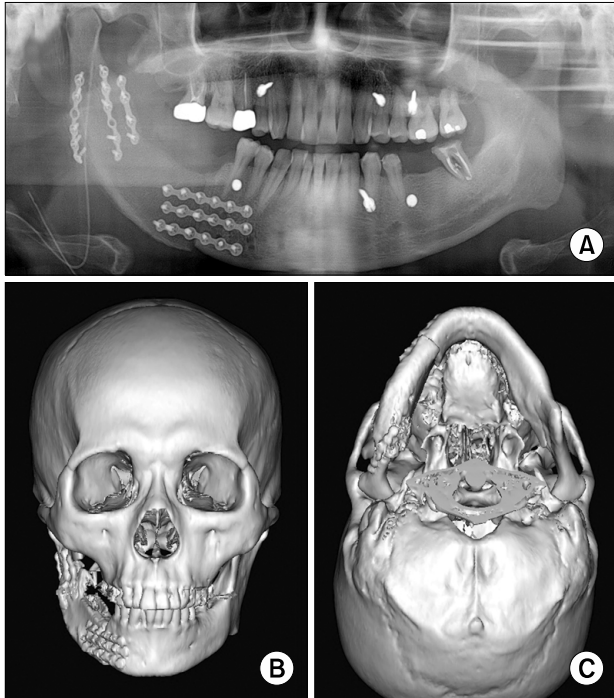


Fig. 4. Postoperative 3-dimensional computed tomography reconstructed images and orthopantograph showing accurate replication of virtually surgical planned mandibular reconstruction with deep circumflex iliac artery flap. Note the restoration of the mandibular continuity and esthetic contour acquired after surgical application of virtual surgical planning.

lowing exact duplication and positioning of the neomandible with minimal adjustments. Flap survival in all patients was 100%. There was no wound infection or dehiscence. Preoperative occlusion and TMJ function were preserved after surgery with good progress. Postoperative 3D computed tomographic scans and orthopantography demonstrate faithful replication of preoperative VSP (Fig. 4). No patients had difficulty in deglutition and speech after surgery and all three are under continuing observation.

Discussion

Osteotomy of DCIA flap, introduced by Taylor and Watson[11] in 1978, requires a long operative time to obtain the desired curvature of neomandible and increases the risk of injury to the vascular pedicle, especially for surgeons without much experience. Mandibular reconstruction using virtual surgery planning and stereolithographic surgical guides is a recent introduction, especially in fibula free flaps[7-9,12], but, there are few reports with DCIA flap. However, current literature still relies on the surgeon's experience to prevent errors. For example, although a virtual surgery planning is successfully implemented and a pre-bent reconstruction plate is prepared for the neomandible, to make the 3D shape of the neomandible using fibular or iliac bone flap is dependent on the surgeon's experience[12,13] or the mirror image of the opposite side

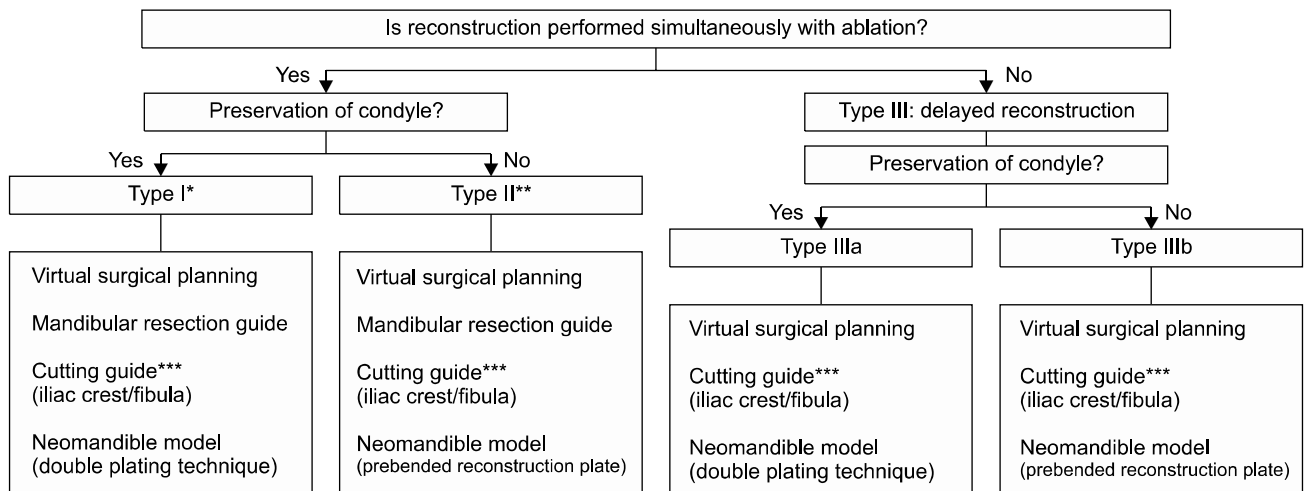


Fig. 5. Proposed protocol categorizing four types of theoretically accurate 'virtual surgical planning and stereolithography-guided osteotomy for 3-dimensional mandibular reconstruction' according to the reconstruction approach (immediate or delayed) and condyle preservation described by Jewer *et al.*[17]. *Jewer's 'L', 'C', 'LC' classification with immediate reconstruction. **Jewer's 'H', 'HL', 'HLC' classification with immediate reconstruction. ***Cutting guide for iliac crest should contain anterior superior iliac spine area; cutting guide for fibula should be fixed to fibula bone by screw.

of the mandible[14] without surgical guides, not considering individual characteristics. Otherwise the reconstruction plate is pre-bent following the native mandible, rather than the neomandible, so it is difficult to achieve close contact between the reconstruction plate and bone flap. If the screws are tightened for fixation, segments are moving outside and away from each other[15].

Considering these problems, necessary components of success in exact mandibular reconstruction with minimal errors include accurate VSP, a mandibular resection guide, a donor site cutting guide, and precise fixation of the pre-bent reconstruction plate to neomandible[8,16].

Repeated simulation of the VSP helped to plan optimal osteotomy planes, and to decide which side of the iliac is used and location of vascular pedicle. The mandibular resection guide yields a reproducible adaptation and stable location without fixation by including the anterior and posterior resection plane and a curved part such as angle or symphysis area. The iliac cutting guide is also improved for adaptation and location by including the ASIS area. Without screw fixation, we can achieve exact location of guides without compromising the blood supply of the donor bone marrow. In addition, stereolithographic model of neomandible and pre-bending of the reconstruction plate is done to preserve positions of resected mandible and bone flap during fixation. The advantages of this procedure are as follows. First, optimal selection of resection plane considering important anatomical structures and the safety margin of the lesion are possible by using virtual simulation surgery of the same size as the patient. Second, preoperative contouring of the reconstruction plate to the planned neomandible model could shorten the operation time and flap ischemia time, improving the flap success rate. Third, achieving plane-to-plane bone contact could be beneficial to bony union, and the functions of TMJs and the occlusion can be preserved. Finally, using this technique helps with explanation to patients of problems and challenges of reconstruction.

Herein, the authors proposed a protocol for mandible reconstruction based on a case-virtual-surgical-plan classification suggested after satisfactory results acquired with DCIA flap using VSP and stereolithographic surgical guides (Fig. 5). The protocol consisted in case categorization into four types of VSP, according to the reconstruction approach

(immediate or delayed) and condyle preservation described by Jewer *et al.*[17]. The detailed procedures are chosen by the reconstruction methods such as FFF, DCIA flap. In type I cases, preserving condyle (Jewer classification 'L' or 'LC') and immediate reconstruction, VSP, mandibular resection guide, fibular or iliac cutting guide, and fixation using miniplate by double plating technique with a pre-bent reconstruction plate on the neomandibular model are needed. In type II cases, not preserving condyle (Jewer classification 'H') and immediate reconstruction, VSP, mandibular resection guide, fibular cutting guide, and fixation using a pre-bent reconstruction plate on the neomandibular model are needed. In type III, delayed reconstruction, the condyle is preserved, and the same procedure as other types is performed except for the mandibular resection guide. If the occlusion is to be restored, virtual surgery planning with additional laser cast scan as being applied in orthognathic surgery is used[18].

Conclusion

Mandibular reconstruction with DCIA flap by VSP and stereolithographic-guided osteotomy offers an easier, faster and more accurate way to obtain excellent functional and aesthetic results. High costs and the difficulty of prompt change of resection margins during malignant tumor surgery are shortcomings. The development of intraoperative model manufacturing for changes of resection plane and the more advanced physical properties of the surgical guides are necessary for better results after surgery.

Acknowledgements

A faculty research grant of Yonsei University College of Dentistry for 6-2012-0127 supported this study.

References

1. Tidstrom KD, Keller EE. Reconstruction of mandibular discontinuity with autogenous iliac bone graft: report of 34 consecutive patients. *J Oral Maxillofac Surg* 1990;48:336-46.
2. Onoda S, Kimata Y, Yamada K, *et al.* Prevention points for plate exposure in the mandibular reconstruction. *J Craniomaxillofac Surg* 2012;40:e310-4.
3. Wei FC, Celik N, Yang WG, Chen IH, Chang YM, Chen HC. Complications after reconstruction by plate and soft-tis-

- sue free flap in composite mandibular defects and secondary salvage reconstruction with osteocutaneous flap. *Plast Reconstr Surg* 2003;112:37-42.
4. Conley J. Use of composite flaps containing bone for major repairs in the head and neck. *Plast Reconstr Surg* 1972;49:522-6.
 5. Bak M, Jacobson AS, Buchbinder D, Urken ML. Contemporary reconstruction of the mandible. *Oral Oncol* 2010;46:71-6.
 6. Frodel JL Jr, Funk GF, Capper DT, *et al*. Osseointegrated implants: a comparative study of bone thickness in four vascularized bone flaps. *Plast Reconstr Surg* 1993;92:449-55.
 7. Hirsch DL, Garfein ES, Christensen AM, Weimer KA, Saddeh PB, Levine JP. Use of computer-aided design and computer-aided manufacturing to produce orthognathically ideal surgical outcomes: a paradigm shift in head and neck reconstruction. *J Oral Maxillofac Surg* 2009;67:2115-22.
 8. Antony AK, Chen WF, Kolokythas A, Weimer KA, Cohen MN. Use of virtual surgery and stereolithography-guided osteotomy for mandibular reconstruction with the free fibula. *Plast Reconstr Surg* 2011;128:1080-4.
 9. Leiggenger C, Messo E, Thor A, Zeilhofer HF, Hirsch JM. A selective laser sintering guide for transferring a virtual plan to real time surgery in composite mandibular reconstruction with free fibula osseous flaps. *Int J Oral Maxillofac Surg* 2009;38:187-92.
 10. Juergens P, Krol Z, Zeilhofer HF, *et al*. Computer simulation and rapid prototyping for the reconstruction of the mandible. *J Oral Maxillofac Surg* 2009;67:2167-70.
 11. Taylor GI, Watson N. One-stage repair of compound leg defects with free, revascularized flaps of groin skin and iliac bone. *Plast Reconstr Surg* 1978;61:494-506.
 12. Wang TH, Tseng CS, Hsieh CY, *et al*. Using computer-aided design paper model for mandibular reconstruction: a preliminary report. *J Oral Maxillofac Surg* 2009;67:2534-40.
 13. Zheng GS, Su YX, Liao GQ, *et al*. Mandible reconstruction assisted by preoperative virtual surgical simulation. *Oral Surg Oral Med Oral Pathol Oral Radiol* 2012;113:604-11.
 14. Hou JS, Chen M, Pan CB, *et al*. Application of CAD/CAM-assisted technique with surgical treatment in reconstruction of the mandible. *J Craniomaxillofac Surg* 2012;40:e432-7.
 15. Ciocca L, Mazzoni S, Fantini M, Persiani F, Marchetti C, Scotti R. CAD/CAM guided secondary mandibular reconstruction of a discontinuity defect after ablative cancer surgery. *J Craniomaxillofac Surg* 2012;40:e511-5.
 16. Zheng GS, Su YX, Liao GQ, *et al*. Mandible reconstruction assisted by preoperative simulation and transferring templates: cadaveric study of accuracy. *J Oral Maxillofac Surg* 2012;70:1480-5.
 17. Jewer DD, Boyd JB, Manktelow RT, *et al*. Orofacial and mandibular reconstruction with the iliac crest free flap: a review of 60 cases and a new method of classification. *Plast Reconstr Surg* 1989;84:391-403.
 18. Nkenke E, Zachow S, Benz M, *et al*. Fusion of computed tomography data and optical 3D images of the dentition for streak artefact correction in the simulation of orthognathic surgery. *Dentomaxillofac Radiol* 2004;33:226-32.