

Arthroscopic Partial Repair of Massive Contracted Rotator Cuff Tears

Sung-Jae Kim, Young-Hwan Kim, Yong-Min Chun

Department of Orthopaedic Surgery, Arthroscopy and Joint Research Institute, Severance Hospital, Yonsei University College of Medicine, Seoul, Korea

Typically, massive rotator cuff tears have stiff and retracted tendon with poor muscle quality, in such cases orthopaedic surgeons are confronted with big challenging to restore the cuff to its native footprint. Furthermore, even with some restoration of the footprint, it is related with a high re-tear rate due to less tension free repair and less tendon coverage. In this tough circumstance, the partial repair has yielded satisfactory outcomes at relatively short follow-up by re-creating the transverse force couple of the rotator cuff. Through this partial repair, the massive rotator cuff tear can be converted to the “functional rotator cuff tear” and provide improvement in pain and functional outcomes in patient’s shoulder.

(Clin Shoulder Elb 2014;17(1):44-47)

Key Words: Shoulder; Massive rotator cuff tear; Partial repair; Arthroscopy

Introduction

Despite advances in arthroscopic techniques and devices, symptomatic massive contracted rotator cuff tear is still a challenging to most shoulder surgeons. This rotator cuff tissue has all of the following characteristics; inelastic and friable tendon quality, adhesion and scarring to severely retracted tendon, muscle atrophy and fatty infiltration. All these factors preclude optimal repair without tension. In addition to aforementioned challenges, inferior biologic milieu and hypovascularity of the tendon impair the healing between tendon and bone.¹⁾ So among the options for addressing the symptomatic massive rotator cuff tears, we will introduce a partial repair as one of appropriate treatment strategies. The purpose of this review is to summarize and update the current status of arthroscopic partial repair in massive tears.

Definition of Massive Rotator Cuff Tear and Status of Cuff Tendon-muscles

The definition of the massive rotator cuff tear was first defined by Cofield²⁾ as a tear > 5 cm in diameter, which was based on

the tear size. Gerber et al.³⁾ proposed more recently the definition of the massive rotator cuff tear by the number of tendon involved, i.e., a tear involving two or more. Although not all massive rotator cuff tear are irreparable, most of massive rotator cuff tear have degenerated and poor muscle belly as well as large and retracted torn tendon with some tendon loss.

With regard to muscle status in rotator cuff tears, Goutallier et al.⁴⁾ classified it by the amount of fatty infiltration in the rotator cuff muscle belly, which was identified in computed tomography (CT). Later, Goutallier’s classification was also validated with magnetic resonance image (MRI),⁵⁾ and currently, MRI is more widely used than CT for evaluating the muscle quality in rotator cuff tears. Even though there are still no general consensus which Goutallier stage is deemed to be irreparable, stage 3 or 4 is believed to be irreversible changes, and it is very difficult to obtain good mobilization and complete repair.⁶⁾

Balancing the Essential Force Couples and Converting to Functional Rotator Cuff Tear

Although, the failure rate was reported up to over 90% in this circumstance,^{7,8)} the concept of “functional rotator cuff tear” was

Received March 13, 2014. **Revised** March 21, 2014. **Accepted** March 22, 2014.

Correspondence to: Yong-Min Chun

Department of Orthopaedic Surgery, Arthroscopy and Joint Research Institute, Severance Hospital, Yonsei University College of Medicine, 50-1 Yonsei-ro, Seodaemun-gu, Seoul 120-752, Korea

Tel: +82-2-2228-5679, **Fax:** +82-2-363-6248, **E-mail:** min1201@hanmail.net

Financial support: None. **Conflict of interests:** None.

introduced by Burkhart.^{9,10} Even though the partial repair and margin convergence of the torn rotator cuff tear cannot cover the humeral head completely, the transverse force couple of the rotator cuff can be restored and play an important role as a stable fulcrum for the glenohumeral joint. Among the rotator cuff tendons surrounding the humeral head, the anterior and posterior portion of rotator cuff alone can provide a concavity compression force, even though the superior portion of rotator cuff was not functional or had a defect. Thus, on the transverse plane, the balancing and coupling force across the glenoid can be obtained. Through fluoroscopic evaluation in patients with massive rotator cuff tear, Burkhart reported that even in massive rotator cuff tear, the sufficient shoulder function is possible if the balance exists between two essential force couples: transverse couple between subscapularis and infraspinatus and teres minor, and coronal plane between rotator cuff and deltoid.⁹ Recently, Oh et al.¹¹ explained this concept more concretely through biomechanical experiment. They simulated a massive rotator cuff tear using cadaveric shoulders, and sought to find the effect of partial repair in case that the complete repair was not feasible. They concluded that posterior fixation (partial repair of the infraspinatus) was imperative to restore the abnormal shoulder kinematics, and anterior margin convergence would be helpful to decrease a residual defect of repaired tendon and to achieve better environment for healing. Another concept "suspension bridge system" was also proposed by Burkhart¹⁰ in the rotator cuff tear, emphasizing the role of the rotator cable. Through the margin convergence or side to side sutures in addressing the massive rotator cuff tears, this concept can be applicable; distributing the tension on the repaired tendon to the anterior and posterior tear leaves.^{10,12} Rather than complete repair under substantial tension, it is of importance that the stable fulcrum of the glenohumeral joint should be re-established.^{1,13-16} Thus, even though the cuff tear is not repaired completely nor humeral head is not covered completely, we can expect that the massive rotator cuff tears convert to the "functional rotator cuff tears" can have good shoulder function. Gerber et al.¹⁷ performed an interesting study to evaluate the role of the supraspinatus in abduction and external rotation of the shoulder through the suprascapular nerve block. Their experiment showed that even with complete supraspinatus paralysis, 75% of the abduction strength and 85% to 90% of external rotation strength was preserved.

The conversion of the massive or irreparable rotator cuff tear to a functional rotator cuff tear by means of partial repair has produced satisfactory clinical outcomes by some.^{14,18,19} Burkhart et al.¹⁸ reported satisfactory outcomes in 14 patients after partial repair for massive rotator cuff tears. Despite the average residual defect (2.9 cm²), 93% of patients were satisfied with their result. They suggested that partial repair should be recommended rather than tendon transposition at the expense of normal shoulder biomechanics to cover the defect. Duralde and Bair¹⁹ reported

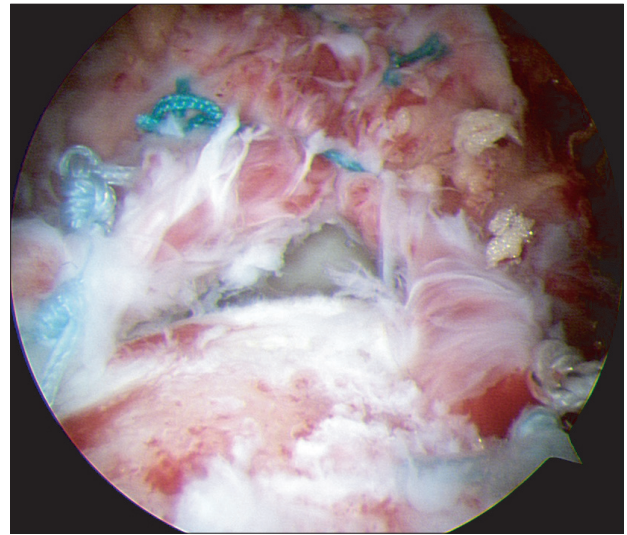


Fig. 1. Arthroscopic partial repair with residual defect.

their 24 patients who underwent open partial repair for massive rotator cuff tears. Despite the remaining defect ranging from 5 mm to 3 cm (mean, 1.7 cm), 67% of patients showed good to excellent result, and satisfactory pain relief was achieved in 83% of the patients. The range of motion was also significantly improved after surgery.

Kim et al.¹⁴ also reported satisfactory outcomes after arthroscopic partial repair with margin convergence (Fig. 1) for irreparable large to massive rotator cuff tears. Although there was a residual defect ranging from 5 mm to 32 mm (anterior to posterior width, mean 12 mm) at the time of surgery, and the mean acromiohumeral distance was decreased from 6.5 mm to 5.9 mm at the final follow-up, all shoulder scores improved significantly. Although the strength of the active forward flexion or abduction of the affected side significantly improved after surgery, it was not restored to the same level as the contralateral side. Recently, Wellmann et al.²⁰ documented favorable outcomes after arthroscopic partial repair of large retracted rotator cuff tears. The overall shoulder scores including active range of motion (ROM) for forward flexion and abduction significantly improved. However, the active ROM for external rotation was decreased slightly, and the abduction strength did not improve significantly after surgery.

In repairing the massive rotator cuff tears, it is not easy to achieve tension free repair, even though the interval slide and release of adhesion around the tendon and capsule are helpful to gain the mobility of the retracted tendon. However, this aggressive release such double interval slides may have an adverse effect on tendon healing. Iagulli et al.²¹ compared the partial and complete arthroscopic repair of massive rotator cuff tears. Both complete repair group (45 patients) and partial repair group (41 patients) yielded significant improvement in shoulder score after surgery, but there was no significant difference be-

tween groups despite an average residual defect area of 5.68 cm² in partial repair group. They concluded that if a complete repair is not feasible due to the poor tissue quality and severe retraction of the torn tendon, a partial repair can yield satisfactory outcome comparable to complete repair in appropriate selected patients. Recently, Kim et al.⁷⁾ compared the functional outcomes and structural integrity after arthroscopic partial versus complete repair of massive contracted rotator cuff tears. In their study, the complete repair was achieved by anterior and posterior interval slide and side to side repair of the interval slide edge (22 patients); the partial repair was achieved by anterior interval slide and margin convergence (19 patients) and the residual defect was about 11 mm at the time of surgery. At two-year follow-up, the functional outcomes were not different significantly between groups. Even though the preoperative tear sizes on magnetic resonance arthrography (MRA) images were not different significantly between groups, follow-up MRA identified a re-tear in 91% in complete repair group and the re-tear size of the complete repair group was significantly greater than that of the partial repair group. They concluded that the complete repair through aggressive release did not have better clinical and structural outcomes, compared with the partial repair without aggressive release for massive contracted rotator cuff tears.

In partial repair status, however, the remaining rotator cuff is placed under overload and may result in early muscle fatigue.²⁰⁾ Hansen et al.²²⁾ revealed in their in vitro study that as the tear size increased, a strong increase of the intact tendon load was identified. Kim et al.¹⁴⁾ also noted that functional shoulder scores showed an inverse correlation with residual defect size despite overall improvement after surgery. Thus further study is necessary to resolve many controversies in this field.

Appropriate Indications and Limitations of Partial Repair in Practice

There are no absolute indications for partial repair in irreparable or massive rotator cuff tear in previous studies.^{7,9,14,18,20)} Interestingly, these studies included only posterosuperior rotator cuff tears and their subscapularis was relatively intact (intact or not requiring repair) or reparable. Thus, based on their favorable outcomes, the integrity of the subscapularis (either before or after) seems to be important to convert to “functional rotator cuff tear” in the posterosuperior rotator cuff tears. Furthermore, if the patient is young and required to work as a manual laborer, the tendon transfer (latissimus dorsi transfer) may be more suitable than partial repair. However, even though the subscapularis tendon is robust, in case that (1) the fatty infiltration is near complete in all three tendons (supraspinatus, infraspinatus, and teres minor); (2) moderate to severe rotator cuff arthropathy; (3) anterosuperior escape of the humeral head; (4) low compliance for postoperative rehabilitation is anticipated, rather than partial

repair, other options such as arthroscopic biceps tenotomy with debridement or arthroplasty should be considered according to the patients’ expectation, age, and health status.

As to the limitations of the partial repair; even though pain, active forward flexion, and overall functional shoulder score improved after surgery, the strength did not restored to the level of complete repair and also the range of motion in external rotation did not improved significantly.^{7,14,20)} Also, there was a trend toward a decrease in the acromiohumeral distance.^{14,20)} Finally, most of the studies had relatively short term follow-up.^{7,14,19-21)} On the other hand, there has been a paucity of literatures regarding the outcomes of partial repair in anterosuperior massive rotator cuff tear. Thus, for the present, it is difficult to predict the result of partial repair of irreparable subscapularis tears.

Conclusion

The partial repair for massive rotator cuff tears is not an almighty solution. Furthermore, our expectation for re-creating the force couple of the rotator cuff and its contribution to re-establishing the stable fulcrum of glenohumeral joint has not yet clearly verified. Nevertheless, many clinical studies showed significant improvement in pain and functional outcomes at least for short term follow-up with partial repair. A long term durability of partial repair needs much more evidence.

References

1. Bedi A, Dines J, Warren RF, Dines DM. Massive tears of the rotator cuff. *J Bone Joint Surg Am.* 2010;92(9):1894-908.
2. Cofield RH. Subscapular muscle transposition for repair of chronic rotator cuff tears. *Surg Gynecol Obstet.* 1982;154(5):667-72.
3. Gerber C, Fuchs B, Hodler J. The results of repair of massive tears of the rotator cuff. *J Bone Joint Surg Am.* 2000;82(4):505-15.
4. Goutallier D, Postel JM, Bernageau J, Lavau L, Voisin MC. Fatty muscle degeneration in cuff ruptures. Pre- and postoperative evaluation by CT scan. *Clin Orthop Relat Res.* 1994;(304):78-83.
5. Fuchs B, Weishaupt D, Zanetti M, Hodler J, Gerber C. Fatty degeneration of the muscles of the rotator cuff: assessment by computed tomography versus magnetic resonance imaging. *J Shoulder Elbow Surg.* 1999;8(6):599-605.
6. Omid R, Lee B. Tendon transfers for irreparable rotator cuff tears. *J Am Acad Orthop Surg.* 2013;21(8):492-501.
7. Kim SJ, Kim SH, Lee SK, Seo JW, Chun YM. Arthroscopic repair of massive contracted rotator cuff tears: aggressive release with anterior and posterior interval slides do not improve cuff healing and integrity. *J Bone Joint Surg Am.* 2013;95(16):1482-8.

8. Galatz LM, Ball CM, Teefey SA, Middleton WD, Yamaguchi K. The outcome and repair integrity of completely arthroscopically repaired large and massive rotator cuff tears. *J Bone Joint Surg Am.* 2004;86-A(2):219-24.
9. Burkhart SS. Arthroscopic treatment of massive rotator cuff tears. Clinical results and biomechanical rationale. *Clin Orthop Relat Res.* 1991;(267):45-56.
10. Burkhart SS. Reconciling the paradox of rotator cuff repair versus debridement: a unified biomechanical rationale for the treatment of rotator cuff tears. *Arthroscopy.* 1994;10(1):4-19.
11. Oh JH, McGarry MH, Jun BJ, et al. Restoration of shoulder biomechanics according to degree of repair completion in a cadaveric model of massive rotator cuff tear: importance of margin convergence and posterior cuff fixation. *Am J Sports Med.* 2012;40(11):2448-53.
12. Burkhart SS, Athanasiou KA, Wirth MA. Margin convergence: a method of reducing strain in massive rotator cuff tears. *Arthroscopy.* 1996;12(3):335-8.
13. Parsons IM, Apreleva M, Fu FH, Woo SL. The effect of rotator cuff tears on reaction forces at the glenohumeral joint. *J Orthop Res.* 2002;20(3):439-46.
14. Kim SJ, Lee IS, Kim SH, Lee WY, Chun YM. Arthroscopic partial repair of irreparable large to massive rotator cuff tears. *Arthroscopy.* 2012;28(6):761-8.
15. Thompson WO, Debski RE, Boardman ND 3rd, et al. A biomechanical analysis of rotator cuff deficiency in a cadaveric model. *Am J Sports Med.* 1996;24(3):286-92.
16. Ahmad CS, Kleweno C, Jacir AM, et al. Biomechanical performance of rotator cuff repairs with humeral rotation: a new rotator cuff repair failure model. *Am J Sports Med.* 2008;36(5):888-92.
17. Gerber C, Blumenthal S, Curt A, Werner CM. Effect of selective experimental suprascapular nerve block on abduction and external rotation strength of the shoulder. *J Shoulder Elbow Surg.* 2007;16(6):815-20.
18. Burkhart SS, Nottage WM, Ogilvie-Harris DJ, Kohn HS, Pachelli A. Partial repair of irreparable rotator cuff tears. *Arthroscopy.* 1994;10(4):363-70.
19. Duralde XA, Bair B. Massive rotator cuff tears: the result of partial rotator cuff repair. *J Shoulder Elbow Surg.* 2005;14(2):121-7.
20. Wellmann M, Lichtenberg S, da Silva G, Magosch P, Habermeyer P. Results of arthroscopic partial repair of large retracted rotator cuff tears. *Arthroscopy.* 2013;29(8):1275-82.
21. Iagulli ND, Field LD, Hobgood ER, Ramsey JR, Savoie FH 3rd. Comparison of partial versus complete arthroscopic repair of massive rotator cuff tears. *Am J Sports Med.* 2012;40(5):1022-6.
22. Hansen ML, Otis JC, Johnson JS, Cordasco FA, Craig EV, Warren RF. Biomechanics of massive rotator cuff tears: implications for treatment. *J Bone Joint Surg Am.* 2008;90(2):316-25.