

## 빠르게 진행되는 신생아 낭성 신경모세포종

염태준<sup>1</sup> · 김명준<sup>1</sup> · 한석주<sup>2</sup>  
이미정<sup>1</sup>

<sup>1</sup>연세대학교 의과대학 세브란스  
어린이병원 영상의학과

방사선외과학 연구소

<sup>2</sup>연세대학교 의과대학 세브란스  
어린이병원 소아외과

**J Korean Soc Ultrasound Med**  
2012;31:263-266

Received June 26, 2012; Revised July  
12, 2012; Accepted September 10, 2012.

### Address for reprints :

Mi-Jung Lee, MD, Department of  
Radiology and Research Institute of  
Radiological Science, Severance  
Children's Hospital, Yonsei University, 50  
Yonsei-ro, Seodaemun-gu, Seoul 120-  
752, Korea.

Tel. 82-2-2228-7400

Fax. 82-2-393-3035

E-mail: mjl1213@yuhs.ac

## Rapidly Evolving Congenital Cystic Neuroblastoma in a Neonate

Tae Jun Yum, MD<sup>1</sup>, Myung-Joon Kim, MD<sup>1</sup>, Seok Joo Han, MD<sup>2</sup>,  
Mi-Jung Lee, MD<sup>1</sup>

<sup>1</sup>Department of Radiology and Research Institute of Radiological Science, Severance  
Children's Hospital, Yonsei University, College of Medicine, Seoul, Korea

<sup>2</sup>Department of Pediatric Surgery, Severance Children's Hospital, Yonsei University, College  
of Medicine, Seoul, Korea

Perinatal detection of neonatal suprarenal masses has increased. Here, we report an unusual case of an adrenal cystic neuroblastoma that presented as a purely cystic lesion upon initial postnatal ultrasonography (US) and showed rapid evolution to a mixed cystic and solid mass during follow-up US and MRI. We suggest a short-term (two weeks) follow-up US for neonatal adrenal cystic lesions, even if they appear as purely cystic.

**Key words :** Neonate, Neuroblastoma, Ultrasonography

### Introduction

The increased use of prenatal and postnatal ultrasonography (US) is leading to the detection of an increasing number of suprarenal masses in neonates [1]. These masses are usually congenital neuroblastomas from the adrenal gland [2, 3]. Cystic suprarenal masses are uncommon, and the differential diagnosis includes adrenal cysts, adrenal hemorrhages, cystic neuroblastomas, renal cortical cysts, bronchogenic cysts, and subdiaphragmatic extralobar pulmonary sequestrations [1, 4]. The optimal diagnosis and treatment of perinatal suprarenal masses have not

yet been determined.

Cystic neuroblastomas generally appear as anechoic masses with multiple or single cysts, irregular margins, and a thick wall [5]. However, there can be various presentations of the mass; accordingly, knowledge of these differences can help with diagnoses and determination of the appropriate treatment.

We describe here a rare case of congenital cystic neuroblastoma that initially presented as a suprarenal pure unilocular cyst on postnatal US with rapid evolution.

## Case Report

A four-day-old male neonate was referred to our hospital with a history of a right renal cyst evident on prenatal US. The boy was born at an outside hospital by normal vaginal delivery at 37 weeks and 5 days with a body weight of 3200 g. Abdominal US administered on the day of admission revealed a thick-walled purely cystic lesion measuring 3 cm from the right adrenal gland (Fig. 1A). There was no internal septation, hemorrhage, or solid portion in the lesion, so the presumptive diagnosis was a benign adrenal cyst. The 24-hour urinary vanillyl mandelic acid level was within the normal range.

Follow-up US two weeks later showed that the lesion had increased in size to 3.4 cm in length and revealed wall thickening, tiny mural nodules, internal septations, and echogenic debris (Fig. 1B). Internal flow was not definitely detected in the lesion upon color Doppler analysis. Due to the possibility of cystic neuroblastoma, the infant underwent magnetic resonance imaging (MRI) three days later. Upon MRI, the cystic mass in the right suprarenal fossa showed an irregular solid wall with restricted diffusion and contrast enhancement, along with internal septations and hemorrhage, as seen upon US (Fig. 1C and 1D). No enlarged retroperitoneal lymph node or other abdominal metastatic lesions were seen. The impression was an adrenal cystic neuroblastoma.

The patient underwent follow-up US two weeks after the previous US, at which time the cystic mass showed an additional increase from 3.4 cm to 3.9 cm, with thickened internal septations and lobulated hyperechoic portions (Fig. 1E). Calcification was not seen in the lesion and there was no visible metastasis observed, including liver and retroperitoneal LN.

Right adrenalectomy was performed due to the lesion's rapid evolution. A well-capsulated mass was resected from the right adrenal gland. There was no demonstrably enlarged lymph node or intraabdominal metastasis observed during surgery.

Histological evaluation revealed the focal area of

adrenal parenchyma with a huge cyst. The final pathological diagnosis was undifferentiated neuroblastoma with cystic change. Calcification was not seen upon pathology and there was no N-myc amplification. Bone marrow biopsy showed no neuroblastoma involvement. The patient required no further treatment and remained free of disease 4 months later.

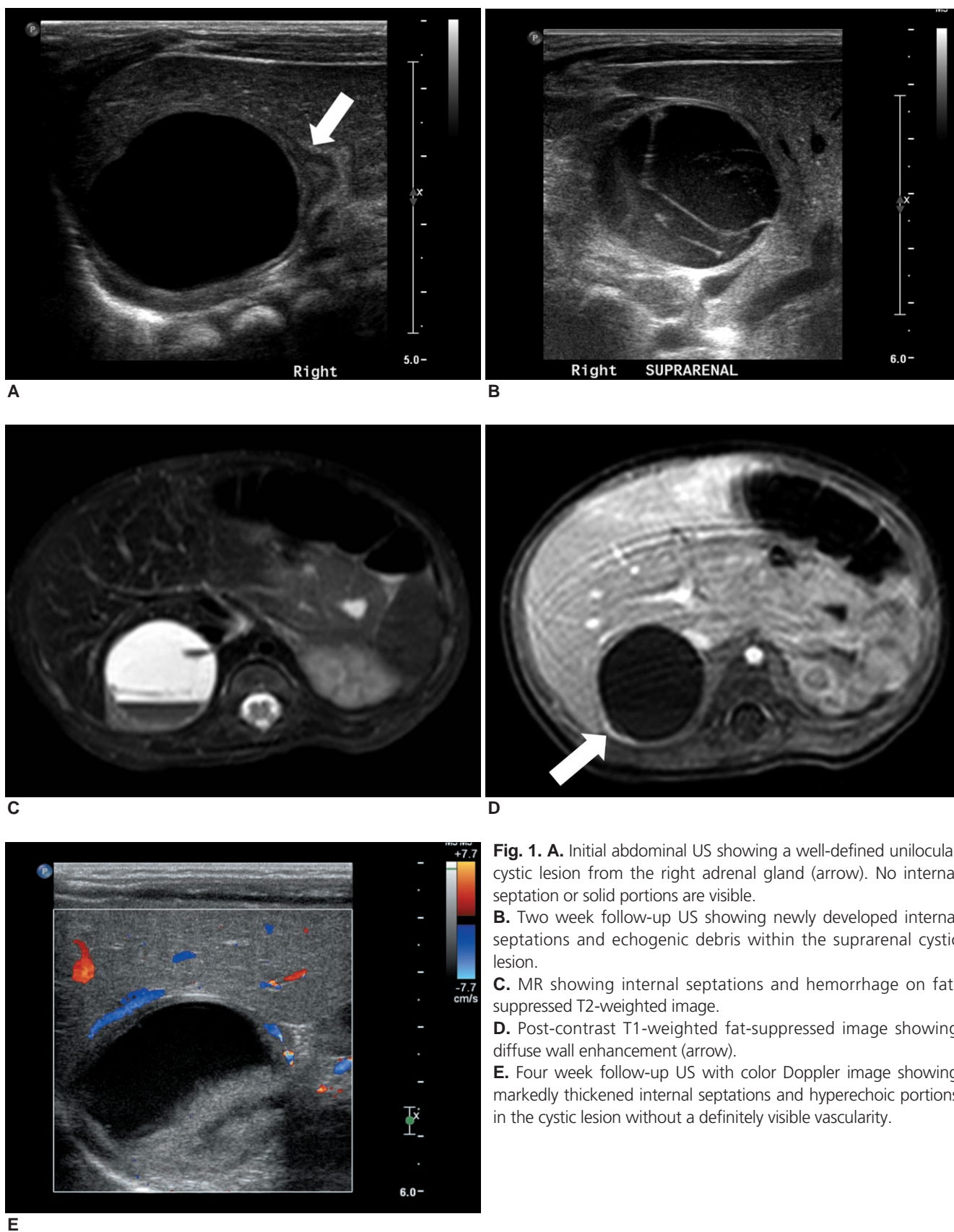
## Discussion

The majority of adrenal cystic lesions discovered upon prenatal US are shown to be cystic neuroblastomas [2, 4]. However, benign lesions such as adrenal cysts, adrenal hemorrhages or subdiaphragmatic extralobar pulmonary sequestration have also been reported as congenital adrenal cystic lesions [4]. The differentiation of these entities presenting as perinatal suprarenal cystic masses is difficult in many cases.

Adrenal cysts are very rare and are classified as endothelial cysts, pseudocysts, epithelial cysts, or parasitic cysts [6]. However, there are few reports on purely cystic adrenal lesions in neonates with limited image findings [2]. In this case, the prenatal diagnosis was a renal cyst, although prenatal US images were not available. The postnatal US showed a purely cystic lesion from the right adrenal gland.

Adrenal hemorrhage represents the most common cause of suprarenal mass lesions in neonates [5]. The spectrum of sonographic appearances of this lesion depends on the age of the hemorrhage [7]; therefore, it is difficult to differentiate an adrenal hemorrhage from cystic neuroblastoma.

It is known that cystic neuroblastomas usually become more complex, solid and form cystic masses with increased solid components upon follow-up imaging [8]. However, initial sonographic findings can range from cystic or mixed solid and cystic to completely solid masses, with or without septation or calcification. Prenatally detected neuroblastomas are frequently associated with normal levels of urinary catecholamine metabolites [2]. In addition, the optimal



**Fig. 1. A.** Initial abdominal US showing a well-defined unilocular cystic lesion from the right adrenal gland (arrow). No internal septation or solid portions are visible. **B.** Two week follow-up US showing newly developed internal septations and echogenic debris within the suprarenal cystic lesion. **C.** MR showing internal septations and hemorrhage on fat-suppressed T2-weighted image. **D.** Post-contrast T1-weighted fat-suppressed image showing diffuse wall enhancement (arrow). **E.** Four week follow-up US with color Doppler image showing markedly thickened internal septations and hyperechoic portions in the cystic lesion without a definitely visible vascularity.

diagnostic modalities and treatments for suprarenal cystic masses have yet to be elucidated.

Eo et al. [7] compared the image findings of 16 congenital cystic neuroblastomas and 12 adrenal hemorrhagic pseudocysts. They concluded that prenatal detection, the presence of calcification on initial images, vascularity upon color Doppler US, and evolution to a more complex mass may favor neuroblastomas. However, with the exception of prenatal detection, these findings were not observed on the initial US in our case, indicating that follow-up imaging studies are important even in the absence of these findings. Moreover, our case showed an increase in size with wall thickening and internal septation upon follow-up conducted at 2-weeks, even though almost no previously reported adrenal cystic neuroblastomas increased in size during follow-up.

Neonatal neuroblastomas usually show a good prognosis with many spontaneous regressions. However, the management strategies are still not clearly defined, and the relative risks associated with surgical excision and a wait-and-see strategy remain unclear. Accordingly, treatment should be restricted to the minimum amount necessary to prevent life threatening complications [4]. Therefore, close observation using US is very important. Observation periods have reportedly ranged from 1 to 6 months. However, an optimal follow-up interval has not been suggested yet. When tumors increase in size during follow-up, surgical excision is required to allow treatment and concurrent biological diagnosis [9]. The cystic neuroblastoma in our case showed significantly increased size with development of hemorrhage, septations, and wall thickening upon 2-week follow-up US. Moreover, it showed a further increase in size upon 4-week follow-up US, with thickened internal septations and lobulated hyperechoic portions. The lobulated hyperechoic portions can be considered as hematoma according to the color Doppler and MRI

findings. Therefore, we suggest a short-term (2 weeks) follow-up for perinatally detected suprarenal cysts, even if they appear as purely benign cysts. Additionally, further study to determine an optimal follow-up interval for neonatal suprarenal cystic lesions is needed.

## 요 약

신생아 신상부 종괴의 주산기 진단이 증가하고 있다. 본 증례는 출생 직후 초음파에서 단순 낭종으로 보였으나 이후 추적 초음파와 MRI 검사에서 빠르게 종괴로 변화한 비전형적인 부신 낭성 신경모세포종에 대한 보고이다. 이 증례를 통해 신생아에서 단순 부신 낭종이 보일 경우라도 단기 (2주) 추적 초음파를 시행할 것을 제안한다.

## References

1. Sauvat F, Sarnacki S, Brisse H, et al. Outcome of suprarenal localized masses diagnosed during the perinatal period: a retrospective multicenter study. *Cancer* 2002;94:2474-2480
2. Rubenstein SC, Benacerraf BR, Retik AB, Mandell J. Fetal suprarenal masses: sonographic appearance and differential diagnosis. *Ultrasound Obstet Gynecol* 1995;5:164-167
3. Acharya S, Jayabose S, Kogan SJ, et al. Prenatally diagnosed neuroblastoma. *Cancer* 1997;80:304-310
4. Stevens MC. Neonatal tumours. *Arch Dis Child* 1988;63:1122-1125
5. Atkinson GO, Jr., Zaatari GS, Lorenzo RL, Gay BB, Jr., Garvin AJ. Cystic neuroblastoma in infants: radiographic and pathologic features. *AJR Am J Roentgenol* 1986;146:113-117
6. Erbil Y, Salmaslioglu A, Barbaros U, et al. Clinical and radiological features of adrenal cysts. *Urol Int* 2008;80:31-36
7. Eo H, Kim JH, Jang KM, et al. Comparison of clinico-radiological features between congenital cystic neuroblastoma and neonatal adrenal hemorrhagic pseudocyst. *Korean J Radiol* 2011;12:52-58
8. Tanaka S, Tajiri T, Noguchi S, et al. Prenatally diagnosed cystic neuroblastoma: a report of two cases. *Asian J Surg* 2003;26:225-227
9. Horiuchi A, Watanabe Y, Miyauchi K, et al. Prenatally detected cystic adrenal neuroblastoma. *Pediatr Int* 2008;50:130-131