

Leiomyosarcoma of the Middle Ear and Temporal Bone

Bo Gyung Kim · Jin Kim · Won-Sang Lee

Department of Otorhinolaryngology, Yonsei University College of Medicine, Seoul, Korea

Leiomyosarcoma is a malignant tumor of smooth muscle cells that is exceedingly rare in the middle ear and temporal bone. Wide surgical resection is treatment of choice and adjuvant treatment has not proven to be of benefit. This is a report on a patient with otorrhea and rapidly growing mass on postauricular area. A tumor that was mainly located in the middle ear and temporal bone was surgically removed and proved to be a leiomyosarcoma. The optimal surgical technique and other treatment strategy are discussed.

Keywords. *Leiomyosarcoma, Middle ear, Temporal bone, Surgery*

INTRODUCTION

Leiomyosarcoma is an aggressive soft tissue sarcoma derived from smooth muscle cells that is exceedingly rare in the middle ear and temporal bone [1]. In the head and neck area, smooth muscle is sparse and found mainly in the walls of blood vessel [2]. And the majority of leiomyosarcoma of the head and neck arise in the oral cavity, superficial soft tissues like scalp, paranasal sinuses and jaws [3]. To best our knowledge, there is only 1 case of leiomyosarcoma reported in English literature before. In this article, we describe a case of leiomyosarcoma in the middle ear and temporal bone and also discuss optimal treatment including facial nerve management.

CASE REPORT

A 54-year-old man presented with 4-month history of otorrhea and a rapidly growing mass on the external auditory canal and

postauricular area after open cavity mastoidectomy at other hospital 5 months ago. He was otherwise healthy, with no significant medical history. He had received no previous radiotherapy. Physical examination revealed polypoid mass totally packed in external auditory canal and exophytic mass about 5×4 cm in postauricular area (Fig. 1).

No cervical lymph nodes were palpitated. No facial paralysis was present. The scalp and the remainder of the findings on otolaryngologic examination were within normal limits. Audiometry demonstrated a mixed hearing loss of 50 dB of bone conduction and 90 dB of air conduction hearing. Routine clinical laboratory data and a chest radiograph were normal. Two biopsies were performed. Histologic evaluation identified the lesion as a leiomyosarcoma with extensive necrosis.

Radiologic findings

Computed tomography (CT) of the temporal bone demonstrated a mass in the middle ear cavity, with absence of almost the entire temporal bone due to previous operation and with destruction of a part of petrous bone. The inner ear structures were preserved (Fig. 2A, B).

Magnetic resonance imaging (MRI) indicated a mass expending to pterygoid muscles, posterior margin of mandible and middle and posterior cranial fossa dura. The lesion obstructed the external auditory canal and could not be demarcated with granulation tissue (Fig. 2C, D).

• Received March 23, 2010

Revised April 23, 2010

Accepted April 28, 2010

• Corresponding author: **Won-Sang Lee**

Department of Otorhinolaryngology, Yonsei University College of Medicine,
134 Sinchon-dong, Seodaemun-gu, Seoul 120-752, Korea

Tel: +82-2-2228-3606, Fax: +82-2-393-0580

E-mail: wsleemd@yuhs.ac

Copyright © 2013 by Korean Society of Otorhinolaryngology-Head and Neck Surgery.

This is an open-access article distributed under the terms of the Creative Commons Attribution Non-Commercial License (<http://creativecommons.org/licenses/by-nc/3.0>) which permits unrestricted non-commercial use, distribution, and reproduction in any medium, provided the original work is properly cited.

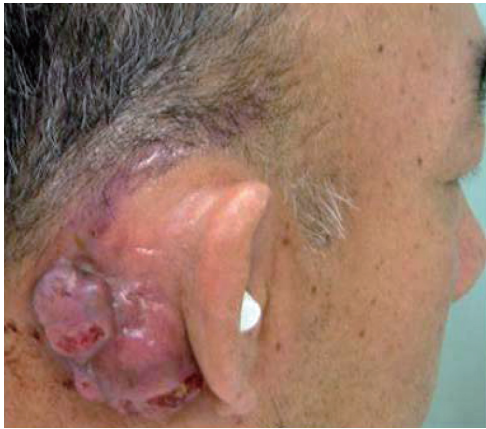

Fig. 1. The exophytic and polypoid mass about 5×4 cm in the right postauricular region. There was a scar of the previous surgical incision on the overlying skin. The mass was reddish and the surrounding skin had color alteration.

Surgical procedures

Subtotal temporal bone resection with epineural dissection of facial nerve

For the en bloc excision of the mass, the clear margin was 1.5 cm or more. The auricle was sacrificed for the design of surgical incision with the discolored skin.

The excisions of the temporal bone was conducted including the external auditory canal, the middle ear, the vestibular organ, middle and posterior fossa dura, and the partial petrous bone. The cochlear, the lateral sinus, and the jugular bulb remain intact (Fig. 3A). For the preservation of facial nerve function, the delicate epineural dissection of facial nerve was performed from tympanic segment to stylomastoid foramen and the fascicle of facial nerve was solely remain in middle ear cavity like as a clothesline (Fig. 3B). Complete tumor excision was confirmed by a frozen section from surgical boundaries.

Dura repair

The main mass did not invade the dura of middle cranial fossa or posterior cranial fossa, but came in direct contact with that. For the clear margin from the mass-contacted surface, the resection of the dura located on the middle cranial fossa was designed about 4.5×2.5 cm size and ovoid shape and the dura located on the posterior cranial fossa was designed about 2.5×2.5 cm size and round shape (Fig. 3C). The repair of the dura was done with Lyodura and reinforced with Gelform (Fig. 3D).

Reconstruction using pectoralis major myocutaneous flap

The pectoralis major myocutaneous flap was advanced and transposed to cover the temporal defect with protecting the fascicle of facial nerve using a piece of the muscle flap. The approximation of the pectoralis muscle flap was done without tension to the defect area (Fig. 3E). The specimen after en-bloc resection

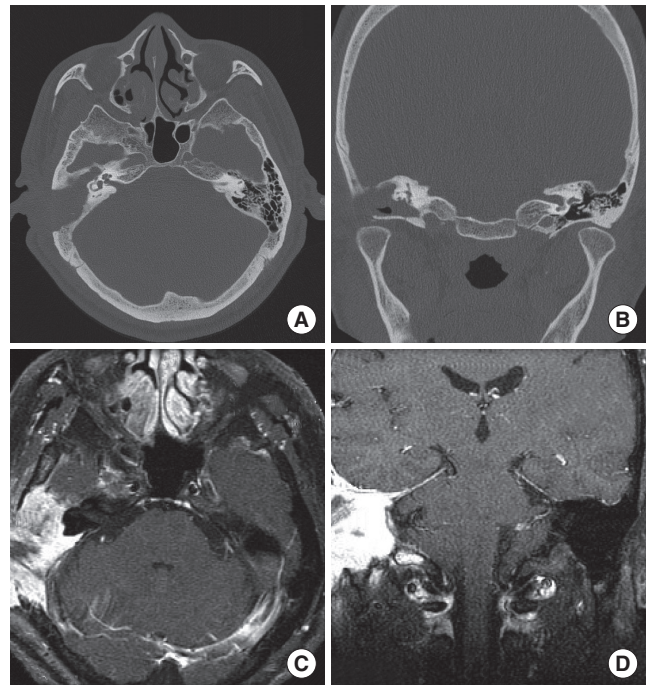


Fig. 2. Leiomyosarcoma of middle ear and temporal bone, (A) axial, (B) coronal computed tomography sections. A massive destructive lesion involves the temporal bone and the partial petrous bone with preservation of inner ear. (C) T1-weighted axial, (D) T1-weighted coronal magnetic resonance sections. The tumor spreads to pterygoid muscles, posterior margin of mandible and middle and posterior cranial fossa dura.

was shown on Fig. 3F.

Pathologic findings

Specimen were fixed in 10% formaldehyde solution, which contained a 0.1 molar phosphate buffering system (Ph=7). Slide stained with H&E were examined under the microscope. The tumor composed of spindle cells with cigar-shaped nuclei. Nuclear atypia was present. Cytoplasmic vacuoles were located at both ends of the nucleus (Fig. 4). Histopathological examination indicated the diagnosis of grade 3 leiomyosarcoma (30 mitoses/10 high power fields). There was no infiltration of tumor into epineurium of facial nerve, dura of middle and posterior cranial fossa, and Eustachian tube orifice.

Postoperative findings

The facial nerve function was well preserved as House-Brackmann grade II after epineural dissection of facial nerve (Fig. 5). There was no invasion of tumor into the epineurium of facial nerve in pathological finding and the fascicle of facial nerve in surgical finding. Although postoperative wound healing was delayed due to cerebrospinal fluid leakage to wound site for several days, but it did not cause any problem. There was not been seen any recurrence or metastasis.

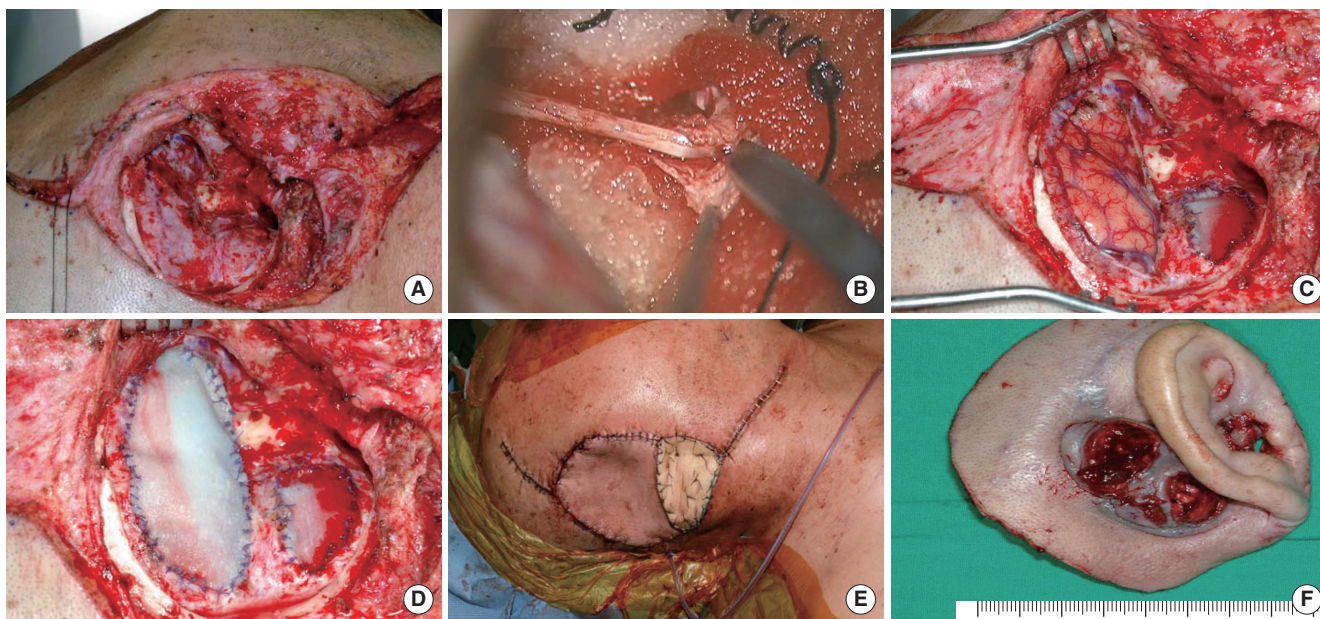


Fig. 3. The surgical procedure of leiomyosarcoma of the middle ear and temporal bone. (A) The excisions of the temporal bone was conducted including the external auditory canal, the middle ear, the vestibular organ, middle and posterior fossa dura, and the partial petrous bone, and the cochlear, the lateral sinus, and the jugular bulb remain intact. (B) The delicate epineural dissection of facial nerve was performed from tympanic segment to stylomastoid foramen. (C) The resections of the dura located on the middle and posterior cranial fossa were made. (D) The repair of the dura was done with Lyodura. (E) The approximation of the pectoralis muscle flap was done. (F) The specimen after en-bloc resection.

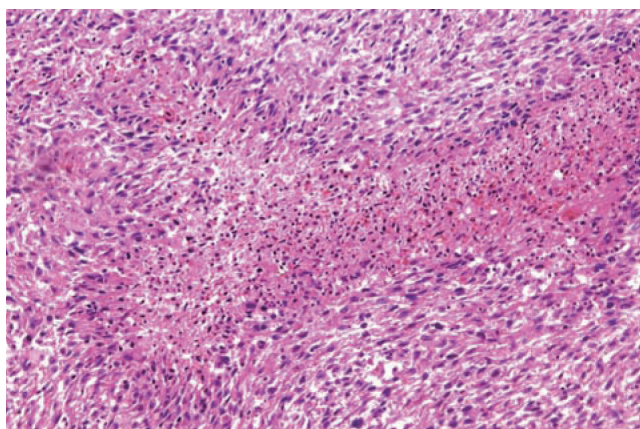


Fig. 4. The histology of leiomyosarcoma. It shows composed of spindle cells with cigar-shaped nuclei. There are mitotic activity and pleomorphic nuclei (H&E, $\times 100$).

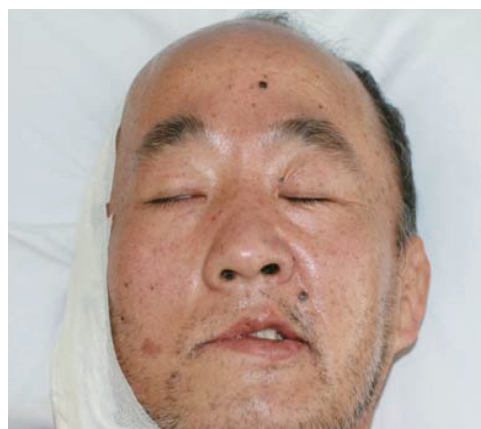

Fig. 5. The postoperative facial function. The facial nerve function was well preserved as House-Brackmann grade II after epineural dissection of facial nerve.

DISCUSSION

Leiomyosarcoma is an aggressive soft tissue sarcoma derived from smooth muscle cells typically of uterine, gastrointestinal or soft tissue origin that is often difficult to treat. The prognosis is poor, with survival rates among the lowest of all soft tissue sarcomas [4]. The rarity of these tumors makes definitive studies difficult to perform and there have only been a limited number of small case series published.

We stressed on three points, for the optimal treatment of this case.

First, surgical excision as wide as possible for the complete local control is required. The local control of leiomyosarcoma is achieved with surgical resection. Achieving wide surgical margins is important in preventing local recurrence [5]. Because adjacent pseudocapsule is commonly infiltrated by the tumor cells, the margin of the excision should be at least 1 cm in all directions when surgery is used alone [6]. But, the proximity of the

adjacent neurovascular structures, en bloc resection and achieving these margins at all tumor planes is almost impossible especially in the head and neck region. For improving rates of local control in this case, we removed dura, some of temporal bone and petrous bone that were adjacent to neurovascular structures and main mass for achieving clear margin. The effectiveness of adjuvant radiation in leiomyosarcoma has not been shown and is still a question since there is no supportive data. Some of the potential advantages of preoperative radiation therapy include decreased intraoperative seeding of tumor cells, and tumor shrinkage that might facilitate later surgery [7]. Suit et al. [8], evaluated the relationship between tumor size and the sequencing of radiation and showed that preoperative radiation was superior to postoperative radiation in terms of local control for patients with tumor greater than 15 cm. And others have shown no difference [9]. However Akcam et al. [10], emphasized the role of adjuvant radiotherapy in reducing the risk of recurrence surgically treated head and neck leiomyosarcoma even without tumor positive margins.

Second, the facial nerve preservation is mandatory. The patient had a mass lesion involving the tympanic and mastoid segment of facial nerve, but had an intact or favorable facial function. The management of facial nerve has been much challenging issue in such a case. In a viewpoint of micro-anatomical cross-section of tympanic and mastoid segment of facial nerve, moving more distally in the fallopian canal to the geniculate ganglion and tympanic segment, the space for the facial nerve becomes tight with the dura, epineurium, and perineurium completely filling the canal between the nerve and the bone at this point. And the epineurium is much thicker in the mastoid segment [11]. If the tumor is invading the facial nerve, as evidenced by the symptoms and radiologic examination, or if the facial nerve involvement is an intraoperative finding, the facial nerve involved should be included in the specimen. But in patients with favorable facial nerve function, we must select the technique of facial nerve preservation. Because of thick epineurium of tympanic and mastoid segment, the fascicle of facial nerve can be protected from tumor spread by the thick epineurium. The delicate epineural dissection of facial nerve is a persuasive technique for the facial nerve preservation in patient with tumor in middle ear or temporal bone. In pathologic finding, there was no invasion of tumor in the epineurium of facial nerve and eventually, the technique was a optimal management for facial nerve preservation and the local control of leiomyosarcoma in this case.

Third, compact repair and reconstruction for the defect of temporal area is essential. The defect in this patient tends to be problematic because of loss of soft tissue bulk after resection of the entire temporal bone and dura. This exposed bone and dura require coverage with myocutaneous flaps, either pedicled or as a free flap. These flaps all provide excellent soft tissue bulk for coverage of bone and dura and provide additional protection against osteonecrosis in the residual temporal bone and skull

base, all minimal donor site morbidity [12]. The pectoralis major flap is a proven method of reconstruction in head and neck surgery [13]. However, it has limitations in the reconstruction of lateral skull base attributable to the inability to achieve adequate length to reach defects involving significant parietal area.

The other free flap can be used in this case was rectus abdominis flap. The rectus can be used as a myofascial or myocutaneous free flap and also provides substantial bulk that is useful for filling dead space and can be placed anywhere on the skull. It can be harvested with the patient in supine position and is far enough away from the recipient site to allow a two-team approach [14]. We used the pectoralis major flap for a method of reconstruction and full thickness skin graft from abdomen without limitation of length to reach the defect, and it provided good soft tissue bulk for coverage of bone and dura.

In conclusion, the present case had an unusual localization of leiomyosarcoma. The leiomyosarcoma in this area was delayed or misdiagnosed, since it is rare tumor. Histopathological examination is essential for accurate histological diagnosis. Radical wide-field resection with or without radiotherapy and/or chemotherapy is the most effective way to treat leiomyosarcoma of middle ear and temporal bone.

CONFLICT OF INTEREST

No potential conflict of interest relevant to this article was reported.

REFERENCES

1. Zbaren P, Ruchti C. Leiomyosarcoma of the middle ear and temporal bone. *Ann Otol Rhinol Laryngol*. 1994 Jul;103(7):537-41.
2. Mindell RS, Calcaterra TC, Ward PH. Leiomyosarcoma of the head and neck: a review of the literature and report of two cases. *Laryngoscope*. 1975 May;85(5):904-10.
3. Marioni G, Bertino G, Mariuzzi L, Bergamin-Bracale AM, Lombardo M, Beltrami CA. Laryngeal leiomyosarcoma. *J Laryngol Otol*. 2000 May;114(5):398-401.
4. Mankin HJ, Casas-Ganem J, Kim JI, Gebhardt MC, Hornicek FJ, Zeegen EN. Leiomyosarcoma of somatic soft tissues. *Clin Orthop Relat Res*. 2004 Apr;421:225-31.
5. Farshid G, Pradhan M, Goldblum J, Weiss SW. Leiomyosarcoma of somatic soft tissues: a tumor of vascular origin with multivariate analysis of outcome in 42 cases. *Am J Surg Pathol*. 2002 Jan;26(1):14-24.
6. Eilber FR, Eckardt J. Surgical management of soft tissue sarcomas. *Semin Oncol*. 1997 Oct;24(5):526-33.
7. Yang JC, Chang AE, Baker AR, Sindelar WF, Danforth DN, Topalian SL, et al. Randomized prospective study of the benefit of adjuvant radiation therapy in the treatment of soft tissue sarcomas of the extremity. *J Clin Oncol*. 1998 Jan;16(1):197-203.
8. Suit HD, Mankin HJ, Wood WC, Gebhardt MC, Harmon DC, Rosenberg A, et al. Treatment of the patient with stage M0 soft tissue sarcoma. *J Clin Oncol*. 1988 May;6(5):854-62.

9. Cheng EY, Dusenbery KE, Winters MR, Thompson RC. Soft tissue sarcomas: preoperative versus postoperative radiotherapy. *J Surg Oncol.* 1996 Feb;61(2):90-9.
10. Akcam T, Oysul K, Birkent H, Gerek M, Yetiser S. Leiomyosarcoma of the head and neck: report of two cases and review of the literature. *Auris Nasus Larynx.* 2005 Jun;32(2):209-12.
11. Ogawa A, Sando I. Spatial occupancy of vessels and facial nerve in the facial canal. *Ann Otol Rhinol Laryngol.* 1982 Jan-Feb;91(1 Pt 1):14-9.
12. Gal TJ, Kerschner JE, Futran ND, Bartels LJ, Farris JB, Ridley MB, et al. Reconstruction after temporal bone resection. *Laryngoscope.* 1998 Apr;108(4 Pt 1):476-81.
13. Baek SM, Biller HF, Krespi YP, Lawson W. The pectoralis major myocutaneous island flap for reconstruction of the head and neck. *Head Neck Surg.* 1979 Mar-Apr;1(4):293-300.
14. Neligan PC, Mulholland S, Irish J, Gullane PJ, Boyd JB, Gentili F, et al. Flap selection in cranial base reconstruction. *Plast Reconstr Surg.* 1996 Dec;98(7):1159-66.