

Importance of immediate surgical intervention and antifungal treatment for rhinocerebral mucormycosis: a case report

Jin-Geun Kim, Hye Jeong Park, Jung Hyun Park, Jiwoong Baek, Hyung Jun Kim, In-Ho Cha, Woong Nam

Department of Oral and Maxillofacial Surgery, College of Dentistry, Yonsei University, Seoul, Korea

Abstract (J Korean Assoc Oral Maxillofac Surg 2013;39:246-250)

Rhinocerebral mucormycosis (RCM) is an opportunistic, potentially life-threatening fungal disease. This infective disease invades not only the facial sinuses, but also the maxilla, zygoma, and rhino-cerebral structures with a massive destruction of the facial skeletons and soft tissue. This disease progresses within various underlying diseases, such as diabetes mellitus, hematologic malignancy, renal failure, and systemic immunodepression. The relationship between mucormycosis and these underlying conditions have been discussed extensively in the literature. The authors studied 6 cases of RCM diagnosed by a tissue biopsy and treated at the department of oral and maxillofacial surgery, from 1997 to 2012. Patients were treated with several kinds of surgical interventions and antifungal agents, and their clinical & radiological signs, underlying conditions, surgical methods, and outcomes were analyzed.

Key words: Mucormycosis, Diabetes mellitus, Diagnosis

[paper submitted 2013. 6. 19 / revised 2013. 8. 4 / accepted 2013. 8. 5]

I. Introduction

Mucormycosis is known as a life-threatening fungal disease that destroys hard and soft tissue especially within various predisposing underlying conditions. Among five subtypes (rhinocerebral, pulmonary, intestinal, cutaneous, and disseminated), rhinocerebral mucormycosis (RCM) is a rare, fatal, opportunistic subtype invading the oral and maxillofacial areas including facial sinuses, maxilla, zygoma, orbit, and oral cavity. Clinical signs include facial cellulitis, orbital swelling, black necrotic palate, and facial (VII) and/or trigeminal (V) nerve involvement¹. Nasal obstruction or congestion with noisy breathing, headache, odontalgia, sinusitis with low-grade fever and unilateral facial swelling, maxillary pain,

hyposmia, and anosmia have also been described as typical symptoms of the disease².

This study sought to present a series of cases involving six patients diagnosed with RCM and treated with several methods, consider the prevalence and mortality factors, and analyze each case with reference to related articles.

II. Case Report

Six patients diagnosed with RCM based on tissue biopsy and treated in several conservative and surgical ways in our department between the years 1997-2012 were studied retrospectively. Their clinical symptoms, imaging findings, underlying diseases, surgical methods, and time consumed from the first visit to our department to the first medical and surgical interventions were analyzed and discussed.

The six patients, whose average age was 65.0 years (49-74 years), were diagnosed with mucormycosis in the oral and maxillofacial areas based on tissue biopsy. (Table 1) Facial swelling (n=3; 50%) and headache (n=3; 50%) were the most common symptoms, followed by hypoesthesia (n=2; 33.3%). Maxillary sinus was involved most frequently (n=5; 83.3%), followed by sphenoid and ethmoid sinus (n=2; 40%) and

Woong Nam

Department of Oral and Maxillofacial Surgery, College of Dentistry, Yonsei University, 50, Yonsei-ro, Seodaemun-gu, Seoul 120-752, Korea

TEL: +82-2-2228-2971 FAX: +82-2227-8022

E-mail: omsnam@yuhs.ac

©This is an open-access article distributed under the terms of the Creative Commons Attribution Non-Commercial License (<http://creativecommons.org/licenses/by-nc/3.0/>), which permits unrestricted non-commercial use, distribution, and reproduction in any medium, provided the original work is properly cited.

Copyright © 2013 The Korean Association of Oral and Maxillofacial Surgeons. All rights reserved.

This research was supported by Basic Science Research Program through the National Research Foundation of Korea (NRF) funded by the Ministry of Education (2009-0094027).

Table 1. Summary of rhinocerebral mucormycosis patient data

No. of patient	Age (yr)	Sex	Clinical symptom	Underlying disease	Imaging finding	Surgical method	1st visit-surgical operation (day)	1st visit-antifungal medication (day)
1	49	M	Facial swelling, hypoesthesia, headache, general toothache	DM Renal failure Meningitis	Right maxillary, sphenoidal, ethmoidal sinus	Ethmoid-sphenoidectomy	12	11
2	74	F	Facial swelling, fever, headache	DM Hepatitis B Hypertension	Left maxillary sinus Nasal cavity Alveolar bone	Sequestrectomy	40	42
3	72	M	Facial swelling, intraoral fistula	DM, MI Angina pectoris Arteriosclerosis S/P PTCA d/t CAOD	Left maxillary, ethmoidal, sphenoidal sinus, left zygoma, nasal bone, floor of orbit, alveolar bone	Sequestrectomy	24	43
4	67	M	Headache, fever, trismus, diplopia	DM	Left maxillary sinus Acute orbital cellulitis Right lateral pterygoid muscle, temporalis muscle, and prezygomatic subcutaneous space abscess	Caldwell-Luc operation Antrostomy	40	45
5	71	M	General toothache, hypoesthesia	DM Aplastic anemia	Right maxillary sinus Right floor of orbit	Sequestrectomy	7	28
6	57	F	Non-symptomatic mass on soft palate	Angina pectoris Pyelonephritis	-	-	-	12

(M: male, F: female, DM: diabetes mellitus, MI: myocardial infarction, S/P: status post, PTCA: percutaneous transluminal coronary angioplasty, d/t: due to, CAOD: coronary artery occlusive disease)

Jin-Geun Kim et al: Importance of immediate surgical intervention and antifungal treatment for rhinocerebral mucormycosis: a case report. *J Korean Assoc Oral Maxillofac Surg* 2013

floor of orbit (n=2; 40%).

Five patients (patient numbers 1, 2, 3, 4, 5) had diabetes mellitus (DM) as an underlying disease (n=5; 83.3%). These patients with DM had surgical intervention and antifungal therapy (amphotericin B [AmB] or liposomal amphotericin B [L-AmB] or posaconazole); one patient (patient number 6) had polyene gargle treatment only without surgery. Antifungal medication was basically initiated with AmB up to 2.0 g. Monitoring nephrotic values such as level of serum blood urea nitrogen or creatinine and calculating accumulative dose, medications were changed to L-AmB or posaconazole.

Surgical methods were sequestrectomy of the involved maxilla, zygoma, and floor of orbit, ethmoid-sphenoidectomy, Caldwell-Luc operation, and antrostomy. Most of our patients (patient numbers 2, 3, 4, 5) had surgery under the impression of osteomyelitis (OM) as their clinical and radiological aspects. Final reports of the pathologic report enabled us to assure the RCM of four patients 2-7 days after the major surgery. The other patient (patient number 1), as we mentioned above, had final diagnosis of RCM based on tissue biopsy 2 days before he had surgery, i.e., ethmoid-sphenoidectomy. After the surgical intervention, they were referred to the Department of Infectious Diseases at Severance Hospital for intensive antifungal treatment. Before all patients were

discharged without any mortality, they had started to be treated in the department of prosthodontics for the restoration of their appearance and function.

We present in detail the case of one patient, a 72-year-old male who had the most aggressive oral-maxillofacial involvement including several facial bones. His had several underlying diseases as seen in Table 1. He was first referred to our department with left maxillary gingival pain and suborbital swelling that had started about 10 days before the first visit. The clinical examination revealed generalized swelling and tenderness on the left mid-face with intraoral fistula in the left maxillary vestibule. The facial computed tomography imaging showed extensive invasion of the left maxillary sinus and other facial bones, making extensive sequestrum at the left maxilla, zygoma, nasal bone, floor of orbit, and maxillary alveolar bone. (Fig. 1) With OM presumed in the above area, the patient underwent sequestrectomy of the left maxilla, zygoma, alveolar bone, and extraction of the teeth involved. After being diagnosed with RCM based on tissue biopsy (Fig. 2), he was referred to the department of infectious diseases for systemic antifungal treatment, receiving AmB, liposomal amphotericin, and posaconazole. Post-operation wound healing was favorable, and temporary acute renal failure was corrected immediately.

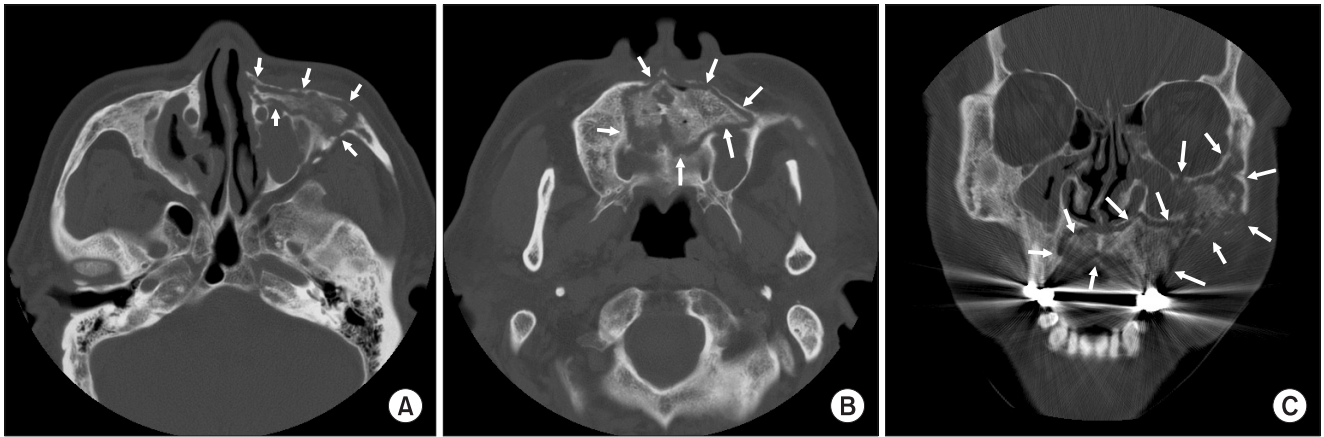


Fig. 1. A. Preoperation computed tomography (CT) axial view: presenting involvement of left maxilla, zygoma and severe mucosal thickening on both maxillary sinus. B. Preoperation CT axial view: presenting involvement of maxilla, left maxillary sinus; and increased bony sclerosis in the medullary portion of left maxilla. C. Preoperation CT frontal view: presenting involvement of left maxilla, zygoma, floor of orbit, ethmoidal, sphenoidal sinus, nasal cavity, alveolar bone. Arrows indicate the border of the lesion.

Jin-Geun Kim et al: Importance of immediate surgical intervention and antifungal treatment for rhinocerebral mucormycosis: a case report. J Korean Assoc Oral Maxillofac Surg 2013

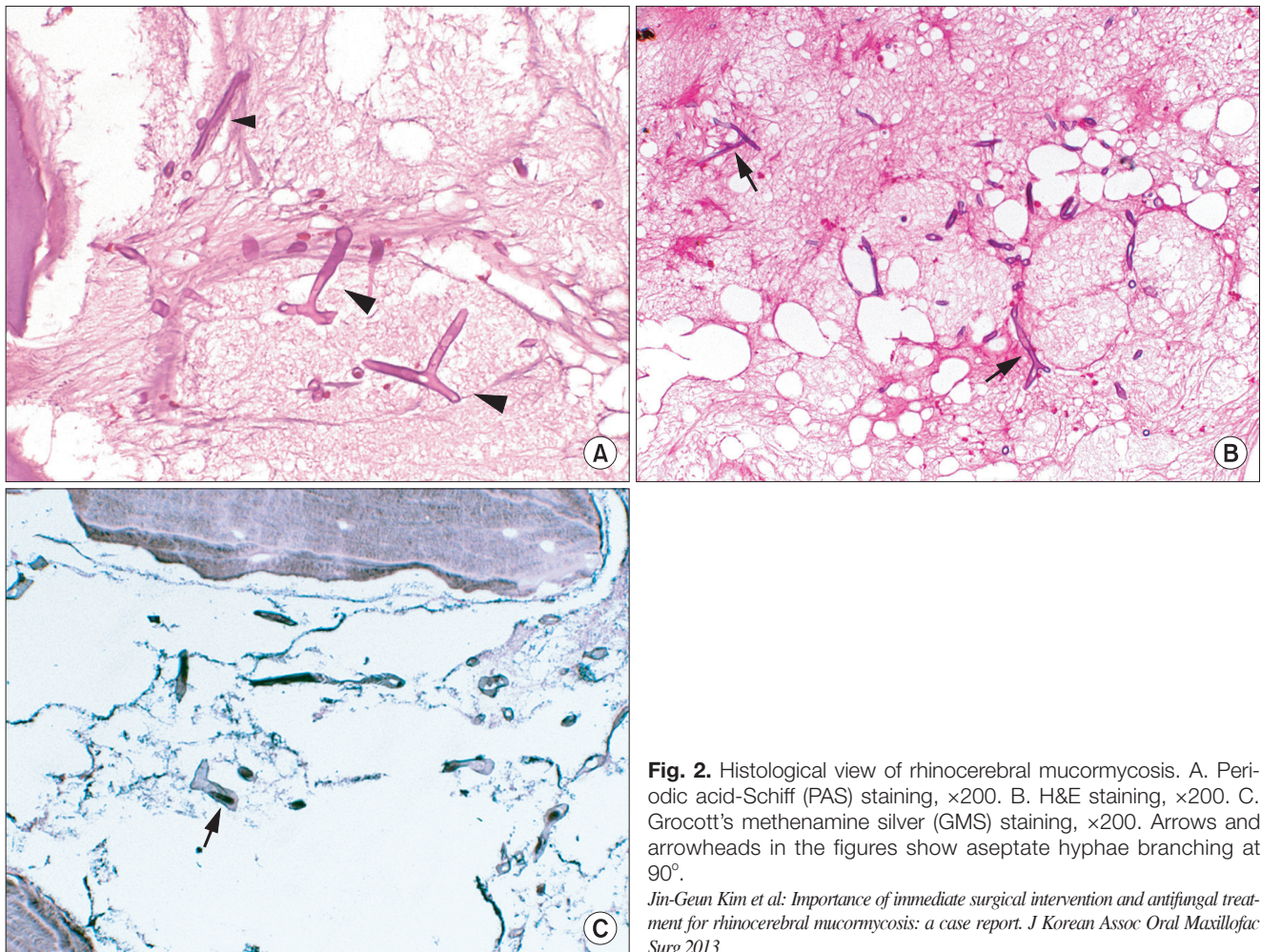


Fig. 2. Histological view of rhinocerebral mucormycosis. A. Periodic acid-Schiff (PAS) staining, $\times 200$. B. H&E staining, $\times 200$. C. Grocott's methenamine silver (GMS) staining, $\times 200$. Arrows and arrowheads in the figures show aseptate hyphae branching at 90° .

Jin-Geun Kim et al: Importance of immediate surgical intervention and antifungal treatment for rhinocerebral mucormycosis: a case report. J Korean Assoc Oral Maxillofac Surg 2013

III. Discussion

Early diagnosis, reversal of underlying host impairments, antifungal medication, and surgical intervention are important in treating RCM³.

Clinical/radiological aspects of RCM are not easy to distinguish from ordinary OM in the oral and maxillofacial areas. The clinical symptoms of our patients included atypical pain, swelling, and loss of functions in the oral and maxillofacial areas, and they do not have particular discriminative points such as fungal infection. Moreover, radiological aspects were not beneficial in prognosticating RCM from OM, either. Typical computed tomography (CT) findings include diffuse thickening of the mucosa of the sinuses involved. This is frequently accompanied by the erosion and destruction of the bony sinus wall and extrasinusoidal spread of the infection³. These resemble the ordinary OM, and the CT views of our patients were also similar to the conventional OM, such as low attenuated irregular intra-bony lesions, sequestrum such as amorphous, high attenuated bony fragments in the affected structure, and increased bony sclerosis in the medullary portion adjacent to the lesions. Because of these unremarkable features of RCM, it used to take time to be aware of fungal infection. When extensive aspect of OM is noted in the oral and maxillofacial areas, we should check the systemic condition and perform prompt tissue biopsy for the confirmation of fungal infection, immediate treatment planning, and proper intervention.

Though the prevalence risk factors and treatment strategies have been well studied for several decades, the rates of mucormycosis with life-threatening mortality are increasing⁴. With well-investigated pathophysiologic pathway^{5,6}, DM is the most commonly reported risk factor of mucormycosis particularly in the oral and maxillofacial areas. Roden et al.⁷ found DM to be the most common underlying condition for mucormycosis in the oral and maxillofacial areas. In the article, diabetes type I and diabetes type 2 were reported as independent predictors for oral and maxillofacial mucormycosis. We could reconfirm the relations between the occurrence of oral and maxillofacial mucormycosis and DM since five of our six patients had DM and unilateral maxillary sinus involvement; two had sphenoid and ethmoid sinus involvement, and two, orbit involvement.

Although an important prevalence risk factor, DM has low relevance with the mortality of mucormycosis^{7,8}. In contrast, hematologic malignancy is presented as the most fatal factor of mucormycosis in many articles^{4,7,9-12}. Given evidence that

the prevalence and mortality risk factors of mucormycosis are not the same, we should approach the prevention and treatment of mucormycosis independently. All six patients in our cases survived regardless of whether they had surgical intervention (n=5) or not (n=1). This high survival rate is suggestive, considering other studies reporting high mortality of RCM. Though 83% (n=5) of the patients had DM, all of them were in a course of proper care. We evaluated that no one had hematologic malignancy, which was an important factor for the low mortality in this report.

The efficacy and proper dosage of AmB have been reproducibly demonstrated in both laboratory (*in vitro* and *in vivo*) investigations and in clinical studies¹²⁻¹⁶, and there is a report of delayed AmB-based therapy resulting in 2-fold increase in mortality rate¹². The L-AmB formulation has better penetration into cerebral tissue than other agents; hence its potentially better efficacy in cases of rhinocerebral involvement¹⁵. Furthermore, posaconazole, combination therapy with echinocandins and deferasirox, and hyperbaric oxygen can be used as adjunctive therapy in the management of mucormycosis¹⁴.

Surgical debridement is fundamental for the successful management of most cases of RCM. Using less aggressive surgical procedures with combined medication may enhance survival from oral and maxillofacial mucormycosis¹⁴. The general impression of intra-operative finding was similar to that of OM as well as clinical/radiological features. There was necrotic bone with sequestrum, with some granulation tissue with pus discharge in the structures involved. Note, however, that there was extensive spreading of the lesions even to the frontal process of maxilla close to the orbit, compared with the OM we used to experience.

We spent 24.6 days and 30.2 days on the average from the first visit to surgical intervention and commencement of antifungal medication. Despite the difficult diagnosis of RCM, shortening the time to start antifungal medication and surgical intervention were thought to be the most important factors for the high survival rate in our study. The authors performed surgical/medical interventions on oral and maxillofacial mucormycosis patients with variable underlying diseases and reported high survival rate of the cases.

References

1. Abu El-Naaj I, Leiser Y, Wolff A, Peled M. The surgical management of rhinocerebral mucormycosis. *J Craniomaxillofac Surg* 2013;41:291-5.
2. Mantadakis E, Samonis G. Clinical presentation of zygomycosis.

- Clin Microbiol Infect 2009;15(Suppl 5):15-20.
3. Dhiwakar M, Thakar A, Bahadur S. Improving outcomes in rhino-cerebral mucormycosis--early diagnostic pointers and prognostic factors. *J Laryngol Otol* 2003;117:861-5.
 4. Bitar D, Van Cauteren D, Lanternier F, Dannaoui E, Che D, Dromer F, et al. Increasing incidence of zygomycosis (mucormycosis), France, 1997-2006. *Emerg Infect Dis* 2009;15:1395-401.
 5. Rammaert B, Lanternier F, Poirée S, Kania R, Lortholary O. Diabetes and mucormycosis: a complex interplay. *Diabetes Metab* 2012;38:193-204.
 6. Chinn RY, Diamond RD. Generation of chemotactic factors by *Rhizopus oryzae* in the presence and absence of serum: relationship to hyphal damage mediated by human neutrophils and effects of hyperglycemia and ketoacidosis. *Infect Immun* 1982;38:1123-9.
 7. Roden MM, Zaoutis TE, Buchanan WL, Knudsen TA, Sarkisova TA, Schaufele RL, et al. Epidemiology and outcome of zygomycosis: a review of 929 reported cases. *Clin Infect Dis* 2005;41:634-53.
 8. Chakrabarti A, Das A, Mandal J, Shivaprakash MR, George VK, Tarai B, et al. The rising trend of invasive zygomycosis in patients with uncontrolled diabetes mellitus. *Med Mycol* 2006;44:335-42.
 9. Spellberg B, Kontoyiannis DP, Fredricks D, Morris MI, Perfect JR, Chin-Hong PV, et al. Risk factors for mortality in patients with mucormycosis. *Med Mycol* 2012;50:611-8.
 10. Llorente A, Perez-Valero I, García E, Heras I, Fraile V, García P, et al. Mortality risk factors in patients with zygomycosis: a retrospective and multicentre study of 25 cases. *Enferm Infecc Microbiol Clin* 2011;29:263-8.
 11. Pagano L, Offidani M, Fianchi L, Nosari A, Candoni A, Piccardi M, et al; GIMEMA (Gruppo Italiano Malattie EMatologiche dell'Adulto) Infection Program. Mucormycosis in hematologic patients. *Haematologica* 2004;89:207-14.
 12. Chamilos G, Lewis RE, Kontoyiannis DP. Delaying amphotericin B-based frontline therapy significantly increases mortality among patients with hematologic malignancy who have zygomycosis. *Clin Infect Dis* 2008;47:503-9.
 13. Rapis AD. Orbitomaxillary mucormycosis (zygomycosis) and the surgical approach to treatment: perspectives from a maxillofacial surgeon. *Clin Microbiol Infect* 2009;15(Suppl 5):98-102.
 14. Gamaletsou MN, Sipsas NV, Roilides E, Walsh TJ. Rhino-orbital-cerebral mucormycosis. *Curr Infect Dis Rep* 2012;14:423-34.
 15. Groll AH, Giri N, Petraitis V, Petraitiene R, Candelario M, Bacher JS, et al. Comparative efficacy and distribution of lipid formulations of amphotericin B in experimental *Candida albicans* infection of the central nervous system. *J Infect Dis* 2000;182:274-82.
 16. Reed C, Bryant R, Ibrahim AS, Edwards J Jr, Filler SG, Goldberg R, et al. Combination polyene-caspofungin treatment of rhino-orbital-cerebral mucormycosis. *Clin Infect Dis* 2008;47:364-71.