

CASE REPORT

Immunology, Allergic Disorders & Rheumatology

<http://dx.doi.org/10.3346/jkms.2013.28.3.472> • *J Korean Med Sci* 2013; 28: 472-475

Two Cases of Refractory Thrombocytopenia in Systemic Lupus Erythematosus that Responded to Intravenous Low-Dose Cyclophosphamide

**Hee-Jin Park, Mi-il Kang, Yoon Kang,
Soo-jin Chung, Sang-Won Lee,
Yong-Beom Park, and Soo-Kon Lee**Division of Rheumatology, Department of Internal
Medicine, Yonsei University College of Medicine,
Seoul, KoreaReceived: 20 July 2012
Accepted: 7 December 2012

Address for Correspondence:

Sang-Won Lee, MD

Division of Rheumatology, Department of Internal Medicine,
Yonsei University College of Medicine, 250 Yonsei-ro,
Seodaemun-gu, Seoul 120-752, Korea
Tel: +82.2-2228-1947, Fax: +82.2-393-6884
E-mail: sangwonlee@yuhs.ac

Treatment of thrombocytopenia in systemic lupus erythematosus (SLE) is considered in cases of current bleeding, severe bruising, or a platelet count below 50,000/ μ L. Corticosteroid is the first choice of medication for inducing remission, and immunosuppressive agents can be added when thrombocytopenia is refractory to corticosteroid or recurs despite it. We presented two SLE patients with thrombocytopenia who successfully induced remission after intravenous administration of low-dose cyclophosphamide (CYC) (500 mg fixed dose, biweekly for 3 months), followed by azathioprine (AZA) or mycophenolate mofetil (MMF). Both patients developed severe thrombocytopenia in SLE that did not respond to pulsed methylprednisolone therapy, and started the intravenous low-dose CYC therapy. In case 1, the platelet count increased to 50,000/ μ L after the first CYC infusion, and remission was maintained with low dose prednisolone and AZA. The case 2 achieved remission after three cycles of CYC, and the remission continued with low dose prednisolone and MMF.

Key Words: Cyclophosphamide; Systemic Lupus Erythematosus; Thrombocytopenia**INTRODUCTION**

Systemic lupus erythematosus (SLE) is the prototypic inflammatory autoimmune disease characterized by multi-organ involvement. Hematological manifestations in the revised criteria for the classification of SLE include hemolytic anemia, leucopenia, lymphopenia, and thrombocytopenia (1).

Treatment of thrombocytopenia in SLE is considered in cases of current bleeding, severe bruising, or a platelet count below 50,000/ μ L (1). For SLE patients suffering from complex and life-threatening thrombocytopenia, high dose corticosteroid should be administered first. When thrombocytopenia does not respond to corticosteroid monotherapy, or when it recurs despite corticosteroid therapy, other medications such as danazol, intravenous immunoglobulin, and immunosuppressants can be added to the corticosteroid (1-4).

Intravenous cyclophosphamide (IV CYC) is widely used in the treatment of proliferative lupus nephritis (class III and IV). Recently, low-dose IV CYC (500 mg/day, biweekly for 3 months) followed by azathioprine (AZA) or mycophenolate mofetil (MMF) has been reported to exhibit effects similar to those of a high-dose IV CYC regimen (National Institutes of Health protocol: 750-1,000 mg/m² body surface area, monthly), but with fewer complications such as infection or bone marrow suppression

than high-dose IV CYC regimen (5). Previous reports have also revealed that a high-dose CYC regimen was effective for refractory thrombocytopenia in SLE (2, 3). However, there are few reports on the efficacy of a low-dose IV CYC regimen in SLE patients with refractory thrombocytopenia.

Here, we report two SLE patients with refractory thrombocytopenia who successfully recovered after the administration of low-dose IV CYC followed by AZA or MMF.

CASE DESCRIPTION**Case 1**

A 24-yr-old woman had been diagnosed with SLE according to the presence of antinuclear antibody (ANA) and anti-ds DNA, pancytopenia, and arthritis in June 2010. At the time of diagnosis, she had an ANA titer of 1:640, mixed type; an anti-ds DNA level of 571.3 AU (ELISA, positive, \geq 92.6 AU); a white blood cell (WBC) count of 560/ μ L (neutrophils, 82.6%; lymphocytes, 2.6%); a platelet count of 65,000/ μ L; and a hemoglobin concentration of 6.7 g/dL. The erythrocyte sedimentation rate (ESR) was 2 mm/h, and the C-reactive protein (CRP) concentration was 4.80 mg/L. Complements 3 and 4 were decreased to 22.1 mg/dL (normal: 90-180 mg/dL) and 5.65 mg/dL (normal: 10-40 mg/dL), respectively. We performed a bone marrow biopsy that showed no ab-

normal findings. Concluding that the leucopenia and thrombocytopenia were hematological manifestations associated with SLE, we started administration of prednisolone (1 mg/kg/day) and AZA (25 mg/day). The thrombocytopenia improved, with an increased platelet count above 100,000/ μ L, and the dose of prednisolone was tapered to 15 mg/day. However, she was admitted with fever, pleuritic chest pain, and pancytopenia, including severe thrombocytopenia, 6 months later. Laboratory results on admission showed that WBC and platelet counts were 2,250/ μ L (neutrophils, 86.3%; lymphocytes, 7.6%) and 10,000/ μ L, respectively. The hemoglobin concentration was 6.7 g/dL, and the corrected reticulocyte percentage was 1.04%. The ESR was 39 mm/hr, and the CRP concentration was 33.02 mg/L. Complements 3 and 4 were reduced to 36.4 and 9.1 mg/dL, respectively, while the anti-ds DNA level had increased, from 497.3 to 548.3 AU (ELISA). Computed tomography of the chest and abdomen revealed pericardial and bilateral pleural effusion, but not splenomegaly. To rule out other diseases, including hemophagocytic syndrome and aplastic anemia, we performed a bone marrow biopsy. The results showed normal cellularity and abundant megakaryocytes, suggesting severe thrombocytopenia in SLE. She received pulsed intravenous methylprednisolone (1,000 mg/day) for 3 days, followed by oral prednisolone (1 mg/kg/day) and intravenous immunoglobulin (5 g/day) for 5 days. The anemia, leucopenia, and serositis were markedly improved, but the platelet count was still 11,000/ μ L after finishing pulsed methylprednisolone therapy. Next day after pulsed methylprednisolone therapy, she began low-dose IV CYC therapy (500 mg/day, biweekly). Her platelet count increased to 50,000/ μ L on day 11 after the first CYC infusion, and a stable platelet count above 100,000/ μ L was maintained with no CYC complications. She completed six cycles of low-dose IV CYC therapy over 3 months and could decrease the dose of prednisolone. She maintained on

low-dose prednisolone (10 mg/day) and 50 mg of AZA, and her platelet count was remained above 150,000/ μ L after 12 months (Fig. 1A).

Case 2

A 47-yr-old woman was admitted for 2-month recurrent oral ulcer, anemia, and skin lesions, including purpura and petechiae, on August 14, 2010. On admission, laboratory results showed WBC and platelet counts of 3,700/ μ L (neutrophils, 55.6%; lymphocytes, 34.5%) and 5,000/ μ L, respectively. The hemoglobin concentration was 7.4 g/dL; the corrected reticulocyte percentage was 1.15%; the ESR was 33 mm/hr; and the CRP concentration was < 0.1 mg/L. Levels of ferritin and LDH were not elevated, to 4.2 ng/mL (normal: 11-306 ng/mL) and 223 IU/L (normal: 119-247 IU/L), respectively. Neither proteinuria nor hematuria was observed. ANA was detected at a titer of 1:640, but anti-ds DNA was negative. Complements 3 and 4 were 78.7 and 11.5 mg/dL, respectively. She was diagnosed with SLE according to the presence of ANA and lupus anticoagulant, the recurrent oral ulcer, and thrombocytopenia. Abdominal ultrasonography showed no splenomegaly. And a bone marrow biopsy showed 50%-60% cellularity and abundant megakaryocytes, suggesting peripheral thrombocytopenia. She received intravenous dexamethasone (20 mg/day) and immunoglobulin (5 g/day) for 5 days, and then was maintained on a moderate dose of prednisolone (30 mg/day). However, 1 month later, her platelet count had decreased to 9,000/ μ L. She received pulsed intravenous methylprednisolone (1,000 mg/day) for 3 days and immunoglobulin (5 g/day) for 5 days, followed by oral prednisolone (1 mg/kg/day). However, this combination treatment showed no efficacy. She started low-dose IV CYC (500 mg/day, biweekly) on September 16 and achieved induction of remission after three cycles of CYC. After she finished six cycles of low-dose IV

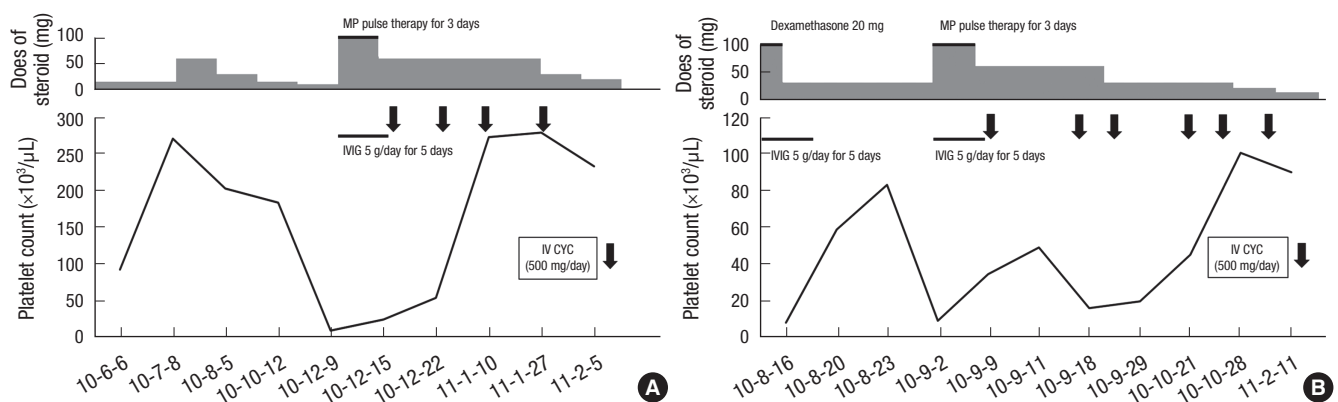


Fig. 1. Changes of platelet count in patients with multiple medical treatments. (A) In case 1, the patient recurred severe thrombocytopenia and received methylprednisolone pulse therapy for 3 days and intravenous immunoglobulin (IVIG) for 5 days. She did not respond to these medications and started low-dose intravenous cyclophosphamide (IV CYC) therapy. She achieved remission of thrombocytopenia after the first IV CYC therapy, and a stable platelet count was maintained. (B) In case 2, the platelet count of the patient was decreased below 10,000/ μ L and received methylprednisolone pulse therapy and IVIG. However, this combination treatment showed no efficacy. The platelet count was increased above 50,000/ μ L after three cycles of IV CYC, and it remained at a stable level. Doses of steroids are presented according to the potency of prednisolone. MP pulse therapy, intravenous methylprednisolone pulse therapy (1,000 mg/day for 3 days); IVIG, intravenous immunoglobulin; IV CYC, intravenous infusion of low-dose cyclophosphamide.

CYC therapy in the outpatient clinic, started AZA (50 mg/day) with reducing the dose of prednisolone to 15 mg/day. However, she switched from AZA to MMF (500 mg/day) because her platelet count was decreased to 41,000/ μ L when she was maintained on AZA. After maintenance on MMF, she showed a stable platelet count without relapse into thrombocytopenia or complications due to the medication after 24 months (Fig. 1B).

DISCUSSION

Thrombocytopenia occurs in 7%-30% of SLE patients; about 25%-50% of these cases show mild thrombocytopenia (platelets, 100,000-150,000/ μ L), and about 10% are severe thrombocytopenia (platelets, < 50,000/ μ L) (2, 3). Thrombocytopenia is often mild in SLE and usually requires no specific drug therapy (6). When thrombocytopenia is moderate to severe, corticosteroids such as prednisolone (1 mg/kg/day) or pulsed methylprednisolone therapy (1,000 mg/day for 3 days) are the initial management choice for inducing remission (1). When the disease does not respond, or when intolerably high doses of corticosteroids are required, intravenous immunoglobulin, danazol, and immunosuppressive agents can be complementary treatments. If medical treatment of thrombocytopenia with prednisolone or other medications is unsuccessful, a splenectomy should be considered. However, the role of splenectomy in the management of severe thrombocytopenia in SLE remains controversial (9-11). Thus, medical therapies such as immunosuppressants and IVIG are recommended as the first choice for lupus thrombocytopenia refractory to corticosteroids. Among immunosuppressants, AZA is traditionally considered a steroid-sparing agent for the treatment of thrombocytopenia in SLE. Cyclosporine A, MMF, and CYC can be used as alternative immunosuppressants for refractory thrombocytopenia (3, 7, 8). Especially in the treatment of severe cytopenias and aplastic anemia in SLE, more cytotoxic treatments such as CYC are often needed (1).

CYC was initially used for lupus nephritis class III and IV, and was not commonly used for isolated thrombocytopenia in SLE. In previous studies, Reiner et al. (4) showed that IV CYC therapy was effective in 20 patients with refractory autoimmune thrombocytopenic purpura. Boumpas et al. (2) investigated the effects of monthly high-dose IV CYC therapy (750-1,000 mg/m² body surface area, similar to the National Institutes of Health protocol for lupus nephritis) in patients with autoimmune thrombocytopenia. They demonstrated that all patients arrived at normal platelet counts within one to four cycles of IV CYC therapy.

The Euro-Lupus Nephritis Trial recently showed that a remission-inducing regimen of low-dose IV CYC (500 mg fixed dose, biweekly for 3 months) followed by AZA or MMF achieved clinical results comparable to those with high-dose IV CYC therapy in lupus nephritis, and had fewer side effects (5, 12). Random-

ized studies showed that both MMF and AZA were effective as maintenance therapies (13). Thus, low-dose IV CYC followed AZA or MMF therapy is commonly used to induce remission of nephritis in SLE. However, few reports on the resolution of refractory thrombocytopenia in SLE after low-dose IV CYC therapy have been published to date (7).

We investigated the efficacy of low-dose IV CYC therapy (500 mg/day, biweekly for 3 months) in two patients with severe thrombocytopenia (platelets, < 20,000/ μ L) in SLE and who failed to respond to high dose steroid and pulsed methylprednisolone therapy. Both patients recovered from thrombocytopenia, with counts above 100,000/ μ L, without a splenectomy and did not experience any side effects of CYC. In case 1, the patient received AZA as a maintenance therapy, and 7 months later, the dose of prednisolone was reduced to 10 mg/day. In case 2, the patient was maintained on MMF because AZA was not effective in maintaining the platelet counts, and the dose of prednisolone was reduced to 10 mg/day 6 months later. Subsequently in both patients, the platelet count remained stable for longer than 1 yr.

In conclusion, we experienced two patients with SLE who achieved remission of thrombocytopenia with low-dose IV CYC, with no complication or splenectomy. Here, we suggest that low-dose IV CYC followed by AZA or MMF therapy can be an effective treatment for inducing remission of severe thrombocytopenia refractory to corticosteroids in SLE.

ACKNOWLEDGMENTS

All authors declare no conflict of interest with regard to this work.

REFERENCES

- Hepburn AL, Narat S, Mason JC. *The management of peripheral blood cytopenias in systemic lupus erythematosus. Rheumatology (Oxford) 2010; 49: 2243-54.*
- Boumpas DT, Barez S, Klippel JH, Balow JE. *Intermittent cyclophosphamide for the treatment of autoimmune thrombocytopenia in systemic lupus erythematosus. Ann Intern Med 1990; 112: 674-7.*
- Arnal C, Piette JC, Léone J, Taillan B, Hachulla E, Roudot-Thoraval F, Papo T, Schaeffer A, Bierling P, Godeau B. *Treatment of severe immune thrombocytopenia associated with systemic lupus erythematosus: 59 cases. J Rheumatol 2002; 29: 75-83.*
- Reiner A, Gernsheimer T, Slichter SJ. *Pulse cyclophosphamide therapy for refractory autoimmune thrombocytopenic purpura. Blood 1995; 85: 351-8.*
- Houssiau FA, Vasconcelos C, D'Cruz D, Sebastiani GD, de Ramon Garrido E, Danieli MG, Abramovicz D, Blockmans D, Cauli A, Direskeneli H, et al. *The 10-year follow-up data of the Euro-Lupus Nephritis Trial comparing low-dose and high-dose intravenous cyclophosphamide. Ann Rheum Dis 2010; 69: 61-4.*

6. Sultan SM, Begum S, Isenberg DA. *Prevalence, patterns of disease and outcome in patients with systemic lupus erythematosus who develop severe haematological problems. Rheumatology (Oxford) 2003; 42: 230-4.*
7. Roach BA, Hutchinson GJ. *Treatment of refractory, systemic lupus erythematosus-associated thrombocytopenia with intermittent low-dose intravenous cyclophosphamide. Arthritis Rheum 1993; 36: 682-4.*
8. Vasoo S, Thumboo J, Fong KY. *Refractory immune thrombocytopenia in systemic lupus erythematosus: response to mycophenolate mofetil. Lupus 2003; 12: 630-2.*
9. Hall S, McCormick JL Jr, Greipp PR, Michet CJ Jr, McKenna CH. *Splenectomy does not cure the thrombocytopenia of systemic lupus erythematosus. Ann Intern Med 1985; 102: 325-8.*
10. You YN, Tefferi A, Nagorney DM. *Outcome of splenectomy for thrombocytopenia associated with systemic lupus erythematosus. Ann Surg 2004; 240: 286-92.*
11. Alarcon-Segovia D. *Splenectomy has a limited role in the management of lupus with thrombocytopenia. J Rheumatol 2002; 29: 1-2.*
12. Gorman C, Bhatia A, Rahman A. *This house believes that low-dose intravenous cyclophosphamide is superior to standard high-dose regimes for treatment of lupus nephritis. Rheumatology (Oxford) 2005; 44: 398-401.*
13. Contreras G, Tozman E, Nahar N, Metz D. *Maintenance therapies for proliferative lupus nephritis: mycophenolate mofetil, azathioprine and intravenous cyclophosphamide. Lupus 2005; 14: s33-8.*