

수술 전 항암화학요법을 시행받는 유방암 환자에서 초음파유도하 클립삽입술의 타당성 연구

김수연¹ · 문희정¹ · 김민정¹
이수현² · 김은경¹

¹연세대학교 의과대학 세브란스병원
영상의학과

²연세대학교 의과대학 세브란스병원
종양내과

US-guided Clip Implantation for Tumor Localization in Breast Cancer Patients Who Undergo Neoadjuvant Chemotherapy: Feasibility Study

Soo-Yeon Kim, MD¹, Hee Jung Moon, MD, PhD¹, Min Jung Kim, MD, PhD¹,
Soo Hyun Lee, MD², Eun-Kyung Kim, MD, PhD¹

¹Department of Radiology and Research Institute of Radiological Science, Yonsei University College of Medicine, Severance Hospital, Korea

²Department of Yonsei Cancer Center, Internal Medicine, Yonsei University College of Medicine, Severance Hospital, Korea

Purpose: The purpose of our study was to investigate the feasibility of US-guided clip implantation in patients receiving neoadjuvant chemotherapy for treatment of breast cancer.

Materials and Methods: From January to May 2012, marker clips were inserted with US guidance in or adjacent to 23 tumors in 20 female patients receiving neoadjuvant chemotherapy for treatment of breast cancer at our institution. One radiologist performed a retrospective review of the identification of tumors on US, mammography, and breast MRI, and MRI artifact caused by a marker clip. Clip migration was evaluated using the clip-to-nipple distance on mammography obtained immediately after clip insertion and within one week before breast surgery. Complication associated with clip insertion was also observed.

Results: After completion of neoadjuvant chemotherapy, all tumors showed a decrease in size, and 13 of 23 (56.5%) tumors were no longer palpable and thus required preoperative localization. In addition, marker clips were the only remaining evidence of the original tumor site in three of 23 (13.0%) tumors at the time of preoperative localization. All signal voids caused by a marker clip on breast MRI were less than 1 cm, which did not have a significant effect on detection and evaluation of the extent of the breast cancer. The mean change of the clip-to-nipple distance was 2.11 mm on a craniocaudal, and 2.67 mm on a mediolateral mammogram. No complication associated with clip insertion was observed in any case.

Conclusion: US-guided clip implantation in or adjacent to a breast cancer is safe and feasible for patients with anticipation of complete or near complete response to neoadjuvant chemotherapy.

Key words : Breast cancer; Neoadjuvant chemotherapy; Clip; Ultrasonography; Breast MRI

J Korean Soc Ultrasound Med
2013;32:51-58

Received August 31, 2012; Revised
October 11, 2012; Accepted November
15, 2012.

Address for reprints :

Eun-Kyung Kim, MD, Department of
Radiology, Research Institute of
Radiological Science, Yonsei University
College of Medicine, 50 Yonsei-ro,
Seodaemun-gu, Seoul 120-752, Korea.
Tel. 82-2-2228-7400
Fax. 82-2-393-3035
E-mail: EKKIM@yuhs.ac

Introduction

Neoadjuvant chemotherapy has become the

standard of treatment for patients with locally advanced breast cancer [1]. With response to neoadjuvant chemotherapy, breast cancer may decrease in size, so that they are no longer apparent

clinically or on imaging studies before surgery. In this situation, in order to facilitate breast conservation surgery, it is important to mark the tumor bed. Marker clips are inserted in or around the tumor to ensure the original site of the tumor at the time of preoperative wire localization [2].

Since publication of the first articles describing the use of marker clips 15 years ago [2, 3], marker clips have usually been used after stereotactic biopsy to assist the subsequent localization procedure [4]. Their use has now become widespread, with several commercial options and expanding indications. As one of the indications, placement of marker clips at the tumor bed is recommended in patients who undergo neoadjuvant chemotherapy for treatment of breast cancer to ensure that the original site of the tumor is localized before surgery. However, until recently, studies of the usefulness of marker clips in this field have been limited [5–7].

Breast MRI has been widely performed, with high diagnostic performance, for evaluation of tumor response to neoadjuvant chemotherapy [8, 9]. The nonferromagnetic or weakly ferromagnetic metal used in marker clips can create MR artifact, which, if significant, could limit interpretation of tumors around the marker clips. Few studies of MR artifact caused by a marker clip have been reported [4, 10, 11]. In addition, to the best of our knowledge, no study investigating the effect of marker clips on breast MRI for evaluation of residual tumors in patients receiving neoadjuvant chemotherapy for treatment of breast cancer has been reported.

Therefore, the purpose of our study was to investigate the feasibility of US-guided clip implantation in patients receiving neoadjuvant chemotherapy for treatment of breast cancer.

Materials and Methods

Patients

From January to May 2012, marker clips were inserted with US guidance in or adjacent to 23 tumors in 20 female patients receiving neoadjuvant

chemotherapy for treatment of breast cancer at our institution. Marker implantation was performed in 17 women for one tumor, and three women for two tumors, main and satellite masses.

The diagnosis of breast cancer was established before administration of neoadjuvant chemotherapy by means of US-guided 14-gauge core biopsy for 20 tumors or vacuum assisted biopsy for three tumors. Nineteen tumors were diagnosed as invasive ductal carcinoma, one as invasive carcinoma with ductal and lobular features, one as ductal carcinoma in situ, one as invasive ductal carcinoma with apocrine and micropapillary features, and one as invasive ductal carcinoma with micropapillary features. Ten of 20 patients had multiple masses, and ten of 20 had a single mass. All had axillary lymph node metastases.

Neoadjuvant chemotherapy consisted of four cycles of Adriamycin and Cyclophosphamide alone in two patients, four cycles of Adriamycin and Cyclophosphamide followed by four cycles of taxoterein in eight patients, and four cycles of Adriamycin and Cyclophosphamide followed by four cycles of docetaxel in 10 patients.

All 20 patients with 23 tumors (median age: 51.2 years, age range: 31–84 years) underwent surgery after completion of neoadjuvant chemotherapy (partial mastectomy: n=11, modified radical mastectomy: n=9).

Marker implantation

Before initiation of chemotherapy, marker implantation was performed for one mass because it was not palpable from the initial presentation. In the remaining 22 masses, marker implantation was requested by the oncologist or the breast surgeon when the tumor became difficult to be palpable due to decreased size during the course of chemotherapy. The interval time between initiation of chemotherapy and marker implantation ranged from seven to 14 weeks (mean: 12 weeks).

Insertion of markers was performed by the same radiologist who performed the US examination. Informed consent was obtained from each of the

Table 1. Identification of Tumors with US, Mammography, and Palpation

Technique	At Initial Presentation	At Marker Insertion	At Pre-operation
US	100.0% (23 of 23)	100.0% (23 of 23)	87.0% (20 of 23)
Mammography	100.0% (23 of 23)	91.3% (21 of 23)	78.3% (18 of 23)
Palpation	95.7% (22 of 23)	60.9% (14 of 23)	43.5% (10 of 23)

patients before marker implantation. After routine preparation with povidone iodine, local anesthesia was administered by instilling lidocaine along the planned needle tract. A 14-gauge guide needle was inserted with the tip of the needle within or adjacent to the lesion under US guidance. A titanium clip embedded in a bioresorbable purified collagen plug (CorMARK™, Ethicon Endo-surgery) for eight masses or a titanium clip (Horizon ligating clip, Weck Closure Systems) for 15 masses was dropped into the lumen of the needle and pushed through the needle. Postprocedural craniocaudal (CC) and mediolateral (ML) mammograms were obtained in order to ensure proper placement of the markers.

Image analysis

One radiologist performed retrospective measurement of the longest diameter of the tumor with a marker clip on US examinations taken at the time of initial presentation, marker implantation, and pre-operation, and also reviewed mammograms taken at the same time in order to assess the identification of the tumor.

In our institution, patients who receive neoadjuvant chemotherapy for treatment of breast cancer usually undergo Breast MRI before administration of neoadjuvant chemotherapy and at the time of its completion before surgery. Breast MR imaging was performed, using a 3T scanner (Trio Tim; Siemens Medial Solutions, Erlangen, Germany) with a dedicated bilateral breast coil with the patient in the prone position with an IV access in place. The dynamic contrast enhanced-MRI sequence was based on a 2D gradient DCE axial (repetition time/echo time, 280/2.6 ms; flip angle, 65°; bandwidth, 540 Hz/pixel; slice thickness, 3 mm; FOV, 340 × 340 mm; matrix size, 512 × 343; voxel size, 1.0 × 0.7 × 3.0 mm). A total

of seven dynamic frames (repetitions) were prescribed, which was acquired in 64 seconds for each frame and in seven minutes, 21 seconds in total. Gadoterate-meglumine (Gd-DOTA, Dotarem, Guerbet, Aulnay-sous-Bois, France; 0.2 mmol/kg) was injected manually at the start of the second-frame acquisition, followed by a 10-cc saline flush.

The same radiologist reviewed the breast MRI images focusing artifacts resultant to marker clips. The first was a susceptibility artifact in the form of a signal void on all sequences. The second was inhomogenous fat suppression due to local magnetic field changes around the marker clip on fat-suppressed sequences. The radiologist also assessed whether those artifacts may have a negative effect on detection and evaluation of the extent of the breast tumor around the marker.

Clip migration was evaluated using the clip-to-nipple distance on mammograms, which was obtained immediately after clip implantation and within one week before breast surgery. The clip-to-nipple distance (defined as the distance from the clip to the nipple) was measured on both CC and ML mammograms. Then the change of distance was evaluated between the two mammograms, obtained immediately after clip implantation and within one week before breast surgery.

Results

Table 1 shows identification of tumors using US, mammography, and palpation at initial presentation, marker insertion, and pre-operation.

At initial presentation, all masses were palpable, except one mass, and all were identified on US and mammography. The longest diameter of the masses was measured from 0.8 to 4.4 cm (mean ± SD, 2.51 ±

1.05 cm) on US.

At the time of marker implantation, all masses had decreased, but were still observed on US, and

measured from 0.4 to 3.5 cm (mean \pm SD, 1.61 \pm 0.95 cm). Only 60.87% (14 of 23) were palpable and two masses were not identified on mammography due to

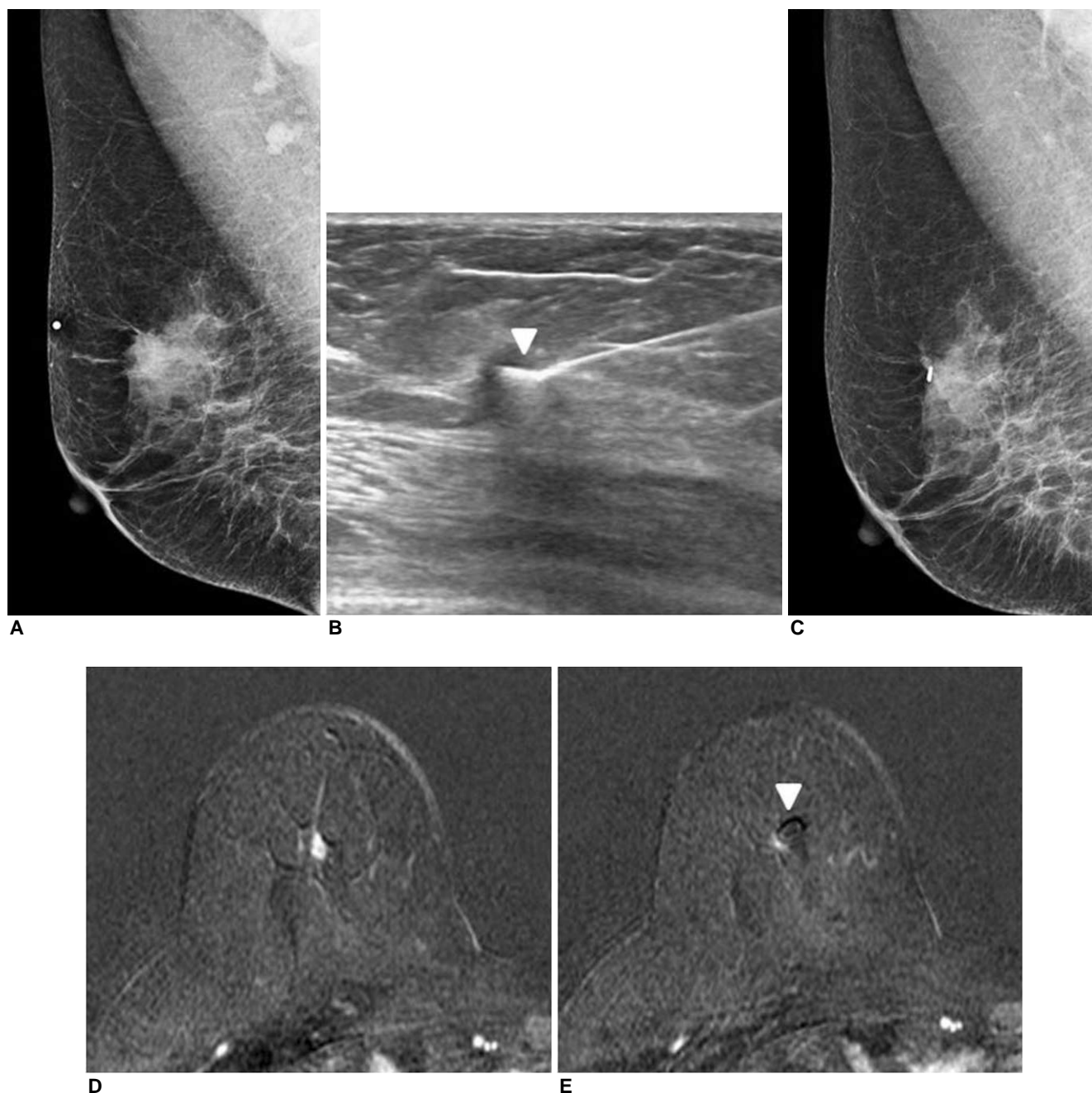


Fig. 1. A 58-year-old female patient with a palpable right breast cancer that responded to neoadjuvant chemotherapy. Initial mediolateral oblique mammogram (A) shows approximately 2.5 cm focal asymmetry with internal microcalcifications corresponding to a palpable lesion, and multiple enlarged axillary lymph nodes. Ultrasonography (B) obtained during marker implantation shows a marker clip (Horizon ligating clip, arrowhead) that has been deposited at the tip of a 14-gauge needle at the periphery of the 1 cm irregular shaped hypoechoic mass that responded to four cycles of neoadjuvant chemotherapy. Mediolateral oblique mammogram after clip insertion (C) confirms the location of the implanted marker clip at the periphery of the residual tumor. Axial contrast-enhanced subtracted MR image of the right breast at completion of neoadjuvant chemotherapy shows a 0.7 cm enhancing residual mass (D) and a marker clip (E, arrowhead) at the periphery of the mass.

decreased size and density.

At the time of preoperative examination, all masses were further decreased, and measured from 0 to 3.4 cm (mean \pm SD, 1.16 ± 0.87 cm) on US. Thirteen of the 23 masses were no longer palpable, and, thus, preoperative localizations were required (Fig. 1). Among them, 10 masses underwent preoperative localization by means of mammography ($n=2$) or US ($n=8$). Localization was not necessary for three masses, because the patients were scheduled to undergo non-breast preserving surgery due to multicentricity of the tumors.

Overall, three of 23 tumors (13.0%) were not identified on US or by mammography and palpation at preoperative examination. However, the original tumor site was identified due to the previously inserted marker clip, and, thus, preoperative localizations were possible for them. In other words, the metallic markers were the only remaining evidence of the original tumor site in 13.0% of tumors at the time of preoperative localization.

The interval between marker implantation and surgery ranged from four to 18 weeks (mean: 13 weeks). Pathologic evaluation of the three masses with complete regression on US confirmed the absence of a residual tumor in two and the presence of residual ductal carcinoma in situ of 0.2 cm in one. Among 11 masses with a diameter of 1.0 cm or less on US, pathologic evaluation revealed one no residual carcinoma, two ductal carcinoma in situ, two invasive and in situ carcinoma, and six invasive ductal carcinoma. Among nine masses with diameters of 1.0 cm or greater on US, results of pathologic evaluation revealed one ductal carcinoma in situ, five invasive ductal carcinomas, two invasive apocrine carcinomas, and one invasive micropapillary carcinoma.

Among 20 patients who underwent surgery, 22 masses in 19 patients had breast MRI after insertion of a marker clip. All clips showed a signal void artifact in order to make them identifiable on breast MRI. Signal voids caused by CorMARK ($n=7$) ranged from 7.5 to 9 mm (mean: 8.3 mm), and those by a Horizon ligating clip ($n=15$) ranged from 6.7 to 9.3

mm (mean: 7.5 mm). Overall, all signal voids were less than 1 cm, which did not significantly affect detection and evaluation of the extent of the breast cancer even in the 11 residual tumors with a diameter of 1.0 cm or less on US. Neither clinically appreciable inhomogenous fat suppression nor other additional artifacts caused by the marker clips was observed.

The clip-to-nipple distance was evaluated in all 23 masses with surgery. The mean change of the clip-to-nipple distance between two mammograms obtained at the time of clip implantation and pre-operation was 2.11 mm (range: 0–5 mm) on CC, and 2.67 mm (0–10 mm) on ML mammogram.

None of the cases showed marker migration and no clinical complications associated with marker insertion, such as hemorrhage, infection, or major pain, was observed at the time of marker insertion and on follow up.

Discussion

Neoadjuvant chemotherapy allows for performance of breast conservation surgery by reducing tumor volume [12]. With the success of neoadjuvant chemotherapy, preoperative localization of the tumor bed can be problematic when complete or near complete tumor regression is achieved with no residual clinical or radiological abnormality. Implantation of the marker clip within or around the breast cancer is useful for preoperative localization in patients with response to neoadjuvant chemotherapy to ensure that the original site of the cancer is localized [5–7].

Dash et al. reported that without the marker clip, preoperative wire localization would have been impossible in 35.7% (10 of 28) of patients because remaining tumors were not visualized on mammography [5]. Similarly, Edeiken et al. reported that the original tumor could not be palpated or visualized on either US or mammography after completion of neoadjuvant chemotherapy in 46.9% (23 of 49) of patients, for whom metallic markers

were the only remaining evidence of the original tumor site [6]. The current study also proves that US-guided implantation of marker clips in or adjacent to a breast cancer is feasible in patients with response to neoadjuvant chemotherapy. All 23 tumors showed a decrease in size after completion of neoadjuvant chemotherapy, and 13 of 23 (56.5%) tumors were no longer palpable, and, thus, required preoperative localization. In addition, three of 23 (13.0%) tumors were not visualized on either US or mammography at the time of preoperative localization, thus, marker clips were the only remaining evidence of the original tumor site in 13.0% of tumors at the time of preoperative localization. However, in the current study, the proportion of patients with marker clips as the only remaining evidence of the original tumor site at the time of pre-operation (namely, patients who achieved complete tumor regression without palpability and radiologic abnormality) was lower than that reported in the two studies described above [5, 6]. The reasons are thought to be as follows. Dash et al. [5] did not evaluate US examination for assessment of the identification of remaining tumors at the time of pre-operation. They evaluated the identification of remaining tumors only on mammography. Also, in the study reported by Edeiken et al. [6], US examination was not performed in seven of 49 tumors, and mammography was not performed before surgery in 39 of 49 tumors. Therefore, in the previous two studies [5, 6], residual tumors that were not visualized on one imaging modality (either US or mammo-graphy) might be visualized on another imaging modality (either US or mammography), then the proportion of patients with marker clips as the only remaining evidence of the original tumor site might be lower than reported in the two studies. In addition, the type and method of neoadjuvant chemotherapy, and the baseline characteristics, including age, race, receptor status, and clinical stage of the tumors were heterogenous, so that the proportion of patients who achieved complete tumor regression after neoadjuvant chemotherapy differed among the three studies.

Metallic clips can create signal voids formed by susceptibility artifact or inhomogenous fat saturation due to local magnetic field changes on MRI, which could limit assessment of the extent of breast cancer [13], however, most are so minor as to be problematic in clinical practice [4, 10, 11]. In the current study, all marker clips showed signal void artifacts less than 1 cm, and they did not limit the evaluation of the extent of residual tumors in all cases, including the 11 residual tumors with a diameter of 1.0 cm or less on the preoperative US examination. Clips were not in the exact position where those 11 residual tumors were located. Clips were located near those small residual tumors, and were helpful in detecting them rather than obscuring them.

Clip migration away from the original tumor site can occur on occasion, and can lead to errors in surgical management [4]. It has been hypothesized to occur at the time of breast decompression along the track of needle insertion because the clip is not anchored to the wall of the biopsy cavity [2, 14]. In compiling data from nine studies, 71.3% of cases exhibited clip displacement less than 1 cm after vacuum-assisted stereotactic biopsy [4], and there was no case of migration after US-guided implantation of metallic markers [6]. Similarly, there was no migration in our cases with US-guided clip implantation showing less than 3 mm of the mean change of the clip-to-nipple distance between two mammograms obtained immediately after clip implantation and before surgery.

There are several limitations in the current study. First, because this was a retrospective study and the authors were aware of the purpose of the study, reviewer bias might have occurred. Second, a small number of patients were enrolled in the study. The current study was a feasible study on US-guided clip implantation for breast cancer patients who undergo neoadjuvant chemotherapy, and US-guided clip implantation is now being performed routinely for these patients with anticipation of response to neoadjuvant chemotherapy at our institution. Third, regarding MRI artifact caused by the clip, we did not

evaluate the MR spectroscopic artifact caused by the marker. Several studies have reported that local signal disturbance caused by a metallic marker can disrupt the spectroscopic data [10, 11]. Further study regarding MR spectroscopic artifact caused by a marker clip is needed.

In conclusion, marker clips were the only remaining evidence of the original tumor site for 13.0% of tumors with radiologically complete regression at the time of preoperative localization. They did not create clinically considerable artifacts on breast MRI, and migration from the original site or complications associated with clip insertion were not observed. Therefore, US-guided clip implantation in or adjacent to a breast cancer is feasible and safe for patients with anticipation of complete or near complete response to neoadjuvant chemotherapy.

Acknowledgement: This study was supported by a grant from Guerbet Korea.

요 약

목적: 수술 전 항암화학요법을 시행 받은 유방암 환자에서 초음파유도하 클립 삽입술의 타당성에 대해서 연구하였다.

대상 및 방법: 2012년 1월부터 5월까지 본원에서 수술 전 항암 화학 요법을 시행 받은 20명 환자에서의 총 23개의 유방암에 대해 초음파유도하 클립 삽입술을 시행하였다. 한 명의 영상의학과 의사가 초음파와 유방촬영술, 유방 자기공명영상검사에서 유방암의 식별과 클립에 의해 발생한 유방 자기공명영상 인공물에 대해 후향적으로 분석하였다. 클립의 위치 이동은 클립 삽입 직후와 수술 일주일 전에 얻어진 유방촬영술에서 클립에서 유두까지의 거리를 이용하여 평가하였다. 클립 삽입과 관련한 합병증의 유무에 대해서도 조사하였다.

결과: 수술 전 항암화학요법 종료 후 모든 유방암은 크기가 감소하였고, 23개 중 13개 (56.5%)에서 더 이상 유방암이 촉진 되지 않아 수술 전 위치결정술이 필요하였다. 수술 전 위치결정술 시에 금속 클립은 23개 중 3개 (13.0%)의 유방암에서 원래 암 위치에 대한 유일한 단서였다. 유방 자기공명영상검사에서 모든 금속 클립은 1 cm 미만의 신호 소실을 보였고, 이는 잔류 유방암의 발견과 평가에 의미

있는 영향을 미치지 않았다. 클립에서 유두까지 거리 변화값의 평균은 상하 영상에서 2.11 mm 였고, 내외 영상에서는 2.67 mm 였다. 모든 경우에서 클립 삽입과 관련한 합병증은 없었다.

결론: 수술 전 항암화학요법으로 종양 소실이 예상되는 유방암 환자에서 초음파유도하 클립 삽입술은 타당하고 안전하게 시행할 수 있는 방법이다.

References

1. Kaufmann M, Hortobagyi GN, Goldhirsch A, et al. Recommendations from an international expert panel on the use of neoadjuvant (primary) systemic treatment of operable breast cancer: an update. *J Clin Oncol* 2006;24:1940-1949
2. Burbank F, Forcier N. Tissue marking clip for stereotactic breast biopsy: initial placement accuracy, long-term stability, and usefulness as a guide for wire localization. *Radiology* 1997;205:407-415
3. Liberman L, Dershaw DD, Morris EA, Abramson AF, Thornton CM, Rosen PP. Clip placement after stereotactic vacuum-assisted breast biopsy. *Radiology* 1997;205:417-422
4. Thomassin-Naggara I, Lalonde L, David J, Darai E, Uzan S, Trop I. A plea for the biopsy marker: how, why and why not clipping after breast biopsy? *Breast Cancer Res Treat* 2012;132:881-893
5. Dash N, Chafin SH, Johnson RR, Contractor FM. Usefulness of tissue marker clips in patients undergoing neoadjuvant chemotherapy for breast cancer. *AJR Am J Roentgenol* 1999;173:911-917
6. Edeiken BS, Fornage BD, Bedi DG, et al. US-guided implantation of metallic markers for permanent localization of the tumor bed in patients with breast cancer who undergo preoperative chemotherapy. *Radiology* 1999;213:895-900
7. Baron LF, Baron PL, Ackerman SJ, Durden DD, Pope TL, Jr. Sonographically guided clip placement facilitates localization of breast cancer after neoadjuvant chemotherapy. *AJR Am J Roentgenol* 2000;174:539-540
8. Abraham DC, Jones RC, Jones SE, et al. Evaluation of neoadjuvant chemotherapeutic response of locally advanced breast cancer by magnetic resonance imaging. *Cancer* 1996;78:91-100
9. Yeh E, Slanetz P, Kopans DB, et al. Prospective comparison of mammography, sonography, and MRI in patients undergoing neoadjuvant chemotherapy for palpable breast cancer. *AJR Am J Roentgenol* 2005;184:868-877
10. Genson CC, Blane CE, Helvie MA, Waits SA, Chenevert TL. Effects on breast MRI of artifacts caused by metallic tissue marker clips. *AJR Am J Roentgenol* 2007;188:372-376

11. Ghate SV, Baker JA, Hawkins AD, Soher BJ. Titanium vs carbon coated ceramic breast tissue marker clips: 3T MR susceptibility artifact and local signal disturbance. *Acad Radiol* 2011;18:770-773
12. Colleoni M, Nole F, Minchella I, et al. Pre-operative chemotherapy and radiotherapy in breast cancer. *Eur J Cancer* 1998;34:641-645
13. Ojeda-Fournier H, Choe KA, Mahoney MC. Recognizing and interpreting artifacts and pitfalls in MR imaging of the breast. *Radiographics* 2007;27(Suppl 1):S147-164
14. Esserman LE, Cura MA, DaCosta D. Recognizing pitfalls in early and late migration of clip markers after imaging-guided directional vacuum-assisted biopsy. *Radiographics* 2004;24:147-156