

Easily Removable Ureteral Catheters for Internal Drainage in Children: A Preliminary Report

Kyung Kgi Park,¹ Myung Up Kim,² Mun Su Chung,³ Dong Hoon Lee,² and Chang Hee Hong²

¹Department of Urology, Jeju National University College of Medicine, Jeju;

²Department of Urology, Gangnam Severance Hospital, Yonsei University College of Medicine, Seoul;

³Department of Urology, Uijeongbu St. Mary's Hospital, The Catholic University of Korea College of Medicine, Uijeongbu, Korea.

Received: January 31, 2012

Revised: April 23, 2012

Accepted: April 24, 2012

Corresponding author: Dr. Chang Hee Hong,

Department of Urology,
Gangnam Severance Hospital,
Yonsei University College of Medicine,
211 Eonju-ro, Gangnam-gu,
Seoul 135-720, Korea.

Tel: 82-2-2019-3473, Fax: 82-2-3462-8887

E-mail: chhong52@yuhs.ac

The authors have no financial conflicts of interest.

Purpose: We review our experience using a new and easily removable ureteral catheter in patients who underwent complicated ureteral reimplantation. Our goal was to shorten hospital stay and lower anxiety during catheter removal without fear of postoperative ureteral obstruction. **Materials and Methods:** Between April 2009 and September 2010, nine patients who underwent our new method of catheter removal after ureteral reimplantation were enrolled. Patients who underwent simple ureteral reimplantation were excluded from the study. Following ureteral reimplantation, a combined drainage system consisting of a suprapubic cystostomy catheter and a ureteral catheter was installed. Proximal external tubing was clamped with a Hem-o-lok clamp and the rest of the external tubing was eliminated. Data concerning the age and sex of each patient, reason for operation, method of ureteral reimplantation, and postoperative parameters such as length of hospital stay and complications were recorded. **Results:** Of the nine patients, four had refluxing megaureter, four had a solitary or non-functional contralateral kidney and one had ureteral stricture due to a previous anti-reflux operation. The catheter was removed at postoperative week one. The mean postoperative hospital stay was 2.4 days (range 1-4 days), and the mean follow-up was 9.8 months. None of the patients had postoperative ureteral obstructions, and there were no cases of migration or dislodgement of the catheter. **Conclusion:** Our new method for removing the ureteral catheter would shorten hospital stays and lower levels of anxiety when removing ureteral catheters in patients with a high risk of postoperative ureteral obstruction.

Key Words: Ureteral reimplantation, ureteral catheter, cystostomy catheter, pediatrics

INTRODUCTION

© Copyright:

Yonsei University College of Medicine 2013

This is an Open Access article distributed under the terms of the Creative Commons Attribution Non-Commercial License (<http://creativecommons.org/licenses/by-nc/3.0>) which permits unrestricted non-commercial use, distribution, and reproduction in any medium, provided the original work is properly cited.

In the field of pediatric urology, there continues to be debate over whether to use a ureteral catheter for ureteral reimplantation in children with vesicoureteral reflux (VUR). For uncomplicated cases, “stentless” ureteral reimplantation is the accepted method, according to the literature.^{1,2} However, we believe that indwelling ureteral catheters should be used in children who have undergone ureteral reimplanta-

tion with ureteral tailoring or have only a single healthy kidney. Placing a drainage system across the ureterovesical system is a safe and reliable method for complicated cases in which ureteral obstruction may result from postoperative edema. However, establishing which postoperative drainage system is the most appropriate and least troublesome to use has always been controversial; as there are advantages and disadvantages to each of the various drainage systems.

Therefore, we have designed a new drainage system that is easy to remove, minimizes patient discomfort, shortens hospital stay, and eliminates the need for additional sedation for removing the catheter. Herein, we describe our initial experience using this new catheter and discuss its potential advantages and limitations.

MATERIALS AND METHODS

Patients

Retrospective review of nine patients who underwent our new catheter procedure after ureteral reimplantation was performed. Between April 2009 and September 2010, nine patients (mean age 5.2 years, range 9 months-12 years) with complicated VUR were recruited from a single tertiary urological center. All enrolled patients had a VUR with contralateral nonfunctioning or solitary kidney or underwent ureteral tapering due to refluxing megaureter or ureteral stricture due to prior ureteral surgery. Data concerning the age and sex of each patient and postoperative parameters such as operation method, length of hospital stay, and complications were recorded.

The catheter method used for the bladder after ureteral reimplantation was selected by the surgeon, and general endotracheal anesthesia was used on all patients. Open intravesical ureteroneocystostomy was performed through a Pfannenstiel incision using the Cohen technique as well as transvesicoscopic ureteral reimplantation, as described in a previous study,³ and ureteral tapering using the Starr plication technique. After ureteral reimplantation, our newly designed ureteral catheter was inserted.

The urethral catheter was kept in place until postoperative hematuria disappeared. Patients were discharged when they could ambulate, tolerate oral liquids, produce adequate urine output, and control their pain with oral analgesics. The ureteral catheter and cystostomy were removed on postoperative day seven at an outpatient office. Abdominal ultrasounds were performed on all patients one month postoper-

atively. If hydronephrosis was present at the one-month postoperative examination, ultrasound was repeated three months postoperatively.

Newly designed ureteral catheter

We designed a new drainage system without externalized tubing in order to prevent longer hospital stays and the need for general anesthetic during cystoscopic catheter removal. Our new method utilizes both a suprapubic cystostomy catheter and a ureteral catheter. This combined catheter consists of a ureteral catheter segment that extends from the ureter to the bladder and a suprapubic cystostomy catheter that is attached to the ureteral catheter within the bladder with a non-absorbable suture. The cystostomy catheter is closed by a Hem-o-lok clip and then cut above the clip. This catheter serves as an internal drainage system allowing the urine to flow into the bladder through the side hole of the cystostomy catheter.

Catheterization procedure after reimplantation

For transvesicoscopic ureteral reimplantation, a guide wire and a 3-Fr open-ended ureteral catheter were inserted into the reimplanted ureter through a 3 mm lateral port, and then the guide wire was removed. The ureteral catheter was cut to full-length (approximately 15 cm), the distal end of the inserted catheter was placed within the drainage tunnel of the cystostomy catheter (14-Fr nephrostomy catheter), and the ureteral catheter was fixed extracorporeally to the drainage hole of the cystostomy catheter using a nylon 4-0 suture. The suprapubic cystostomy catheter and ureteral catheter were inserted into the bladder through a 3 mm lateral port. Then the balloon of the cystostomy catheter was inflated (3 cc). After pulling the lateral port, the external tube of the cystostomy was clamped extracorporeally close to the skin using a Hem-o-lok clip. Then the pulled lateral port and distal external tube were eliminated together (Fig. 1). For open ureteral reimplantation, the procedure was similar to that used for laparoscopic ureteral reimplantation. There were differences in the procedures, however, as follows: the cystostomy catheter was inserted in the usual manner before fixing the ureteral catheter to the cystostomy drainage hole, and then the fixed ureteral catheter and cystostomy were inserted through the open surgical window of the bladder.

Catheter removal procedure

The newly designed catheter was removed at an outpatient clinic on postoperative day seven in three steps. First, the

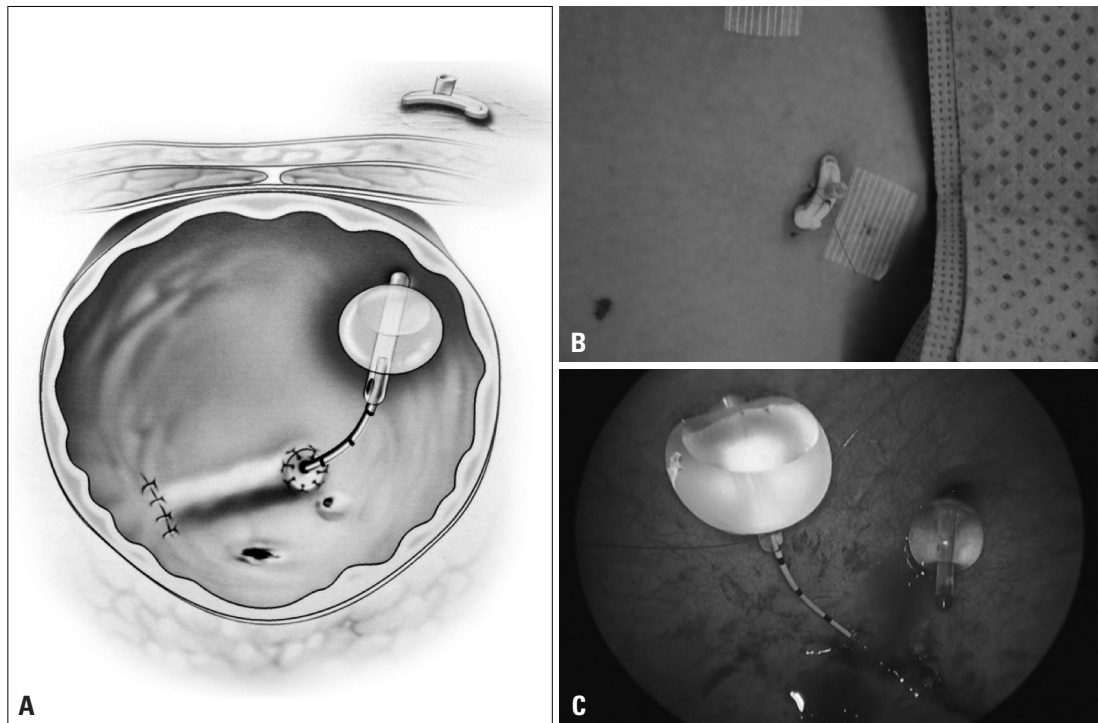


Fig. 1. (A) Schematic illustration of our new internal drainage system. (B) Hem-o-lok clamp holding the suprapubic catheter without an external drainage system. (C) The ureteral catheter and suprapubic cystostomy catheter are positioned, and the ureteral catheter is fixed to the drainage hole at the distal end of the cystostomy catheter using a nylon 4-0 suture.

cystostomy tube beneath the Hem-o-lok was clamped with a Mosquito clamp to prevent the advancement of the proximal end of the catheter inside the body. Second, the cystostomy tube just below the Hem-o-lok clamp was cut using sharp scissors. Finally, to deflate the cystostomy balloon, the Mosquito clamp was released while holding the drainage hole at the stoma portion of the cystostomy tube using another Mosquito clamp. These sequential procedures prevented advancement of the proximal end of the catheter into the bladder. The ureteral and cystostomy catheters were then pulled together.

RESULTS

Nine patients (eight boys and one girl) ranging in age from 9 months to 12 years old (average age 5.2 years) underwent ureteral reimplantation with and without ureteral tapering. Among the patients, four had refluxing megaureter, four had VUR with a solitary or non-functional contralateral kidney, and one had ureteral stricture due to previous anti-reflux surgery. The urethral catheter was removed as usual when their urine was clear. We routinely remove the cystostomy and ureteral catheters at the end of postoperative week one. The mean hospital stay was 2.4 days (range 1-4 days). Aver-

age follow-up was 9.8 months (range 5-14 months). None of the patients had postoperative ureteral obstruction. Three patients stayed in the hospital until postoperative day four due to gross hematuria. In addition, there were no cases of migration or dislodgement of the ureteral catheter (Table 1).

DISCUSSION

Our new method for ureteral catheter removal can be used in patients for ureteral reimplantation. Based on our results, there is the possibility of early discharge without requiring home care for an external catheter and drainage bag or additional anesthesia for removing the catheter. Although three patients were discharged on postoperative day four, the six other patients were discharged without postoperative hydronephrosis two days after surgery.

In the pediatric urological field, ureteral reimplantation without a catheter is the widely accepted method. Brandell and Brock¹ reviewed the cases of 34 children with reflux who underwent simple ureteroneocystostomy. In their study, ureteral catheters were used for 14 of the 34 patients. Patients who did not receive a ureteral catheter had a 30% decrease in length of hospital stay and a 50% decrease in cost compared to the patients who did receive the ureteral catheter.

Table 1. Perioperative Outcomes in Patients (n=9)

	Sex	Age (yrs)	Diagnosis	Non-functional kidney*	Approach Method of bladder	Ureteral tapering	Postoperative hospital stay (days)	Hydronephrosis after operation
1	M	2	Refluxing megaureter, Rt	None	Open	Unilateral	4	No
2	M	7	VUR, Lt/MCDK, Rt	Unilateral	Transvesicoscopic	None	4	No
3	M	2	UVJ stricture, Lt after OUR, bil	None	Transvesicoscopic	None	1	No
4	M	2	Refluxing megaureter, Rt	None	Open	Unilateral	4	No
5	M	10	VUR, Rt/solitary kidney	Unilateral	Transvesicoscopic	None	2	No
6	M	1	Refluxing megaureter, Lt	None	Transvesicoscopic	Unilateral	2	No
7	M	1	VUR, bil/atrophic kidney, Rt	None	Transvesicoscopic	None	2	No
8	M	10	VUR, Rt/solitary kidney	Unilateral	Transvesicoscopic	None	1	No
9	F	12	Refluxing megaureter, Lt	None	Transvesicoscopic	Unilateral	2	No

VUR, vesicoureteral reflux; MCDK, multicystic dysplastic kidney; UVJ, ureterovesical junction; OUR, open ureteral reimplantation; Rt, right; Lt, left; bil, bilateral.

Ureteral catheters were routinely removed at the end of postoperative week one.

*Non-functional kidney means that the relative function of the kidney was less than 5% in a dimercaptosuccinic acid scan.

ter. All patients were followed for three months. During the follow-up period, there was no evidence of persistent reflux or ureteral obstruction. Miller, et al.² also reported the results of 101 patients who underwent ureteral reimplantation without using a ureteral catheter. They argued that ureter reimplantation without a ureteral catheter shortens hospital stay and reduces major complications. Although their results confirm this conclusion, their study excluded patients who underwent complicated ureteral surgery such as ureteral tapering. Therefore, we still believe that a ureteral catheter is necessary for ureteral reimplantation in patients with complications in order to overcome postoperative ureteral obstruction. Although using a ureteral stent has the advantage of not requiring external tubing, additional sedation is necessary for removing the stent in pediatric patients. In order to easily remove the ureteral stent, some physicians use a stent composed of string and place it outside the urethra. This method does not lead to good morbidity. In addition, many patients treated by this method complain of moderate to intolerable discomfort and a few patients even experience premature migration or dislodgment of the ureteral catheter.⁴ Therefore, we believe the ureteral stent method is not suitable for children. For open-ended ureteral catheters, the catheter directly penetrates the bladder and suprapubic abdominal wall and is externally located with a drainage bag. The catheter is easy to remove and does not require any additional sedation for removal; however, care of the external catheter is needed to avoid inappropriate migration or dislodgement.

Barbour, et al.⁵ reported results for an easy to remove catheter system in complicated ureteral reimplantation cas-

es that involved using a combined drainage system consisting of cystostomy and a double J stent. In their study, patients were discharged early and their ureteral stents were easily removed. On postoperative day five, the cystostomy combined with a ureteral stent and a non-absorbable suture were removed without anesthesia. However, their method requires caring for the external drainage tube and the average length of hospital stay was similar to other methods. More recently, the Salle intraoperative pyeloplasty stent was introduced.⁶ The Salle stent can be placed such that the external portion is passed out suprapubically, which also can obviate the need for a Foley catheter and external tubing structure, so that it can be easily removed after a few days. However, occasionally for younger patients, the Salle stent cannot be used because Salle stents less than 4-Fr are not produced. In addition, the stent is not distributed worldwide like the Foley catheter and ureteral catheter.

To lower anxiety when removing the ureteral catheter and eliminate unnecessary external tubing and a drainage bag, we modified the post ureteral reimplantation procedure using a ureteral catheter and a suprapubic cystostomy catheter. After ureteral reimplantation, a combined internal drainage system consisting of the suprapubic cystostomy and ureteral catheter was installed without external tubing structures. Our new catheter method has several advantages. First, it requires no external catheter or drainage bag, which is difficult to handle at home and is at risk of becoming dislodged. As patients are generally unfamiliar with how to care for external catheters and drainage bags, they usually request to remain in the hospital while the catheter is in place, despite the disadvantages of longer hospital stays. Second, addi-

tional sedation was not necessary to remove the ureteral catheter. For most pediatric patients, general anesthesia is needed to remove the ureteral catheter because any unconscious movement or anxiety experienced during the cystoscopic procedure may induce hazardous complications, but our method did not require additional anesthesia. Third, our method has a low risk of postoperative ureteral obstruction. For patients with normal kidneys, unilateral ureteral obstruction might not be hazardous. However, patients with a solitary functional kidney are at risk of postoperative ureteral obstruction which can lead to post-obstructive azotemia. In addition, with our method, patients who have undergone complicated ureteral manipulation such as ureteral tapering can be discharged without fear of ureteral obstruction. Therefore, in cases such as our enrolled patients, a ureteral catheter should be inserted. Fourth, patients are able to be discharged from the hospital immediately if no postoperative complications are present which require the care of a physician (for example: gross hematuria, infection, or bladder leakage). These types of complications can affect the length of hospital stay. Our patients had a mean hospital stay of 2.4 days. The average hospital stay in patients undergoing ureteral reimplantation is reported to be 2.8 to 5.6 days.^{7,8} Shorter hospital stays for pediatric patients would decrease the incidence of hospital acquired infection, cost, and parental anxiety.⁹⁻¹² We believe that when the new internal drainage system is used after ureteral reimplantation, care of the catheter and fear of transient ureteral obstruction will not be reasons for prolonged hospitalization. However, there are also some disadvantages in our methods. First, a complicated procedure should be learned and special care is necessary in critical steps such as removing the catheter. If a more simple nephroureterovesical stent set is introduced, our complicated steps can be made simple. Second, there are possibility of unwanted events such as disconnection between cystostomy catheter and ureteral catheter in the bladder or migration of the cystostomy catheter inside the body. None of these events occurred during our initial experience, however, we had a small sample size. Therefore, the incidence of possible complications should be discussed to verify the effectiveness and safety.

Our study had some limitations. First, the number of enrolled subjects was small. Therefore, the explanatory power of our results is compromised. Our results explain only the

possibility of a new method but do not suggest superiority. Therefore, effectiveness of our method should be analyzed using larger scale comparative studies in a future. Second, the internal drainage system has less drainage ability, due to closing of the luminal area, than other systems with the lumen open. In conclusion, our new method can possibly be used for preventing postoperative ureteral obstruction in patients with a solitary functional kidney or who have undergone a complicated ureteral manipulation procedure without necessitating delayed discharge from the hospital and additional sedation to remove the indwelling ureteral catheter.

REFERENCES

1. Brandell RA, Brock JW 3rd. Ureteral reimplantation: postoperative management without catheters. *Urology* 1993;42:705-7.
2. Miller OF, Bloom TL, Smith LJ, McAleer IM, Kaplan GW, Kolon TF. Early hospital discharge for intravesical ureteroneocystostomy. *J Urol* 2002;167:2556-9.
3. Hong CH, Kim JH, Jung HJ, Im YJ, Han SW. Single-surgeon experience with transvesicoscopic ureteral reimplantation in children with vesicoureteral reflux. *Urology* 2011;77:1465-9.
4. Bregg K, Riehle RA Jr. Morbidity associated with indwelling internal ureteral stents after shock wave lithotripsy. *J Urol* 1989;141:510-2.
5. Barbour KW, Arunachalam P, King PA, McAndrew HF. The use of ureteral stents and suprapubic catheter in vesicoureteric reflux surgery. *Pediatr Surg Int* 2004;20:387-8.
6. Taveres A, Manaboriboon N, Lorenzo AJ, Farhat WA. Insertion of an internal-external nephroureteral stent during pediatric laparoscopic pyeloplasty: description of the technique. *Urology* 2008;71:1199-202.
7. Kennelly MJ, Bloom DA, Ritchey ML, Panzl AC. Outcome analysis of bilateral Cohen cross-trigonal ureteroneocystostomy. *Urology* 1995;46:393-5.
8. Flickinger JE, Trusler L, Brock JW 3rd. Clinical care pathway for the management of ureteroneocystostomy in the pediatric urology population. *J Urol* 1997;158(3 Pt 2):1221-5.
9. Jarvis WR. Controlling healthcare-associated infections: the role of infection control and antimicrobial use practices. *Semin Pediatr Infect Dis* 2004;15:30-40.
10. Festini F, Cocchi P, Mambretti D, Tagliabue B, Carotti M, Ciofi D, et al. Nosocomial Rotavirus Gastroenteritis in pediatric patients: a multi-center prospective cohort study. *BMC Infect Dis* 2010;10:235.
11. Zhang Q, Xu X, Langley JM, Zhu B, Zhang N, Tang Y. Health-associated infections in a pediatric nephrology unit in China. *Am J Infect Control* 2010;38:473-5.
12. Spencer JD, Schwaderer A, McHugh K, Hains DS. Pediatric urinary tract infections: an analysis of hospitalizations, charges, and costs in the USA. *Pediatr Nephrol* 2010;25:2469-75.