



REVIEW ARTICLE

Oral manifestations of thrombocytopaenia



R.A.G. Khammissa^a, J. Fourie^a, A. Masilana^a, S. Lawrence^b, J. Lemmer^a,
L. Feller^{a,*}

^a Department of Periodontology and Oral Medicine, Sefako Makgatho Health Sciences University, Pretoria, South Africa

^b Department of Periodontology and Oral Medicine, University of the Western Cape, Cape Town, South Africa

Received 15 December 2015; accepted 23 August 2017

Available online 23 September 2017

KEYWORDS

Ecchymosis;
Petechiae;
Haemorrhagic blister;
Immune mediated
thrombocytopaenia

Abstract The appearance in the mouth of haemorrhagic petechiae, ecchymoses or blood blisters with spontaneous bleeding is suggestive of a haemorrhagic disorder that may be caused either by functional impairment of platelets or of blood vessel walls, by an abnormal decrease in the number of circulating platelets (thrombocytopaenia), or by defects in the blood clotting mechanism. Thrombocytopaenia from decreased production or increased destruction of platelets may be caused by multiple factors including immune mediated mechanisms, drugs or infections.

A diagnosis of thrombocytopaenic purpura can be made when any other disease entity that might be causing the purpura is excluded on the basis of the medical history, the physical examination, a complete blood count and a peripheral blood smear.

In this paper, we outline the clinical features of oral thrombocytopaenic purpura and briefly discuss some aspects of its aetiopathogenesis and treatment.

© 2017 The Authors. Production and hosting by Elsevier B.V. on behalf of King Saud University. This is an open access article under the CC BY-NC-ND license (<http://creativecommons.org/licenses/by-nc-nd/4.0/>).

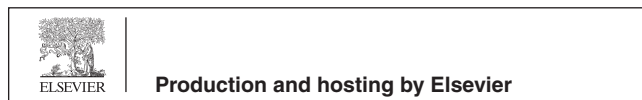Contents

1. Introduction	20
2. Thrombocytopaenia.	21
3. Causes of thrombocytopaenia.	21
4. Diagnosis, evaluation and management of a patient with thrombocytopaenia	24
5. Thrombocytopaenia in relation to HIV infection	24
Conflict of interest.	24

* Corresponding author at: Dept. Periodontology and Oral Medicine, Box D26 School of Dentistry, Sefako Makgatho Health Sciences University, Medunsa 0204, South Africa.

E-mail address: liviufeller@smu.ac.za (L. Feller).

Peer review under responsibility of King Saud University.



Funding	24
Competing interest	24
Ethical approval	24
Acknowledgments	24
References	24

1. Introduction

Thrombocytopaenic purpura is a haemorrhagic disorder characterized by an abnormal reduction in the number of circulating platelets with the extravasation of blood from small blood vessels, affecting particularly the mucous membranes of the aerodigestive and the genitourinary tracks, and the skin (Rajendran and Nooh, 2012; Parke et al., 2013, McCarthy and Shklar, 1964; Aster, 2005; Rodeghiero et al., 2013). Melena, haematuria, epistaxis, gingival bleeding or excessive menstrual flow may be the first signs of the disease (Aster, 2005); intracranial bleeding caused by thrombocytopaenia is a life-threatening condition (Aster, 2005).

According to the severity, oral thrombocytopaenic purpura manifests as small single or multiple petechial haemorrhages,

as ecchymosis, as haemorrhagic blisters or as spontaneous bleeding (Figs. 1–4) (McCarthy and Shklar, 1964). In the mouth, the thrombocytopaenic lesions are usually on the soft tissues most susceptible to trauma, such as the buccal mucosa from cheek biting, the junction between the hard and soft palate in denture wearing subjects or the gingiva (Regezi and Sciubba, 1989). The extravasated blood is gradually resorbed over a period of a few days, but in larger lesions resolution will take longer, and in the case of haemorrhagic blisters the overlying epithelium may slough and the resulting erosion may become secondarily infected (McCarthy and Shklar, 1964).

Oral haemorrhagic purpura can be brought about not only by diminution in the number of circulating platelets but also by impairment of their functional activity, by defects in blood clotting or by abnormalities of blood vessel walls. Exclusion of

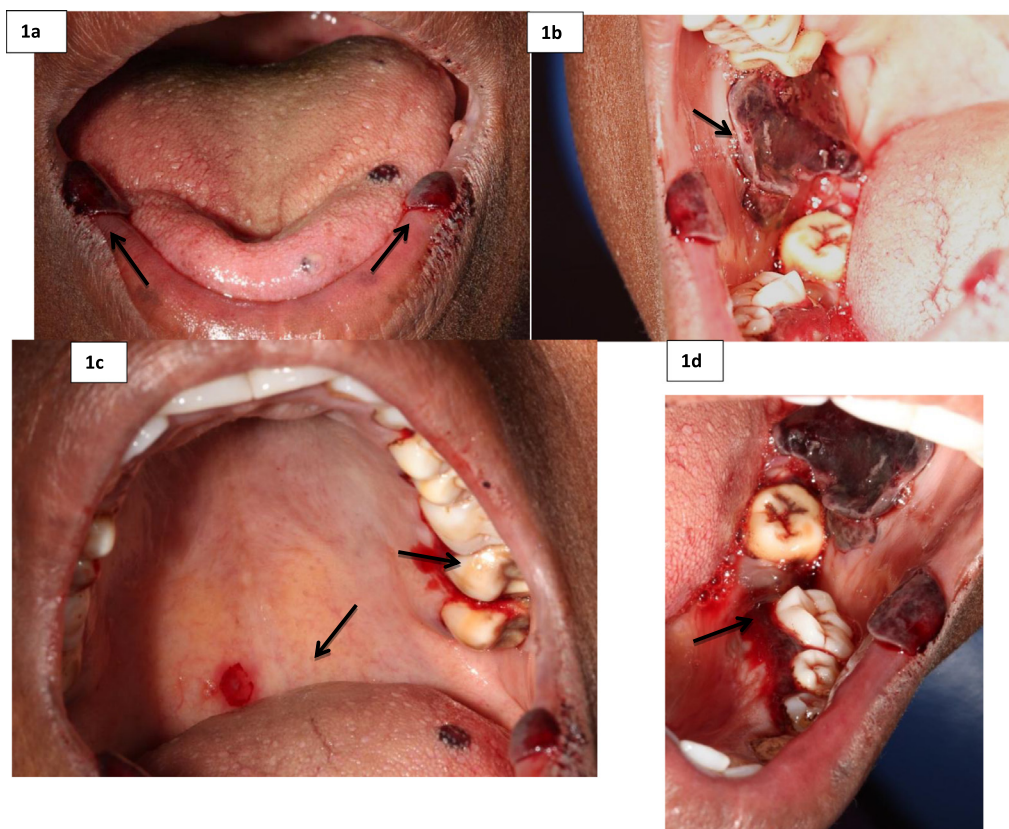


Fig. 1 A 42-year-old female attended for multiple haemorrhagic bullae affecting her lower labial mucosa and dorsum of the tongue (a); right buccal mucosa (b) and palate (c). There was spontaneous bleeding of the lower lingual gingiva (d) and upper palatal gingiva. A full blood count was normal excepting for her platelet count: $4000/\text{mm}^3$ (normal range: 150,000–400,000) and MCHC was marginally low: 29.9 g/dl (normal range: 31.5–34.5). She reported that two days previously she had had continuous bleeding from the mouth and she then noticed the oral lesions. She was treated in the Department of Haematology but the details of the treatment are not available: the spontaneous bleeding resolved and 48 h later the oral lesions were in the process of healing. The cause of her thrombocytopaenia remains unknown.

Table 1 The severity of thrombocytopaenia in relation to oral manifestations.

Platelet count $\times 10^3/\text{mm}^3$	Severity of thrombocytopaenia	Manifestations
100–150	Mild	Normal mucosa Sometimes slight increase in postoperative bleeding
50–100	Moderate	Postoperative bleeding Possible petechial and ecchymosis
30–50	Severe	Sometime spontaneous bleeding Multiple petechial haemorrhage Ecchymosis, blood blisters
<30	Life-threatening	Spontaneous bleeding

Table 2 Some causes of thrombocytopaenia. Certain drugs and infective agents may cause thrombocytopaenia by both decreasing production and increasing destruction of platelets.

1. Decreased production of platelets by the bone marrow
 - Hypoplasia or aplasia of megakaryocytes
 - Ionizing radiation
 - Drugs and chemicals (e.g. cytotoxic drugs, certain antibiotics, antidiabetic, anticonvulsive, sedative and tranquilizers, insecticides, heavy metals and a variety of other agents)
 - Congenital conditions
 - Idiopathic
 - Infiltration of bone marrow
 - Leukaemia, multiple myeloma, histiocytosis, metastatic tumours
 - Metabolic disorders
 - Hypothyroidism, azothemia
 - Infections
 - Bacterial, viral, protozoan and metazoan diseases
2. Sequestration of platelets, usually in an enlarged spleen
3. Increased destruction of platelets
 - Infection - induced thrombocytopenia
 - Drug - induced thrombocytopenia
 - Immune - mediated thrombocytopenia
 - Idiopathic thrombocytopenia

other haemorrhagic disorders will enable prompt diagnosis of the thrombocytopaenia and its treatment (McCarthy and Shklar, 1964).

There are no clear-cut guidelines to the management of thrombocytopaenic patients who are going to receive dental or oral surgical treatment; but in general if the platelet count is below $50,000/\text{mm}^3$, it is advisable to administer an infusion of platelets and to treat any oral or dental condition that may cause local bleeding in hospital (Scully et al., 2007).

The purpose of this paper is to inform the general dental practitioner about the clinical presentation, diagnosis, course, aetiopathogenesis and management of oral thrombocytopaenic purpura.

2. Thrombocytopaenia

The normal count of platelets in the blood ranges from $150,000$ to $450,000/\text{mm}^3$ (Konkle, 2010; Handin, 2005) and the average lifespan of platelets ranges from 7 to 12 days (Scully, 2014). Thrombocytopaenia is defined as a platelet count below $150,000/\text{mm}^3$ (Ganda, 2008) and it has been classified into mild, moderate, severe and life threatening based on the plate-

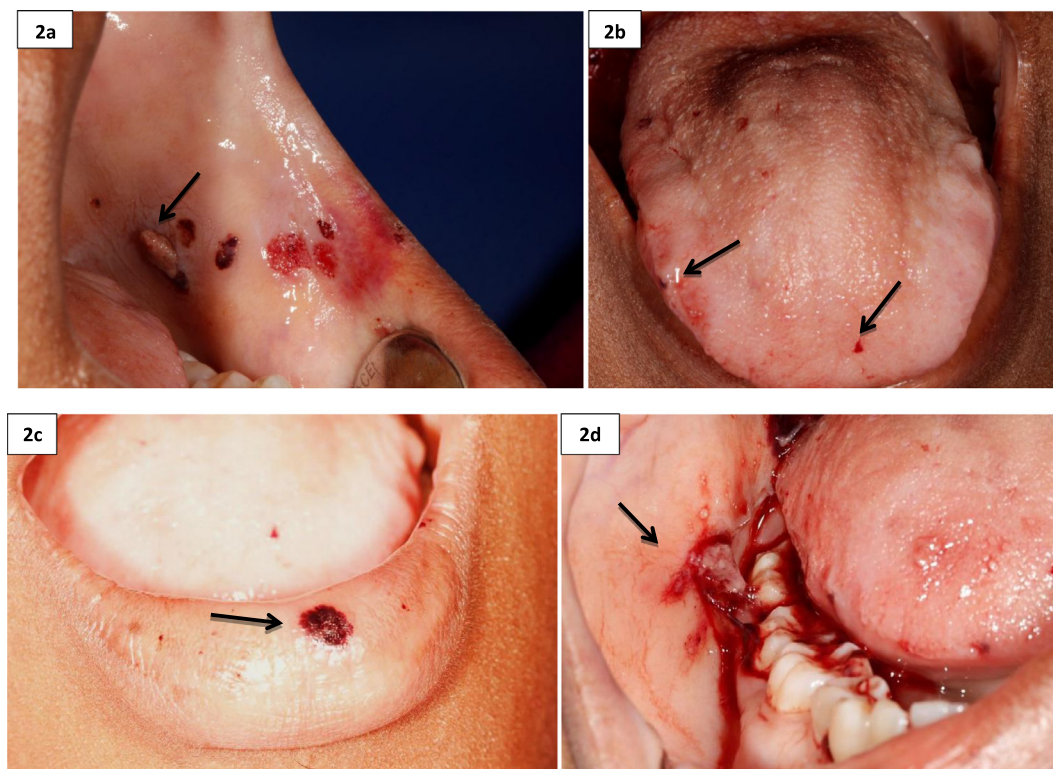
let count (Table 1) (Scully, 2014; Scully et al., 2007). However, there is no direct correlation of platelet count with clinical signs and symptoms, so such a classification is not of great clinical value (Vinholt et al., 2014; Handin, 2005; Aster, 2005). Regardless of the platelet count, recurrent spontaneous bleeding is the determinant of whether treatment is necessary (Aster, 2005; Rodeghiero et al., 2013, 2009). Despite prolonged bleeding time, protrombin time (PT) and partial thromboplastin time (PTT) remain normal in thrombocytopaenic subjects (Aster, 2005).

There is a dynamic equilibrium between the number of platelets produced in the bone marrow and the number sequestered in the spleen, maintaining a stable pool of circulating platelets. A decrease in the number of circulating platelets brings about an increase in the production of the hormone thrombopoietin by the liver. This in turn stimulates bone marrow megakaryocytes, increasing the production and the release of platelets into the circulation (Kuter, 2014; Handin, 2005; Grozovsky et al., 2015). Splenomegaly, whatever its cause, results in an increase in the sequestration of platelets, and if this exceeds the rate of production, thrombocytopaenia will develop (Konkle, 2010).

3. Causes of thrombocytopaenia

Thrombocytopaenia may be brought about by decreased production of platelets by megakaryocytes in the bone marrow, by increased destruction of platelets in the circulation, and by abnormal sequestration of platelets in the spleen (Table 2) (Konkle, 2010; Rajendran and Nooh, 2012). Bone marrow aplasia, fibrosis, infiltration by malignant cells, and the effect of cytotoxic drugs or infective agents are the most common causes of bone marrow suppression (Table 2). Although thrombocytopaenia may occur as the sole outcome of bone marrow dysfunction, more often than not bone marrow suppression also affects the production of white and red blood cells, so that thrombocytopaenia is accompanied by anaemia and leukopaenia (Rajendran and Nooh, 2012).

Increased destruction of circulating platelets is common in persons with established thrombotic thrombocytopaenic purpura, haemolytic uraemic syndrome and as a manifestation of disseminated intravascular coagulation. In addition, destruction of circulating platelets can be induced by drugs or infections, may be immune-mediated or may be idiopathic (Konkle, 2010). Certain drugs can directly affect platelets, but most drugs that cause thrombocytopaenia do so by

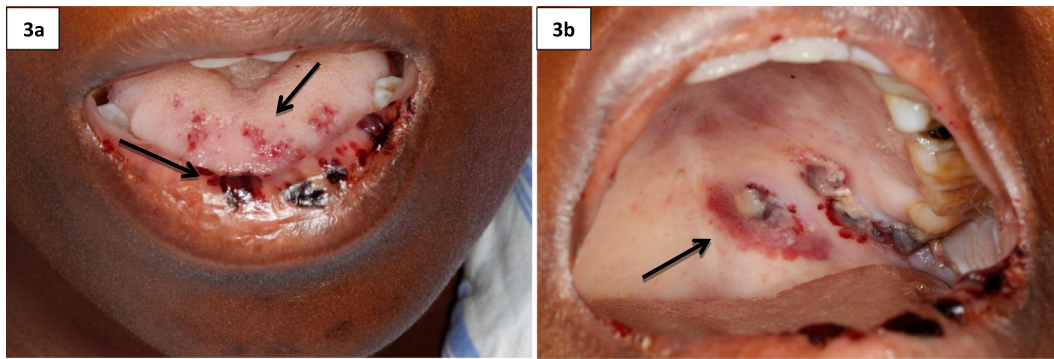


	Results	Range
White Cell Count	16.44H* $\times 10^9$ /L	3.90-12.60
Red Cell Count	2.79x 10^{12} /L	3.93-5.40
Haemoglobin	7.6 L* g/dL	11.6 - 16.4
Haematocrit	0.256 L* L/L	0.340 - 0.480
MCV	91.5 fL	78.9 – 98.5
MCH	27.3 pg	26.1 - 33.5
MCHC	29.8 L* g/dL	32.7 - 34.9
RDW	27.4 H* %	12.4 - 17.3
Platelet Count	6000 L* /mm ³	186000 – 454000
MPV	9.1 fL	7.3 - 11.3

Fig. 2 A 24-year-old female attended for multiple haemorrhagic bullae affecting the left buccal mucosa (a), multiple scattered petechiae of the tongue, lower lip and elsewhere (b), and a haemorrhagic vesicle on the lower lip (c). Some of the lesions were bleeding (d). A full blood count is given in the above table. She reported that bleeding from her mouth had started three days before the consultation when she had also noticed the oral lesions which she thought were becoming worse. After a blood transfusion, the oral bullae and petechiae started to get better.

eliciting an anti-platelet immune response (Konkle, 2010; Liu et al., 2013): in cases of infections, the infective agent may induce the production of antibodies that cross react with platelet surface antigens causing their elimination (Bettaieb et al., 1992). Drug- and infection-induced thrombocytopenia usually resolves after withdrawal of the drug, or after resolution of the infection (Konkle, 2010).

Immune thrombocytopenia with purpura is an acquired auto-immune disorder (Liu et al., 2013) that is considered 'secondary' when it is associated with other autoimmune diseases particularly lupus erythematosus and autoimmune lymphoproliferative syndrome, or with certain infective agents such as HIV, hepatitis C virus, cytomegalovirus and *Helicobacter pylori* (Konkle, 2010).



	Results	Range
White Cell Count	9.54x10 ⁹ /L	3.90-12.60
Red Cell Count	1.94L *x 10 ¹² /L	3.93-5.40
Haemoglobin	5.1 L* g/dL	11.6 - 16.4
Haematocrit	0.155 L* L/L	0.340 - 0.480
MCV	80.2 fL	78.9 – 98.5
MCH	26.2 pg	26.1 - 33.5
MCHC	32.7 g/dL	32.7 - 34.9
RDW	17.1 %	12.4 - 17.3
Platelet Count	18000 L*/mm ³	186000 – 454000
MPV	16.4 H*fL	7.3 - 11.3

Fig. 3 41-year-old HIV-seropositive female on HAART with a CD4+ T cell count of 402 cells/mm³ was referred by the Department of Haematology with multiple petechiae and bullae of the lower lip and dorsum of the tongue (a) and dried out bullae on the soft palate (b). A full blood count was given in the above table. The patient reported that her mouth had started bleeding about two weeks previously and that the lesions in her mouth had become more numerous and widespread since she first noticed them. She was then treated with a blood transfusion in the Department of Haematology and by the time of our consultation a few days later, the lesions were already somewhat better and the bleeding had stopped.

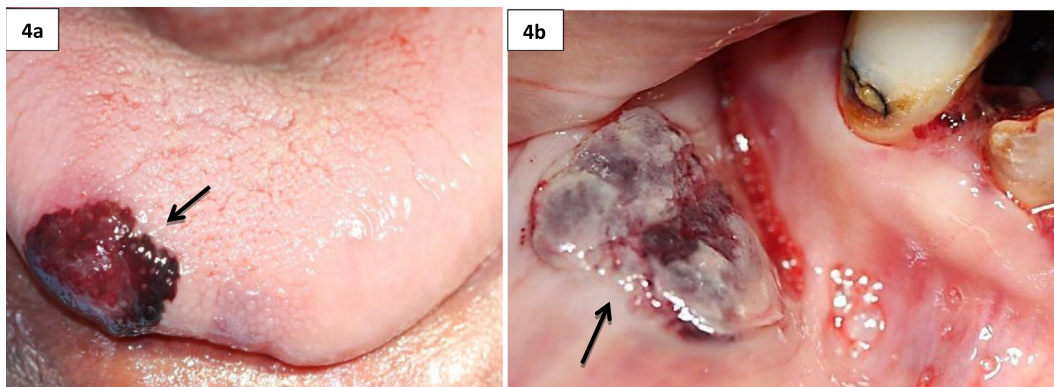


Fig. 4 A 42-year-old HIV-TB co-infected HAART-naïve female with multiple haemorrhagic bullae on the dorsum of the tongue (a) and lower labial mucosa (b), reported that the lesions had been present for three weeks and were getting progressively worse. Patient was referred to the Department of Haematology, where she was diagnosed with idiopathic thrombocytopaenia and was treated with a blood transfusion. She was also referred to the local HIV clinic for treatment of HIV-TB co-infection. The results of her blood test were not available.

Autoantibodies directed against the glycoprotein (GP) GPIIb-IIIa on the platelet surface, or against as yet an unidentified platelet antigen, or the formation of immune complexes on platelet surfaces result in increased platelet clearance (Scully, 2014; Louache et al., 1991). In those persons with immune thrombocytopenic purpura who do not have autoantibodies against platelets, activated cytotoxic T cells probably destroy the platelets (Cines et al., 2014; Olsson et al., 2003). As megakaryocytes express some antigenic glycoproteins identical to those of platelets, the same immune response against megakaryocytes will also cause impairment of platelet production bringing about thrombocytopenic purpura (Konkle, 2010). Thus, immune-mediated thrombocytopenia is caused both by a decrease in production of platelets in the bone marrow, and by an increase in clearance of circulating platelets (Kashiwagi and Tomiyama, 2013).

4. Diagnosis, evaluation and management of a patient with thrombocytopenia

A diagnosis of thrombocytopenia is predicated by a count of circulating platelets below $150,000/\text{mm}^3$ (Grozovsky et al., 2015). A comprehensive history of drug usage, illnesses, a thorough physical examination, a complete blood count and a peripheral blood smear are all essential for the initial evaluation of the thrombocytopenic patient (Konkle, 2010; Provan et al., 2010). Importantly, there are no clinical or laboratory predictors of the course of thrombocytopenia (Rodeghiero and Ruggeri, 2014), and the differential diagnosis of purpura is more complex for elderly, ill persons on medications, than for otherwise healthy young adults (Konkle, 2010).

Serological testing for antibodies against platelets is seldom helpful because of the low specificity and sensitivity of the tests; and bone marrow investigation is usually necessary for those who do not respond to treatment. The diagnosis of primary immune thrombocytopenic purpura is based on the exclusion of other causes of purpura. A peripheral blood smear allows for identification of abnormalities in size and morphology of platelets: in immune thrombocytopenic purpura the morphology of the platelets is normal, but they may be abnormally large (Aster, 2005; Provan et al., 2010). If there has been significant bleeding owing to thrombocytopenia there will be microcytic anaemia; however, if the thrombocytopenia is the result of bone marrow suppression of whatever cause, then there may be macrocytic anaemia (Provan et al., 2010).

Thrombocytopenic purpura manifests clinically as mucocutaneous petechiae, ecchymoses and haemorrhagic blisters with spontaneous bleeding (Figs. 1–4). The severity of the clinical manifestations does not always correlate with the platelet count (Vinholt et al., 2014), but the presence of a haemorrhagic blister in the oral cavity may serve as an indicator for spontaneous intracranial haemorrhage (Konkle, 2010).

Thrombocytopenia should be treated when there is spontaneous bleeding or if the platelet count falls below $30,000/\text{mm}^3$ (Konkle, 2010). In the absence of spontaneous bleeding, the decision as to the treatment of thrombocytopenia when the platelet count is above $30,000/\text{mm}^3$ is dictated by the patient's age, gender, medications and comorbidities (Rodeghiero and Ruggeri, 2014; Provan et al., 2010).

Severe thrombocytopenia not of immune origin should be treated with transfusion of platelets. On the other hand

immune thrombocytopenia should be treated with systemic glucocorticoids, or with cytotoxic chemotherapy, but not with platelet transfusion because the host anti-platelet immunoglobulins will destroy the transfused platelets (Ganda, 2008; Scully et al., 2007). However, regardless of the pathogenesis, established thrombocytopenic bleeding must be treated by transfusion of platelets (Scully, 2014).

5. Thrombocytopenia in relation to HIV infection

Thrombocytopenia is the most frequent haematological disorder associated with HIV infection. Cross reaction of antibodies in response to HIV gp120 with certain platelet glycoproteins will promote clearance of the platelets, and the direct effect of HIV on megakaryocytes in the bone marrow may impair platelet production (Scully, 2014). Thus both increased platelet destruction and diminished platelet production are implicated in the pathogenesis of HIV-associated thrombocytopenia (Bettaieb et al., 1992, Louache et al., 1991).

Conflict of interest

The authors declared that there is no conflict of interest.

Funding

No funding was received for this paper.

Competing interest

None.

Ethical approval

Approved: SMUREC/D/295/2015: Case Presentation (J).

Acknowledgments

None.

References

- Aster, J.C., 2005. Red blood cell and bleeding disorders. In: Kumar, V., Abbas, A.K., Fausto, N. (Eds.), *Robbins and Cotran Pathologic Basis of Disease*. Elsevier Saunders, Pennsylvania, USA, pp. 649–653.
- Bettaieb, A., Fromont, P., Louache, F., Oksenhendler, E., Vainchenker, W., Duedari, N., Bierling, P., 1992. Presence of cross-reactive antibody between human immunodeficiency virus (HIV) and platelet glycoproteins in HIV-related immune thrombocytopenic purpura. *Blood* 80, 162–169.
- Cines, D.B., Cuker, A., Semple, J.W., 2014. Pathogenesis of immune thrombocytopenia. *Presse Med.* 43, e49–e59.
- Ganda, K.M., 2008. Platelet disorders: thrombocytopenia, platelet dysfunction, and thrombocytosis: assessment, analysis, and associated dental management guidelines. In: Ganda, K.M. (Ed.), *Dentist's Guide to Medical Conditions and Complications*. Wiley-Blackwell, USA, pp. 155–158.

- Grozovsky, R., Giannini, S., Falet, H., Hoffmeister, K.M., 2015. Regulating billions of blood platelets: glycans and beyond. *Blood* 126, 1877–1884.
- Handin, R.I., 2005. Disorders of the platelet and vessel wall. In: Kasper, D.L., Fauci, A.S., Longo, D.L., Braunwald, E., Hauser, S. L., Jameson, J.L. (Eds.), *Harrison's Principles of Internal Medicine*. 16th ed. McGraw-Hill, pp. 660–673.
- Kashiwagi, H., Tomiyama, Y., 2013. Pathophysiology and management of primary immune thrombocytopaenia. *Int. J. Hematol.* 98, 24–33.
- Konkle, B.A., 2010. Disorders of platelets and vessel wall. In: Longo, D.L. (Ed.), *Harrison's Hematology and Oncology*. McGraw Hill Professional, USA, pp. 224–234.
- Kuter, D.J., 2014. Milestones in understanding platelet production: a historical overview. *Br. J. Haematol.* 165, 248–258.
- Liu, X., Hou, Y., Peng, J., 2013. Advances in immunopathogenesis of adult immune thrombocytopaenia. *Front. Med.* 7, 418–424.
- Louache, F., Bettaieb, A., Henri, A., Oksenhendler, E., Farcet, J.P., Bierling, P., Seligmann, M., Vainchenker, W., 1991. Infection of megakaryocytes by human immunodeficiency virus in seropositive patients with immune thrombocytopenic purpura. *Blood* 78, 1697–1705.
- Mccarthy, P.L., Shklar, G., 1964. Oral manifestations of blood dyscrasias. In: Mccarthy, P.L., Shklar, G. (Eds.), *Diseases of the Oral Mucosa*. McGraw-Hill, United States of America, pp. 263–264.
- Olsson, B., Andersson, P.O., Jernas, M., Jacobsson, S., Carlsson, B., Carlsson, L.M., Wadenvik, H., 2003. T-cell-mediated cytotoxicity toward platelets in chronic idiopathic thrombocytopenic purpura. *Nat. Med.* 9, 1123–1124.
- Parke, E., Hart, J., Baldock, D., Barchard, K., Etkoff, L., Allen, D., et al, 2013. Poster sessions schedule. *Arch. Clin. Neuropsychol.* 28, 518–626.
- Provan, D., Stasi, R., Newland, A.C., Blanchette, V.S., Bolton-Maggs, P., Bussel, J.B., et al, 2010. International consensus report on the investigation and management of primary immune thrombocytopaenia. *Blood* 115, 168–186.
- Rajendran, R., Nooh, N., 2012. Diseases of the blood and blood forming organs. In: Sharma, R., Goswami, N., Jha, A.K., Bali, I. (Eds.), *Shafer's Textbook of Oral Pathology*. seventh ed. Elsevier, New Delhi, India, pp. 3066–3082.
- Regezi, J.A., Sciubba, J.J., 1989. Red-Blue Lesions. In: Dyson, J. (Ed.), *Oral Pathology Clinical-Pathologic Correlations*. W.B. Saunders, Canada, pp. 146–150.
- Rodeghiero, F., Michel, M., Gernsheimer, T., Ruggeri, M., Blanchette, V., Bussel, J.B., et al, 2013. Standardization of bleeding assessment in immune thrombocytopaenia: report from the International Working Group. *Blood* 121, 2596–2606.
- Rodeghiero, F., Ruggeri, M., 2014. ITP and international guidelines: what do we know, what do we need? *Presse Med.* 43, e61–e67.
- Rodeghiero, F., Stasi, R., Gernsheimer, T., Michel, M., Provan, D., Arnold, D.M., et al, 2009. Standardization of terminology, definitions and outcome criteria in immune thrombocytopenic purpura of adults and children: report from an international working group. *Blood* 113, 2386–2393.
- Scully, C., 2014. Haematology. In: Scully, C. (Ed.), *Scully's Medical Problems in Dentistry*, seventh ed. Churchill Livingstone Elsevier, London, pp. 212–222.
- Scully, C., Dios, P.D., Kumar, N., 2007. Specific problems areas; alphabetically arranged. In: Scully, C., Dios, P.D., Kumar, N. (Eds.), *Special Care in Dentistry, Handbook of Oral Healthcare*. Philadelphia, USA, Churchill Livingstone Elsevier, pp. 418–422.
- Vinholt, P.J., Hvas, A.M., Nybo, M., 2014. An overview of platelet indices and methods for evaluating platelet function in thrombocytopenic patients. *Eur. J. Haematol.* 92, 367–376.