

Georgia State University
ScholarWorks @ Georgia State University

Psychology Theses

Department of Psychology

8-13-2019

Dimensions of Depression and Cerebellar Subregion Volumes in Older Adults

Hannah R. Michalak
Georgia State University

Follow this and additional works at: https://scholarworks.gsu.edu/psych_theses

Recommended Citation

Michalak, Hannah R., "Dimensions of Depression and Cerebellar Subregion Volumes in Older Adults." Thesis, Georgia State University, 2019.
https://scholarworks.gsu.edu/psych_theses/204

This Thesis is brought to you for free and open access by the Department of Psychology at ScholarWorks @ Georgia State University. It has been accepted for inclusion in Psychology Theses by an authorized administrator of ScholarWorks @ Georgia State University. For more information, please contact scholarworks@gsu.edu.

DIMENSIONS OF DEPRESSION AND CEREBELLAR SUBREGION VOLUMES IN
OLDER ADULTS

by

HANNAH R. MICHALAK

Under the Direction of Vonetta M. Dotson, Ph.D.

The present study examined the relationship between subthreshold depressive symptoms and gray matter volume in subregions of the posterior cerebellum in middle-aged to older adults. Structural magnetic resonance imaging data from 38 adults aged 51 to 80 years were analyzed along with participants' responses to the Center for Epidemiologic Studies Depression Scale. Subscale scores for depressed mood, somatic symptoms, and lack of positive affect were calculated, and multiple regression analyses were used to examine the relationship between symptom dimensions and cerebellar volumes. Greater somatic symptoms of depression were significantly related to larger vermis VI volumes, as were total depressive scores. Exploratory analyses revealed that greater severity on the lack of positive affect subscale was related to larger vermis VIII volumes. These results support that depressive symptom profiles have unique relationships within the cerebellum that may be important as the field moves towards targeted treatment approaches for depression.

INDEX WORDS: Depressive symptoms, Symptom dimensions, Subthreshold depression, Cerebellum, Aging, Brain

DIMENSIONS OF DEPRESSION AND CEREBELLAR SUBREGION VOLUMES IN
OLDER ADULTS

by

HANNAH R. MICHALAK

A Thesis Submitted in Partial Fulfillment of the Requirements for the Degree of

Master of Arts

in the College of Arts and Sciences

Georgia State University

2019

Copyright by
Hannah Ryan Michalak
2019

DIMENSIONS OF DEPRESSION AND CEREBELLAR SUBREGION VOLUMES IN
OLDER ADULTS

by

HANNAH R. MICHALAK

Committee Chair: Vonetta M. Dotson

Committee: Tricia Z. King

Jessica A. Turner

Electronic Version Approved:

Office of Graduate Studies

College of Arts and Sciences

Georgia State University

May 2019

TABLE OF CONTENTS

LIST OF TABLES	VII
LIST OF FIGURES	VIII
LIST OF ABBREVIATIONS	IX
1 INTRODUCTION.....	1
1.1 Overview	1
1.2 Subthreshold Depression in Older Adults	2
1.3 Depression: A Complex Illness	3
1.4 Subthreshold Depression and Structural Brain Abnormalities	5
1.5 The Limbic Cerebellum.....	7
1.6 The Cerebellum and Depression.....	9
1.7 The Present Study	10
1.8 Aims of the Proposed Study	11
<i>1.8.1 Specific Aim 1.....</i>	<i>11</i>
<i>1.8.2 Specific Aim 2.....</i>	<i>12</i>
<i>1.8.3 Exploratory Aim 1.....</i>	<i>12</i>
<i>1.8.4 Exploratory Aim 2.....</i>	<i>13</i>
<i>1.8.5 Exploratory Aim 3.....</i>	<i>13</i>
2 METHODS	13
2.1 Participants.....	13

2.2	Measures	15
2.3	Imaging Procedure.....	16
2.4	Imaging Analysis.....	17
2.5	Data Analysis.....	17
2.5.1	<i>Outlier Analysis</i>	18
2.5.2	<i>Aim 1: Identify whether the gray matter volume of vermal regions VI and VII is predicted by depressive symptom severity.</i>	18
2.5.3	<i>Aim 2: Identify distinct relationships between cerebellar subregions, vermis VI and VII, and subthreshold symptom dimensions.</i>	18
2.5.4	<i>Exploratory Analysis 1</i>	18
2.5.5	<i>Exploratory Analysis 2</i>	19
2.5.6	<i>Exploratory Analysis 3</i>	19
2.5.7	<i>Power Analysis</i>	19
3	RESULTS	20
3.1	<i>Aim 1: Identify whether the gray matter volume of vermal regions VI and VII is predicted by depressive symptom severity.</i>	20
3.2	<i>Aim 2: Identify distinct relationships between cerebellar subregions, vermis VI and VII, and subthreshold symptom dimensions.</i>	20
3.3	<i>Exploratory Analysis 1.</i>	20
3.4	<i>Exploratory Analysis 2.</i>	21
3.5	<i>Exploratory Analysis 3.</i>	21

4	DISCUSSION	23
4.1	Limitations.....	29
4.2	Conclusion	29
	REFERENCES.....	31
	APPENDIX.....	49

LIST OF TABLES

Table 1.1 Cerebellar Subregions in Relation to Affect and Depression	10
Table 2.1 Sample Characteristics.....	15
<i>Table 3.1 Results of Regression Analyses: Total CES-D Predicting Cerebellar Volumes.....</i>	<i>20</i>
Table 3.2 Results of Regression Analyses: CES-D Subscales Predicting Cerebellar Volumes...	22

LIST OF FIGURES

Figure 1. Aim 1 Regression Analyses.....	49
Figure 2. Aim 2 Regression Analyses.....	50

LIST OF ABBREVIATIONS

SubD	Subthreshold Depression
RDoC	Research Domain Criteria
MDD	Major Depressive Disorder
CES-D	Center for Epidemiologic Studies Depression Scale

1 INTRODUCTION

1.1 Overview

According to the World Health Organization, more than 300 million people suffer from depression globally ("World Health Organization: Depression," 2017). This statistic is staggering, and yet it does not include the vast number of individuals who are impaired by depressive symptoms yet fail to meet clinical criteria for major depression, which is known as "subthreshold depression" (SubD). Given the psychology field's diagnosis-driven approach to research in the past, there is no good estimate of the number of individuals experiencing subclinical symptoms of mental illness (Cuthbert, 2014). However, due in part to the Research Domain Criteria (RDoC), a relatively new research framework from the National Institute of Mental Health, the literature now supports that depression, as an illness, is best thought of as a continuum of symptoms rather than as a discrete diagnosis (Adams & Moon, 2009; Hybels, Blazer, & Pieper, 2001; Lee, Hasche, Choi, Proctor, & Morrow-Howell, 2013; Meeks, Vahia, Lavretsky, Kulkarni, & Jeste, 2011). This approach has opened the door for additional research on subthreshold symptoms of mental illness.

With RDoC has come a research focus on dimensions of behavior in psychological disorders (Insel, Cuthbert, Garvey, Heinssen, & Pine, 2010), which encourages researchers to examine symptom profiles within mental illness in an effort to better understand the heterogeneous etiology of these disorders. Depression in older adults has already been linked to a variety of structural brain changes (Naismith, Norrie, Mowszowski, & Hickie, 2012), yet the diversity of symptoms and clinical outcomes experienced by these individuals indicates a need for more research regarding the neurobiological basis of depressive symptoms. In order to

address this need, the current study seeks to evaluate the relationship between symptom dimensions of depression and cerebellar volumes in a population of older adults.

1.2 Subthreshold Depression in Older Adults

At least 10-13.8% of all older adults are estimated to experience SubD (Laborde-Lahoz et al., 2015; Meeks et al., 2011), with some estimates as high as 35% (Blazer, 2003). This significant proportion of older adults with SubD represents a particularly vulnerable population. Research indicates that while SubD causes significant functional impairment in adults of all ages, older adults with SubD show significantly worse functional impairment compared to their healthy, age-matched peers (Karsten, Penninx, Verboom, Nolen, & Hartman, 2013). Additionally, older adults with SubD have an increased risk of mortality equivalent to those with Major Depressive Disorder (MDD) when compared to non-depressed older adults (Cuijpers et al., 2013). Those who receive a diagnosis of SubD also have twice the incidence rate of developing MDD as those without a SubD diagnosis (Jeuring, Huisman, Comijs, Stek, & Beekman, 2016). Older adults who go on to develop MDD utilize greater outpatient services compared to non-depressed older adults (Huang et al., 2014) in addition to having higher rates of falls (Stubbs, Stubbs, Gnanaraj, & Soundy, 2016) and both vascular and Alzheimer's dementia (Diniz, Butters, Albert, Dew, & Reynolds, 2013; Geerlings & Heijer, 2008).

As the field stands, treatment of both clinical and subclinical depression in older adults is lacking. While approximately 13.7% of adults aged 55 years and older experience MDD and an additional 13.8% experience SubD in late life (Laborde-Lahoz et al., 2015), almost two-thirds of depressed older adults remain untreated (Kales & Valenstein, 2002). Additionally, half of all older adults with depression do not respond to first-time pharmacotherapy (Joel et al., 2014), and these individuals with persistent depression are more likely to experience cognitive deficits as

they age (Singh-Manoux, Akbaraly, & Marmot, 2010). Despite our knowledge of the negative impact that SubD has on aging adults, there is a critical gap in the literature when it comes to understanding the etiology of the heterogeneous symptoms that comprise depression.

1.3 Depression: A Complex Illness

Depression is an illness with multiple underlying symptom dimensions (Lux & Kendler, 2010), which makes it particularly challenging to study. While many depressed individuals experience mainly sad mood, crying spells, and feelings of worthlessness or failure, others can present with primarily somatic symptoms such as fatigue or insomnia, increased or decreased appetite, or difficulty getting “going” (American Psychiatric Association, 2013). Still others experience a lack of positive affect, that is, symptoms related to the inability to experience pleasure or other positive emotions in the same way that they did in the past. Older adults are more likely than younger adults to present with these symptoms of anhedonia (Wuthrich, Johnco, & Wetherell, 2015), and there is some evidence that they are more likely to endorse somatic symptoms such as sleep disturbance, fatigue, and psychomotor retardation (Fiske, Wetherell, & Gatz, 2009). Given the heterogeneity of this illness, examining the sum of symptoms that a person is experiencing can obscure subtle connections between particular depressive symptoms and changes in the brain.

A factor analysis of multiple depression scales by Dunlop, Cole, Nemeroff, Mayberg, and Craighead (2018) illustrates the complex symptomology of this disorder. Using data from 306 medication-naïve individuals assigned to cognitive behavioral therapy, escitalopram, or duloxetine treatment groups, four symptom factors emerged from their analyses: despair, mood and interest, sleep, and appetite. These analyses revealed that while participants had similar improvement in symptoms at the end of the treatment trials, symptom type had an effect on how

quickly participants benefited from each treatment (Dunlop et al., 2018). This illustrates the importance of examining symptom dimensions when studying depression, given the multiple factors underlying this singular diagnosis and their potential relationship with treatment outcome.

Using this approach, research utilizing subscales of depression measures has revealed that depressive symptom dimensions are uniquely related to changes in the brain (O'Shea et al., 2018; Pizzagalli et al., 2004). A study by McLaren et al. (2016) illustrated this with the finding that the depressed mood and somatic symptom subscales of the Center for Epidemiologic Studies Depression Scale (CES-D) had opposite relationships with posterior cingulate volumes among a group of older adults. Specifically, higher scores on the depressed mood subscale were significantly related to larger left posterior cingulate volumes, whereas higher somatic symptom scores were significantly associated with smaller volumes in this region. The study also found that higher scores on the lack of positive affect subscale were associated with larger volumes of the anterior cingulate, and higher scores on the depressed mood subscale were associated with smaller volumes in the isthmus cingulate.

In another study among middle-aged and older adults, elevated levels of somatic symptoms of depression were related to decreased cortical thickness of the precuneus, while depressed mood and lack of positive affect were not related to precuneus thickness (Szymkowicz et al., 2017). Additionally, Lener et al. (2016) found that sadness, worry, and fatigue were significantly correlated with low cortical thickness in the ventrolateral prefrontal cortex among depressed individuals, indicating yet again that symptom dimensions are associated with distinct etiologies. Symptom dimensions have also been linked to unique profiles of cognitive deficits among older adults (Brailean et al., 2016), and have been shown to predict treatment outcomes in individuals with MDD (Vrieze et al., 2014). Thus, in order to most accurately examine the

relationship between depression and changes in the brain, it is necessary to conduct this research through the lens of symptom dimensions.

1.4 Subthreshold Depression and Structural Brain Abnormalities

Dysregulation of the frontolimbic network is a hallmark of depression in both young and older adults (Kaiser, Andrews-Hanna, Wager, & Pizzagalli, 2015; Tadayonnejad & Ajilore, 2014). The frontolimbic network includes the amygdala, subgenual anterior cingulate cortex, hypothalamus, orbitofrontal cortex, and nucleus accumbens. Together, these brain structures function primarily to process emotion and maintain emotional stability (Palazidou, 2012). In adults with late-life depression, however, this entire system is marked by disrupted functional connectivity (Alexopoulos et al., 2013a; Fujimoto et al., 2008). Distinct structural abnormalities among components of this network are also well-described. For example, in the amygdala, abnormal shape (Tamburo et al., 2009) and reduced volume (Egger et al., 2008; Hickie et al., 2007) of this structure, as well as network dysfunction (H. Li et al., 2015) has been identified among depressed older adults. The uncinate fasciculus, an important white matter tract that connects limbic structures such as the amygdala and hippocampus to the prefrontal cortex, is also often disrupted in those with late-life depression (Steffens, Taylor, Denny, Bergman, & Wang, 2011). Additionally, reduced volumes in prefrontal regions, such as the orbitofrontal cortex (Taylor et al., 2003) and hippocampus (Naismith et al., 2012) have been observed.

SubD symptoms are related to similar frontolimbic abnormalities in older individuals, even without meeting the clinical criteria for a major depressive episode. This has been documented in studies that use criteria for so-called “minor depression” as well as those that examine depressive symptoms as a continuous measure based on questionnaire scores. For example, older adults with SubD have smaller right parahippocampal volumes compared with

age-matched controls (Zhou et al., 2016), whereas cortical thickness in the isthmus cingulate and middle frontal gyrus has been positively associated with the number of depressive symptoms in this population (Szymkowicz et al., 2016). Additionally, bilateral reductions in prefrontal cortex gray matter volume have been demonstrated in a sample of older males with SubD (Taki, Kinomura, Awata, & Inoue, 2005). Compromised frontal lobe integrity was also observed in a longitudinal study of older adults, in which the severity of SubD symptoms was found to be associated with more rapid white matter volume loss in the left frontal region (Dotson, Davatzikos, Kraut, & Resnick, 2009), as well as gray matter volume reductions in the frontal and temporal lobes (Dotson, Davatzikos, et al., 2009; Kumar, Jin, Bilker, Udupa, & Gottlieb, 1998; Kumar et al., 1997). A relationship between SubD and changes in white matter microstructure has also been observed among older adults in a pattern similar to the white matter changes in adults with MDD (Allan et al., 2016).

Functional imaging studies support these findings as well. Researchers have identified higher resting-state connectivity in the anterior cingulate cortex for those with SubD, similar to what is seen in patients in remission from MDD (R. Li, Ma, Yu, He, & Li, 2014), as well as decreased cerebral blood flow in the frontal regions of the brain (Dotson, Beason-Held, Kraut, & Resnick, 2009; McLaren et al., 2016). Additionally, Hwang, Xin, Ou, Zhang, and Liang (2016), illustrated elevated functional connectivity between the default mode network and ventral striatum in individuals with SubD, perhaps indicating a compensatory response to the disrupted reward system often seen in individuals with depression. Overall, SubD appears to be related to both structural and functional abnormalities in the brain in ways quite similar to the deficits observed in MDD.

1.5 The Limbic Cerebellum

The cerebellum is not a brain region typically studied in depression; however, researchers have demonstrated that it is involved in emotion processing (Stoodley & Schmahmann, 2009, 2010) in addition to its well-known role in motor coordination. Given that the cerebellum has widespread connections to both the cortex and limbic system, it is no surprise that it plays a role in emotion processing. The cerebellum is designed such that there are multiple closed-loop cerebellar circuits that exist in parallel (Strick, Dum, & Fiez, 2009), and a large part of the cerebellum is linked to the association cortex. In fact, almost half the cerebellum targets the cognitive control and default mode networks (Buckner, Krienen, Castellanos, Diaz, & Yeo, 2011). For example, lobule VII accounts for approximately 48% of the cerebellar cortex (Diedrichsen, Balsters, Flavell, Cussans, & Ramnani, 2009) and has major connections to the parietal and prefrontal cortices (Kelly & Strick, 2003), illustrating that it is not solely relevant for motor activity (Stoodley & Schmahmann, 2018).

Additionally, Habas et al. (2009) have provided evidence that distinct regions of the cerebellum participate in two major networks involved in depression, both the default mode (lobule IX) and salience networks (lobule VI), in a way that is separate from the sensorimotor functions of the cerebellum. Drawing conclusions from the literature and their findings regarding cerebellar participation in intrinsic connectivity networks, Habas et al. (2009) propose that the vermis of lobule VI could play a modulatory role in the salience network, perhaps representing a “phylogenetically older cerebellar emotional processor” (pp. 9) in conjunction with other areas of the posterior vermis. In further support of the affective role of the cerebellum, vermal regions of areas VIIB, VIII, and IX have been found to have connections with the amygdala (Leggio & Olivito, 2018; Sang et al., 2012), and a “cerebello-amygdaloid” network has been suggested

(Habas, 2018). Other research has found distinct patterns of activity in the cerebellum in response to primary emotions, and found that all five primary emotions tested evoked activity in the vermis (Baumann & Mattingley, 2012).

Additional evidence for the “limbic cerebellum” (Schmahmann, 1991) comes from studies of cerebellar lesions in which individuals develop what is known as Cerebellar Cognitive Affective Syndrome (CCAS), a syndrome that is often marked by emotional lability (such as uncontrollable laughter or tearfulness) and changes in affect (Schmahmann & Sherman, 1997, 1998; Schmahmann, Weilburg, & Sherman, 2007). These disruptions to emotion and behavior are most notable in CCAS patients with injury to the cerebellar vermis and paravermal regions in particular (Schmahmann et al., 2007).

Furthermore, the cerebellar vermis has been activated in functional imaging studies investigating panic (Reiman et al., 1989), sadness and grief (Beauregard et al., 1998; Gündel, O'Connor, Littrell, Fort, & Lane, 2003; Lane et al., 1997), which provides additional support for its role in processing emotions. At a more basic level, the activation of hemispherical lobule VI and vermal lobule VII have been consistent across studies of emotionally salient stimuli (Depping, Schmitgen, Kubera, & Wolf, 2018; Stoodley & Schmahmann, 2009). The left crus I region of the cerebellum has also been activated during these emotion processing tasks (Stoodley & Schmahmann, 2009). Negative emotional faces have been found to activate lobules VIII and IX in the vermis, thus influencing researchers to hypothesize that the cerebellum has greater involvement in the control of negative compared to positive emotions (Schraa-Tam et al., 2012). Thus, the posterior cerebellum, and in particular the vermal region of the posterior cerebellum, appears to have the greatest involvement in emotion processing.

1.6 The Cerebellum and Depression

In an expansion of the cerebellum's known role as a modulator of emotion processing, previous research also demonstrated that the cerebellum plays a role in many psychiatric disorders such as autism, attention-deficit/hyperactivity disorder, schizophrenia, and post-traumatic stress disorder, as well as other anxiety and mood disorders (J. R. Phillips, Hewedi, Eissa, & Moustafa, 2015; Shakiba, 2014). Regarding depression specifically, individuals experiencing an acute episode of MDD were shown to have increased volume in left cerebellar area IX, while remitted participants had bilaterally increased volumes in this area (Depping et al., 2016). This has led to the suggestion that area IX of the cerebellum may be a potential trait marker for MDD (Depping et al., 2016).

Structural imaging studies have also provided evidence that depressive symptoms are related to smaller vermis volumes (Shah et al., 1992) as well as smaller overall cerebellar volumes (Escalona et al., 1993). Additionally, in depressed non-responders to fluoxetine treatment, depression severity was associated with smaller total cerebellar gray matter volume (Pillay et al., 1997). Volume reductions in the posterior crus I region were also observed in adults with MDD in comparison to healthy, age-matched controls (Grieve, Korgaonkar, Koslow, Gordon, & Williams, 2013). Structural imaging studies of the cerebellum in late-life depression are lacking, but a functional imaging study suggested that vermis-posterior cingulate cortex connectivity is positively associated with depression severity in a geriatric population (Alalade, Denny, Potter, Steffens, & Wang, 2011). These studies generally implicate posterior regions of the cerebellum, particularly the vermis (see Table 1; for a review of the cerebellum's contributions to MDD, see Depping et al., 2018). It should also be noted that both increases and decreases in cerebellar volume have been observed in depression.

Table 1.1 Cerebellar Subregions in Relation to Affect and Depression

Cerebellar Subregion	Relationship with Affect and Depression
Vermis	<ul style="list-style-type: none"> • Activated in functional imaging studies investigating panic (Reiman et al., 1989), sadness and grief (Beauregard et al., 1998; Gündel et al., 2003; Lane et al., 1997) • Patients with depression had smaller vermis volumes than healthy controls (Shah et al., 1992) • Patients with treatment-resistant depression had smaller vermis volumes than controls (Machino et al., 2014) • Posterior vermis was activated when processing one's own painful experience (Singer et al., 2004) • Children with extensive vermal damage experience emotional dysregulation, while children without vermal damage did not (Levisohn, Cronin-Golomb, & Schmahmann, 2000)
Vermal Lobule VI	<ul style="list-style-type: none"> • Active across emotionally salient stimuli (Stoodley & Schmahmann, 2009) • Bilateral activation during empathy for another's pain (Singer et al., 2004)
Vermal Lobule VII	<ul style="list-style-type: none"> • Emotion processing (Stoodley & Schmahmann, 2009) • Decreased gray matter volume in a sample with MDD vs. controls (Grieve et al., 2013)
Vermal Lobule VIII	<ul style="list-style-type: none"> • Activated by negative emotional faces (Schraa-Tam et al., 2012)
Vermal Lobule IX	<ul style="list-style-type: none"> • Participants with acute MDD had increased volume in left vermal lobule IX (Depping et al., 2016) • Participants with remitted MDD had bilaterally increased volume in lobule IX (Depping et al., 2016)
Vermal Crus I	<ul style="list-style-type: none"> • Emotion processing (Stoodley & Schmahmann, 2009) • Participants with treatment-resistant depression had decreased volumes of the right Crus I compared to controls (Machino et al., 2014) • Volume reduction in MDD patients vs controls (Grieve et al., 2013)

Given the proposed modulatory nature of the posterior “limbic” cerebellum, more research is needed to understand the role that it plays in depression. Specifically, a study of cerebellar volumes in an older adult population suffering from SubD has yet to be conducted.

1.7 The Present Study

The current climate of mental health research supports a dimensional view of psychological disorders. Psychological disorders as defined by the DSM-5 tend to have within-group heterogeneity as well as substantial overlap between disorders, providing evidence that mental illness is better studied using a dimensional approach (Grisanzio et al., 2018). This

approach to viewing symptoms on a continuum is supported by research indicating that SubD symptoms, while not meeting full diagnostic criteria for MDD, do cause suffering and impairment (Chopra et al., 2005; Meeks et al., 2011). Thus, it is imperative for research to explore the neurobiology of sub-syndromal mood disorders to understand their commonality and inform future treatments.

Additionally, given the vulnerability of the aging brain, it is essential to understand how SubD symptoms are related to brain changes in adults in later life. This proposal would be the first to perform a volumetric analysis of the cerebellum in a population of late middle-aged and older adults with SubD. In addition, studies to date have focused on the relationship between cerebellar volume and total depressive symptoms, therefore it is not clear whether symptom dimensions have unique relationships with individual areas of the cerebellum. Much remains to be learned about the cerebellum's role in mood disorders, therefore this project will add to the literature on a mood-focused exploration of the cerebellum. Identifying symptom dimension-related abnormalities in the cerebellum may inform diagnostic markers of depression in an older adult population and may serve as an indicator of which older adults are more vulnerable to developing MDD. This study will also contribute to the growing movement towards examining depression from a dimensional standpoint.

1.8 Aims of the Proposed Study

1.8.1 Specific Aim 1

The first major goal of the present study was to assess whether the total severity of depressive symptoms in older adults is associated with cerebellar subregion volumes. A self-report depression measure was used to identify SubD symptoms in relation to subregions of the vermis. Vermal regions VI and VII of the cerebellum have been the posterior cerebellar regions

most consistently involved in emotion processing studies to date (Depping et al., 2018; Stoodley & Schmahmann, 2010), thus the current study will examine these regions in relation to SubD symptoms.

1.8.1.1 Hypothesis 1

Given past structural research identifying smaller vermal and posterior cerebellar region volumes in individuals with depression, we hypothesized that overall symptom severity would be negatively associated with the gray matter volumes of vermal regions VI and VII.

1.8.2 Specific Aim 2

The second major goal of the present study was to assess whether symptom dimensions of SubD have distinct associations with subregions in the posterior cerebellum.

1.8.2.1 Hypothesis 2

We expected to find distinct relationships between specific cerebellar subregions and depressive symptom dimensions. Specifically, given the literature implicating these regions' involvement in emotion processing, we hypothesized that symptom dimensions would disparately predict the structural volumes of vermal regions VI and VII. Given the paucity of structural imaging studies regarding symptom dimensions and these subregions, however, we did not have a specific hypothesis about the direction of the relationship between these variables.

1.8.3 Exploratory Aim 1

Given the literature supporting the posterior vermis as the main cerebellar region involved in emotion processing (Stoodley & Schmahmann, 2009, 2010), we explored the other subregions of the posterior vermis in relation to depressive symptom severity. Together with VI and VII, regions VIII and IX come together to form the posterior region of the cerebellum. Additionally, vermal crus I has been implicated in studies of emotion processing and treatment-

resistant depression (Machino et al., 2014; Stoodley & Schmahmann, 2009). Given the prominent role of the vermis in relation to mood and emotion processing, the structural volumes of vermal VIII, IX, and crus I regions were examined in relation to total depressive symptom severity.

1.8.4 Exploratory Aim 2

The literature supports examining symptom dimensions to uncover more subtle relationships between mood disorders and structural brain volumes. Thus, we examined whether the depressed mood, somatic symptoms, and lack of positive affect subscales of a depression measure were able to predict the gray matter volumes of vermal regions VIII, IX and crus I.

1.8.5 Exploratory Aim 3

Since we did not expect the anterior cerebellum to have a relationship with depressive symptoms, the anterior cerebellum was used as a control region to determine whether SubD is specifically related to the posterior cerebellum or more generally associated with the cerebellum. Analyses were performed associating the anterior cerebellum (bilateral lobules I-IV) with both total depressive symptoms and the depressed mood, somatic symptoms, and lack of positive affect subscales of the depression measure.

2 METHODS

Secondary data analysis was performed on data previously collected in the Cognitive Neuroscience of Aging and Depression lab at the University of Florida.

2.1 Participants

Thirty-eight healthy adults from the community aged 51 to 80 years old were recruited from the University of Florida and the surrounding community. See Table 2.1 for a description

of the sample characteristics. All participants included in this study were native English speakers, right-handed, had normal or corrected-to-normal vision, and had nine or more years of education. Exclusion criteria included evidence of dementia per the Telephone Interview for Cognitive Status (Brandt, Spencer, & Folstein, 1988), self-report of major or unstable medical conditions, neurological disorders including seizure and stroke, learning disorders, current use of antiepileptic or antipsychotic medication, and magnetic resonance imaging (MRI) contraindications. Additionally, any participants that met criteria for a major psychological disorder as measured by the Structured Clinical Interview for DSM-IV Axis I Disorders (SCID-IV; First, Spitzer, Gibbon, & Williams, 2002) were excluded from the study. All participants provided written and verbal consent to participation in the study consistent with the University of Florida's IRB guidelines.

Table 2.1 Sample Characteristics

	Mean	s.d.	Observed range	Possible range
Age (years)	67.92	6.94	51-80	–
Education (years)	15.32	2.64	10-20	–
Sex (% female)	74	.446	–	–
Total Intracranial Volume (mm³)	1314629.13	120797.80	1062503-1569711	–
Ethnicity				
African-American (%)	5	–	–	–
Caucasian (%)	95	–	–	–
CES-D Total Score				
	5.50	4.97	0-19	0-60
CES-D Subscales				
Depressed mood	.84	1.44	0-6	0-21
Somatic	1.97	2.41	0-10	0-12
Lack of positive affect	1.47	2.08	0-9	0-21
Interpersonal difficulties*	1.21	1.68	0-6	0-6
Cognitive Status**				
MMSE (n = 17)	29.41	.712	28-30	0-30
TICS (n = 14)	36.07	2.09	33-40	0-41
MoCA (n = 7)	27.14	2.12	25-30	0-30
Medical Comorbidities				
Hypertension (%)	39.5	–	–	–
Hyperlipidemia (%)	21.1	–	–	–
Diabetes (%)	0	–	–	–
Any Cardiovascular Risk (%) ***	81.6			

Note. CES-D = Center for Epidemiologic Studies Depression Scale.

** Due to the limited distribution of this subscale it was not included in the main analyses.*

*** This data is comprised of participants combined from three studies which used three different measures of cognitive status: the Folstein Mini-Mental State Exam (>24 = healthy), the Telephone Interview for Cognitive Status (>30 = healthy), and the Montreal Cognitive Assessment (>23 = healthy).*

****Cardiovascular Risk includes the presence of any of the following risk factors: smoking, hypertension, hyperlipidemia, diabetes, heart disease, or high body mass index*

2.2 Measures

Prior to enrollment, potential participants were screened for eligibility over the phone with an IRB-approved screening form, which included information regarding their medical history and current medications to rule out exclusionary medical conditions and MRI

contraindications. They were administered the Telephone Interview for Cognitive Status, an 11-item measure which detects dementia with high validity and reliability (Brandt et al., 1988; Welsh, Breitner, & Mgruder-Habib, 1993).

To measure depressive symptoms, participants completed the CES-D, a commonly used 20-item self-report measure of depressive symptoms with high internal consistency among the general population (Cronbach's $\alpha = 0.85$). This scale was chosen for its well-documented validity in an older adult population (Gellis, 2010; Gomez & McLaren, 2015; Lewinsohn, Seeley, Roberts, & Allen, 1997) in addition to its well-replicated four factor structure, which includes depressed mood, somatic symptoms, lack of positive affect, and interpersonal difficulties (Carleton et al., 2013; Haringsma, Engels, Beekman, & Spinhoven, 2004; Radloff, 1977). Thus, the CES-D allows us to take a dimensional approach to assessing subthreshold depressive symptoms. Continuous measures of CES-D total and subscale scores were used in statistical analyses. The interpersonal problems subscale of the CES-D was not used in the current analyses due to the limited distribution of scores in this sample (most scores were 0).

A subset of participants was also administered a neuropsychological battery focusing on measures of memory and executive functioning; however, cognitive test scores will not be included in the current project.

2.3 Imaging Procedure

Magnetic resonance imaging (MRI) data were acquired at the University of Florida's McKnight Brain Institute on a Philips (Amsterdam, The Netherlands) 3-T scanner using an 8-channel head coil. Structural images were acquired using a T1-weighted turbo field echo high-resolution three-dimensional anatomical scan with 170 1-mm slices in sagittal orientation

(repetition time = 28.1 ms; echo time = 3.7 ms; flip angle = 8°). Foam padding was used within the head coil to minimize motion within the scanner.

2.4 Imaging Analysis

Pre-processing of the images occurred within Statistical Parameter Mapping (SPM) Version 8 in MATLAB. Preprocessing included the conversion of each image from DICOM to NIfTI files using MRICron, and then manually inspecting images for quality using FSL View. The isolation, normalization, and segmentation steps of processing the images took place within the Spatially Unbiased Infratentorial Template (SUIT) Toolbox, which operates within SPM Version 8 in MATLAB (Diedrichsen, 2006). The SUIT toolbox is available to download freely online (http://www.diedrichsenlab.org/imaging/suit_download.htm). Briefly, processing included motion correction, skull stripping, and segmentation of the gray and white matter tissue. Once the images were segmented, a high-resolution, spatially unbiased atlas template of the cerebellum and brainstem within SUIT was used to define regions of interest within the cerebellar lobules (Diedrichsen, 2006; Diedrichsen et al., 2009; Diedrichsen et al., 2011; Diedrichsen & Zotow, 2015). Analyses will focus on vermal regions VI and VII.

2.5 Data Analysis

Statistical analyses were conducted using SPSS Version 24.0 (IBM Corp, 2016). Multiple regression analyses were performed using the ratio of cerebellar region of interest volume to total intracranial volume as the dependent variable and CES-D scores (total or subscale scores depending on the study aim) as the independent variables. All models, including exploratory analyses, controlled for sex and age. An $\alpha \leq 0.05$ was considered significant.

2.5.1 *Outlier Analysis*

Any individuals with CES-D values ≥ 3 standard deviations from the mean were removed from the data analysis. This was to prevent exceptionally high scores from skewing the data or driving the results of the analyses. Additionally, any participants with a vermal crus I volume of zero and/or multiple other cerebellar regions with volumes of zero were removed from the analyses, given that this indicated poor image processing quality.

2.5.2 *Aim 1: Identify whether the gray matter volume of vermal regions VI and VII is predicted by depressive symptom severity.*

Two separate multiple regression analyses were conducted, one with the gray matter volume of vermal region VI as the outcome variable and one with the gray matter volume of vermal region VII as the outcome variable. In each model, the CES-D total score was entered as the predictor variable.

2.5.3 *Aim 2: Identify distinct relationships between cerebellar subregions, vermis VI and VII, and subthreshold symptom dimensions.*

Separate multiple regression analyses were conducted for cerebellar vermal regions VI and VII. In each analysis, CES-D subscale scores for the depressed mood, somatic symptoms, and lack of positive affect subscales were entered simultaneously into the model as predictors. Across two separate models, gray matter volume for vermal regions VI and VII functioned as the outcome variables.

2.5.4 *Exploratory Analysis 1*

Vermal regions of lobules VIII, IX, and crus I were examined in relation to total depressive symptom severity using a multiple regression model. The gray matter volumes of

vermal regions VIII, IX, and crus I were examined as the outcome variables across three separate models. Total CES-D symptom severity functioned as the predictor variable in all analyses.

2.5.5 Exploratory Analysis 2

Three multiple regression analyses were run to explore the relationships between vermal regions VIII, IX, and crus I and depressive symptoms dimensions. The depressed mood, somatic symptoms, and lack of positive affect CES-D subscales were entered simultaneously into each model as continuous outcome variables. In each model, the predictor variable was the gray matter volume of the cerebellar subregion (vermal VIII, IX, or crus I).

2.5.6 Exploratory Analysis 3

A multiple regression analysis was run to examine the relationship between anterior cerebellum (lobules I-IV) volume and total depressive symptoms, with total CES-D symptom severity as the predictor variable. An additional multiple regression analysis was run to examine the relationship between the anterior cerebellum and subscales of the CES-D. With the anterior cerebellum functioning as the predictor variable, the depressed mood, somatic symptoms, and lack of positive affect CES-D subscales were entered simultaneously into the model as continuous outcome variables.

2.5.7 Power Analysis

Two post-hoc power analyses were conducted using the program GPower (Erdfelder, Faul, & Buchner, 1996) in order to identify the current study's ability to detect significant relationships. With the sample size of 38 participants, the study is adequately powered ($1-\beta = .84$) to detect a large effect ($f = 2.88$) at the .05 alpha level when three predictors are included in the model, and the study is slightly underpowered ($1-\beta = .74$) to detect a large effect ($f = 2.51$) at the .05 alpha level when five predictors are included in the model.

3 RESULTS

3.1 Aim 1: Identify whether the gray matter volume of vermal regions VI and VII is predicted by depressive symptom severity.

Analyses revealed a positive relationship between total CES-D scores and vermis VI volume ($\beta = .378, p < .05, sr_3^2 = .139$). No significant relationship between vermis VII volume and total CES-D scores was detected (see Table 3.1).

Table 3.1 Results of Regression Analyses: Total CES-D Predicting Cerebellar Volumes

	Age			Sex			Total CES-D		
	β	t	p	β	t	p	β	t	p
Vermis VI	.104	.640	.527	.025	.155	.878	.378	2.348	.025*
Vermis VII	-.044	-.261	.796	-.053	-.316	.754	.227	1.346	.187
Vermis VIII	-.331	-2.137	.040*	.017	.113	.910	.276	1.793	.082
Vermis IX	-.208	-1.262	.215	-.035	-.212	.833	2.39	1.462	.153
Vermis Crus I	.176	1.025	.313	.126	.743	.463	-.017	-1.100	.921
Anterior CB	-.191	-1.222	.230	.313	2.031	.050*	.210	1.357	.184

Note. * = $p \leq .05$, ** = $p \leq .01$

3.2 Aim 2: Identify distinct relationships between cerebellar subregions, vermis VI and VII, and subthreshold symptom dimensions.

We observed a positive relationship between somatic symptom subscale scores and vermis VI volume ($\beta = .389, p < .05, sr_4^2 = .113$). No other subscales were significantly related to vermis VI volumes. Additionally, there were no significant relationships detected between vermis VII volume and CES-D subscales (see Table 3.2).

3.3 Exploratory Analysis 1.

Total CES-D score did not significantly predict vermis VIII, IX, or crus I volumes (see Table 3.1); however, age significantly predicted vermis VIII volume ($\beta = -.331, p < .05, sr_3^2 = .118$).

3.4 Exploratory Analysis 2.

Analyses revealed a positive relationship between the lack of positive affect subscale scores and vermis VIII volume ($\beta = .527, p < .01, sr_4^2 = .248$). No other significant relationships were found between Vermis VIII, Vermis IX, or Vermis Crus I volumes and CES-D subscales (see Table 3.2).

3.5 Exploratory Analysis 3.

The anterior cerebellum was not significantly related to total CES-D scores (see Table 3.1); however, sex significantly predicted anterior cerebellum volume ($\beta = .313, p = .05, sr_3^2 = .097$) in this model. Additionally, the anterior cerebellum did not have a significant relationship with any subscale of the CES-D (see Table 3.2), but sex significantly predicted anterior cerebellum volume ($\beta = .351, p < .05, sr_4^2 = .119$) in this model.

Table 3.2 Results of Regression Analyses: CES-D Subscales Predicting Cerebellar Volumes

	Age			Sex			Depressed Mood			Somatic Symptoms			Lack of Positive Affect		
	β	t	p	β	t	p	β	t	p	β	t	p	β	t	p
Vermis VI	.070	.409	.686	.045	.278	.783	.040	.213	.833	.389	2.094	.044*	.037	.215	.831
Vermis VII	- .020	-1.110	.913	-.055	-.313	.756	-.112	-.553	.584	.171	.859	.397	.137	.751	.458
Vermis VIII	- .283	- 1.924	.063	.029	.208	.836	-.017	-.107	.915	-.138	-.866	.393	.527	3.614	.001**
Vermis IX	- .253	- 1.468	.152	-.016	-.099	.922	.082	.433	.668	.297	1.595	.121	-.061	-.358	.723
Vermis Crus I	.128	.711	.482	.127	.737	.467	.072	.361	.720	.067	.343	.734	-.216	-1.209	.236
Anterior CB	- .234	- 1.478	.149	.351	2.325	.027*	.262	1.500	.144	-.059	-.345	.732	.254	1.618	.115

Note. * = $p \leq .05$, ** = $p \leq .01$

4 DISCUSSION

Over the past couple of decades, the posterior cerebellum, particularly the vermis, has been implicated in emotion processing (Habas et al., 2009; Stoodley & Schmahmann, 2009; Strick et al., 2009). Thus, the present study investigated the relationship between symptom dimensions of depression and subregions of the cerebellum in older adults with SubD. Broadly, results from our analyses indicate that the relationship between regions of the vermis and depressive symptoms differs depending on the types of depressive symptoms experienced by the participant. Given these findings, our hypotheses were partially supported.

We hypothesized that overall depressive symptom severity would be negatively related to both vermal region VI and VII volumes. Additionally, we hypothesized that vermis VI and VII would have distinctly different relationships with symptom dimensions of depression, as measured by subscales of our depression measure. Analyses revealed that total depressive symptoms were indeed associated with vermis VI volumes, but we observed larger rather than smaller volumes as a function of higher depressive symptoms. No relationship was found between vermis VII and total depressive symptoms. Analysis of the somatic symptoms, depressed mood, and lack of positive affect subscales suggested that this relationship was mostly driven by the somatic symptom subscale, as this was the only significant subscale in the regression model. Additionally, our exploratory analyses identified a positive relationship between vermis VIII volume and the lack of positive affect subscale scores. Thus, our hypothesis that regions of the vermis would have distinct relationships with depressive symptom subtypes was supported.

Given the consistent evidence to support the role of vermis VI in emotion processing (Depping et al., 2018; Habas et al., 2009; Stoodley & Schmahmann, 2009, 2018), it is not

surprising that our analyses found a relationship between vermis VI volume and total depressive symptom severity. In fact, Habas et al. (2009) have gone so far as to suggest that the vermis VI region of the cerebellum has a modulatory role in the subcortical aspects of the salience network, an intrinsic connectivity network disrupted in individuals with depression. The salience network is comprised of the dorsal anterior cingulate cortex, frontoinsula cortex, amygdala, and ventral striatum, and is responsible for the bottom-up detection of salient events as well as for facilitating attentional and executive resources when salient events are detected (for a review, see Wang, Ongur, Auerbach, & Yao, 2016). This network is important for depression because it facilitates experiences of pain and pleasure, and also determines the importance of both internal and external stimuli in order to guide behavior (Seeley et al., 2007).

Emerging evidence also supports that a major role of the salience network is to switch between the default mode and central executive networks, and that this switching capability is impaired in individuals with MDD (Sliz & Hayley, 2012; Wang et al., 2016). Additionally, the abnormal switching function of the salience network is related to the negative response bias in depression, which has been identified as a cognitive vulnerability of depression (Wang et al., 2016). Vermis VI has been found to be functionally involved in the salience network (Habas et al., 2009), and has been hypothesized to be recruited during primary emotion processing as well (Leggio & Olivito, 2018). Thus, the relationship between vermis VI and total depressive symptoms identified in the present study is consistent with the literature. Our additional finding that somatic symptoms were positively related to vermis VI adds to our understanding of this complex relationship between depressive symptoms and the cerebellar vermis. Given the heterogenous nature of the CES-D somatic symptoms subscale, which includes questions about apathy (e.g. “I could not get going”) and cognitive symptoms (e.g. “I had trouble keeping my

mind on what I was doing”), in addition to somatic complaints (e.g. “I did not feel like eating”), more research is needed to determine the vermis VI’s involvement in this particular cluster of symptoms.

The finding that the CES-D lack of positive affect subscale, which grossly measures symptoms related to anhedonia, is associated with larger vermis VIII volumes may in part be explained by vermis VIII’s functional connections to the amygdala (Depping et al., 2018; Leggio & Olivito, 2018; Sang et al., 2012). The amygdala is intimately related to depression through its role in both the affective/frontolimbic network, which is dysregulated in late-life depression (Tadayonnejad & Ajilore, 2014), as well as its role in the reward system, which has been found to be disrupted in patients with MDD (Gong et al., 2017). This is important, given that anhedonia can be characterized as dysfunction in the reward system leading to reduced emotional response to pleasurable events as well as a lack of engagement in goal-related behaviors (Hoflich, Michenthaler, Kasper, & Lanzenberger, 2019). In individuals with major depression, the amygdala has been shown to decrease the responsiveness of the reward (i.e., dopamine) system (Belujon & Grace, 2017), as well as have reduced intrinsic connectivity to the cerebellum (Ramasubbu et al., 2014). The amygdala has also been related to apathy, which is distinct from but related to anhedonia. For example, a study of depressed individuals with apathetic symptoms found reduced functional connectivity between the nucleus accumbens and the amygdala compared to depressed, non-apathetic patients (Alexopoulos et al., 2013b). Future research should explore the link between vermis VIII, anhedonia, and the amygdala.

While the bulk of the literature has identified smaller cerebellar volumes in relation to greater levels of depression, other brain regions have demonstrated a positive relationship between volume and depression. Higher levels of CES-D depressed mood subscale scores were

found to be related to larger volumes in the left posterior cingulate (McLaren et al., 2016) and left inferior temporal lobe (McLaren et al., 2017) among older adults with SubD. Additionally, greater volume in the left temporal lobe has also been associated with higher depressive symptoms (Ballmaier et al., 2004), as has increased volume in the middle temporal gyrus (Szymkowicz et al., 2016). Greater cortical thickness has also been identified in relation to depressive symptoms in both the dorsolateral prefrontal and anterior cingulate cortices (Dotson et al., 2015). Additionally, larger bilateral hippocampal regions (Bearden et al., 2009) as well as larger total hippocampal volumes (J. L. Phillips, Batten, Tremblay, Aldosary, & Blier, 2015) have been identified in adults with MDD. Perhaps most relevant to the current study, a study of patients experiencing an acute major depressive episode revealed that regardless of medication status, those experiencing MDD had larger left cerebellar lobule IX volumes than controls (Depping et al., 2016). Previous work from our lab has also indicated that greater total depression scores are associated with larger vermal VI and VII volumes in a small pilot sample (Michalak, King, Turner, Semmel, & Dotson, 2019). Thus, the positive relationships that the present study found between vermal volumes and depressive symptoms is not entirely unexpected.

The significance of larger vermal volumes in relation to depressive symptoms remains unclear. Some researchers have discussed the role of “inflammaging,” or the concept that aging is characterized by chronic, low-level inflammation (Franceschi & Campisi, 2014), and believe that this could be an underlying mechanism of depression in older adults (Alexopoulos & Morimoto, 2011). In support of this hypothesis, a meta-analysis by Dowlati et al. (2010) confirmed the presence of higher concentrations of proinflammatory cytokines in depressed participants compared to controls, which provides further evidence that the inflammatory

response system is activated among depressed individuals. The researchers hypothesized that inflammation in the hippocampus in particular may be a precursor to the smaller hippocampal volumes identified in depressed individuals as the disease progresses. Other research suggests that early stages of depression are associated with increased brain volume, possibly due to the increased metabolic activity and enhanced cerebral blood flow that occurs early on in the illness, which may then be responsible for volume loss at later stages of depression (Frodl et al., 2003).

Thus, it is possible that inflammation is linked to increased brain volume seen in early stages of depression. The present study's findings of larger vermis VI and VIII volumes in relation to higher depressive symptom load among older adults with SubD appears to provide support for this inflammation hypothesis of depression. Given that these findings were identified within a sample of adults with SubD, it is possible that our findings of larger vermis volumes, potentially due to inflammation, are precursors of the decreased volume that may occur as these individuals progress to major depression (Dowlati et al., 2010). Longitudinal research is needed to identify the changes in the brain that occur as older individuals progress from SubD to MDD.

The findings of the present study also support that there are unique relationships between symptom dimensions of depression and areas of the cerebellum. Given that the present study was sufficiently powered to detect only a large effect, the findings described in this article are robust. Importantly, the significant relationship between vermis VIII and the lack of positive affect subscale in the absence of a relationship between vermis VIII and total depressive symptom scores, supports that examining total depressive symptoms can obscure subtle relationships between symptom types and the brain. The present study also provides further evidence that the posterior vermis has a relationship with depression, even within a population with only

subthreshold depressive symptoms. Finally, these results add to our understanding of the neural correlates of SubD in an aging population.

These findings become significant when examined within the context of research identifying treatment profiles for depression with distinct etiologies. In particular, neurobiological markers of depression have been linked to types of depressive symptoms and the causes and consequences of depression have been shown to be different based on these symptomatic and neurobiological profiles. For example, a randomized controlled trial of a physical activity intervention in adults aged 70 to 89 years old found that treatment efficacy of the intervention on depressive symptoms varied by symptom type, sex and genotype (Dotson et al., 2016). Men who participated in the physical activity intervention, particularly men with the BDNF Met allele, experienced more decreases in somatic depressive symptoms compared to all other groups, while in comparison to women, men also experienced greater reductions in anhedonic symptoms of depression (Dotson et al., 2016).

Additionally, faster rates of symptom improvement in a trial of fluoxetine treatment were experienced by individuals with greater anterior cingulate cortex volume and functional activation at baseline (Chen et al., 2007). Increased anterior cingulate cortex activity in response to fearful faces pre-treatment has also been found to predict antidepressant response to ketamine (Salvadore et al., 2009). Likewise, distinct symptomatic and biological profiles have been found to affect transcranial magnetic stimulation treatment efficacy. In a study of medication treatment-resistant individuals with MDD, higher baseline anhedonia and lower connectivity in the classic reward pathway was predictive of a reduced treatment response (Downar et al., 2014). Thus, these studies point to the importance of identifying potential biomarkers of depression in order to inform treatment efficacy.

Given the current lack of effective treatment for late-life depression, it is important to examine the different etiologies of depression in order to develop a more precise understanding of how SubD symptoms interact with the brain. The present study indicates that specific areas of the cerebellar vermis are related to distinct symptoms of SubD. Given the heterogeneity of depressive symptomology, by identifying the neurobiological differences that underlie symptom profiles in depression, the field will become closer to developing effective, targeted treatments for individuals with depression.

4.1 Limitations

The present study is not without limitations. Given the small size of the sample, the study is powered only to detect a large effect. Additionally, the sample is highly educated, highly female, and highly Caucasian. In this way, our sample lacks generalizability and requires replication in a larger, more diverse community sample in order to better understand the relationship between the cerebellar vermis and dimensions of depression. Our sample also consisted of late-middle to older-aged adults. For a better understanding of the specific relationship between cerebellar volumes and symptoms of depression in late life, future research should be conducted with a more homogenous sample of adults specifically 65 years of age and older. Future research should also extend the present research question to individuals experiencing greater depressive symptom severity, given that this sample consisted of adults with SubD.

4.2 Conclusion

This study identified positive relationships between total depressive symptom severity and vermis VI volume, somatic symptom subscale severity and vermis VI volume, and lack of positive affect subscale severity and vermis VIII volume. These findings are important in that

they add to the literature identifying neurobiological correlates of depressive symptom dimensions, as well as provide further evidence for the role of the posterior vermis in depression specifically, and, more broadly, mood. By gaining a more precise understanding of the neurobiological correlates of depressive symptom profiles, these results may inform future targeted treatments for depression.

REFERENCES

- Adams, K. B., & Moon, H. (2009). Subthreshold depression: characteristics and risk factors among vulnerable elders. *Aging Ment Health, 13*(5), 682-692.
doi:10.1080/13607860902774501
- Alalade, E., Denny, K., Potter, G., Steffens, D., & Wang, L. (2011). Altered cerebellar-cerebral functional connectivity in geriatric depression. *PLoS One, 6*(5), e20035.
doi:10.1371/journal.pone.0020035
- Alexopoulos, G. S., Hoptman, M. J., Yuen, G., Kanellopoulos, D., Seirup, J., Lim, K. O., & Gunning, F. M. (2013a). Functional connectivity in apathy of late-life depression: a preliminary study. *J Affect Disord, 149*(0), 398-405. doi:10.1089/pho.2008.2318
- Alexopoulos, G. S., Hoptman, M. J., Yuen, G., Kanellopoulos, D., Seirup, J. K., Lim, K. O., & Gunning, F. M. (2013b). Functional connectivity in apathy of late-life depression: a preliminary study. *J Affect Disord, 149*(1-3), 398-405. doi:10.1016/j.jad.2012.11.023
- Alexopoulos, G. S., & Morimoto, S. S. (2011). The inflammation hypothesis in geriatric depression. *Int J Geriatr Psychiatry, 26*(11), 1109-1118. doi:10.1002/gps.2672
- Allan, C. L., Sexton, C. E., Filippini, N., Topiwala, A., Mahmood, A., Zsoldos, E., . . . Ebmeier, K. P. (2016). Sub-threshold depressive symptoms and brain structure: A magnetic resonance imaging study within the Whitehall II cohort. *J Affect Disord, 204*, 219-225.
doi:10.1016/j.jad.2016.06.049
- American Psychiatric Association. (2013). *Diagnostic and statistical manual of mental disorders*. Arlington, VA: American Psychiatric Publishing.

- Ballmaier, M., Sowell, E. R., Thompson, P. M., Kumar, A., Narr, K. L., Lavretsky, H., . . . Toga, A. W. (2004). Mapping brain size and cortical gray matter changes in elderly depression. *Biol Psychiatry, 55*(4), 382-389. doi:10.1016/j.biopsych.2003.09.004
- Baumann, O., & Mattingley, J. B. (2012). Functional topography of primary emotion processing in the human cerebellum. *Neuroimage, 61*(4), 805-811.
doi:10.1016/j.neuroimage.2012.03.044
- Bearden, C. E., Thompson, P. M., Avedissian, C., Klunder, A. D., Nicoletti, M., Dierschke, N., . . . Soares, J. C. (2009). Altered hippocampal morphology in unmedicated patients with major depressive illness. *ASN Neuro, 1*(4). doi:10.1042/AN20090026
- Beauregard, M., Leroux, J. M., Bergman, S., Arzoumanian, Y., Beaudoin, G., Bourgouin, P., & Stip, E. (1998). The functional neuroanatomy of major depression: an fMRI study using an emotional activation paradigm. - PubMed - NCBI. *Neuroreport, 9*(14), 3253-3258.
doi:10.1097/00001756-199810050-00022
- Belujon, P., & Grace, A. A. (2017). Dopamine System Dysregulation in Major Depressive Disorders. *Int J Neuropsychopharmacol, 20*(12), 1036-1046. doi:10.1093/ijnp/pyx056
- Blazer, D. G. (2003). Depression in late life: review and commentary. *J Gerontol A Biol Sci Med Sci, 58*(3), 249-265.
- Brailean, A., Comijs, H. C., Aartsen, M. J., Prince, M., Prina, A. M., Beekman, A., & Huisman, M. (2016). Late-life depression symptom dimensions and cognitive functioning in the Longitudinal Aging Study Amsterdam (LASA). *J Affect Disord, 201*(Sep 1), 171-178.
- Brandt, J., Spencer, M., & Folstein, M. (1988). The telephone interview for cognitive status. *Neuropsychiatry, Neuropsychology, & Behavioral Neurology, 1*, 111-117.

- Buckner, R. L., Krienen, F. M., Castellanos, A., Diaz, J. C., & Yeo, B. T. (2011). The organization of the human cerebellum estimated by intrinsic functional connectivity. *J Neurophysiol*, *106*(5), 2322-2345. doi:10.1152/jn.00339.2011
- Carleton, R. N., Thibodeau, M. A., Teale, M. J., Welch, P. G., Abrams, M. P., Robinson, T., & Asmundson, G. J. (2013). The center for epidemiologic studies depression scale: a review with a theoretical and empirical examination of item content and factor structure. *PLoS One*, *8*(3), e58067. doi:10.1371/journal.pone.0058067
- Chen, C. H., Ridler, K., Suckling, J., Williams, S., Fu, C. H., Merlo-Pich, E., & Bullmore, E. (2007). Brain imaging correlates of depressive symptom severity and predictors of symptom improvement after antidepressant treatment. *Biol Psychiatry*, *62*(5), 407-414. doi:10.1016/j.biopsych.2006.09.018
- Chopra, M. P., Zubritsky, C., Knott, K., Have, T. T., Hadley, T., Coyne, J. C., & Oslin, D. W. (2005). Importance of Subsyndromal Symptoms of Depression in Elderly Patients. *The American Journal of Geriatric Psychiatry*, *13*(7), 597-606. doi:10.1097/00019442-200507000-00008
- Corp, I. B. M. (2016). IBM SPSS Statistics Version 24.0.
- Cuijpers, P., Vogelzangs, N., Twisk, J., Kleiboer, A., Li, J., & Penninx, B. W. (2013). Differential mortality rates in major and subthreshold depression: meta-analysis of studies that measured both. *Br J Psychiatry*, *202*(1), 22-27. doi:10.1192/bjp.bp.112.112169
- Cuthbert, B. N. (2014). The RDoC framework : facilitating transition from ICD / DSM to dimensional approaches that integrate neuroscience and psychopathology. *World Psychiatry*, *13*(February), 28-55.

- Depping, M. S., Schmitgen, M. M., Kubera, K. M., & Wolf, R. C. (2018). Cerebellar Contributions to Major Depression. *Front Psychiatry, 9*, 634.
doi:10.3389/fpsy.2018.00634
- Depping, M. S., Wolf, N. D., Vasic, N., Sambataro, F., Hirjak, D., Thomann, P. A., & Wolf, R. C. (2016). Abnormal cerebellar volume in acute and remitted major depression. *Prog Neuropsychopharmacol Biol Psychiatry, 71*, 97-102. doi:10.1016/j.pnpbp.2016.06.005
- Diedrichsen, J. (2006). A spatially unbiased atlas template of the human cerebellum. *Neuroimage, 33*(1), 127-138. doi:10.1016/j.neuroimage.2006.05.056
- Diedrichsen, J., Balsters, J. H., Flavell, J., Cussans, E., & Ramnani, N. (2009). A probabilistic MR atlas of the human cerebellum. *Neuroimage, 46*(1), 39-46.
doi:10.1016/j.neuroimage.2009.01.045
- Diedrichsen, J., Maderwald, S., Kuper, M., Thurling, M., Rabe, K., Gizewski, E. R., . . . Timmann, D. (2011). Imaging the deep cerebellar nuclei: a probabilistic atlas and normalization procedure. *Neuroimage, 54*(3), 1786-1794.
doi:10.1016/j.neuroimage.2010.10.035
- Diedrichsen, J., & Zotow, E. (2015). Surface-Based Display of Volume-Averaged Cerebellar Imaging Data. *PLoS One, 10*(7), e0133402. doi:10.1371/journal.pone.0133402
- Diniz, B. S., Butters, M. A., Albert, S. M., Dew, M. A., & Reynolds, C. F., 3rd. (2013). Late-life depression and risk of vascular dementia and Alzheimer's disease: systematic review and meta-analysis of community-based cohort studies. *Br J Psychiatry, 202*(5), 329-335.
doi:10.1192/bjp.bp.112.118307

- Dotson, V. M., Beason-Held, L., Kraut, M. A., & Resnick, S. M. (2009). Longitudinal study of chronic depressive symptoms and regional cerebral blood flow in older men and women. *Int J Geriatr Psychiatry, 24*(8), 809-819. doi:10.1002/gps.2298
- Dotson, V. M., Davatzikos, C., Kraut, M. A., & Resnick, S. M. (2009). Depressive symptoms and brain volumes in older adults: a longitudinal magnetic resonance imaging study. *J Psychiatry Neurosci, 34*(5), 367-375.
- Dotson, V. M., Hsu, F. C., Langaee, T. Y., McDonough, C. W., King, A. C., Cohen, R. A., . . . Life Study, G. (2016). Genetic Moderators of the Impact of Physical Activity on Depressive Symptoms. *J Frailty Aging, 5*(1), 6-14. doi:10.14283/jfa.2016.76
- Dotson, V. M., Szymkowicz, S. M., Sozda, C. N., Kirton, J. W., Green, M. L., O'Shea, A., . . . Woods, A. J. (2015). Age Differences in Prefrontal Surface Area and Thickness in Middle Aged to Older Adults. *Front Aging Neurosci, 7*, 250. doi:10.3389/fnagi.2015.00250
- Dowlati, Y., Herrmann, N., Swardfager, W., Liu, H., Sham, L., Reim, E. K., & Lanctot, K. L. (2010). A meta-analysis of cytokines in major depression. *Biol Psychiatry, 67*(5), 446-457. doi:10.1016/j.biopsych.2009.09.033
- Downar, J., Geraci, J., Salomons, T. V., Dunlop, K., Wheeler, S., McAndrews, M. P., . . . Giacobbe, P. (2014). Anhedonia and reward-circuit connectivity distinguish nonresponders from responders to dorsomedial prefrontal repetitive transcranial magnetic stimulation in major depression. *Biol Psychiatry, 76*(3), 176-185. doi:10.1016/j.biopsych.2013.10.026
- Dunlop, B. W., Cole, S. P., Nemeroff, C. B., Mayberg, H. S., & Craighead, W. E. (2018). Differential change on depressive symptom factors with antidepressant medication and

- cognitive behavior therapy for major depressive disorder. *J Affect Disord*, 229, 111-119.
doi:10.1016/j.jad.2017.12.035
- Egger, K., Schocke, M., Weiss, E., Auffinger, S., Esterhammer, R., Goebel, G., . . . Marksteiner, J. (2008). Pattern of brain atrophy in elderly patients with depression revealed by voxel-based morphometry. *Psychiatry Res*, 164(3), 237-244.
doi:10.1016/j.psychres.2007.12.018
- Erdfelder, E., Faul, F., & Buchner, A. (1996). GPOWER: A general power analysis program. *Behavior Research Methods, Instruments, & Computers*, 28(1), 1-11.
doi:10.3758/bf03203630
- Escalona, P. R., Early, B., McDonald, W., Doraiswamy, P. M., Shah, S. A., Husain, M. M., . . . Krishnan, K. R. R. (1993). Reduction of cerebellar volume in major depression: a controlled MRI study. *Depression*, 1, 156-158.
- First, M. B., Spitzer, R. L., Gibbon, M., & Williams, J. B. W. (2002). *Structured clinical interview for DSM-IV-TR axis I Disorders, Research Version*. New York: Biometrics Research, New York State Psychiatric Institute.
- Fiske, A., Wetherell, J. L., & Gatz, M. (2009). Depression in older adults. *Annu Rev Clin Psychol*, 5, 363-389. doi:10.1146/annurev.clinpsy.032408.153621
- Franceschi, C., & Campisi, J. (2014). Chronic inflammation (inflammaging) and its potential contribution to age-associated diseases. *J Gerontol A Biol Sci Med Sci*, 69 Suppl 1, S4-9.
doi:10.1093/gerona/glu057
- Frodl, T., Meisenzahl, E. M., Zetsche, T., Born, C., Jager, M., Groll, C., . . . Moller, H. J. (2003). Larger amygdala volumes in first depressive episode as compared to recurrent major depression and healthy control subjects. *Biol Psychiatry*, 53(4), 338-344.

- Fujimoto, T., Takeuchi, K., Matsumoto, T., Fujita, S., Honda, K., Higashi, Y., & Kato, N. (2008). Metabolic changes in the brain of patients with late-onset major depression. *Psychiatry Res, 164*(1), 48-57. doi:10.1016/j.psychresns.2007.03.010
- Geerlings, M. I., & Heijer, T. D. (2008). History of depression , depressive symptoms , and medial temporal lobe atrophy and the risk of Alzheimer disease.
- Gellis, Z. D. (2010). Assessment of a brief CES-D measure for depression in homebound medically ill older adults. *J Gerontol Soc Work, 53*(4), 289-303. doi:10.1080/01634371003741417
- Gomez, R., & McLaren, S. (2015). The Center for Epidemiological Studies Depression Scale: Measurement and structural invariance across ratings of older adult men and women. *Personality and Individual Differences, 75*, 130-134. doi:10.1016/j.paid.2014.11.005
- Gong, L., Yin, Y., He, C., Ye, Q., Bai, F., Yuan, Y., . . . Zhang, Z. (2017). Disrupted reward circuits is associated with cognitive deficits and depression severity in major depressive disorder. *J Psychiatr Res, 84*, 9-17. doi:10.1016/j.jpsychires.2016.09.016
- Grieve, S. M., Korgaonkar, M. S., Koslow, S. H., Gordon, E., & Williams, L. M. (2013). Widespread reductions in gray matter volume in depression. *Neuroimage Clin, 3*, 332-339. doi:10.1016/j.nicl.2013.08.016
- Grisanzio, K. A., Goldstein-Piekarski, A. N., Wang, M. Y., Ahmed, A. P. R., Samara, Z., & Williams, L. M. (2018). Transdiagnostic symptom clusters and associations with brain, behavior, and daily function in mood, anxiety, and trauma disorders. *JAMA Psychiatry, 75*(2), 201-209. doi:10.1001/jamapsychiatry.2017.3951

- Gündel, H., O'Connor, M. F., Littrell, L., Fort, C., & Lane, R. D. (2003). Functional neuroanatomy of grief: An fMRI study. *American Journal of Psychiatry*, *160*(11), 1946-1953. doi:10.1176/appi.ajp.160.11.1946
- Habas, C. (2018). Research note: a resting-state, cerebello-amygdaloid intrinsically connected network. *Cerebellum Ataxias*, *5*, 4. doi:10.1186/s40673-018-0083-0
- Habas, C., Kamdar, N., Nguyen, D., Prater, K., Beckmann, C. F., Menon, V., & Greicius, M. D. (2009). Distinct cerebellar contributions to intrinsic connectivity networks. *J Neurosci*, *29*(26), 8586-8594. doi:10.1523/JNEUROSCI.1868-09.2009
- Haringsma, R., Engels, G. I., Beekman, A. T., & Spinhoven, P. (2004). The criterion validity of the Center for Epidemiological Studies Depression Scale (CES-D) in a sample of self-referred elders with depressive symptomatology. *Int J Geriatr Psychiatry*, *19*(6), 558-563. doi:10.1002/gps.1130
- Hickie, I. B., Naismith, S. L., Ward, P. B., Scott, E. M., Mitchell, P. B., Schofield, P. R., . . . Parker, G. (2007). Serotonin transporter gene status predicts caudate nucleus but not amygdala or hippocampal volumes in older persons with major depression. *J Affect Disord*, *98*(1-2), 137-142. doi:10.1016/j.jad.2006.07.010
- Hoflich, A., Michenthaler, P., Kasper, S., & Lanzenberger, R. (2019). Circuit Mechanisms of Reward, Anhedonia, and Depression. *Int J Neuropsychopharmacol*, *22*(2), 105-118. doi:10.1093/ijnp/pyy081
- Huang, H., Menezes, P. R., da Silva, S. A., Tabb, K., Barkil-Oteo, A., & Scazufca, M. (2014). The association between depressive disorders and health care utilization: results from the Sao Paulo ageing and health study (SPAH). *Gen Hosp Psychiatry*, *36*(2), 199-202. doi:10.1016/j.genhosppsy.2013.11.003

- Hwang, J. W., Xin, S. C., Ou, Y. M., Zhang, W. Y., & Liang, Y. L. (2016). Enhanced default mode network connectivity with ventral striatum in subthreshold depression individuals. *Journal of psychiatric ...*, 111-120. doi:10.1016/j.jpsychires.2016.02.005.Enhanced
- Hybels, C. F., Blazer, D. G., & Pieper, C. F. (2001). Toward a threshold for subthreshold depression: an analysis of correlates of depression by severity of symptoms using data from an elderly community sample. *The Gerontologist*, 41(3), 357-365. doi:10.1093/geront/41.3.357
- Insel, T., Cuthbert, B., Garvey, M., Heinssen, R., & Pine, D. (2010). Research Domain Criteria (RDoC): Toward a New Classification Framework for Research on Men. *The American Journal of Psychiatry*, 167(7), 748-751.
- Jeuring, H. W., Huisman, M., Comijs, H. C., Stek, M. L., & Beekman, A. T. (2016). The long-term outcome of subthreshold depression in later life. *Psychol Med*, 46(13), 2855-2865. doi:10.1017/S0033291716001549
- Joel, I., Begley, A. E., Mulsant, B. H., Lenze, E. J., Dew, M. A., Blumberger, D., . . . Team, I. (2014). Dynamic prediction of treatment response in late-life depression. *Am J Geriatr Psychiatry*, 22(2), 167-176. doi:10.1016/j.jagp.2012.07.002.DYNAMIC
- Kaiser, R. H., Andrews-Hanna, J. R., Wager, T. D., & Pizzagalli, D. A. (2015). Large-Scale Network Dysfunction in Major Depressive Disorder: A Meta-analysis of Resting-State Functional Connectivity. *JAMA Psychiatry*, 72(6), 603-611. doi:10.1001/jamapsychiatry.2015.0071
- Kales, H. C., & Valenstein, M. (2002). Complexity in late-life depression: impact of confounding factors on diagnosis, treatment, and outcomes. *J Geriatr Psychiatry Neurol*, 15(3), 147-155. doi:10.1177/089198870201500306

- Karsten, J., Penninx, B. W., Verboom, C. E., Nolen, W. A., & Hartman, C. A. (2013). Course and risk factors of functional impairment in subthreshold depression and anxiety. *Depress Anxiety, 30*(4), 386-394. doi:10.1002/da.22021
- Kelly, R. M., & Strick, P. L. (2003). Cerebellar loops with motor cortex and prefrontal cortex of a nonhuman primate. *J Neurosci, 23*(23), 8432-8444.
- Kumar, A., Jin, Z., Bilker, W., Udupa, J., & Gottlieb, G. (1998). Late-onset minor and major depression : early evidence for common neuroanatomical substrates detected by using MRI. *Proc. Natl. Acad. Sci. USA, 95*(June), 7654-7658.
- Kumar, A., Schweizer, E., Zhisong, J., Miller, D., Bilker, W., Swan, L. L., & Gottlieb, G. (1997). Neuroanatomical Substrates of Late-Life Minor Depression. *Arch Neurol, 54*, 613-617.
- Laborde-Lahoz, P., El-Gabalawy, R., Kinley, J., Kirwin, P. D., Sareen, J., & Pietrzak, R. H. (2015). Subsyndromal depression among older adults in the USA: prevalence, comorbidity, and risk for new-onset psychiatric disorders in late life. *Int J Geriatr Psychiatry, 30*(7), 677-685. doi:10.1002/gps.4204
- Lane, R. D., Reiman, E. M., Bradley, M. M., Lang, P. J., Ahern, G. L., Davidson, R. J., & Schwartz, G. E. (1997). Neuroanatomical correlates of pleasant and unpleasant emotion. *Neuropsychologia, 35*(11), 1437-1444. doi:10.1016/S0028-3932(97)00070-5
- Lee, M. J., Hasche, L. K., Choi, S., Proctor, E. K., & Morrow-Howell, N. (2013). Comparison of major depressive disorder and subthreshold depression among older adults in community long-term care. *Aging Ment Health, 17*(4), 461-469. doi:10.1080/13607863.2012.747079
- Leggio, M., & Olivito, G. (2018). Topography of the cerebellum in relation to social brain regions and emotions. *Handb Clin Neurol, 154*, 71-84. doi:10.1016/B978-0-444-63956-1.00005-9

- Lener, M. S., Kundu, P., Wong, E., Dewilde, K. E., Tang, C. Y., Balchandani, P., & Murrrough, J. W. (2016). Cortical abnormalities and association with symptom dimensions across the depressive spectrum. *J Affect Disord, 190*, 529-536. doi:10.1016/j.jad.2015.10.027
- Levisohn, L., Cronin-Golomb, A., & Schmahmann, J. D. (2000). Neuropsychological consequences of cerebellar tumour resection in children. Cerebellar cognitive affective syndrome in a paediatric population. *Brain, 123*(5), 1041-1050.
doi:10.1093/brain/123.5.1041
- Lewinsohn, P. M., Seeley, J. R., Roberts, R. E., & Allen, N. B. (1997). Center for Epidemiologic Studies Depression Scale (CES-D) as a screening instrument for depression among community-residing older adults. *Psychol Aging, 12*(2), 277-287.
- Li, H., Wei, D., Sun, J., Chen, Q., Zhang, Q., & Qiu, J. (2015). Brain structural alterations associated with young women with subthreshold depression. *Sci Rep, 5*, 9707.
doi:10.1038/srep09707
- Li, R., Ma, Z., Yu, J., He, Y., & Li, J. (2014). Altered local activity and functional connectivity of the anterior cingulate cortex in elderly individuals with subthreshold depression. *Psychiatry Res, 222*(1-2), 29-36. doi:10.1016/j.psychresns.2014.02.013
- Lux, V., & Kendler, K. S. (2010). Deconstructing major depression: a validation study of the DSM-IV symptomatic criteria. *Psychol Med, 40*(10), 1679-1690.
doi:10.1017/S0033291709992157
- Machino, A., Kunisato, Y., Matsumoto, T., Yoshimura, S., Ueda, K., Yamawaki, Y., . . . Yamawaki, S. (2014). Possible involvement of rumination in gray matter abnormalities in persistent symptoms of major depression: an exploratory magnetic resonance imaging

voxel-based morphometry study. *J Affect Disord*, 168, 229-235.

doi:10.1016/j.jad.2014.06.030

McLaren, M. E., Szymkowicz, S. M., O'Shea, A., Woods, A. J., Anton, S. D., & Dotson, V. M. (2016). Dimensions of depressive symptoms and cingulate volumes in older adults.

Transl Psychiatry, 6, e788. doi:10.1038/tp.2016.49

McLaren, M. E., Szymkowicz, S. M., O'Shea, A., Woods, A. J., Anton, S. D., & Dotson, V. M. (2017). Vertex-wise examination of depressive symptom dimensions and brain volumes in older adults. *Psychiatry Res Neuroimaging*, 260, 70-75.

doi:10.1016/j.psychres.2016.12.008

Meeks, T., Vahia, I., Lavretsky, H., Kulkarni, G., & Jeste, D. (2011). A Tune in “A Minor” Can “B Major”: A Review of Epidemiology, Illness Course, and Public Health Implications of Subthreshold Depression in Older Adults. *Journal of Affective Disorders*, 129(1-3), 126-142. doi:10.1016/j.jad.2010.09.015.A

Michalak, H. R., King, T. Z., Turner, J. A., Semmel, E. S., & Dotson, V. M. (2019). *Dimensions of Depression and Cerebellar Subregion Volumes in Older Adults: A Pilot Study*. Paper presented at the International Neuropsychological Society Conference, New York, NY.

Naismith, S. L., Norrie, L. M., Mowszowski, L., & Hickie, I. B. (2012). The neurobiology of depression in later-life: Clinical, neuropsychological, neuroimaging and pathophysiological features. *Progress in Neurobiology*, 98(1), 99-143.

doi:10.1016/j.pneurobio.2012.05.009

O'Shea, D. M., Dotson, V. M., Woods, A. J., Porges, E. C., Williamson, J. B., O'Shea, A., & Cohen, R. (2018). Depressive Symptom Dimensions and Their Association with

- Hippocampal and Entorhinal Cortex Volumes in Community Dwelling Older Adults. *Front Aging Neurosci*, 10, 40. doi:10.3389/fnagi.2018.00040
- Palazidou, E. (2012). The neurobiology of depression. *Br Med Bull*, 101, 127-145. doi:10.1093/bmb/lds004
- Phillips, J. L., Batten, L. A., Tremblay, P., Aldosary, F., & Blier, P. (2015). A Prospective, Longitudinal Study of the Effect of Remission on Cortical Thickness and Hippocampal Volume in Patients with Treatment-Resistant Depression. *Int J Neuropsychopharmacol*, 18(8). doi:10.1093/ijnp/pyv037
- Phillips, J. R., Hewedi, D. H., Eissa, A. M., & Moustafa, A. A. (2015). The cerebellum and psychiatric disorders. *Front Public Health*, 3, 66. doi:10.3389/fpubh.2015.00066
- Pillay, S. S., Yurgelun-todd, D. A., Bonello, C. M., Lafer, B., Fava, M., & Renshaw, P. F. (1997). A Quantitative Magnetic Resonance Imaging Study of Cerebral and Cerebellar Gray Matter Volume in Primary Unipolar Major Depression : Relationship to Treatment Response and Clinical Severity. *i*.
- Pizzagalli, D. A., Oakes, T. R., Fox, A. S., Chung, M. K., Larson, C. L., Abercrombie, H. C., . . . Davidson, R. J. (2004). Functional but not structural subgenual prefrontal cortex abnormalities in melancholia. *Mol Psychiatry*, 9(4), 325, 393-405. doi:10.1038/sj.mp.4001469
- Radloff, L. S. (1977). The CES-D scale: A self-report depression scale for research in the general population. *Applied Psychological Measurement*, 1(30), 385-401.
- Ramasubbu, R., Konduru, N., Cortese, F., Bray, S., Gaxiola, I., & Goodyear, B. (2014). Reduced Intrinsic Connectivity of Amygdala in Adults with Major Depressive Disorder. *Frontiers in Psychiatry*, 5(17). doi:10.3389/fpsy.2014.00017

Reiman, E. M., Raichle, M. E., Robins, E., Mintun, M. A., Fusselman, M. J., Fox, P. T., . . .

Hackman, K. A. (1989). Neuroanatomical Correlates of a Lactate-Induced Anxiety Attack. *Archives of General Psychiatry*, *46*(6), 493-500.

doi:10.1001/archpsyc.1989.01810060013003

Salvadore, G., Cornwell, B. R., Colon-Rosario, V., Coppola, R., Grillon, C., Zarate, C. A., Jr., &

Manji, H. K. (2009). Increased anterior cingulate cortical activity in response to fearful faces: a neurophysiological biomarker that predicts rapid antidepressant response to ketamine. *Biol Psychiatry*, *65*(4), 289-295. doi:10.1016/j.biopsych.2008.08.014

Sang, L., Qin, W., Liu, Y., Han, W., Zhang, Y., Jiang, T., & Yu, C. (2012). Resting-state

functional connectivity of the vermal and hemispheric subregions of the cerebellum with both the cerebral cortical networks and subcortical structures. *Neuroimage*, *61*(4), 1213-1225. doi:10.1016/j.neuroimage.2012.04.011

Schmahmann, J. D. (1991). An emerging concept: the cerebellar contribution to higher function.

Arch Neurol, *48*(November), 1178-1187.

Schmahmann, J. D., & Sherman, J. C. (1997). Cerebellar cognitive affective syndrome. *Int Rev*

Neurobiol, *41*, 443-440.

Schmahmann, J. D., & Sherman, J. C. (1998). The cerebellar cognitive affective syndrome.

Brain, *121*, 561-579. doi:10.1093/brain/121.4.561

Schmahmann, J. D., Weilburg, J. B., & Sherman, J. C. (2007). The neuropsychiatry of the

cerebellum - insights from the clinic. *Cerebellum*, *6*(3), 254-267.

doi:10.1080/14734220701490995

Schraa-Tam, C. K., Rietdijk, W. J., Verbeke, W. J., Dietvorst, R. C., van den Berg, W. E.,

Bagozzi, R. P., & De Zeeuw, C. I. (2012). fMRI activities in the emotional cerebellum: a

- preference for negative stimuli and goal-directed behavior. *Cerebellum*, 11(1), 233-245.
doi:10.1007/s12311-011-0301-2
- Seeley, W. W., Menon, V., Schatzberg, A. F., Keller, J., Glover, G. H., Kenna, H., . . . Greicius, M. D. (2007). Dissociable intrinsic connectivity networks for salience processing and executive control. *J Neurosci*, 27(9), 2349-2356. doi:10.1523/JNEUROSCI.5587-06.2007
- Shah, S. A., Doraiswamy, P. M., Husain, M. M., Escalona, P. R., Na, C., Figiel, G. S., . . . et al. (1992). Posterior fossa abnormalities in major depression: a controlled magnetic resonance imaging study. *Acta Psychiatr Scand*, 85(6), 474-479.
- Shakiba, A. (2014). The Role of the Cerebellum in Neurobiology of Psychiatric Disorders. *Neuro Clin*, 32, 1105-1115.
- Singer, T., Seymour, B., O'Doherty, J., Kaube, H., Dolan, R., & Frith, C. (2004). Empathy for pain involves the affective but not sensory components of pain. *303*(FEBRUARY), 1157-1163.
- Singh-Manoux, A., Akbaraly, T. N., & Marmot, M. (2010). Persistent depressive symptoms and cognitive function in late midlife: the Whitehall II study. *J Clin Psychiatry*, 71, 1379-1385.
- Sliz, D., & Hayley, S. (2012). Major depressive disorder and alterations in insular cortical activity: a review of current functional magnetic imaging research. *Front Hum Neurosci*, 6, 323. doi:10.3389/fnhum.2012.00323
- Steffens, D. C., Taylor, W. D., Denny, K. L., Bergman, S. R., & Wang, L. (2011). Structural integrity of the uncinate fasciculus and resting state functional connectivity of the ventral

- prefrontal cortex in late life depression. *PLoS One*, 6(7), e22697.
doi:10.1371/journal.pone.0022697
- Stoodley, C. J., & Schmahmann, J. D. (2009). Functional topography in the human cerebellum: A meta-analysis of neuroimaging studies. *Neuroimage*, 44(2), 489-501.
doi:10.1016/j.neuroimage.2008.08.039
- Stoodley, C. J., & Schmahmann, J. D. (2010). Evidence for topographic organization in the cerebellum of motor control versus cognitive and affective processing. *Cortex*, 46(7), 831-844. doi:10.1016/j.cortex.2009.11.008.Evidence
- Stoodley, C. J., & Schmahmann, J. D. (2018). Functional topography of the human cerebellum. *Handb Clin Neurol*, 154, 59-70. doi:10.1016/B978-0-444-63956-1.00004-7
- Strick, P. L., Dum, R. P., & Fiez, J. A. (2009). Cerebellum and nonmotor function. *Annu Rev Neurosci*, 32, 413-434. doi:10.1146/annurev.neuro.31.060407.125606
- Stubbs, B., Stubbs, J., Gnanaraj, S. D., & Soundy, A. (2016). Falls in older adults with major depressive disorder (MDD): a systematic review and exploratory meta-analysis of prospective studies. *Int Psychogeriatr*, 28(1), 23-29. doi:10.1017/s104161021500126x
- Szymkowicz, S. M., Dotson, V. M., McLaren, M. E., De Wit, L., O'Shea, D. M., Talty, F. T., . . . Woods, A. J. (2017). Precuneus abnormalities in middle-aged to older adults with depressive symptoms: An analysis of BDI-II symptom dimensions. *Psychiatry Res Neuroimaging*, 268, 9-14. doi:10.1016/j.psychresns.2017.08.002
- Szymkowicz, S. M., McLaren, M. E., Kirton, J. W., O'Shea, A., Woods, A. J., Manini, T. M., . . . Dotson, V. M. (2016). Depressive symptom severity is associated with increased cortical thickness in older adults. *Int J Geriatr Psychiatry*, 31(4), 325-333. doi:10.1002/gps.4324

- Tadayonnejad, R., & Ajilore, O. (2014). Brain network dysfunction in late-life depression: a literature review. *J Geriatr Psychiatry Neurol*, 27(1), 5-12.
doi:10.1177/0891988713516539
- Taki, Y., Kinomura, S., Awata, S., & Inoue, K. (2005). Male elderly subthreshold depression patients have smaller volume of medial part of prefrontal cortex and precentral gyrus compared with age-matched normal subjects : A voxel-based morphometry. 88, 313-320.
doi:10.1016/j.jad.2005.08.003
- Tamburo, R. J., Siegle, G. J., Stetten, G. D., Cois, C. A., Butters, M. A., Reynolds, C. F., 3rd, & Aizenstein, H. J. (2009). Amygdalae morphometry in late-life depression. *Int J Geriatr Psychiatry*, 24(8), 837-846. doi:10.1002/gps.2167
- Taylor, W. D., Steffens, D. C., McQuoid, D. R., Payne, M. E., Lee, S. H., Lai, T. J., & Krishnan, K. R. R. (2003). Smaller orbital frontal cortex volumes associated with functional disability in depressed elders. *Biological Psychiatry*, 53(2), 144-149. doi:10.1016/S0006-3223(02)01490-7
- Vrieze, E., Demyttenaere, K., Bruffaerts, R., Hermans, D., Pizzagalli, D. A., Sienaert, P., . . . Claes, S. (2014). Dimensions in major depressive disorder and their relevance for treatment outcome. *J Affect Disord*, 155, 35-41. doi:10.1016/j.jad.2013.10.020
- Wang, X., Ongur, D., Auerbach, R. P., & Yao, S. (2016). Cognitive Vulnerability to Major Depression: View from the Intrinsic Network and Cross-network Interactions. *Harv Rev Psychiatry*, 24(3), 188-201. doi:10.1097/HRP.0000000000000081
- Welsh, K. A., Breitner, J. C. S., & Mgruder-Habib, K. M. (1993). Detection of dementia in the elderly using telephone screening of cognitive status. *Neuropsychiatry, Neuropsychology, & Behavioral Neurology*, 6, 103-110.

World Health Organization: Depression. (2017). Retrieved from

<http://www.who.int/mediacentre/factsheets/fs369/en/>

Wuthrich, V. M., Johnco, C. J., & Wetherell, J. L. (2015). Differences in anxiety and depression symptoms: comparison between older and younger clinical samples. *Int Psychogeriatr*, 27(9), 1523-1532. doi:10.1017/S1041610215000526

Zhou, H., Li, R., Ma, Z., Rossi, S., Zhu, X., & Li, J. (2016). Smaller gray matter volume of hippocampus/parahippocampus in elderly people with subthreshold depression: a cross-sectional study. *BMC Psychiatry*, 16, 219. doi:10.1186/s12888-016-0928-0

APPENDIX

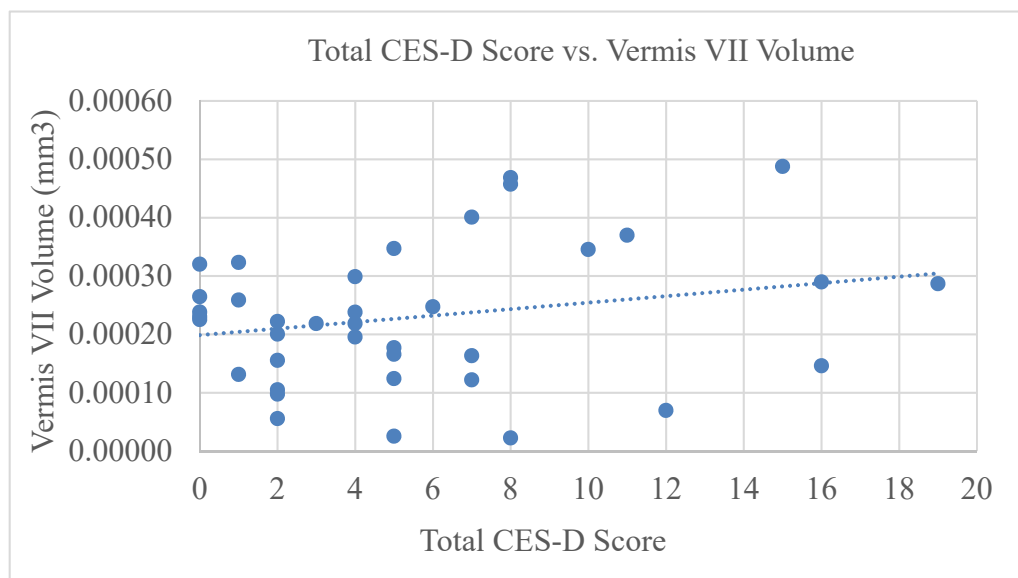
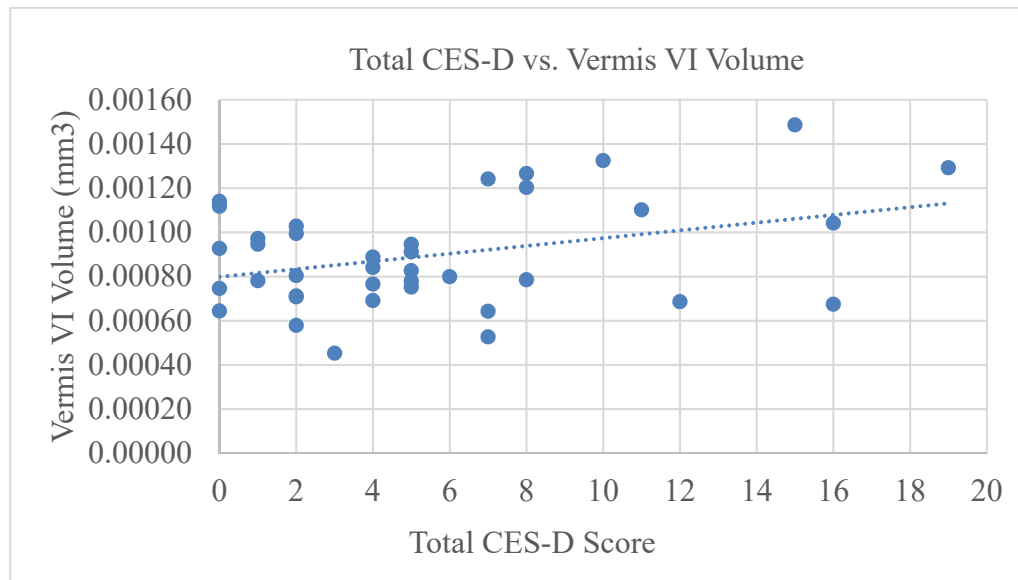


Figure 1. Aim 1 Regression Analyses.

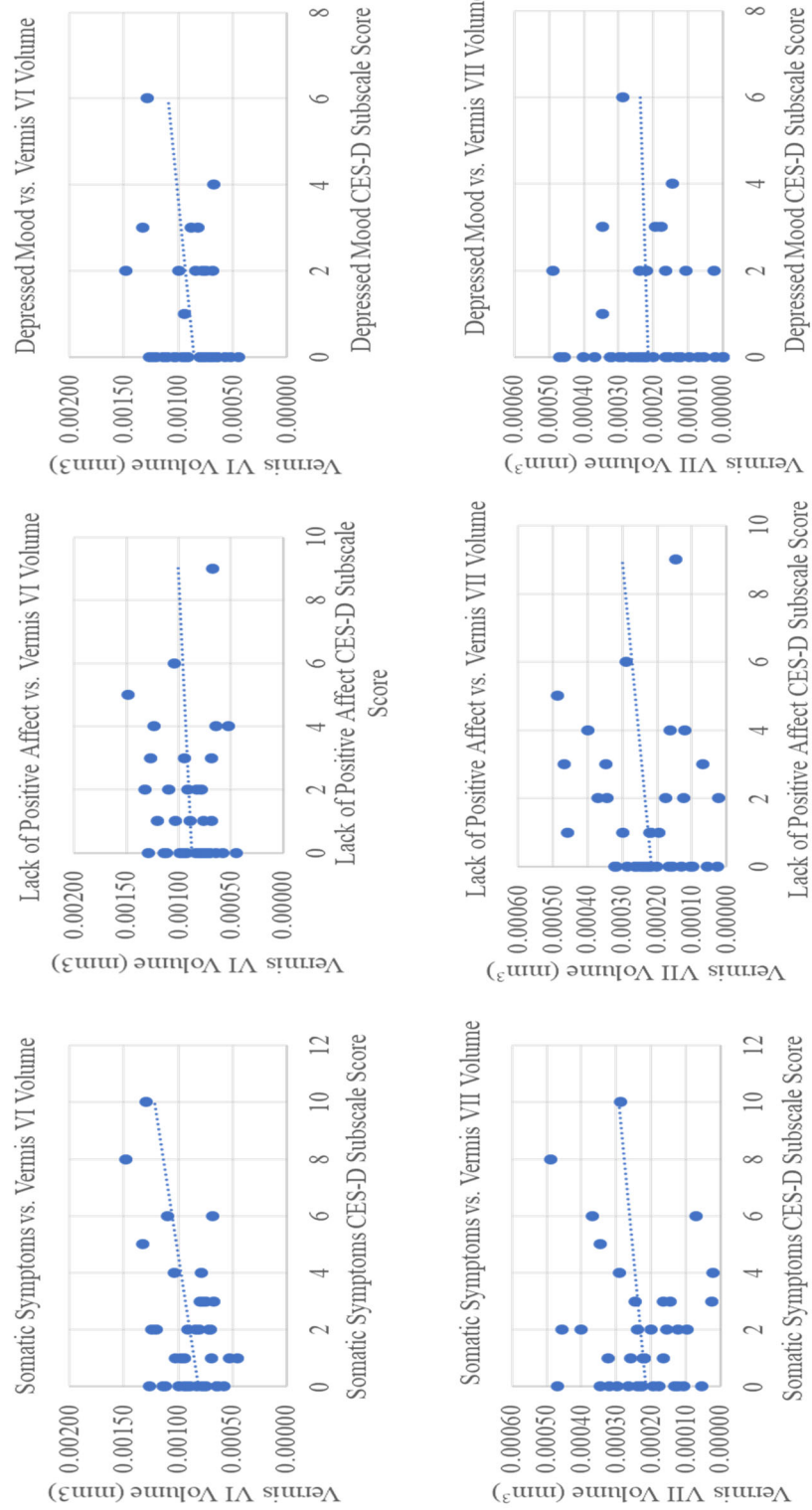


Figure 2. Aim 2 Regression Analyses.