

## Original article

## Blau syndrome: cross-sectional data from a multicentre study of clinical, radiological and functional outcomes

Carlos D. Rosé<sup>1</sup>, Steven Pans<sup>2</sup>, Ingele Casteels<sup>3</sup>, Jordi Anton<sup>4</sup>, Brigitte Bader-Meunier<sup>5</sup>, Philippe Brissaud<sup>6</sup>, Roland Cimaz<sup>7</sup>, Graciella Espada<sup>8</sup>, Jorge Fernandez-Martin<sup>9</sup>, Eric Hachulla<sup>10</sup>, Miroslav Harjacek<sup>11</sup>, Raju Khubchandani<sup>12</sup>, Friederike Mackensen<sup>13</sup>, Rosa Merino<sup>14</sup>, Antonio Naranjo<sup>15</sup>, Sheila Oliveira-Knupp<sup>16</sup>, Christine Pajot<sup>17</sup>, Ricardo Russo<sup>18</sup>, Caroline Thomée<sup>19</sup>, Sebastiaan Vastert<sup>20</sup>, Nico Wulffraat<sup>21</sup>, Juan I. Arostegui<sup>22</sup>, Kevin P. Foley<sup>23</sup>, John Bertin<sup>23</sup> and Carine H. Wouters<sup>24</sup>

## Abstract

**Objective.** To report baseline articular, functional and ocular findings of the first international prospective cohort study of Blau syndrome (BS).

**Methods.** Three-year, multicentre, observational study on articular, functional (HAQ, Childhood HAQ and VAS global and pain), ophthalmological, therapeutic and radiological data in BS patients.

**Results.** Baseline data on the first 31 recruited patients (12 females and 19 males) from 18 centres in 11 countries are presented. Of the 31 patients, 11 carried the p.R334W *NOD2* mutation, 9 the p.R334Q and 11 various other *NOD2* missense mutations; 20 patients were sporadic and 11 from five BS pedigrees. Median disease duration was 12.8 years (1.1–57). Arthritis, documented in all but one patient, was oligoarticular in 7, polyarticular in 23. The median active joint count was 21. Functional capacity was normal in 41%, mildly impaired in 31% and moderate–severe in 28% of patients. The most frequently involved joints at presentation were wrists, ankles, knees and PIPs. On radiographs, a symmetrical non-erosive arthropathy was shown. Previously unknown dysplastic bony changes were found in two-thirds of patients. Ocular disease was documented in 25 of 31 patients, with vitreous inflammation in 64% and moderate–severe visual loss in 33%. Expanded manifestations (visceral, vascular) beyond the classic clinical triad were seen in 52%.

**Conclusion.** BS is associated with severe ocular and articular morbidity. Visceral involvement is common and may be life-threatening. Bone dysplastic changes may show diagnostic value and suggest a

<sup>1</sup>Pediatrics, Nemours/Alfred I. duPont Hospital for Children, Wilmington, DE, USA, <sup>2</sup>Department of Radiology, <sup>3</sup>Department of Ophthalmology, Catholic University of Leuven (KU Leuven), Leuven, Belgium, <sup>4</sup>Unidad de Reumatología Pediátrica, Universidad de Barcelona, Barcelona, Spain, <sup>5</sup>Unité d'Immunologie, Hématologie et Rhumatologie Pédiatrique, Hôpital Necker-Enfants Malades, Inserm U 768, Imagine Foundation, Paris, <sup>6</sup>Rheumatology Practice, Neuilly-sur-Seine, France, <sup>7</sup>Dipartimento di Pediatria, Università degli Studi di Firenze, Firenze, Italy, <sup>8</sup>Sección Reumatología, Universidad de Buenos Aires, Buenos Aires, Argentina, <sup>9</sup>Fundación Biomédica Galicia Sur Hospital Meixoeiro, Hospital do Meixoeiro, Vigo, Spain, <sup>10</sup>Service de Médecine Interne, Hôpital Claude Huriez, Lille, France, <sup>11</sup>Department of Rheumatology, University of Zagreb, Zagreb, Croatia, <sup>12</sup>Department of Paediatrics, Jaslok Hospital, Mumbai, India, <sup>13</sup>Interdisciplinary Uveitis Center, Universitat Klinikum Heidelberg, Heidelberg, Germany, <sup>14</sup>Unidad de Reumatología Pediátrica, Hospital La Paz, Madrid, <sup>15</sup>Servicio de Reumatología, Hospital de Gran Canarias Dr Negrin, Las Palmas, Spain, <sup>16</sup>Instituto de Puericultura e Pediatría Martagao Gesteira (IPPMG), Universidad Federal do Rio de Janeiro, Rio de

Janeiro, Brazil, <sup>17</sup>Pédiatrie – Néphrologie, Médecine Interne et Hypertension, Hôpital des Enfants, Toulouse, France, <sup>18</sup>Servicio de Immunología/Reumatología, University of Buenos Aires, Buenos Aires, Argentina, <sup>19</sup>Pediatric Clinic, Centre Hospitalier de Luxembourg, Luxembourg, Luxembourg, <sup>20</sup>Division of Pediatrics, <sup>21</sup>Department of Pediatric Immunology and Rheumatology, UMC Utrecht, Utrecht, The Netherlands, <sup>22</sup>Department of Immunology-CDB, Hospital Clinic Barcelona, Spain, <sup>23</sup>Pattern Recognition Receptor Discovery Performance Unit, Immuno-inflammation Therapeutic Area, GlaxoSmithKline, Collegeville, Pennsylvania, USA and <sup>24</sup>Department of Pediatric Rheumatology, Catholic University of Leuven (KU Leuven), Leuven, Belgium

Submitted 13 May 2014; revised version accepted 16 September 2014

Correspondence to: Carine H. Wouters, Department of Pediatric Rheumatology, UZ Leuven Gasthuisberg, Herestraat 49, 3000 Leuven, Belgium. E-mail: carine.wouters@uzleuven.be

previously unknown role of NOD2 in bone morphogenesis. BS is resistant to current drugs, suggesting the need for novel targeted therapies.

**Key words:** Blau syndrome, sarcoidosis, NOD2, uveitis.

#### Rheumatology key messages

- Blau syndrome patients may show articular activity beyond 10 years and visceral/vascular involvement in 50%.
- Blau syndrome patients showed moderate/severe visual impairment in 1/3 and functional impact in 1/2.
- Radiological features of Blau arthritis include post-inflammatory and previously undescribed morphological bony changes.

## Introduction

Blau syndrome (BS) and early-onset sarcoidosis are respectively the familial and sporadic forms of a dominantly inherited granulomatous autoinflammatory disease that results from mutations in or near the nucleotide oligomerization domain of the NOD2 pattern recognition receptor [1–6]. Our knowledge of the phenotype of BS has evolved since the early descriptive series, mainly thanks to diagnostic genetic testing [4–7]. Classically associated with the clinical triad of arthritis, dermatitis and uveitis, systemic features, vasculitis and the involvement of various organs/systems have become widely recognized in patients with BS [8–20]. Furthermore, the clinical diversity of BS has become evident from the recent description of patients carrying disease-causing *NOD2* mutations, but lacking the classic clinical triad [21]. At present, BS is considered to be one of the monogenic systemic autoinflammatory diseases.

To date, all studies on BS have been either short case series or multicentre registries [22, 23] based on retrospectively collected data. The natural history of BS and its functional consequences remain largely unknown. As our knowledge of the putative pathogenic pathways underlying BS progresses, we also need to prospectively collect data on prognosis, natural history and the evolution of articular, ocular and visceral symptoms. Given the rarity of BS, this can only be achieved via a multicentre collaborative effort.

We are reporting herein the baseline results of a prospective international study collecting patient history, clinical and functional assessments, and radiological and standardized ophthalmological evaluations using widely used evaluation tools on the baseline visit from the first 31 recruited BS patients. This article contains a combination of historical data and cross-sectional evaluations including physical and functional assessments, ophthalmological evaluation, and radiological data. To date, this is the first and largest comprehensive analysis of BS featuring a prospective study design.

## Patients and methods

Investigators who participated in the Pediatric Granulomatous Arthritis International Registry and

members of paediatric rheumatology societies (PREs, Eurofever, PRINTO and the paediatric section of ACR) were invited to join in this 3-year observational study. Ethics committee or institutional review board approval was obtained at the coordinating centre (University of Leuven) and all participating sites.

Patients with BS and proven *NOD2* mutations [22, 24] were included after informed consent had been obtained. Standardized data collection forms included descriptions of triad (arthritis, dermatitis and uveitis) and expanded manifestations, as well as medication use. The investigators were asked to report on the efficacy of treatments at the time using the following categories: complete response, partial response or failure. Articular assessment comprised the number of active and limited joints assessed by a paediatric or adult rheumatologist using the 75-joint count score. The presence of deformities (micrognathia, swan neck, boutonnière, camptodactyly, brachydactyly, genu valgus or other) was also recorded. Patient-reported functional status via the Childhood HAQ (CHAQ) or HAQ, and 100 mm VAS for pain and global status of well-being were collected. For the CHAQ, parent reporting was used for patients aged  $\leq 9$  years. A single-view wrist and hand X-ray was obtained. All plain films were scored for specific radiological features by a musculoskeletal radiologist (S.P.). Radiographic features were divided into two categories: arthritis-related features and morphological changes. Arthritis-related radiological signs considered were soft tissue swelling, periarticular osteopenia, joint space narrowing, bony ankylosis, epiphyseal overgrowth and erosions. For children, the Poznanski score was measured [25]. X-rays of healthy age-matched children were used as controls. A comprehensive ophthalmological evaluation was obtained within a month of each study visit by the patient's treating ophthalmologist. Standardization of Uveitis Nomenclature (SUN) classification was used to grade anterior uveitis.

Assessment of response to therapy was performed for articular, ocular and expanded manifestations as part of a *post hoc* analysis. At the time of the baseline visit, patients with  $\geq 3$  months of drug exposure were classified as responders or non-responders according to the findings at the baseline visit. For articular disease, if one or more swollen joints was present, the patient was deemed to

be a non-responder. For eye disease, if cells in the anterior chamber, active vitritis or active retinal inflammation were present, the patient was deemed to be a non-responder. As for the patient's expanded manifestation, analysis was based on the investigator's input according to a request for a narrative of the evolution of the manifestation.

Descriptive statistics were used to report the data, and the Mann-Whitney *U*-test was used to compare datasets. VAS scores were converted to a 0–3 score by multiplying each VAS value by a factor of 0.03. Next, the CHAQ, HAQ and VAS well-being and pain scores were divided into four categories of severity [26]: none (0), mild ( $>0$  to  $\leq 0.5$ ), moderate ( $>0.5$  to  $\leq 1.5$ ) and severe ( $>1.5$ ). To facilitate comparisons, visual acuity was converted into logMAR units by calculating the  $-\log$  of the visual acuity in the decimal Snellen scale in metres. Normal visual acuity is defined by a logMAR of 0.0–0.5, moderate visual impairment from 0.6 to 1.0 and severe visual loss from  $>1.0$ . Median and absolute range were used for description (see Results section).

## Results

### Demographic and genetic data

This study included 31 patients (12 females and 19 males) from 18 centres in 11 countries. Of the 31 patients, 23 were recruited from the Pediatric Granulomatous Arthritis International Registry and 8 through rheumatology societies. It was found that 11 patients were carrying heterozygous p.R334W *NOD2* mutations, 9 heterozygous p.R334Q mutations, and the remaining 11 patients a variety of different *NOD2* mutations (E600K, Y563S, M513T, A755V, G481D, T605P, G464W and C495Y). Twenty individuals had a sporadic form of the disease, while the remaining 11 patients belonged to five distinct BS pedigrees. The study included 18 children and 13 adults, with a median age at baseline evaluation of 16.5 years (range 1.9–58). Median disease duration was 12.8 years (range 1.1–57). Median age at onset of joint disease was 2 years (range 3 months to 13 years) and eye disease was 4.4 years (range 6 months to 22 years) ( $P < 0.001$ , Mann-Whitney *U*-test). The median age at onset of skin rash was 1.1 years (range 2 months to 20 years).

### Cutaneous manifestations

Based on case histories at the baseline visits for this study, the classical BS rash was described in a total of 25 patients. The appearance of this rash varied from predominantly papuloerythematous (five patients), mild scaly eczematoid (eight patients), tan-coloured mildly scaly (eight patients) to ichthyosiform (four patients). The second most common cutaneous manifestation was erythema nodosum (four patients). One patient had a leucocytoclastic vasculitis.

### Articular findings

Articular involvement was documented in all but one patient. Arthritis onset was oligoarticular in 7 and

polyarticular in 23 patients. In the latter group, the median joint count at onset was 15 (range 5–57). The most commonly affected joints at presentation were wrists (87%), knees (73%), ankles (63%) and PIP (53%). One-third of patients had involvement of MCPs and/or elbows. Rarely involved joints at onset were hips (9%), spine (6%) and TM joints (3%). At baseline evaluation, articular disease was active in 21 patients (70%) after a median evolution of 12.8 years. The median active joint count at the baseline visit [2, interquartile range (IQR) 7] was significantly lower than the joint count at presentation (15, IQR 14) ( $P < 0.001$ , Mann-Whitney *U*-test), suggesting improvement of arthritis activity. At their baseline evaluation, 81% of patients had limited joints, with a median limited joint count of 6 (IQR 14), and 53% of patients had deformities, with a median number of deformed joints of 8 (IQR 8). The most common deformities were noted at the PIP joints, with camptodactyly observed in 19 patients. Of the 19 patients with  $> 10$  years of active disease at baseline, 13 patients still had active arthritis with a median joint count of 5 (IQR 10).

### Functional outcomes

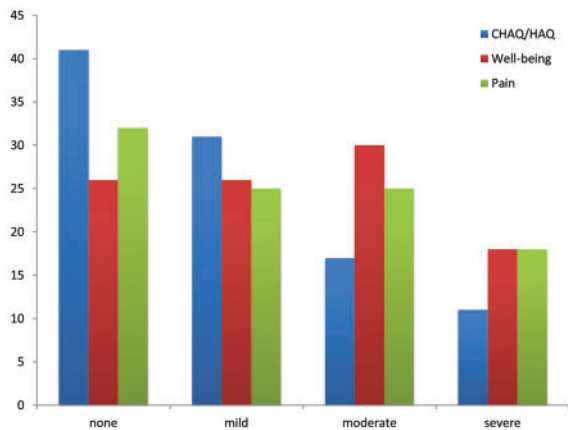
Functional capacity, as assessed by CHAQ and HAQ, showed normal function in 41% of patients, mild impairment in 31%, moderate in 17% and severe in 11%. Median VAS scores for well-being and pain were 15 (IQR 39) and 13 (IQR 48), respectively. Almost half of BS patients (48%) reported a moderate to severe impact of the disease on their global well-being, while 26% of patients reported no impact. Similarly, moderate to severe pain was reported by 43% of patients and 32% experienced no pain. Fig. 1 shows the distribution of BS patients according to categories of function, well-being and pain.

### Radiographic findings

Plain radiographs of hands and wrists of 13 children (aged between 5.9 and 16 years) and 11 adults were reviewed. Typical arthritis-related features were symmetrical in both children and adults and are summarized in Table 1.

Dysplastic changes are shown in Figs 2 and 3. They include camptodactyly (flexion contracture in PIP joints), carpal dysplasia with carpal crowding (changes in shape and position affecting bones in the proximal carpal row) not due to narrowing, an abnormal distal radial epiphysis with a biconcave articular surface (prominent bony ridge in contact with the scapholunate joint), an abnormal shape of the distal ulna (plump ulna), a short ulna and abnormal shape of the second metacarpal bone (long small diaphysis). In children, radiographic camptodactyly, carpal dysplasia, biconcave radius, plump ulna and abnormal shape of the second metacarpal were seen in 59%, 68%, 64%, 32% and 32%, respectively. In adults, the same bone deformities were seen at higher frequencies, specifically 63%, 88%, 100%, 81% and 63%. The average Poznanski index in all paediatric patients increased from 9% to 24% compared with an age-matched control group ( $P < 0.05$ ).

**Fig. 1** Percentages of patients (y-axis) in the various groups of functional severity utilizing converted units of CHAQ/HAQ and VASs as described in Patients and methods



The CHAQ/HAQ data are for 29 patients, the VAS on well-being for 27 patients and the VAS on pain for 28 patients. Individual patients fall into separate severity groups for different variables.

**TABLE 1** Arthritis-related findings in X-rays of hands and wrists in Blau syndrome, expressed as percentages (total of 45 hands)

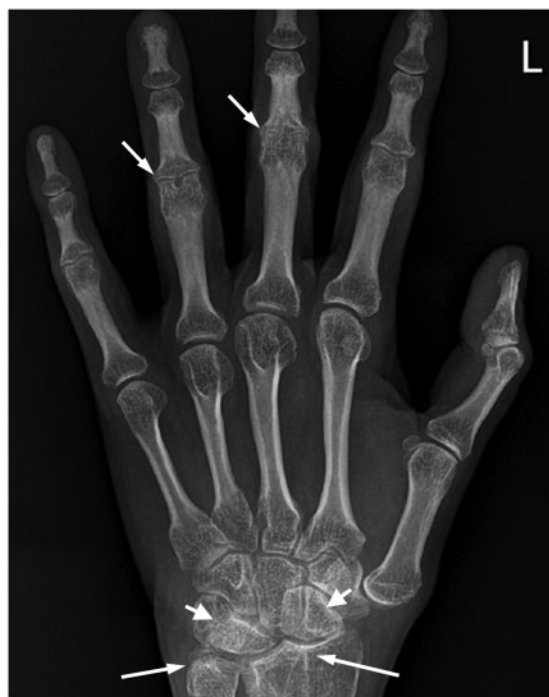	Soft tissue swelling		Joint space narrowing Erosions	
	Osteopenia			
DIP	0	36	9	0
PIP	2	78	56	0
MCP	0	80	9	0
Phalanges	2	0	0	0
Metacarpal	0	0	0	0
CMC	0	62	22	0
Carpal	0	64	47	0
Radiocarpal	0	40	38	0
DRUJ	0	13	29	0
Radius	0	0	0	0
Ulna	0	0	0	0

DRUJ: distal radioulnar joint.

### Ophthalmological findings

A total of 25 patients (81%) had ocular involvement, with 96% (24/25) exhibiting bilateral disease. Anterior uveitis was seen in all patients and was associated with posterior involvement in 72%. Intermediate uveitis was observed in 52% of patients. After a median disease duration of 12.1 years (range 0.75–53), 36% of patients had anterior uveitis activity, 64% had active vitreous inflammation, 18% showed active chorioretinitis and 5% had active retinal vasculopathy. Complication rates for anterior involvement were synechiae in 64%, cataracts in 55%, band

**Fig. 2** BS-related radiological findings in a representative adult patient (38 years)



Diffuse peri-articular osteopenia and joint space narrowing in the PIP and wrist joints (short arrows). Dysplasia of the scaphoid and lunate bone (arrowhead). Associated biconcave radial epiphysis and abnormal plump distal ulna (longarrows) were typical of the Blau hand.

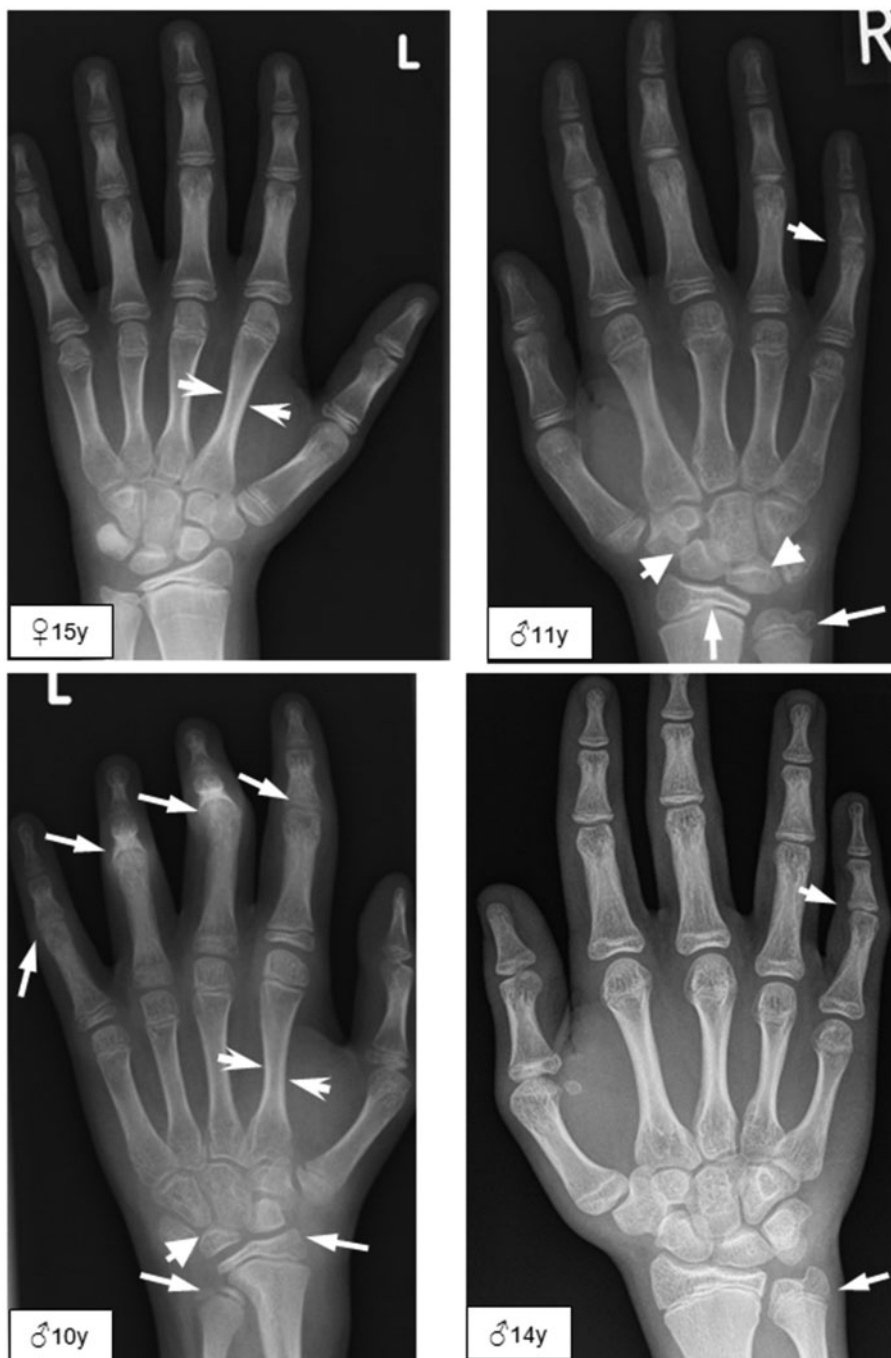keratopathy in 23% and increased intraocular pressure in 36%. Posterior disease sequelae included optic atrophy and macular oedema in 14% and retinal detachment in 9% of cases. Visual acuity data in 22 of 25 patients showed a mean decimal Snellen for corrected visual acuity of 7.2 (range 0.1–10) for the right eye and 6.5 (range 0.5–10) for the left. Using the logMAR scale, 68% of patients had normal acuity, with 18% and 14% showing moderate and severe visual loss, respectively.

### Expanded manifestations

Clinical manifestations beyond the classical triad included systemic, vascular and visceral organ involvement and were observed in 16 of the 31 patients (52%). Of these 16 patients, 14 exhibited the three triad components, 1 had only cutaneous components and 1 only joint disease. Table 2 shows the clinical characteristics of the expanded manifestations.

### Medication use at baseline visit

Systemic medication was being administered to 30 patients, with 70% receiving a combination of immunosuppressive drugs and/or biologic therapy with systemic corticosteroids. Table 3 lists the anti-inflammatory and

**FIG. 3** BS-related radiological features in four children

Plain films of hands and wrists showing typical morphological changes including: (i) rotation and pseudo-collapse of the lunate and scaphoid bone (arrowheads in upper right and lower left panels); (ii) different grades of dysplasia of ulnar and radial epimetaphysis (biconcave shape) (long arrows in upper right and lower left panels); (iii) ulnar shortening, from subtle to severe grade (long arrows in upper right, lower left and lower right panels); and (iv) long and small diaphysis of the MC2 (sharp arrow in upper and lower left panels). Note the presence of osteopenia in hands and wrists. In one child, the PIP-contracture is present in four fingers (long arrows in lower left panel). In other children, camptodactyly and carpal dysplasia are more subtle.

**TABLE 2** Clinical description and *NOD2* mutations observed in 16 patients with expanded manifestations

Patient	<i>NOD2</i> mutation	Expanded manifestations
4	R334Q	GL
5	R334Q	Transient facial palsy
6	R334Q	ILD, pulmonary embolism (single episode)
7	R334Q	Hepatomegaly (hepatic granuloma), GL (granulomatous), ILD, sialadenitis, EN
9	R334Q	HT
10	R334W	HT, GL
13	R334W	Recurrent fever, GL
14	R334W	Recurrent fever, GL, interstitial nephritis (granulomatous)
16	A755V	Recurrent fever, EN, HT, ILD, interstitial nephritis
17	G481D	GL, splenomegaly (required splenectomy), ILD, transient facial palsy, HT, ischaemic stroke, nephrocalcinosis
19	R334W	EN
21	E383K	GL, hepatomegaly, splenomegaly
24	G464W	HT, large vessel vasculitis (Takayasu's-like), hepatomegaly
25	C495Y	Hepatitis (granulomatous), splenomegaly
27	R334W	ILD, nephrocalcinosis
28	R334Q	Recurrent fever, EN, leucocytoclastic vasculitis, interstitial and glomerulonephritis (granulomatous)

HT: hypertension; EN: erythema nodosum; GL: generalized lymphadenopathy; ILD: interstitial lung disease.

immunosuppressive drugs for all patients, as well as the judgement of their actual efficacy on articular, ocular and expanded manifestations. All patients had at least 3 months of exposure to the current treatment at baseline.

## Discussion

We herein describe data from baseline visits for a prospective cohort study set up to better understand the natural history of BS. This multicentre study involved direct examination of 31 patients with documented *NOD2* mutations by rheumatologists and ophthalmologists utilizing a standardized clinical report form, and constitutes the largest prospectively assembled study to date on BS.

Inflammatory eye disease in BS is frequent and most often involves both the uveal tract and the posterior segment. In the present study, uveitis was seen more frequently than in a previous retrospective BS registry [17]. In a Canadian cohort of 1081 JIA patients focusing on ocular involvement, Saurenman *et al.* [27] found uveitis in only 13.1% of all JIA patients and in 12.5% of patients with polyarticular JIA ( $n=256$ ). In our study, more than one-third of BS patients manifested active anterior uveitis, with a median disease duration of 12.1 years. Posterior involvement was seen in 72% of patients, but was not seen in any of the 142 JIA patients in the Canadian series, while vitreous involvement was seen in only 3.5%. Although the different lengths of follow-up have to be taken into account, the frequency of anterior uveitis complications in our study exceed those of the Canadian study with frequencies for synechiae, cataracts, glaucoma and band keratopathy being twice as high. Macular oedema was found in 14% of BS patients compared with 4.9% of the Canadian patients [27]. Moderate or severe visual loss was seen in 32% of our patients

compared with 13% of the JIA cohort. In one study, worse visual impairment was linked to the p.R334W *NOD2* mutation [28], whereas in our study, we found no specific *NOD2* mutations associated with more severe visual impairment ( $\log\text{MAR} > 0.5$ ).

The characteristics of arthritis in BS, comprising boggy synovitis and tenosynovitis, are distinct from those observed in both JIA and RA. We found a differential pattern of joint involvement, with very rare involvement of axial joints, hips and TM joints. We noted radiographic features in BS patients that are different from those in JIA and RA. Whereas periarticular osteopenia and joint space narrowing typically involving the PIPs and carpal joints were relatively frequent, the most distinguishing feature observed in our cohort was the virtual absence of marginal erosions, notably including patients with longstanding arthritis. Different from adult RA is the rarity of severe MCP joint involvement as well. The presence of a symmetrical non-erosive arthritis could help recognition of BS when evaluating a patient with suspected RA. The virtual absence of epiphyseal overgrowth (data not shown) may help to differentiate the Blau hand from a polyarticular JIA hand.

This is the first report to document a number of radiological dysplastic changes that contribute to a typical Blau hand. Of interest is the high frequency and early onset of camptodactyly, a contracture virtually limited to the PIP joints, which has been previously described as a clinical characteristic in early reports [4, 7] and documented as a radiological feature in 48% of young and 64% of adult patients in our study. This deformity is the most consistent contracture found in all BS patients. It should be noted that camptodactyly is reported in association with more than 180 recognized genetic syndromes [from Online Mendelian Inheritance in Man (OMIM)]. Further, previously

**TABLE 3** Medication use: anti-inflammatory and immunosuppressive drugs and responses at baseline for different disease manifestations

Patient	Systemic drugs	Topical steroids	Articular control	Ocular control	Expanded disease resolved
1	—	Yes	Yes	No	NA
2	MTX, CS	No	No	NA	NA
3	MTX	No	No	NA	NA
4	MTX, CS	Yes	No	No	No
5	A, MTX, CS	Yes	No	No	Yes
6	CS	No	No	Yes	Yes
7	CS, I	No	No	No	Yes
8	I	Yes	No	No	NA
9	CS, A	Yes	No	No	Yes
10	CS, A	Yes	No	No	Yes
11	MTX	NA	No	NA	NA
12	CS, MTX, C	Yes	Yes	No	NA
13	A, MTX	Yes	No	No	Yes
14	MTX, CS, A	Yes	No	No	Yes
15	MTX, A	Yes	Yes	No	NA
16	MTX, A	NA	NA	NA	Yes
17	Th, CS	Yes	No	No	No
18	MTX, A	Yes	Yes	No	NA
19	CS, A	Yes	No	No	No
20	MTX, A	Yes	No	No	NA
21	I	Yes	Yes	Yes	Yes
22	MTX, I	No	Yes	No	NA
23	CS	Yes	No	No	NA
24	CS, MTX	NA	Yes	NA	No
25	CS	No	No	No <sup>a</sup>	No <sup>b</sup>
26	MTX, A	No	Yes	Yes	NA
27	CS, MTX, A	Yes	No	No	Yes
28	CS, MMF	No	No	No	No <sup>c</sup>
29	CS, A	No	No	No	NA
30	CS	NA	No	NA	NA
31	MTX	No	No	No	NA

CS: systemic corticosteroids; I: Infliximab; A: adalimumab; C: canakinumab; TH: thalidomide; NA: manifestation not present. <sup>a</sup>Had end-stage eye disease. <sup>b</sup>Hepatomegaly resolved, splenomegaly persisted. <sup>c</sup>Fever persisted.

unrecognized dysplastic findings include an abnormal morphology of the bones of the first carpal row (seen in 91% of the adult patients), a biconcave radial distal epiphysis, a plump distal ulna, and a long thin diaphysis of the second metacarpal bone. The underlying mechanism for these changes is unclear, yet in view of their presence in both young and adult patients, we suspect they are not a consequence of post-inflammatory bone remodelling. Dysplastic bone changes are described in chronic infantile neurological cutaneous articular/neonatal onset multisystem inflammatory disease (CINCA/NOMID) syndrome, a dominantly inherited autoinflammatory disorder associated with gain of function mutations in the *NLRP3* gene, encoding cryopyrin, a protein that shares both structural and functional characteristics with NOD2 [29]. In CINCA/NOMID syndrome, enlargement of the non-ossified portion of the physis is followed by splaying and

cupping of the metaphysis, with later calcification of a paraphyseal mass. A role for cryopyrin in chondrocyte apoptosis has been suggested [30]. Although the dysplastic changes observed in BS are less severe and rather epiphyseal than metaphyseal, they could well be the result of abnormal pathways in bone or cartilage morphogenesis in which NOD2 may have a role.

This study is also the first to look at functional capacity in a cohort of patients with BS. The functional status of these patients was not dissimilar to that found in a cross-sectional study of 21 polyarticular JIA patients cared for at a tertiary centre [31]. In fact, the value for moderate or severe CHAQ/HAQ was 33% in JIA, while for BS it was 37.8%. Overall, well-being was moderately or severely impaired in 30% of the JIA group and more frequently impaired in 49% of our BS cohort, while moderate to severe pain perception was 35% for JIA and 43% for the BS cohort [31].

Although arthritis, uveitis and dermatitis are the diagnostic bedrock for the clinician at disease onset, with increasing awareness of and availability of genetic testing, several non-triad manifestations of BS have been documented in recent years [8–23]. We reported an expanded phenotype in one-third of patients in a retrospective study [17]. Here, probably as a result of more intensive and standardized data collection, we found expanded manifestations in 48% of BS patients. Physicians caring for BS patients should be aware of the possibility of visceral involvement, as well as the possibility of large vessel vasculitis with potential life-threatening course. The present cohort included one child whose main manifestation was a Takayasu's-like arteritis [21]. Fatal pulmonary hypertension has been observed in one case (not in this cohort) by one of the authors (C.D.R.), and severe systemic hypertension was found in >20% of the present cohort. The underlying mechanism is probably multicausal. Of the five patients with hypertension, two have some form of renal disease (one interstitial nephritis and one nephrocalcinosis) and one developed large vessel vasculitis (Takayasu's-like) with involvement of the renal artery. In one patient, whose hypertension began at the age of 5 years, there was no large vessel involvement by digital angiography and no renal disease. We hypothesized a form of intermediate-sized vasculopathy of the kidney; his response to angiotensin-converting enzyme inhibitors was dramatic. The other patient developed hypertension at the age of 40 years and continues to be exposed to chronic use of corticosteroids to control severe eye disease. Also fever, lymphadenopathy and hepatosplenomegaly were relatively frequent and mostly clustered in the same patients. BS presents as a systemic inflammatory illness suggestive of systemic JIA, as has been reported earlier by Arostegui *et al.* [23].

More than two-thirds of BS patients received medical therapy, often combining systemic steroids, immunosuppressive and/or biologic drugs. Despite this, up to 70% of patients had evidence of active arthritis, 61% had vitreous inflammation and 35% had active anterior uveitis at evaluation. TNF- $\alpha$  inhibition was the most commonly used

therapy, which seemingly helps in achieving partial control of articular disease. The role of IL-1 and IL-1 blockade in BS is unclear. Arostegui *et al.* [23] found clinical improvement and downregulation of plasma cytokines in one patient treated with anakinra, and more recently Simonini *et al.* [32] reported effectiveness for posterior uveitis with canakinumab. Martin *et al.* [33] also found no response to anakinra in one BS patient with ocular disease.

To our knowledge, this is the largest collection of BS patients reported to date and providing a combination of retrospective and prospectively collected clinical, ophthalmological and radiological data. Since the disease course of BS is prolonged, the baseline data offer comprehensive information on the natural course of the disease to the point of inception. An additional advantage of this prospective cohort is that it will offer the possibility of assessing the impact of ongoing treatments on disease progression. We acknowledge that reliance on retrospective collection of physical findings at onset based on record review is a weakness of this study; hence, comparisons between baseline and onset status should be interpreted with caution. As the study continues during the next few years, the robustness of the data on the natural history of the disease is expected to increase.

In conclusion, our study confirms that BS is associated with severe ocular and articular morbidity. Systemic illness and visceral involvement are common and may be life-threatening. A novel finding described in this study was the presence of bone dysplastic changes in affected hands, the mechanism for which needs further study. BS seems to be resistant to currently available therapies in many patients, suggesting that early intervention and the development of novel therapies will be paramount in altering the course of the disease.

## Acknowledgements

We wish to express our gratitude to Ms Marleen Jannis and to Ms Anne Maes, MBS, for excellent administrative support and editorial work with the manuscript, and to Janice Connor for her organizational contribution to this project.

**Funding:** This work was supported in part by an unrestricted grant from GlaxoSmithKline awarded to C.W.

**Disclosure statement:** C.D.R. was awarded a Grant to Study Blau Syndrome from the University of Leuven. J.B. is an employee of GlaxoSmithKline with stock ownership. K.P.F. is an employee and shareholder of GlaxoSmithKline. C.H.W. received an unrestricted grant from GlaxoSmithKline to carry out the work described here. F.M. has received lecture honoraria from Heidelberg Eng, MSD; has provided consultancy services for Merck Serono and Abbvie; and has received grants/research support from Allergan, Santen, Servier and AbbVie. All other authors have declared no conflicts of interest.

## References

- Miceli-Richard C, Lesage S, Rybojad M *et al.* *CARD15* mutations in Blau syndrome. *Nat Genet* 2001;29:19–20.
- Kanazawa N, Okafuji I, Kamble N *et al.* Early onset sarcoidosis and *CARD 15* mutations with constitutive nuclear factor- $\kappa$ B activation: common genetic etiology with Blau syndrome. *Blood* 2005;105:1195–7.
- Rose CD, Doyle TM, McIlvain-Simpson G *et al.* Blau syndrome mutation of *CARD15/NOD2* in sporadic early onset granulomatous arthritis. *J Rheumatol* 2005;32:373–5.
- Blau EB. Familial granulomatous arthritis, iritis, and rash. *J Pediatr* 1985;107:689–93.
- Jabs DA, Houk JL, Bias WB, Arnett FC. Familial granulomatous synovitis, uveitis, and cranial neuropathies. *Am J Med* 1985;78:801–4.
- North AF Jr, Fink CW, Gibson WM *et al.* Sarcoid arthritis in children. *Am J Med* 1970;48:449–55.
- Pastores GM, Michels VV, Stickler GB. Autosomal dominant granulomatous arthritis, uveitis, skin rash, and synovial cysts. *J Pediatr* 1990;117:403–8.
- Ting SS, Ziegler J, Fischer E. Familial granulomatous arthritis (Blau syndrome) with granulomatous renal lesions. *J Pediatr* 1998;133:450–2.
- Saini SK, Rose CD. Liver involvement in familial granulomatous arthritis (Blau syndrome). *J Rheumatol* 1996;23:396–9.
- Hafner R, Vogel P. Sarcoidosis of early onset. A challenge for the pediatric rheumatologist. *Clin Exp Rheumatol* 1993;11:685–91.
- Rotenstein D, Gibbas DL, Majmudar B, Chastain EA. Familial granulomatous arteritis with polyarthritis of juvenile onset. *N Engl J Med* 1982;306:86–90.
- Gedalia A, Shetty AK, Ward K *et al.* Abdominal aortic aneurysm associated with childhood sarcoidosis. *J Rheumatol* 1996;23:757–9.
- Gross KR, Malleson PN, Culham G *et al.* Vasculopathy with renal artery stenosis in a child with sarcoidosis. *J Pediatr* 1986;108:724–6.
- Rose CD, Eichenfield AH, Goldsmith DP, Athreya BH. Early onset sarcoidosis with aortitis—“juvenile systemic granulomatosis?”. *J Rheumatol* 1990;17:102–6.
- Fink CW, Cimaz R. Early onset sarcoidosis: not a benign disease. *J Rheumatol* 1997;24:174–7.
- Coutant R, Leroy B, Niaudet P *et al.* A. Renal granulomatous sarcoidosis in childhood: a report of 11 cases and a review of the literature. *Eur J Pediatr* 1999;158:154–9.
- Rose CD, Arostegui JI, Martin TM *et al.* NOD-2-associated pediatric granulomatous arthritis (PGA) an expanding phenotype: study of an international registry and a national cohort in Spain. *Arthritis Rheum* 2009;60:1797–803.
- Becker ML, Martin TM, Doyle TM, Rose CD. Interstitial pneumonitis in Blau syndrome with documented mutation in *CARD 15*. *Arthritis Rheum* 2007;56:1292–94.
- Meiorin SM, Espada G, Costa CE *et al.* Granulomatous nephritis associated with R334Q mutation in *NOD2*. *J Rheumatol* 2007;34:1945–7.
- Wang X, Kuivaniemi H, Bonavita G *et al.* *CARD15* mutations in familial granulomatosis syndromes: a study of the



- original Blau syndrome kindred and other families with large-vessel arteritis and cranial neuropathy. *Arthritis Rheum* 2002;46:3041–5.
- 21 Khubchandani RP, Hasija R, Touitou I *et al.* Blau arteritis resembling Takayasu disease with a novel NOD2 mutation. *J Rheumatol* 2012;39:1888–92.
  - 22 Rose C, Wouters C, Meiorin S *et al.* Pediatric granulomatous arthritis: an international registry. *Arthritis Rheum* 2006;54:3337–44.
  - 23 Arostegui J, Arnal C, Merino R *et al.* NOD2 gene-associated pediatric granulomatous arthritis: clinical diversity, novel and recurrent mutations, and evidence of clinical improvement with interleukin-1 blockade in a Spanish cohort. *Arthritis Rheum* 2007;56:3805–13.
  - 24 Rose CD, Martin TM, Wouters CH. Blau syndrome, revisited. *Curr Opin Rheumatol* 2011;23:411–8.
  - 25 Poznanski AK, Hernandez RJ, Guire KE, Bereza U, Garn SM. Carpal length in children: a useful measurement in the diagnosis of rheumatoid arthritis and some congenital malformation syndromes. *Radiology* 1978;129:661–8.
  - 26 Ruperto N, Levinson JE, Ravelli A *et al.* Long-term health outcomes and quality of life in American and Italian inception cohorts of patients with juvenile rheumatoid arthritis. I. Outcome status. *J Rheumatol* 1997;24:945–51.
  - 27 Saurenmann RK, Levin AV, Feldman BM *et al.* Prevalence, risk factors and outcome of uveitis in juvenile idiopathic arthritis: a long-term followup study. *Arthritis Rheum* 2007;56:647–57.
  - 28 Okafuji I, Nishikomori R, Kanazawa N *et al.* Role of the NOD2 genotype in the clinical phenotype of Blau syndrome and early onset sarcoidosis. *Arthritis Rheum* 2009;60:242–50.
  - 29 Hill SC, Namde M, Dwyer A *et al.* Arthropathy of neonatal onset multisystem inflammatory disease (NOMID/CINCA). *Pediatr Radiol* 2007;37:145–52.
  - 30 Zaki FM, Shridaran R, Pei TS, Ibrahim S, Ping TS. NOMID: the radiographic and MRI features and review of the literature. *J Radiol Case Rep* 2012;6:1–8.
  - 31 Boiu S, Marniga E, Bader-Meunier B *et al.* Functional status in severe juvenile idiopathic arthritis in the biologic treatment era: an assessment in a French paediatric rheumatology referral centre. *Rheumatology* 2012;51:1285–92.
  - 32 Simonini G, Xu Z, Caputo R *et al.* Clinical and transcriptional response to the long-acting IL-1 blocker canakinumab in Blau syndrome-related uveitis. *Arthritis Rheum* 2013;65:513–8.
  - 33 Martin TM, Zhang Z, Kurz P *et al.* The NOD2 defect in Blau syndrome does not result in excess interleukin 1 activity. *Arthritis Rheum* 2009;60:611–8.