

Contents lists available at [ScienceDirect](http://www.sciencedirect.com)

Seizure

journal homepage: www.elsevier.com/locate/yseiz

Case report

Galloway–Mowat syndrome: An early-onset progressive encephalopathy with intractable epilepsy associated to renal impairment. Two novel cases and review of literature

Marianna Pezzella ^{a,1}, Nune S. Yeghiazaryan ^{a,b,1,*}, Pierangelo Veggiotti ^c, Alberto Bettinelli ^d,
Giovanna Giudizioso ^a, Federico Zara ^a, Pasquale Striano ^a, Carlo Minetti ^a

^a Muscular and Neurodegenerative Disease Unit, Institute G. Gaslini, Genova, Italy

^b Armenian Republican Epilepsy Center Erebouni, Yerevan State Medical University, 0087 Yerevan, Armenia

^c Department of Child Neurology and Psychiatry, Neurology Institute “C. Mondino”, Italy

^d Pediatric Renal Unit and Laboratory of Medical Genetics, Fondazione Ospedale Maggiore Policlinico, Mangiagalli e Regina Elena, Milano, Italy

ARTICLE INFO

Article history:

Received 16 November 2009

Received in revised form 6 December 2009

Accepted 17 December 2009

Keywords:

Galloway–Mowat syndrome

Epilepsy

Nephrotic syndrome

Developmental delay

Microcephaly

ABSTRACT

Galloway–Mowat Syndrome (GMS) is an autosomal recessively inherited condition which manifests with severe encephalopathy, featuring microcephaly, developmental delay, and early-onset intractable epilepsy. Patients typically show also renal involvement from the onset. We report two siblings with GMS presenting with early-onset, intractable epilepsy and neurological deterioration, later followed by renal impairment. In both patients intractable epilepsy started during the first months of life and included a combination of spasms, focal and myoclonic/atonic seizures, along with psychomotor retardation and dysmorphic features. One of the patient died from fulminating renal failure at age 6 years. The other patient developed only isolated proteinuria from the age 3 years. Our cases differ from ‘classic’ GMS, as manifested the clinical and laboratory features of renal involvement only some years later the onset of epilepsy and neurological symptoms. Therefore, the diagnosis of GMS should be considered in infants with intractable epilepsy, encephalopathy, and multiple neurological deficits, also in absence of renal manifestations. The literature data about the electroclinical features of epilepsy in GMS are also reviewed.

© 2010 British Epilepsy Association. Published by Elsevier Ltd. All rights reserved.

1. Introduction

Galloway–Mowat syndrome (GMS; OMIM 251300) is a rare autosomal recessive condition first described in 1968¹ and characterized by the association of nephrotic syndrome and central nervous system involvement. The nephrotic syndrome occurs in the first months of life and is typically steroid-resistant, followed by constant and rapid deterioration of renal function. The degree of renal anatomopathological damage is variable and ranges from minimal changes up to diffuse mesangial sclerosis.^{2,3} Death usually occurs within few years from the onset.^{1–4} The spectrum of neurological manifestations is wide and includes microcephaly, severe developmental delay, and structural brain abnormalities, such as malformations of cortical development,

hypomyelination, and cerebellar atrophy.^{5,6} We report two siblings presenting with early-onset, intractable epilepsy and neurological deterioration, followed by renal impairment only some years from the clinical onset.

2. Case reports

2.1. Patient 1

The proband is a boy born from non-consanguineous parents after full-term pregnancy complicated by a risk of abortion at the 30th week of gestation. Birth weight was 3060 g, birth length 50 cm, occipito-frontal circumference 35 cm (50th percentile). Neonatal period and growth were initially normal. At the age of 2 months, the boy started suffering from daily epileptic spasms. At that time, EEGs showed a typical pattern of hypsarrhythmia (Fig. 1a and b). Neurological examination revealed severe psychomotor delay, prominent axial hypotonia, no head maintenance, poor eye contact, microcephaly (36 cm; <3rd percentile), mild dysmorphisms, namely, hypertelorism, long philtrum, protruding tongue, and floppy ears. Routine blood analyses,

* Corresponding author at: Armenian Republican Epilepsy Centre Erebouni, Yerevan State Medical University, 14 Titogradyan str., 0087 Yerevan, Armenia.

E-mail addresses: ynune@yahoo.com, nunepilepsy@gmail.com (N.S. Yeghiazaryan).

¹ These authors contributed equally to this work.

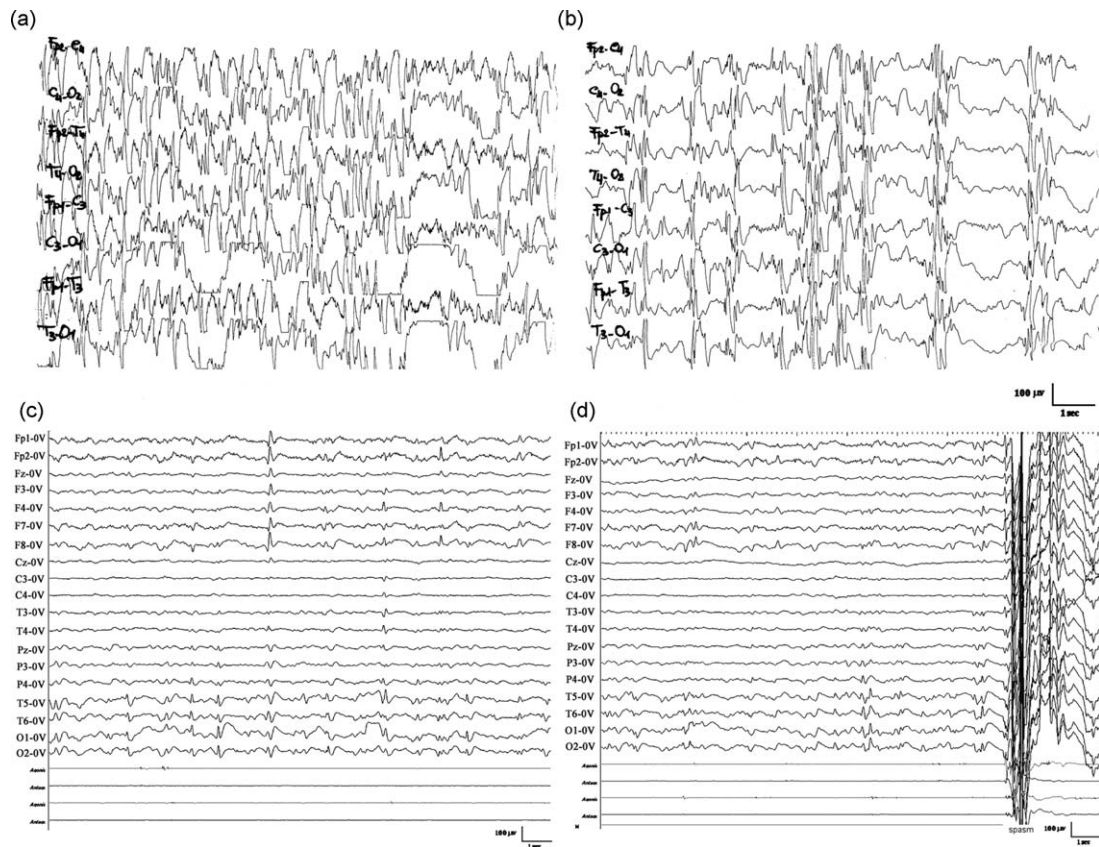


Fig. 1. (a) Interictal EEGs of patient 1 (at age 5 months) showing hypsarrhythmia at awake (b) intermixed to suppression-burst pattern during sleep. (c) EEG recordings of patient 2 (at age 3 years) showing slowed background activity and interictal diffuse and multifocal (bilateral frontal and occipital) epileptiform abnormalities (d) ictal diffuse polyspikes preceding the epileptic spasm.

muscular enzymes, serum lactate, serum and urine amino acids, lysosomal enzymes, funduscopy, and karyotyping were normal. Within few months, also other seizure types appeared, i.e., head drops and focal seizures with chewing automatisms. We observed the boy for the first time at 3 years of life. Neurological examination revealed severe psychomotor delay, spastic tetraparesis, and dystonic-hyperkinetic movements involving the face and the arms, facilitated by tactile stimuli. At that time, he showed daily epileptic spasms as well as focal seizures with eye deviation and oral automatisms. EEG revealed diffusely slowed background activity with multifocal epileptiform abnormalities, prevalent on the right temporo-central areas. Brain MRI revealed mild atrophy of both temporal lobes and hippocampal malrotation. An intensive metabolic screening (urinary, serum and CSF aminoacids; serum and CSF lactate and pyruvate; serum biotinidase, acylcarnitine, very long chain fatty acids; urinary organic amino acids, mucopolysaccharides; coenzyme Q10 in muscle tissue), serological (TORCH complex) and hormonal (ACTH, cortisol, 17OH-progesterone, DHEAS, delta-4-androstenedione, renin, aldosterone) screening were normal. Therapy with several anticonvulsants (AEDs), including valproate, vigabatrin, lamotrigine, and nitrazepam-used alone or in combination-was ineffective. At age 5 years the patient developed facial and leg edema due to nephrotic syndrome (selective glomerular proteinuria: 4.14 g/day, n.v.: 0–8 mg/dL; serum hypoproteinemia: 4 g/dL, n.v. 5.5–9.0 g/dL, hypoalbuminemia (3.1 g/dL, n.v. 3.5–5.5). Renal ultrasound was unremarkable but renal biopsy showed segmental focal glomerulosclerosis. The patient was treated with corticosteroids and cyclophosphamide but showed no response. He died from renal insufficiency at 6 years of life.

2.2. Patient 2

The 3-year-old brother of patient 1 was born after full-term pregnancy, complicated by a risk of abortion at 24 weeks of gestation. Birth growth parameters were normal; occipito-frontal circumference was 33 cm (<10th percentile). Generalized hypotonia and bilateral neurosensory hypoacusia were also observed at the birth. Afterwards, prominent psychomotor delay became evident. At age 3 months daily epileptic spasms started. EEG recordings showed a pattern of hypsarrhythmia. Treatment with ACTH and then with vigabatrin gave partial benefit. Within few months, other seizure types, namely, complex partial seizures with upward and left eye deviation accompanied by oral automatisms, and erratic myoclonus also manifested. At examination, the patient showed slight dysmorphic features (i.e., low-set ears, narrow forehead, and long philtrum), microcephaly (46 cm; <3 percentile), severe psychomotor delay, diffuse axial hypotonia, lower spastic paraparesis, bilateral hypoacusia, and impaired vision. Video-poligraphy showed diffusely slowed background, interictal generalized and multifocal, namely bilateral frontal and occipital, and generalized spikes preceding the spasm (Fig. 1c and d).

Polytherapy with valproate, lamotrigine, and levetiracetam was poorly effective. MRI revealed diffuse hypomyelination and hypoplasia of cerebellar vermis and corpus callosum. Visual evoked potentials were delayed whereas electroretinogram, electromyography, and nerve conduction velocities were unremarkable. Karyotyping, subtelomere FISH, and testing of congenital nephrotic syndromes genes (*NPHS1*, *NPHS2*, *LAMB2*) were normal. At the last follow-up, at age 3 years, the boy presented with proteinuria (1.2 g/dl) with normal serum protein, creatinine,

Table 1
Clinical, neurophysiological, and pathological findings of the GMS patients with epilepsy reported in the literature.

References	Onset of isolated proteinuria	Onset of nephrotic syndrome	Dysmorphic features	Neurological status	Seizure onset	Seizure type (s)	Neuroimaging	EEG abnormalities	AEDs/response	Pathological findings	Outcome
Robain et al. ⁹	–	1 day	Absent	Not reported	6 days	Myoclonus	NA	Multifocal	N/A/Absent	Mesangial fibrosclerosis; Pachygyria	Died at 3 months
Roos et al. ⁸ –Case 1	1 year	2 years	Bristly hair, bilateral club feet	DD, hypotonia, absent eye contact, pyramidal signs	6 months	Spasms	Diffuse brain atrophy	Generalized	N/A/Poor	FSGS; polimicrogyria	Died at 3 years
Roos et al. ⁸ –Case 2	1 year	NA	Not reported	DD, hypotonia, pyramidal signs	3 months	Spasms, myoclonus	Normal	SBP	ACTH, Nitrazepam/Absent	NA	NA
Sano et al. ⁷	16 months	34 months	Abnormal-shaped skull, coarse hair, narrow forehead large low-set ears, almond-shaped eyes, low nasal bridge, pinched nose, thin lips, micrognathia	DD, hypotonia, absent eye contact	10 months	N/A	Diffuse brain atrophy	Generalized	VPA/Poor	FSGS, capillary microaneurysms, mesangiolytic; NA	Alive 35 months
Nishikawa et al. ¹³	–	53 days	Hypoplastic nails on toes, limited elbow flexion, rocker-bottom heels	DD, pyramidal signs	At birth	Myoclonus, focal, clonic	Cerebellar hypoplasia, colpocephaly	SBP	PB, VPA, CBZ, CLZ, B6/Absent	NA	Died at 80 days
de Vries et al. ³ –Case 1	–	2.5 years	Facial asymmetry, broad alveolar ridges, single left palmar crease	DD, hypotonia, nystagmus extrapyramidal signs	9 weeks	Spasms, myoclonus	Bilateral fronto-temporal hypoplasia	NA	NA	Glomerular sclerosis, mesangial expansion, patchy tubular atrophy, chronic inflammatory infiltrates; NA	Died at 4 year
Nakazato et al. ¹⁰ –Case 2	–	21 months	Convergent strabismus, narrow forehead	DD	11 months	NA	Frontal lobe atrophy	Focal	NA	NA	Alive 35 months
Nakazato et al. ¹⁰ –Case 4	–	11 months	Not reported	DD	2 months	NA	Frontal lobe atrophy	Hypsarrhythmia	N/A/Poor	FSGS; NA	Died at 23 months
Sartelet et al. ¹²	9 months	3 years, 8 months	Micrognathia, receding forehead, large mouth, large and floppy ears	DD, hypotonia	9 months	Tonic–clonic	Cerebellar vermis atrophy	NA	VPA/Good	FSGS, collapsing glomerulopathy; NA	Died at 3 years, 11 months
Akhtar et al. ¹¹	–	5 years	High narrow forehead, almond-shaped eyes, large, low-set ears, micrognathia, high arched palate	DD, hypotonia hemiplegia	5 years	Tonic–clonic	Normal	NA	NA	NA	NA
Present paper–Case 1	–	5 years	Hypertelorism, long philtrum, protruding tongue, floppy ears	DD, axial hypotonia spastic tetraparesis, extrapyramidal signs	2 months	Spasms, atonic, focal	Bilateral temporal hypoplasia, hippocampal malrotation	Hypsarrhythmia; multifocal	VPA, VGB, LTG, Nitrazepam/Absent	FSGS; NA	Died at 6 years
Present paper–Case 2	3 years	–	Low-set ears, narrow forehead, long philtrum	DD, hypoacusia, axial hypotonia, lower spastic paraparesis, impaired vision	2 months	Spasms, myoclonus, focal	Hypomyelination, inferior vermis and corpus callosum hypoplasia	Hypsarrhythmia; multifocal	ACTH, VGB, VPA, LTG, LEV/Absent	NA	Alive

DD = developmental delay; EEG = electroencephalography; SBP = suppression-burst pattern; NA = not available; FSGS = Focal segmental glomerular sclerosis; VPA = valproic acid; VGB = vigabatrin, LTG = lamotrigine, LEV = levetiracetam; ACTH = adrenocorticotropic hormone; CBZ = carbamazepine; CLZ = clonazepam

and urea. Renal ultrasound was unremarkable. Treatment with ubiquinone was started.

3. Discussion

In the original description, GMS was reported as a clinical triad of nephrotic syndrome, neurological manifestations, and hiatus hernia.¹ Since then more than 50 cases with GMS ('nephrosis-microcephaly syndrome') have been reported and hiatus hernia is no longer considered a key clinical feature.^{2–4} Therefore, the co-occurrence in infants of renal impairment (i.e., nephrotic syndrome) and central nervous system abnormalities, such as defects of neuronal migration, cerebellar atrophy, hypomyelination, clinically associated to microcephaly, psychomotor delay, severe epilepsy, and mild dysmorphic features, should raise the suspect of GMS. Nosologically, it is thought that GMS constitutes a heterogeneous group of disorders and several attempts has been made to classify the syndrome according to age of onset and severity of nephrotic syndrome, renal histopathology, prognosis, progression of mental retardation, and structural brain abnormalities.^{4,8} Because of the prominent and life-threatening renal manifestations, GMS is relatively unknown to most pediatric neurologists, although neurological involvement is the rule in this condition.

We report two siblings presenting with severe encephalopathy, featuring microcephaly, developmental delay, and early-onset intractable epilepsy. Both patients manifested the clinical and laboratory features of renal impairment only few years from the onset, finally allowing the diagnosis of GMS. A particularly devastating manifestation in our patients was the early-onset refractory epilepsy. Review of the literature showed that age of onset of epilepsy is largely variable in GMS, ranging from few hours to 5 years of life, seldom before the clinical evidence of renal impairment.^{4–7} Different seizure types, including infantile spasms, myoclonus, tonic-clonic, clonic, atonic, and focal seizures, have been reported^{3,7–13}; [Table 1]. EEG findings vary considerably and include mainly a hypsarrhythmia pattern later followed by multifocal epileptiform abnormalities. In almost all the patients, epilepsy is drug-refractory with poor or no response to AEDs, used in monotherapy or in combination.

The genetics of GMS remains unknown, despite the efforts to characterize proteins that may be involved in its pathogenesis. It has been reported reduced glomerular expression of some proteins such as epithelial protein 1, synaptopodin, and nephrin, but this is non-specific and a primary role of these proteins has been ruled out.¹⁴ The possible defective role of several proteins of glomerular basement membrane, including the family of laminins and integrins were unsuccessfully studied.¹⁵ Further research is required to clarify the pathogenesis of this dramatic condition.

In summary, the diagnosis of GMS should be considered as another, rare cause of severe, intractable epilepsy and multiple neurological deficits in infants, also in absence of renal manifestations. Early recognition of this syndrome is of paramount importance especially for genetic counseling and family planning.

Conflict of interest

Authors declare no conflicts of interest.

Acknowledgements

Dr. Martin Zenker, Institute of Human Genetics, Erlangen, Germany is kindly acknowledged for offering genetic testing of laminin $\beta 2$ gene. The European Federation of Neurological Societies is warmly acknowledged for supporting the educational fellowship of Dr. Yeghiazaryan.

References

- Galloway WH, Mowat AP. Congenital microcephaly with hiatus hernia and nephrotic syndrome in two sibs. *J Med Genet* 1968;**5**:319–21.
- Cooperstone BG, Friedman A, Kaplan BS. Galloway–Mowat syndrome of abnormal gyral patterns and glomerulopathy. *Am J Med Genet* 1993;**47**:250–4.
- de Vries BB, van't Hoff WG, Surtees RA, Winter RM. Diagnostic dilemmas in four infants with nephrotic syndrome, microcephaly and severe developmental delay. *Clin Dysmorphol* 2001;**10**:115–21.
- Meyers KE, Kaplan P, Kaplan BS. Nephrotic syndrome, microcephaly, and developmental delay: three separate syndromes. *Am J Med Genet* 1999;**82**:257–60.
- Steiss JO, Gross S, Neubauer BA, Hahn A. Late-onset Nephrotic syndrome and severe cerebellar atrophy in Galloway–Mowat syndrome. *Neuropediatrics* 2005;**36**:332–5.
- Kozłowski PB, Sher JH, Nicastrì AD, Rudelli RD. Brain morphology in the Galloway syndrome. *Clin Neuropathol* 1989;**8**(2):85–91.
- Sano H, Miyanosita A, Watanabe N, Koga Y, Miyazawa Y, Yamaguchi Y. Microcephaly and early-onset nephrotic syndrome—confusion in Galloway–Mowat syndrome. *Pediatr Nephrol* 1995;**9**(6):711–4.
- Roos RA, Maaswinkel-Mooy PD, vd Loo EM, Kanhai HH. Congenital microcephaly, infantile spasms, psychomotor retardation, and nephrotic syndrome in two sibs. *Eur J Pediatr* 1987;**146**(5):532–6.
- Robain O, Deonna T. Pachygyria and congenital nephrosis disorder of migration and neuronal orientation. *Acta Neuropathol* 1983;**60**(1–2):137–41.
- Nakazato H, Hattori S, Karashima S, Kawano T, Seguchi S, Kanahori M, et al. Another autosomal recessive form of focal glomerulosclerosis with neurological findings. *Pediatr Nephrol* 2002;**17**:16–9.
- Akhtar N, Kiran S, Hafeez F. Galloway–Mowat syndrome. *J Coll Physicians Surg Pak* 2008;**18**(8):520–1.
- Sartelet H, Pietremont C, Noel LH, Sabouraud P, Birembaut P, Oligny LL, et al. Collapsing glomerulopathy in Galloway–Mowat syndrome: a case report and review of the literature. *Pathol Res Pract* 2008;**204**(6):401–6.
- Nishikawa M, Ichiyama T, Hayashi T, Furukawa S. A case of early myoclonic encephalopathy with the congenital nephrotic syndrome. *Brain Develop* 1997;**19**:144–7.
- Srivastava T, Whiting JM, Garola RE, Dasouki MJ, Ruotsalainen V, Tryggvason K, et al. Podocyte proteins in Galloway–Mowat syndrome. *Pediatr Nephrol* 2001;**16**:1022–9.
- Dietrich A, Matejas V, Bitzan M, Hashmi S, Kiraly-Borri C, Lin SP, et al. Analysis of genes encoding laminin $\beta 2$ and related proteins in patients with Galloway–Mowat syndrome. *Pediatr Nephrol* 2008;**23**:1779–86.