

## TREATMENT OPTION FOR MAC

# Transcatheter aortic valve in mitral annular calcification (TAV-in-MAC): A new treatment option for mitral valve replacement in patients with severe annular calcification

Hellmuth Weich\*, Jacques van Wyk#, Lou Hofmeyr# and Carl Vogts#

\*Division of Cardiology, Tygerberg Hospital & Stellenbosch University, Tygerberg, South Africa

#Heart Unit, Private Practice, Mediclinic Panorama, Cape Town, South Africa

### Address for correspondence:

Dr Hellmuth Weich  
Division of Cardiology  
Tygerberg Hospital  
Private Bag  
Parow  
7505  
South Africa

### Email:

[hweich@sun.ac.za](mailto:hweich@sun.ac.za)

## INTRODUCTION

Since the first transcatheter aortic valve implant (TAVI) in 2002,<sup>(1)</sup> the field has enjoyed exponential growth. Interventions for the mitral valve, however, have lagged due to the more complex structure of the mitral valve. Candidates for mitral valve surgery tend to be younger and therefore surgical candidates. A significant group of elderly patients, however, are denied any surgical intervention because of excessive mitral annular calcification (MAC). Our group performed the first percutaneous aortic and mitral valve replacement<sup>(2)</sup> but this led to severe left ventricular outflow tract (LVOT) obstruction due to displacement of the anterior mitral valve leaflet (AMVL) into the LVOT. This complication turned out to be the Achilles' heel of the procedure. Surgical excision of the anterior mitral valve leaflet may be the solution to this problem and we describe such a case.

## PATIENT HISTORY

A 79-year-old female patient was referred with dyspnoea. She had been living independently on a farm despite a previous aortic valve replacement (mechanical prosthesis for degenerative aortic stenosis 14 years prior) and chronic atrial fibrillation with good rate control. The aortic valve prosthesis was found

## ABSTRACT

Severe mitral annular calcification is not an uncommon occurrence in the elderly and up to now, this has often precluded surgical replacement of the mitral valve. Initial attempts at percutaneous placement of transcatheter aortic valves in the calcified mitral annulus, has not been very successful due to obstruction of the left ventricular outflow tract. We describe a surgical approach where the anterior mitral valve leaflet was resected and a balloon expandable transcatheter aortic valve then deployed within the calcified annulus. The benefits of this technique over a fully percutaneous approach is discussed. SAHeart 2019;16:136-139

to function well, but she had severe mitral valve stenosis with a valve area of 0.6cm<sup>2</sup> and a mean gradient of 14mmHg. The gradients over the aortic prosthesis were 17/8mmHg. She had, at least, moderate mitral regurgitation and severe pulmonary hypertension (pulmonary arterial pressures of 60mmHg). A CT scan confirmed severe MAC (Figure 1), which excluded conventional surgery. She presented twice in a 7-week period with pulmonary oedema and a decision was taken to offer her a procedure.

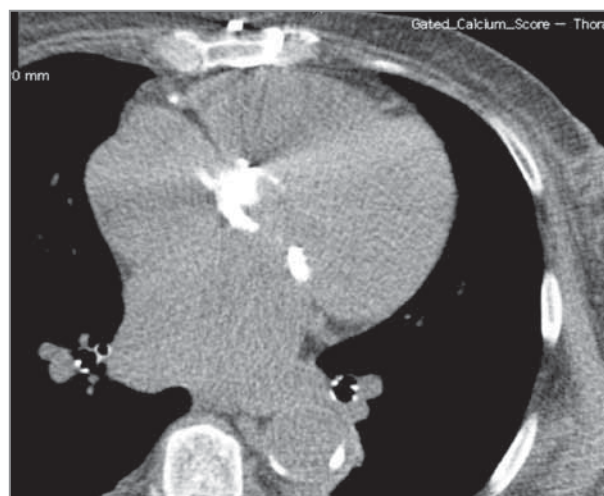


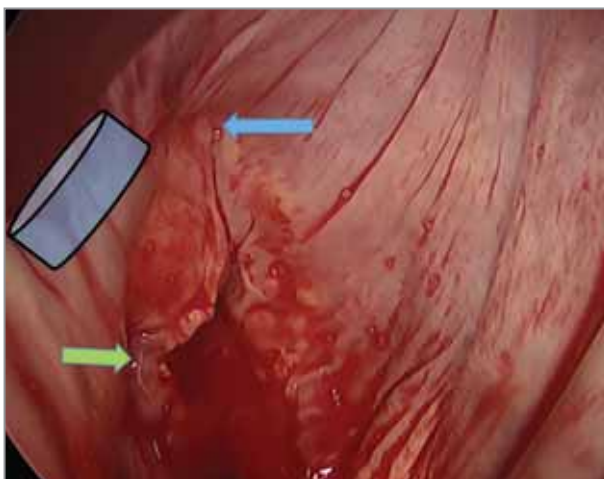
FIGURE 1: CT scan image showing the severely calcified mitral annulus in a long axis view.

### THE PROCEDURE

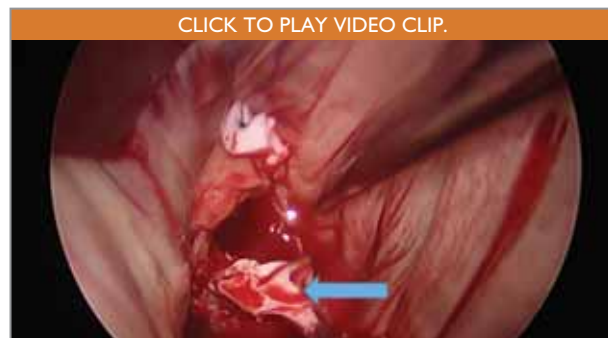The procedure was performed in a hybrid theatre under general anaesthesia on a beating heart. The patient was positioned on her back with her right arm in an abducted position and a sandbag under her scapula. The right femoral vessels were cannulated with a Bio-Medicus (Medtronic, MN) 21FG arterial cannula and a 23FG venous cannula. A right mini-thoracotomy in the fourth intercostal space (ICS) was performed and an endoscope inserted in the second ICS, lateral clavicular line for an optimal viewing angle. Cardiopulmonary bypass (CPB) was initiated: an aortic root vent and right superior pulmonary vein vent was inserted. Due to the fact that she has a porcelain aorta, the aorta was not cross-clamped. Because the procedure was done on a beating heart, concern

existed that air may pass through the mechanical aortic valve. To address this, the patient was tilted head down (Trendelenburg position), and the mean arterial pressure kept above 75mmHg and placed an ascending aorta vent as well as a left ventricular vent. Waterstone's groove was dissected, the left atrium was opened, and a left atrial retractor was placed through the thoracotomy (Figure 2 demonstrates the anatomy as seen at this stage).

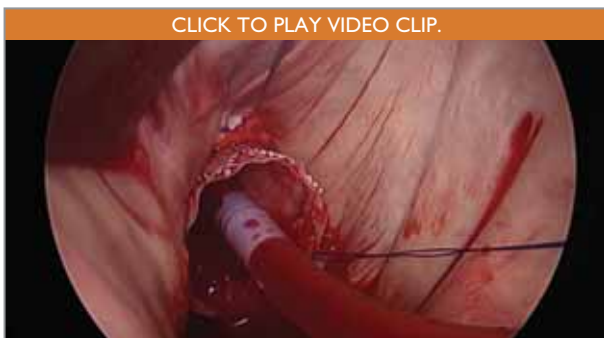The antero-medial mitral commissure was plicated with a single pledgeted suture to create a more circular annulus and potentially less chance of paravalvular leakage. The postero-medial commissure was too calcified to suture. The anterior mitral valve leaflet and chords were then resected (see Figure 3 and online Video 1). The orifice was sized with a 25mm balloon and a 26mm Edwards SAPIEN XT valve (Edwards Lifesciences, Irvine, CA) was implanted. The valve was mounted in an inverse orientation on the delivery system and rotated to an orienta-



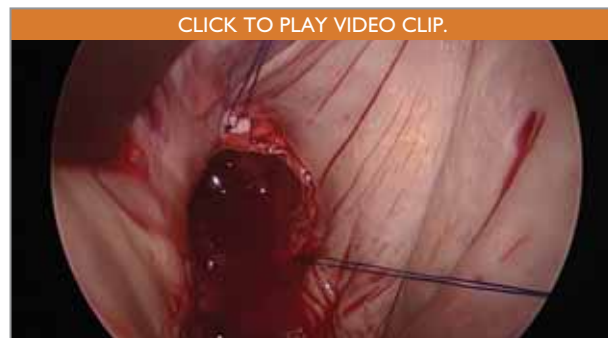**FIGURE 2:** A view of the mitral valve from the atrial side to show orientation: the antero-lateral commissure (blue arrow) was plicated and the postero-medial commissure (green arrow) was too calcified to suture. The position of the aortic valve is shown as a superimposed blue disc.



**FIGURE 3:** After plication of the antero-lateral commissure, the A2 portion of the anterior leaflet was resected together with its chords – the blue arrow indicates the A2 segment as it is pulled out.



**FIGURE 4:** The Edwards SAPIEN XT valve after the first deployment. Note how much of it is visible on the atrial side. A paravalvular jet was seen at 10 o'clock and the valve was removed.



**FIGURE 5:** The valve after a second deployment sitting significantly less atrial and no leaks were seen. The pledgeted sutures seen were then used to put anchor sutures through the struts of the stent.

tion that ensured none of the SAPIEN XT valve's commissures were over the LVOT. It was deployed under direct vision and without rapid ventricular pacing (see online Video 2). This initial position was too atrial (see Figure 4 and online Video 3) and resulted in a paravalvular leak. The fact that the heart was beating enabled us to detect this leak immediately. The device was removed and recrimped. A second deployment resulted in a better position (see Figure 5 and online Video 3). The valve stent was fixed with 2 pledgeted sutures.

The patient was weaned from CPB and intra-operative transoesophageal echo showed a mean LVOT gradient of 8.3mmHg, minimal paravalvular leak and good valve function (see online Video 4). The patient was extubated the next morning, made an uncomplicated recovery and was discharged on day 6. A follow up echo did not show any paravalvular leaks and a mean gradient of 3mmHg over the mitral valve. She remains in NYHA functional class I.

## DISCUSSION

Conventional mitral valve replacement surgery for patients with severe MAC is often not possible or carries high risk due to the surgeon's inability to place sutures in the annulus or the extent of debridement required to place the valve.<sup>(3)</sup> We describe the first case of a transcatheter aortic valve prosthesis implanted into a calcified native mitral annulus (TAV-in-MAC) published in South Africa. TAV-in-MAC was first described in 2013<sup>(4)</sup> but this approach has met slow acceptance for a number of reasons. In the largest series reported (n=64), more than 30% of screened patients were excluded from the procedure because their anatomy was deemed unsuitable. Access was transapical (45%) and transseptal (40%) in most cases and the authors did not mention how often the AMVL was resected in the transatrial cases. Procedural success was achieved in 72% with high rates of clinically significant LVOT obstruction (9%) and the need for a second valve (17%). Significant LVOT obstruction was fatal in all but 1 case and the authors unfortunately did not report on LVOT gradients in the majority of other cases. It therefore remains unknown to what extent this complication influences the outcome of patients who survive the procedure. Thirty-day mortality was 29.7% and technical success was worst with transseptal approach (65%), followed by transapical (71%) and transatrial (89%).<sup>(5)</sup> These sobering results may be due to a number of factors but inability to predict LVOT obstruction may be a significant one and our approach was to assume the worst and address this risk prior to implantation of the valve.

Pre-operative imaging is crucial. Apart from the correct diagnosis of severe mitral stenosis (which may be very challenging), it is important to confirm the degree of MAC on CT-scanning. A CT scan can also help to determine the risk of LVOT obstruction. There is no validated method of predicting this, but techniques utilised include measuring the angle between the planes of the aorta and mitral valves (if it is <120 degrees, LVOT obstruction is more likely) and special software that enables superimposing the intended transcatheter valve on the annulus and calculating the LVOT area.<sup>(6)</sup>

A percutaneous alternative would be preferable, provided the results are similar. In the series described above, the success rate and mortality was higher in the percutaneous arms of the studies. The authors, however, did not report on the occurrence of the main complications (LVOT obstruction and valve embolisation) stratified according to access site. Our approach is that both of these can be managed better with a transatrial approach. During percutaneous implantation, most operators flared the ventricular side of the prosthesis to enable better anchoring.<sup>(5)</sup> Whilst this may improve anchoring, it is not known whether the altered geometry of the stent will have a negative influence on the valve function and longevity. The first attempt at addressing LVOT obstruction percutaneously was alcohol septal ablation (either electively prior to the valve replacement or as a bail out) but this has been shown to be associated with mortality.<sup>(5)</sup> More recently, a technique of percutaneously bisecting the anterior mitral valve leaflet – so called LAMPOON technique – was described.<sup>(7)</sup> This, however, requires specialised equipment, was tested mainly in patients with either a mitral annuloplasty ring or a surgical mitral valve ring and does not allow for resection of the anterior chords. Patients who are not good surgical candidates due to comorbidities rather than technical limitations, may benefit from these procedures.

We are of the opinion that in patients who are surgical candidates the transatrial approach holds certain important advantages over current percutaneous approaches:

- The same degree of debulking of the AMVL and chords cannot be achieved percutaneously.
- LVOT obstruction cannot be predicted reliably yet and bail-out alternatives, if it occurs, are limited.
- Plication of 1 or both mitral annuli probably reduces paravalvular leaks and enables insertion of a smaller valve with less chance of LVOT obstruction.

- Valve embolisation is common with percutaneous techniques<sup>(5, 8)</sup> and suture anchoring of the valve should reduce this.
- Rotating the TAV prosthesis to enable optimal orientation of cusps.
- Operating on a beating heart enables evaluation and correction of paravalvular leaks intra-operatively.
- Retrieving a valve is possible, should it be required.

Degenerative mitral stenosis with severe MAC is a common problem in older patients and, until recently, there have been very few treatment options for these patients. We believe that TAV-in-MAC offers a new treatment modality that may benefit a significant proportion of these patients.

**Conflict of interest: none declared.**

## REFERENCES

1. Cribier A, Eltchaninoff H, Tron C. First human transcatheter implantation of an aortic valve prosthesis in a case of severe calcific aortic stenosis. *Ann Cardiol Angeiol (Paris)* 2003;52(0003-3928;3):173-75.
2. Weich H, Janson J, Pecoraro A, et al. First case of transcatheter native mitral and aortic valve replacement. *EuroIntervention* 2016;12(9). DOI: 10.4244/EIJV12I9A195.
3. Sud K, Agarwal S. Degenerative mitral stenosis unmet need for percutaneous interventions. *Circulation* 2016;133:1594-604. DOI: 10.1161/CIRCULATIONAHA.115.020185.
4. Hasan R, Mahadevan VS, Schneider H, Clarke B. First in human transapical implantation of an inverted transcatheter aortic valve prosthesis to treat native mitral valve stenosis. *Circulation* 2013;128(6):e74-76. DOI: 10.1161/CIRCULATIONAHA.113.001466.
5. Guerrero M, Dvir D, Himbert D, et al. Transcatheter mitral valve replacement in native mitral valve disease with severe mitral annular calcification: Results from the first multicentre global registry 2016.
6. Eleid MF, Foley TA, Said SM, Pislaru SV, Rihal CS. Severe mitral annular calcification: Multimodality imaging for therapeutic strategies and interventions. *JACC Cardiovasc Imaging* 2016;9(11):1318-37. DOI: 10.1016/j.jcmg.2016.09.001.
7. Babaliaros VC, Greenbaum AB, Khan JM, et al. Intentional percutaneous laceration of the anterior mitral leaflet to prevent outflow obstruction during transcatheter mitral valve replacement. *JACC Cardiovasc Interv* 2017;10(8):798-809. DOI: 10.1016/j.jcin.2017.01.035.
8. Lazkani M, Verma DR, Gellert G, Morris M, Fang K, Pershad A. Limitations of transcatheter mitral valve replacement in native mitral valve disease with severe mitral annular calcification. *JACC Cardiovasc Interv* 2016;9(23):2460-61. DOI: 10.1016/j.jcin.2016.09.042.