

## Brief Report

**Cite this article:** Vanhie ESI, Bogers, AJJC, and Helbing WA (2019) Long-term outcome after tricuspid valvectomy in a neonate with *Candida* endocarditis: a case report. *Cardiology in the Young* **29**: 528–530. doi: [10.1017/S1047951119000027](https://doi.org/10.1017/S1047951119000027)

Received: 2 November 2018  
Revised: 5 December 2018  
Accepted: 21 December 2018

**Key words:**

Tricuspid valve; valvectomy; endocarditis; children

**Author for correspondence:**

Willem A. Helbing, MD, PhD, Division of Paediatric Cardiology, Department of Paediatrics, Erasmus University Medical Centre - Sophia Children's Hospital, Doctor Molewaterplein 40, 3015 GD Rotterdam, The Netherlands. Tel: +31107036264; Fax: +31107036801; E-mail: [w.a.helbing@erasmusmc.nl](mailto:w.a.helbing@erasmusmc.nl)

# Long-term outcome after tricuspid valvectomy in a neonate with *Candida* endocarditis: a case report

Ellen S. I. Vanhie<sup>1,2</sup>, Ad J. J. C. Bogers,<sup>3</sup> and Willem A. Helbing<sup>2</sup>

<sup>1</sup>Department of Paediatrics, University Hospital of Ghent, Ghent, Belgium; <sup>2</sup>Division of Paediatric Cardiology and Radiology, Department of Paediatrics, Erasmus University Medical Centre - Sophia Children's Hospital, Rotterdam, The Netherlands and <sup>3</sup>Department of Cardiothoracic Surgery, Erasmus University Medical Centre, Rotterdam, The Netherlands

**Abstract**

Tricuspid valvectomy is a rare surgical intervention, and knowledge regarding long-term outcome in children is lacking. We report a favourable outcome 11 years after tricuspid valvectomy in early infancy without subsequent surgery or other cardiac interventions. Specific criteria for timing of re-intervention are lacking. Application of adult tricuspid and pulmonary regurgitation recommendations is helpful but has limitations.

Isolated right-sided infective endocarditis is uncommon, especially in neonates. *Candida* species is the underlying micro-organism in 10% of infants with infective endocarditis. In neonates, this results in a right-sided endocarditis in 90% of the *Candida* endocarditis cases.<sup>1</sup>

First choice treatment is anti-microbial medication. Surgery should be considered when large tricuspid valve vegetation is present, when antibiotic medical treatment fails, when the infection is caused by micro-organisms difficult to eradicate, or when refractive right heart failure is present.<sup>2</sup> The preferred surgical treatment is valve repair. Because of the long-term risk of developing severe right heart failure, tricuspid valvectomy is considered only in exceptional cases.<sup>3</sup>

Data on prognosis of living without tricuspid valve are scarce.<sup>3,4</sup> Aim of this report is to share a history of over 10-year survival after tricuspid valvectomy in infancy.

**Case report**

We describe the case of a female infant born at 29 weeks and 3 days of gestational age with birth weight of 1310 kg. Details of her medical history in the first months of life have been reported previously.<sup>5</sup>

At the age of 5 months, she was diagnosed with a thrombus obstructing the tricuspid orifice. Cardiac surgery was performed within 24 hours after admission. The tricuspid valve could not be repaired and valvectomy was performed. Blood cultures and thrombus examination showed a *Candida albicans*, so fluconazole was initiated. The post-operative course was prolonged, requiring maximal support with inotropic medication, diuretics, nitric oxide, and sildenafil. Eventually she was discharged 5 weeks post-operatively using diuretics, sildenafil 8 mg/kg/day, and fluconazole. Ultrasonography at discharge showed a dilated right heart, with normal cardiac output and moderate reversed flow in the hepatic veins.<sup>5</sup>

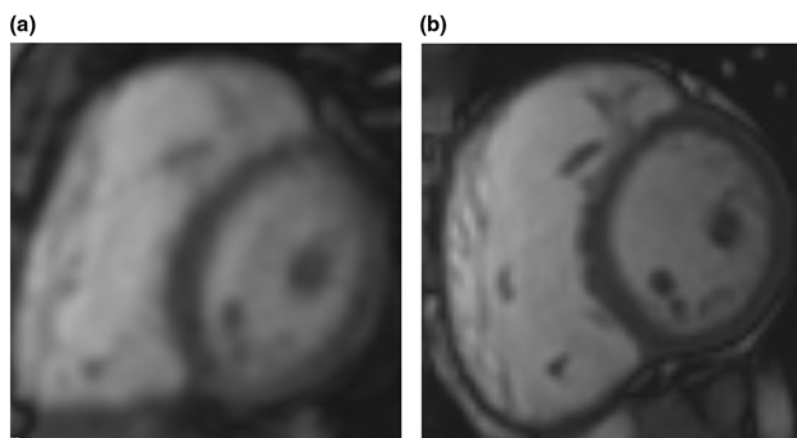
The following years the girl did surprisingly well. Mild pulmonic regurgitation was noted. Based on the measurements of pulmonic regurgitation flow velocity and the shape of the right ventricle, there were no signs of increased pulmonary artery pressure. Because of the combined clinical and echo findings, we did not perform invasive measurements. Sildenafil dosage was gradually reduced and sildenafil was stopped 1 year after surgery. With the diuretics as only medication, she had a normal growth pattern and exercise capacity during the subsequent years. There was no progressive dilatation of the right atrium or ventricle. Until the age of 11 years old, she stayed clinically stable without cardiac arrhythmias or signs of right heart failure.

Since the age of 11 years, exercise intolerance is present. Cardiopulmonary exercise test showed exercise intolerance with a peak workload of 100 W (predicted 140 W, 71%) and a decrease of peak oxygen uptake from 37 to 28 ml/kg/minute over the last 3 years (Table 1). There were no signs of ventricular arrhythmias (as confirmed on 24-hour Holter monitoring). Cardiac MRI showed non-progressive dilatation of the right ventricle and a normal ventricular ejection fraction (Fig 1). Because of sub-optimal exercise performance and dilatation of the right heart (Table 1), the question for surgical intervention arises. Based on criteria including those used in more common situations of right ventricular dilatation, such as pulmonary regurgitation, for now a conservative strategy is implemented, guided by the clinical state of the patient.

**Table 1.** Evolution of cardiopulmonary measurements

Age (years)	8	11
<b>MRI</b>		
LV end-diastolic volume (ml/m <sup>2</sup> )	61	74
LV stroke volume (ml/m <sup>2</sup> /beat)	35	48
LV ejection fraction (%)	58	65
RV end-diastolic volume (ml/m <sup>2</sup> )	164	158
RV stroke volume (ml/m <sup>2</sup> )	97	98
RV ejection fraction (%)	59	62
Tricuspid regurgitation (%)	64	51
<b>CPET</b>		
RER peak	>1.2	>1.1
Maximal Power(W/kg)	2.9	2.3
VO <sub>2</sub> peak (ml/kg/minute)	37	28
VO <sub>2</sub> peak % of predicted value	88	76

CPET = cardiopulmonary exercise testing; LV = left ventricle; RER peak = respiratory exchange ratio at peak exercise; RV = right ventricle.



**Figure 1.** Still frames of end-diastolic images of short axis orientation steady-state free-precession cine cardiac magnetic resonance imaging performed in 2014 (a) and 2017 (b). Left ventricle is on the right-hand side of panels (a) and (b).

## Discussion

Information on long-term outcome after tricuspid valvectomy is scarce. Isolated tricuspid regurgitation is commonly well tolerated in adults.<sup>4</sup> However, chronic severe tricuspid regurgitation may lead to volume overload of the right ventricle, which may cause ventricular dilatation and loss of cardiac function. Symptoms may appear only when the disease is already advanced.<sup>4</sup> Chronic medical treatment for severe isolated tricuspid regurgitation in adults consists of diuretics, and is used when clinical symptoms of right heart failure are present. There is no evidence that the use of diuretics improves the survival rate in these patients.<sup>4,6</sup> Furthermore, diuretics might reduce clinical symptoms and be successful in reducing heart failure symptoms, which might result in delay of surgical intervention and poorer outcome.<sup>7</sup>

In our case, pulmonary hypertension, following tricuspid valvectomy, initially persisted despite maximum support with diuretics, inotropics, high oxygen ventilation, and inhaled NO. Eventually, weaning from respiratory support was successful after

introduction of sildenafil 8 mg/kg/day. In the following year, the girl was treated with diuretics and sildenafil to provide optimal preload and afterload of the right ventricle. There were no side effects reported.

Sildenafil is well studied and approved for pulmonary hypertension in adults. Currently, large trials in term and pre-term neonates are lacking.<sup>8</sup> A Cochrane 2017 systematic review evaluated the efficacy of sildenafil monotherapy in lowering mortality in neonates compared to placebo. Sildenafil as adjuvant therapy with other pulmonary vasodilating products did not change mortality rates.<sup>9</sup>

Tricuspid valvectomy has never been the first choice treatment option for endocarditis.<sup>3</sup> In our case, clinical state and heart function remained normal for 10 years after tricuspid valvectomy. This favourable outcome can be explained by the positive response on medical treatment and absence of complications such as pulmonary embolism in the acute phase. Furthermore, chronic medical treatment with diuretics and new drugs such as sildenafil may have improved the outcome.<sup>8,9</sup>

There is no guideline concerning timing of surgical re-intervention after tricuspid valvectomy.<sup>4</sup> Our case shows a long-term survival with possibility to postpone surgery, in a young child.

The AHA/ACC and ESC/EACTS guidelines for adults recommend surgical intervention for primary, isolated tricuspid regurgitation when patients are symptomatic or, if they are asymptomatic, when there is progressive right ventricular dilatation and/or dysfunction (class IIa recommendation, level of evidence C). Surgery needs to be performed as soon as the indication is set, to avoid irreversible right ventricular dysfunction.<sup>6,7</sup>

Follow-up includes imaging with echocardiography and MRI. The 2017 ESC/EACTS guideline describes cut-off values of echocardiographic measurements defining severe valve regurgitation in adults.<sup>6,7</sup> The lack of cut-off values for children is striking. This bears resemblance to the setting of chronic right ventricle volume overload following chronic pulmonary regurgitation, in which size criteria of the right ventricle as indication for intervention are subject of continued debate.<sup>10</sup> This hampers decision-making in a case like this. In analogy to the situation in valve replacement in pulmonary regurgitation, we will opt for tricuspid valve replacement if symptoms, exercise test results, right ventricular size, and function and/or ECG changes all point towards progressive decline of right ventricular function.

## Conclusion

This case illustrates the ability for survival in good clinical condition for more than 10 years after tricuspid valvectomy performed in infancy. Growth, exercise capacity, and right ventricular size and function remained within acceptable limits. Consensus criteria for timing of re-intervention are lacking.

**Financial Support.** This research received no specific grant from any funding agency, commercial or not-for-profit sectors.

**Conflicts of Interest.** None.

**Ethical Standards.** Written informed consent was obtained.

## References

1. Anil Kumar V, Francis E, Sreehari S, Raj B. Tricuspid valve mycetoma in an infant successfully treated by excision and complex tricuspid valve repair followed by fluconazole therapy. *Surg Infect (Larchmt)* 2014; 15: 134–140.
2. Habib G, Lancellotti P, Jung B. 2015 ESC guidelines on the management of infective endocarditis: a big step forward for an old disease. *Heart* 2016; 102: 992–994.
3. Yong MS, Coffey S, Prendergast BD, et al. Surgical management of tricuspid valve endocarditis in the current era: a review. *Int J Cardiol* 2016; 202: 44–48.
4. Rodes-Cabau J, Taramasso M, O’Gara PT. Diagnosis and treatment of tricuspid valve disease: current and future perspectives. *Lancet* 2016; 388: 2431–2442.
5. du Plessis FA, Helbing WA, Bogers AJ. Excision of the tricuspid valve in a baby with *Candida* endocarditis. *Cardiol Young* 2007; 17: 545–547.
6. Nishimura RA, Otto CM, Bonow RO, et al. 2014 AHA/ACC guideline for the management of patients with valvular heart disease: a report of the American College of Cardiology/American Heart Association Task Force on Practice Guidelines. *J Thoracic Cardiovas Surg* 2014; 148: e1–e132.
7. Baumgartner H, Falk V, Bax JJ, et al. 2017 ESC/EACTS guidelines for the management of valvular heart disease. *Eur Heart J* 2017; 38: 2739–2791.
8. Perez KM, Laughon M. Sildenafil in term and premature infants: a systematic review. *Clin Ther* 2015; 37: 2598–2607.
9. Kelly LE, Ohlsson A, Shah PS. Sildenafil for pulmonary hypertension in neonates. *Cochrane Database Syst Rev* 2017; 8: CD005494.
10. Tretter JT, Friedberg MK, Wald RM, McElhinney DB. Defining and refining indications for transcatheter pulmonary valve replacement in patients with repaired tetralogy of Fallot: contributions from anatomical and functional imaging. *Int J Cardiol* 2016; 221: 916–925.