



Praying Sitting Position for Pineal Region Surgery: An Efficient Variant of a Classic Position in Neurosurgery

Joham Choque-Velasquez¹, Roberto Colasanti^{1,2}, Julio C. Resendiz-Nieves¹, Kléber E. González-Echevarría¹, Rahul Raj¹, Behnam Rezai Jahromi¹, Felix Goehre^{1,3}, Ann-Christine Lindroos¹, Juha Hernesniemi¹

■ **BACKGROUND:** The sitting position has lost favor among neurosurgeons partly owing to assumptions of increased complications, such as venous air embolisms and hemodynamic disturbances. Moreover, the surgeon must assume a tiring posture. We describe our protocol for the “praying position” for pineal region surgery; this variant may reduce some of the risks of the sitting position, while providing a more ergonomic surgical position.

■ **METHODS:** A retrospective review of 56 pineal lesions operated on using the praying position between January 2008 and October 2015 was performed. The praying position is a steeper sitting position with the upper torso and the head bent forward and downward. The patient’s head is tilted about 30° making the tentorium almost horizontal, thus providing a good viewing angle. G-suit trousers or elastic bandages around the lower extremities are always used.

■ **RESULTS:** Complete lesion removal was achieved in 52 cases; subtotal removal was achieved in 4. Venous air embolism associated with persistent hemodynamic changes was nonexistent in this series. When venous air embolism was suspected, an immediate reaction based on good teamwork was imperative. No cervical spine cord injury or peripheral nerve damage was reported. The microsurgical time was <45 minutes in most of the cases. Postoperative pneumocephalus was detected in all patients, but no case required surgical treatment.

■ **CONCLUSIONS:** A protocolized praying position that includes proper teamwork management may provide a

simple, fast, and safe approach for proper placement of the patient for pineal region surgery.

INTRODUCTION

The use of the sitting position for pineal region surgery may offer several advantages, such as lower intracranial pressure, good venous outflow, gravitational retraction, and straight anatomic orientation.^{1,2} However, different complications are described for the sitting position. Air embolism associated with hypotension is commonly reported.^{3,5} In addition, particular disadvantages are frequently mentioned by some surgeons, such as time-consuming positioning, tiring standing posture, impossibility for adequate positioning of the microscope, and obstruction of the operative view owing to a deficient dressing. Therefore, many institutions avoid the sitting position to prevent perioperative complications.⁶

In our department, the sitting position is routinely used for pathologies in the pineal region, midline parieto-occipital approaches, and midline approaches to the posterior fossa or craniocervical junction.^{7,8} Although the main protocol is always the same, pineal region surgery requires a particular variant of the classic sitting positioning called “praying position.” This variant, together with proper teamwork and skillful microsurgery, may remarkably reduce the risks of venous air embolism (VAE) associated with hemodynamic disturbances, while offering the surgeon a more ergonomic surgical position and allowing the surgeon to operate on pineal region lesions in a “simple, clean, and fast way, while preserving the normal anatomy.”⁹ The first

Key words

- Air embolism
- Ergonomics
- Hemodynamics
- Microneurosurgery
- Pineal region lesions
- Sitting position
- Supracerebellar infratentorial approach

Abbreviations and Acronyms

PPTID: Pineal parenchymal tumor of intermediate differentiation
VAE: Venous air embolism

¹From the Department of Neurosurgery, Helsinki University Hospital, Helsinki, Finland;

²Department of Neurosurgery, Umberto I General Hospital, Università Politecnica delle Marche, Ancona, Italy; and ³Department of Neurosurgery, Stroke Center, Bergmannstrost Hospital Halle, Halle, Germany

To whom correspondence should be addressed: Joham Choque-Velasquez, M.D.
 [E-mail: johchove@hotmail.com]

Citation: *World Neurosurg.* (2018) 113:e604-e611.
<https://doi.org/10.1016/j.wneu.2018.02.107>

Journal homepage: www.WORLDNEUROSURGERY.org

Available online: www.sciencedirect.com

1878-8750/\$ - see front matter © 2018 Elsevier Inc. All rights reserved.

article about the microsurgical management of pineal lesions was published by the senior author (J.H.) in 2008.⁷ The objective of the present article is to describe our protocol for the praying position.

MATERIALS AND METHODS

Study Design and Ethics

This is a single-center retrospective study regarding the surgical treatment of consecutive pineal region lesions using the praying sitting position. Following Institutional Review Board approval, data were collected from hospital records. Patient consent was not required for this retrospective study, as the research data analysis had no effect on the participants.

Participants

Patients with pineal lesions who were operated on using the praying position by the senior author (J.H.) between January 2008 and October 2015 were included. Patients with missing information were excluded. During the study period, 64 patients with pineal lesions were treated. Of these, 56 met the study inclusion criteria (28 men, 28 women). Mean patient age was 34.5 years (range, 2–79 years).

Table 1. Exclusion Criteria and Anesthetic Considerations for the Sitting Position

Exclusion Criteria

- Classically, exclusion criteria for the sitting position are ventriculoatrial shunt, severe congestive heart failure, uncontrolled previous hypertension, previously known cerebral ischemia, patent foramen ovale, old age, and right atrial pressure greater than left atrial pressure.
- In our department, we did not have complications related to the sitting position in elderly patients or in patients with cardiovascular diseases.
- We routinely use and recommend the sitting position for patients with heavy obesity.

Anesthetic Considerations

- Conventional use of fentanyl, thiopental, propofol (or rarely inhaled anesthetic), and rocuronium or vecuronium.
- Administration of bolus of intravenous Ringer acetate or hydroxyethyl starch just before positioning of the patient; hydroxyethyl starch is slightly more effective than Ringer acetate in achieving comparable hemodynamics.
- In adults, target mean arterial pressure, measured at the level of the foramen of Monro, is ≥ 60 mm Hg, and/or mean systolic arterial pressure is ≥ 100 mm Hg.
- Precordial Doppler ultrasound probe is placed over the right fifth intercostal space.
- Normoventilation of patients (target $P_{aCO_2} = 4.4\text{--}5.0$ kPa [33.0–37.5 mm Hg]) is with 100% inspired oxygen without positive end-expiratory pressure by volume-controlled ventilation. Nitrous oxide is not given.
- Arterial blood gases are analyzed after induction of anesthesia and then as needed.



Video available at
WORLDNEUROSURGERY.org

Praying Sitting Position

Table 1 describes the exclusion criteria and anesthetic considerations for the praying sitting position. Our step-by-step procedure for sitting positioning in pineal region surgery is as follows (**Figures 1–3** and **Video 1**):

1. The surgeon fixes the Mayfield-Kees head clamp (Integra LifeSciences Corp., Plainsboro, New Jersey, USA) when the patient is in supine position, intubated and with peripheral venous access (no central venous access), with urinary catheter and G-suit trousers (inflated to 40 mm Hg) or loosely tied elastic bandages around the lower extremities. Beginning at this stage, the surgeon holds the patient's head through the head frame throughout the procedure.
2. At the surgeon's command, the auxiliary personnel move the patient to locate his or her hips at the level of the surgical table flexing place, while maintaining the shoulders 10–15 cm above the cranial edge of the table. Pillows are located below the knees of the patient.
3. The table is bent approximately 90° – 100° elevating the upper torso of the patient. During this step, the neck and the head of the patient are tilted forward and downward beyond the projection of the anterior wall of the thorax. The head is usually flexed 20° – 30° , preserving a distance between the chin and sternum. This creates a more ergonomic working position for the neurosurgeon allowing his or her arms to rest over the patient's shoulders during the procedure (praying position) (**Figure 3**).
4. The aforementioned sequence permits us to keep the horizontal axis of the tentorium parallel to the floor, with $<90^{\circ}$ in relation to the axis of the surgeon. The anesthesia team is responsible for permanently modifying the position of the table and the patient.
5. The Mayfield head frame is attached to the surgical table with a special system called a trapeze. The flexion of the head (always keeping 2 fingers between the chin and the sternum), without or with just minimal lateral rotation of the head, is extremely important to obtain optimal surgical positioning without cervical cord damage.
6. A safety belt around the pelvis and a suction cushion wrapping the patient will prevent his or her accidental movement when the position is changed forward during the surgery. A flat board against the feet will also prevent any caudal slide.
7. Pillows are placed on the top of the abdomen to support the arms. Precordial Doppler device is positioned, and the endotracheal tube is secured to the clamp system. Then the correct positioning of the head is reviewed again.
8. The surgical table, which is parallel to the floor and is as low as possible, will be angulated by the anesthesiologist according to the surgeon's needs during the surgery.

After proper positioning and antisepsis of the operative field, the drape is attached to the Mayfield head frame with a big adhesive film (**Figure 2**). This prevents the surgical dress sliding over the surgical field during the procedure. The nurse drapes

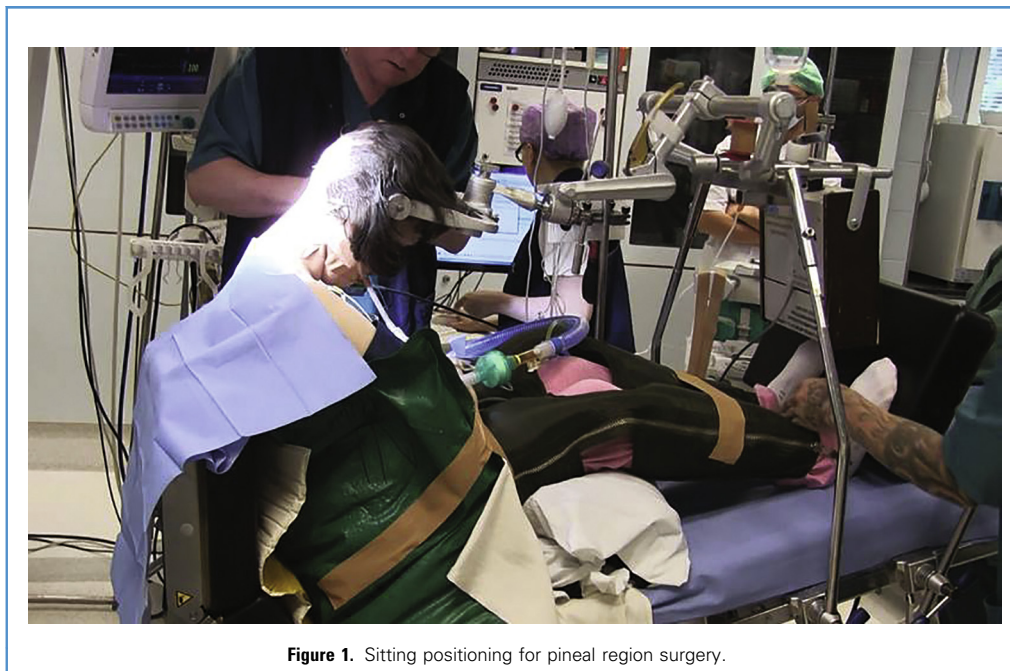

Figure 1. Sitting positioning for pineal region surgery.

the patient in a systematic sequence (**Figure 2**). Two aspects are notable: 1) the adhesive borders of a light single-use surgical dressing are attached to the drape, and both elements are fixed with adhesive films; 2) despite the dressing, the anesthesiologist has free access to both jugular veins. As shown in **Video 1**, a protocolized sitting positioning may be performed in <5 minutes for a normal-weight adult.

Postintervention Variables

The surgical outcome of the patients was reviewed. Microsurgical times, between the opening and the closure of the dura mater, were recorded from 51 surgical videos. Complications regarding

the positioning were also analyzed. Minor VAE was diagnosed by a decrease of end-tidal carbon dioxide concentration of >5.25 mm Hg associated or not with a precordial Doppler variation or direct vision of a damaged sinus in the absence of hemodynamic instability or a related change in minute ventilation. Severe VAE was defined as the presence of VAE associated with persistent hemodynamic instability (we considered >2 controls in 5-minute intervals) or a related change in a minute ventilation.

Statistics

Means with standard deviations were used to describe the cohort. Correlations between microsurgical time, lesion size, and patient

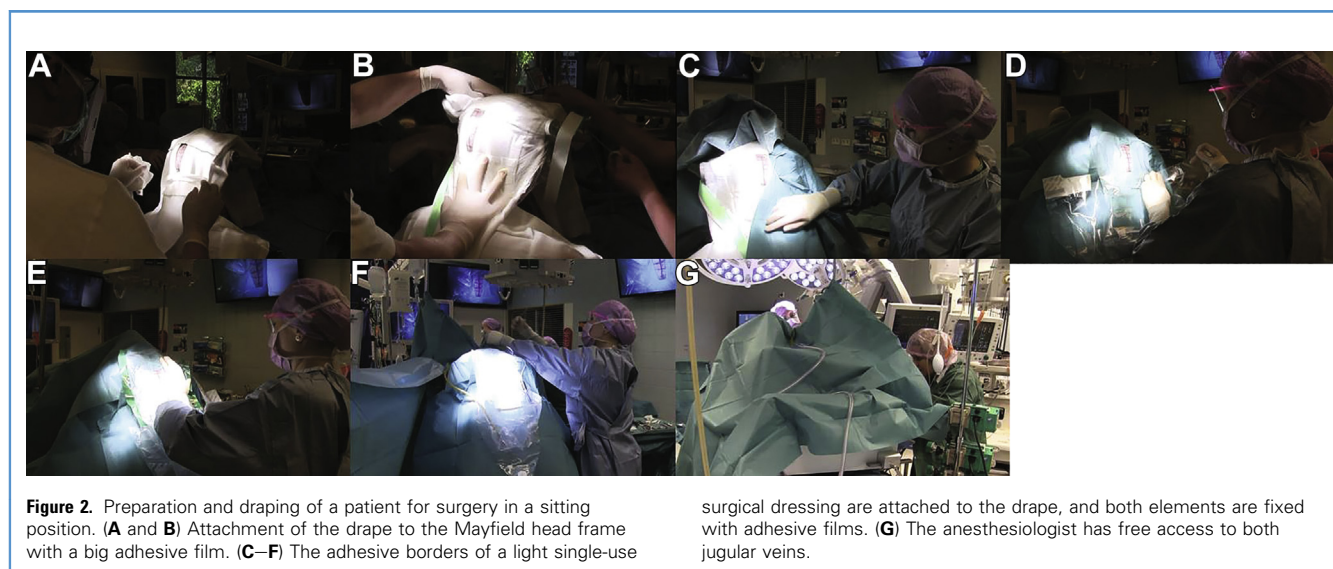
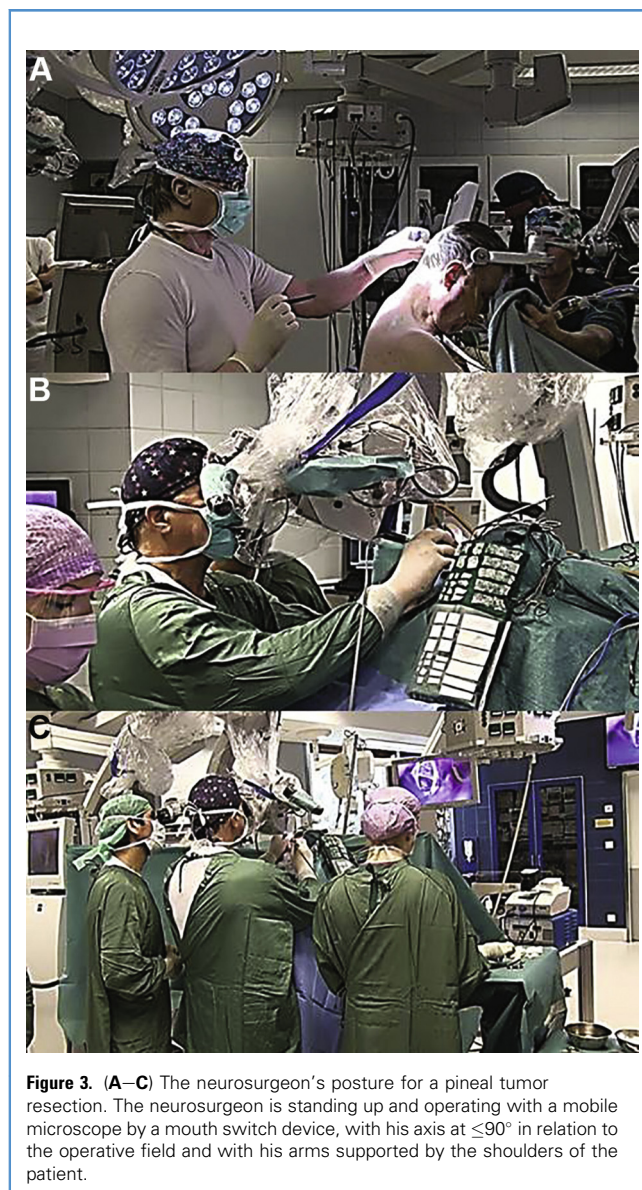


Figure 2. Preparation and draping of a patient for surgery in a sitting position. (A and B) Attachment of the drape to the Mayfield head frame with a big adhesive film. (C–F) The adhesive borders of a light single-use

surgical dressing are attached to the drape, and both elements are fixed with adhesive films. (G) The anesthesiologist has free access to both jugular veins.



age were analyzed using the Pearson test. P values < 0.05 were considered significant. IBM SPSS Version 22 (IBM Corp., Armonk, New York, USA) was used.

RESULTS

Participants and Descriptive Data

Two of 58 consecutive patients operated by the senior author (J.H.), respectively harboring a pineal meningioma without preoperative images and a pineal cyst with no follow-up, were not included. Characteristics of the remaining 56 patients are presented in **Table 2**. Preoperative clinical status included neurologic symptoms related to pineal region compression and/or infiltration, hydrocephalus in case of ruptured vascular lesions owing to subarachnoid hemorrhage, and nonspecific symptoms in patients

with incidental lesions. In the patient with vein of Galen malformation, signs of congestive cardiac failure were detected by echocardiography.

Surgical Approaches

Of patients, 48 were operated on with only the supracerebellar infratentorial approach, and 4 patients required only a parieto-occipital interhemispheric approach. In 2 patients (a meningioma and an arteriovenous malformation in the roof of the third ventricle), both approaches were combined. One case with a large pineal parenchymal tumor of intermediate differentiation (PPTID) required 3 different approaches: supracerebellar infratentorial, telovelar, and occipital interhemispheric approach to the third ventricle. The unique vein of Galen malformation of this series required a subtemporal approach to resect an associated arteriovenous malformation and an occipital interhemispheric approach after multiple but minimal endovascular procedures. Four recurrent tumors had been operated on in previous years.

Microsurgical Time

The microsurgical time was < 45 minutes in most of the small and medium size pineal lesions. Large and giant tumors (tumors with maximal diameters between 3.71 and 5.5 cm) required longer microsurgical times, between 1 and 2.5 hours (66–151 minutes). The giant vein of Galen malformation was operated on under the microscope for 6.5 hours. We found only a moderate Pearson correlation between the microsurgical time and the volume of the lesions ($P < 0.05$) (**Table 3**).

Surgical Outcome

The mean clinical and radiologic follow-up durations were 25.9 months (range, 0–88 months) and 20.6 months (range, 0–100 months), respectively. A patient with a World Health Organization grade II giant glioma ($3.5 \times 2.6 \times 3.8$ cm) presented with infarction in both thalamic regions and died 1 month after surgery. Some postoperative deficit was present in 11 patients. A patient with a recurrent hemangiopericytoma ($3.1 \times 2.3 \times 2.5$ cm) recovered quite well after some thalamic infarction (modified Rankin scale score 3 at 3-year follow-up). The child with the giant vein of Galen malformation is still very dependent 4 years after treatment (modified Rankin Scale score 4). A patient who had 3 surgeries had slight diplopia and was still using a wheelchair (modified Rankin scale score 4) after 3 years. A foreign patient with immediate postoperative moderate hemiparesis was lost to long-term follow-up. Five patients developed visual deficits that improved during the follow-up period. Two patients had nonspecific neuropsychological disturbances. One patient with an asymptomatic pineal cyst presented with a granulomatous reaction in the surgical site and received medical treatment. All patients, including 18 patients with incidental findings and related symptoms (headaches, depression and other psychological symptoms, vertigo, nonspecific numbness) improved after surgery.

Four patients underwent a subtotal resection and postoperative radiotherapy according to protocols with a good course during follow-up in 3 cases (2 germinomas and 1 PPTID). The other patient with a PPTID required a second surgery 15 months later and had no surgical complications. Four patients (2 grade II PPTID, 1 hemangioblastoma, and 1 pilocytic astrocytoma) required

Table 2. Characteristics of Patients with Pineal Region Lesions Operated in Sitting Position Between 2008 and 2015

Characteristic	Value
Age, years, mean \pm SD; Min, Max	34.5 \pm 19; 2, 79
Sex, male/female	28/28
Surgical treatment	
Total resection*	52 (92.7%)
Partial resection	4 (7.3%)
Surgical time (skin to skin), minutes, mean \pm SD; Min, Max	115.6 \pm 61; 60, 480
Microsurgical time, minutes	
Pineal lesions, mean \pm SD; Min, Max	47.3 \pm 31; 12, 152
Vein of Galen malformation	386
Diagnosis	
Tumors	51 (91.1%)
Pineal cysts	23
Parenchymal tumors of intermediate differentiation (grade II)	5
Pineal germinomas	5
Meningiomas	4
Pilocytic astrocytomas	3
Grade II diffuse astrocytomas	2
Hemangioblastomas	1
Ependymoma (grade II)	1
Epidermoid tumor	1
Glioblastoma multiforme	2
Hemangiopericytoma	
Papillary tumor of the pineal region	1
Parenchymal tumor of intermediate differentiation (grade III)	1
Solitary fibrous tumor of the pineal region	1
Vascular lesions	5 (8.9%)
Arteriovenous malformations (1 case associated with PChA aneurysm)	2
Cavernous malformation	1
Posterior choroidal artery aneurysm	1
Vein of Galen malformation	1
Size of pineal lesions, cm, mean \pm SD; Max, Min	
X	2.5 \pm 1.2; 6, 0.5
Y	2.2 \pm 1.1; 5.41, 0.5
Z	2.1 \pm 1.1; 5.47, 0.5
Minor venous air embolism	19 (34%)
Severe venous air embolism	0 (0%)
Continues	

Table 2. Continued

Characteristic	Value
Pneumocephalus	100%
Subdural pneumocephalus	85%
Intraventricular pneumocephalus	78%
Min, minimum value; Max, maximum value; PChA, posterior choroidal artery; X, anteroposterior length; Y, axial width; Z, height.	
*Regarding vascular lesions, all arteriovenous malformations and cavernomas were completely resected, and all aneurysms were totally occluded.	

multiple surgeries owing to recurrences after complete resections without complications.

Complications with Praying Position

Minor VAE was observed in 19 (34%) cases. Capnography (decrease of end-tidal P_{CO_2} $>$ 5.25 mm Hg) was used for the diagnosis in 16 cases, precordial Doppler ultrasound was used in 7 cases, and the air leak was identified at the surgical site in 3 cases. In 3 of the 19 cases, the decrease of end-tidal P_{CO_2} did not fulfill the criteria, and the VAE was diagnosed only on the basis of a variation of the precordial Doppler ultrasound. Severe VAE was nonexistent in our series. However, we had 3 adult patients (a pineal cyst, a solitary fibrous tumor, and an arteriovenous malformation) with a very short period (1 measurement in a 5-minute interval) of low systolic blood pressure associated with VAE that was rapidly corrected with routine vasoactive agents and fluid filling. Mean arterial pressure was $>$ 50 mm Hg in 2 cases and $>$ 45 mm Hg in 1 case. No immediate or late postoperative complications were observed in those patients. When VAE was suspected, an immediate reaction based on good teamwork and proper communication between the anesthesiologist and surgeon was imperative. Compression of both jugular veins by the anesthesiologist was very effective to find the leak, and repair with hemostatic agents or direct suturing was performed by the surgeon. Air aspiration from the venous central catheter was never used.

No cervical spine cord injury, no facial or tongue edema, and no peripheral nerve damage were reported. Postoperative computed tomography scan revealed pneumocephalus in all patients, but none required surgical decompression.

DISCUSSION

Key Results

In our department, classic sitting position was commonly used until the 1980s. Then the technical construction of the praying position was carefully revised and reintroduced in 1997 for the management of pineal and some posterior fossa lesions.^{7,8,10} Good teamwork and proper communication between the anesthesiologist and the surgeon, an ergonomic position for the surgeon, and quick and effective surgical management of pineal lesions, help to make the praying sitting position protocol a simple, effective, and safe way to approach the pineal region lesions.

Table 3. Correlations Between Microsurgical Time, Patient Age, and Volume of Lesions

		Microsurgical Time (minutes)	Patient Age (years)	Volume of Lesion (cm ³)
Microsurgical time (minutes)	Pearson correlation	1	0.090	0.649*
	2-tailed <i>P</i> value		0.536	0.000
	Number	51	50	51
Patient age (years)	Pearson correlation	0.090	1	0.067
	2-tailed <i>P</i> value	0.536		0.644
	Number	50	65	50
Volume of lesion (cm ³)	Pearson Correlation	0.649*	0.067	1
	2-tailed <i>P</i> value	0.000	0.644	
	Number	51	50	51

*Correlation is significant at 0.01 level (2-tailed).

Interpretation

The senior author (J.A.) previously reported the surgical outcomes of 119 pineal lesions that were operated on between 1980 and 2007.⁷ The percentage of total resection was 88% compared with the 93% in this series. Benign pineal tumors were the most prevalent diagnoses in both series, and all tumors were completely excised.

The literature is inconclusive about complications resulting from the sitting position, and several protocols may be effectively used in the clinical setting to prevent major complications.¹¹⁻¹⁷ In a systematic review of craniotomy studies comparing sitting and horizontal positions, the incidence of VAE was 15%–45% and 0%–12%, respectively.^{8,18} The incidence of severe VAE in sitting position was found to be 1%–6% in 6 large studies.^{3,19-23} Although previous series from our department described the occurrence of minor VAE in the sitting position, no case of severe VAE was reported.^{7,8,24} Moreover, no difference in administered vasoactive agents, intraoperative fluids, or postoperative management in patients with and without VAE was reported.^{8,25}

It is well known that the risk for VAE is directly related to the damage and the opening of venous structures during the surgery and to the low cardiac preload conditioned by the position. In this regard, skillful and clean microneurosurgery preserving the normal anatomy is imperative during pineal region operations.^{9,26-32} This, together with the use of antigraivty trousers (offering a sufficient cardiac preload while allowing ergonomic surgical positioning) and proper teamwork (which permits quick management of the complication), may reduce the risk of severe VAE. In our department, positive end-expiratory pressure has been never used in patients operated on in the upright position because it increases the intracranial pressure and removes the advantages of the sitting position.³³

Many neurosurgeon refuse to operate on pineal lesions in the sitting position to avoid a long, tiring standing procedure. In this regard, correct sitting positioning of the patient should allow and support an ergonomic posture of the surgeon, preventing

muscular fatigue during the procedure. In our series, the average microsurgical time for most of the pineal lesions except the vein of Galen malformation was about 45 minutes. Three factors are important to maintain an ergonomic working position for the surgeon during sitting position surgery: 1) the head of the patient should be positioned in such a way that the horizontal axis of the tentorium is parallel to the floor and with <90° in relation to the axis of the surgeon, 2) the patient's upper torso should be properly elevated and the head tilted 20°–30° forward enough to keep 2 fingers between the chin and the sternum (thus preventing spinal cord damage) to allow to the surgeon to support his or her arms on the shoulders of the patient while performing the procedure, and 3) a properly balanced operating microscope with a mouth piece should be used.

Regarding the other complications associated with the sitting position, our rate of pneumocephalus was higher than reported before owing to regular and immediate control computed tomography scans. However, none of the cases required surgical decompression, as pneumocephalus gradually resolved (intraventricular pneumocephalus more slowly than subdural pneumocephalus). Rarely, patients with large pneumocephalus required mechanical ventilation with high partial pressures of oxygen.^{8,34}

According to our experience, with a simple set of craniotomy and microsurgical instruments, the supracerebellar infratentorial approach may be used for most pineal lesions. Microsurgery of pineal lesions requires long instruments and is impossible without them. An occipital interhemispheric approach may be required in case of an important supratentorial component or for vein of Galen malformations. Occasionally, tumors with large diameters require a combined approach (supracerebellar infratentorial with occipital interhemispheric or telovelar approach). Small tumoral remnants at the level of their inferiormost extensions were observed for 3 large tumors operated on through a supracerebellar infratentorial approach. In this regard, we believe that an intraoperative endoscopic control in case of large and giant lesions would increase the accuracy of the resection.³⁵

Limitations

A limitation of this study is that a comparative control group of patients operated on in another surgical position is not included.

CONCLUSIONS

Pineal lesions may be managed in a simple, safe, and effective way with a protocolized schema for positioning of the patient, careful consideration of the surgical approach, skillful microneurosurgery, and proper teamwork. The praying position represents a simple,

fast, and safe approach for proper placement of the patient for the pineal region surgery. The step-by-step protocol we illustrate may allow this position to be safely and effectively used in different neurosurgical centers.

ACKNOWLEDGMENTS

The C. Ehrnrooth Foundation partially supports the present study, which is part of the Pineal Region Surgery project.

REFERENCES

- Dohn DF, Gardner WJ. The antigravity suit (G-suit) in surgery; control of blood pressure in the sitting position and in hypotensive anesthesia. *J Am Med Assoc.* 1956;162:274-276.
- Yonekawa Y. Operative neurosurgery: personal view and historical backgrounds (8) suboccipital craniotomy-sitting position-linear incision [in Japanese] *No Shinkei Geka.* 2011;39:789-809.
- Slbin MS, Babinski M, Maroon JC, Jannetta PJ. Anesthetic management of posterior fossa surgery in the sitting position. *Acta Anaesthesiol Scand.* 1976; 20:117-128.
- Ganslandt O, Merkel A, Schmitt H, Tzabazis A, Buchfelder M, Eyupoglu I, et al. The sitting position in neurosurgery: indications, complications and results. A single institution experience of 600 cases. *Acta Neurochir (Wien).* 2013;155:1887-1893.
- Porter JM, Pidgeon C, Cunningham AJ. The sitting position in neurosurgery: a critical appraisal. *Br J Anaesth.* 1999;82:117-128.
- Black S, Ockert DB, Oliver WC, Cucchiara RF. Outcome following posterior fossa craniectomy in patients in the sitting or horizontal positions. *Anesthesiology.* 1988;69:49-56.
- Hernesniemi J, Romani R, Albayrak BS, Lehto H, Dashti R, Ramsey C 3rd, et al. Microsurgical management of pineal region lesions: personal experience with 119 patients. *Surg Neurol.* 2008;70:576-583.
- Lindroos A-C, Niiya T, Randell T, Romani R, Hernesniemi J, Niemi T. Sitting position for removal of pineal region lesions: the Helsinki experience. *World Neurosurg.* 2010;74:505-513.
- Velasquez JC, Lau J, Kozyrev D, Sharafeddin F, Colasanti R, Luostarinen T, et al. Clean, fast and preserving normal anatomy: "the Helsinki revolution" in microneurosurgery. *J Neurosurg Sci.* 2016;60: 44-53.
- Choque-Velasquez J, Colasanti R, Resendiz-Nieves JC, Jahromi BR, Kozyrev DA, Thiarawat P, et al. Supracerebellar infratentorial paramedian approach in Helsinki neurosurgery: cornerstones of a safe and effective route to the pineal region. *World Neurosurg.* 2017;105:534-542.
- Ammirati M, Theeb Lamki T, Brian Shaw A, Forde B, Nakano I, Mani M. A streamlined protocol for the use of the semi-sitting position in neurosurgery: a report on 48 consecutive procedures. *J Clin Neurosci.* 2013;20:32-34.
- Colasanti R, Tailor A-RA, Zhang J, Ammirati M. Expanding the horizon of the suboccipital retrosigmoid approach to the middle incisural space by cutting the tentorium cerebelli: anatomic study and illustration of 2 cases. *World Neurosurg.* 2016; 92:303-312.
- Colasanti R, Tailor A-RA, Zhang J, Ammirati M. Functional petrosectomy via a suboccipital retrosigmoid approach: guidelines and topography. *World Neurosurg.* 2016;87:143-154.
- Colasanti R, Tailor A-RA, Lamki T, Zhang J, Ammirati M. Maximizing the petroclival region exposure via a suboccipital retrosigmoid approach: where is the intrapetrous internal carotid artery? *Neurosurgery.* 2015;11(suppl 2):329-336 [discussion: 336-337].
- Colasanti R, Tailor A-RA, Gorjian M, Zhang J, Ammirati M. Microsurgical and endoscopic anatomy of the extended retrosigmoid infratemporal approach. *Neurosurgery.* 2015; 11(suppl 2):181-189 [discussion: 189].
- Colasanti R, Lamki T, Tailor A-RA, Ammirati M. Recurrent atlantoaxial synovial cyst resection via a navigation-guided, endoscope-assisted posterior approach. *Surg Neurol Int.* 2014;5(suppl 15): S567-569.
- Jadik S, Wissing H, Friedrich K, Beck J, Seifert V, Raabe A. A standardized protocol for the prevention of clinically relevant venous air embolism during neurosurgical interventions in the semi-sitting position. *Neurosurgery.* 2009;64:533-538 [discussion: 538-539].
- Fathi A-R, Eshtheardi P, Meier B. Patent foramen ovale and neurosurgery in sitting position: a systematic review. *Br J Anaesth.* 2009;102:588-596.
- Duke DA, Lynch JJ, Harner SG, Faust RJ, Ebersold MJ. Venous air embolism in sitting and supine patients undergoing vestibular schwannoma resection. *Neurosurgery.* 1998;42:1282-1286 [discussion: 1286-1287].
- Harrison EA, Mackerse A, McEwan A, Facer E. The sitting position for neurosurgery in children: a review of 16 years' experience. *Br J Anaesth.* 2002; 88:12-17.
- Matjasko J, Petrozza P, Cohen M, Steinberg P. Anesthesia and surgery in the seated position: analysis of 554 cases. *Neurosurgery.* 1985;17:695-702.
- Standefer M, Bay JW, Trusso R. The sitting position in neurosurgery: a retrospective analysis of 488 cases. *Neurosurgery.* 1984;14:649-658.
- Young ML, Smith DS, Murtagh F, Vasquez A, Levitt J. Comparison of surgical and anesthetic complications in neurosurgical patients experiencing venous air embolism in the sitting position. *Neurosurgery.* 1986;18:157-161.
- Lindroos A-CB, Niiya T, Silvasti-Lundell M, Randell T, Hernesniemi J, Niemi TT. Stroke volume-directed administration of hydroxyethyl starch or Ringer's acetate in sitting position during craniotomy. *Acta Anaesthesiol Scand.* 2013;57: 729-736.
- Giebler R, Kollenberg B, Pohlen G, Peters J. Effect of positive end-expiratory pressure on the incidence of venous air embolism and on the cardiovascular response to the sitting position during neurosurgery. *Br J Anaesth.* 1998;80:30-35.
- Choque-Velasquez J, Colasanti R, Fotakopoulos G, Elera-Florez H, Hernesniemi J. Seven cerebral aneurysms: a challenging case from the Andean slopes managed with 1-stage surgery. *World Neurosurg.* 2017;97:565-570.
- Choque-Velasquez J, Colasanti R, Jahromi BR, Hernesniemi J. "Squeeze maneuver" assisted by indocyanine green videoangiography: simple technique to "resuscitate" partially occluded bridging veins during microneurosurgical operations. *World Neurosurg.* 2017;97:225-230.
- Choque-Velasquez J, Colasanti R, Jahromi BR, Rafei A, Sharafeddin F, Hernesniemi J. Short-burst bipolar coagulation for repairing partially damaged brain arteries preserving their flow: technical note. *World Neurosurg.* 2016;93:324-329.
- Choque-Velasquez J, Colasanti R, Baffigo-Torre V, Sacieta-Carbajo LE, Olivari-Heredia J, Falcon-Lizaraso Y, et al. Developing the first highly specialized neurosurgical center of excellence in Trujillo, Peru: work in progress, first four months results. *World Neurosurg.* 2017;102:334-339.
- Sharafeddin F, Hafez A, Lehecka M, Raj R, Colasanti R, Rafei A, et al. A5 segment aneurysm of the anterior cerebral artery, imbedded into the body of the corpus callosum: a case report. *Surg Neurol Int.* 2017;8:18.
- Choque-Velasquez J, Kozyrev DA, Colasanti R, Thiarawat P, Intarakhao P, Jahromi BR, et al. The open access video collection project "Hernesniemi's 1001 and more microsurgical videos of Neurosurgery": a legacy for educational purposes. *Surg Neurol Int.* 2017;8:188.
- Choque-Velasquez J, Colasanti R, Kozyrev DA, Hernesniemi J, Kawashima A. Moyamoya disease

- in an 8-year-old boy: direct bypass surgery in a province of Peru. *World Neurosurg.* 2017;108:50-53.
33. Luostarinen T, Lindroos A-C, Niiya T, Silvasti-Lundell M, Schramko A, Hernesniemi J, et al. Prone versus sitting position in neurosurgery—differences in patients' hemodynamic management. *World Neurosurg.* 2017;97:261-266.
34. Sloan T. The incidence, volume, absorption, and timing of supratentorial pneumocephalus during posterior fossa neurosurgery conducted in the sitting position. *J Neurosurg Anesthesiol.* 2010;22:59-66.
35. Iacoangeli M, Colasanti R, Esposito D, Di Rienzo A, di Somma L, Dobran M, et al. Supra-orbital subfrontal trans-laminar endoscope-assisted approach for tumors of the posterior third ventricle. *Acta Neurochir (Wien).* 2017;159:645-654.

Conflict of interest statement: J. Hernesniemi is a consultant for Aesculap. The remaining authors have no conflicts to report.

Received 22 August 2017; accepted 17 February 2018

Citation: *World Neurosurg.* (2018) 113:e604-e611.
<https://doi.org/10.1016/j.wneu.2018.02.107>

Journal homepage: www.WORLDNEUROSURGERY.org

Available online: www.sciencedirect.com

1878-8750/\$ - see front matter © 2018 Elsevier Inc. All rights reserved.