

Case report

Clinically variable nemaline myopathy in a three-generation family caused by mutation of the skeletal muscle alpha-actin gene

Vilma-Lotta Lehtokari ^{a,*}, Maria Gardberg ^b, Katarina Pelin ^{a,c}, Carina Wallgren-Pettersson ^a

^a The Folkhälsan Institute of Genetics and the Department of Medical and Clinical Genetics, University of Helsinki, Helsinki, Finland

^b Department of Pathology, Turku University Hospital and University of Turku, Turku, Finland

^c Department of Biosciences, Division of Genetics, University of Helsinki, Helsinki, Finland

Received 21 August 2017; received in revised form 11 December 2017; accepted 18 December 2017

Abstract

We present here a Finnish nemaline myopathy family with a dominant mutation in the skeletal muscle α -actin gene, p.(Glu85Lys), segregating in three generations. The index patient, a 5-year-old boy, had the typical form of nemaline myopathy with congenital muscle weakness and motor milestones delayed but reached, while his mother never had sought medical attention for her very mild muscle weakness, and his maternal grandmother had been misdiagnosed as having myotonic dystrophy. This illustrates the clinical variability in nemaline myopathy.

© 2017 Elsevier B.V. All rights reserved.

Keywords: Nemaline myopathy; Dominant inheritance; Skeletal muscle alpha-actin; Three-generation family; Clinical variability

1. Introduction

To date, more than 200 different pathogenic variants have been identified in the α -actin 1 gene (*ACTA1*). The vast majority, over 170 of these disease-causing variants, cause nemaline myopathy (NM), but variants in *ACTA1* may cause a wide spectrum of myopathies, clinically varying from lethal fetal akinesia to disorders with mild muscle weakness [1,2]. In addition to NM, *ACTA1* myopathies include actin myopathy, cap myopathy, congenital fibre-type disproportion, core-rod myopathy, intranuclear rod myopathy, zebra body myopathy, and progressive scapuloperoneal myopathy. Recently, dominant mutations in *ACTA1* have been identified as the cause of a dominant distal myopathy with nemaline rods [3–11]. Correspondingly, the muscle histopathology of patients with *ACTA1* mutations is diverse. The spectrum encompasses nemaline bodies, actin filament aggregates, core structures, caps, fibre-type disproportion, zebra bodies, and dystrophic features. In some patients with muscle weakness, only minimal histological changes have been detected. Diagnostics based on muscle histopathology can thus be very difficult; the clinical and histological features overlap

between entities, and one single muscle biopsy may show a combination of different histopathologies [9,12].

The most common myopathy related to *ACTA1* is NM. We have estimated that variants in *ACTA1* cause 23% of NM cases. *ACTA1* variants are the most common cause of sporadic NM, and a common cause of very severe (lethal) forms with fetal akinesia also. Most of the pathogenic variants in *ACTA1* are dominant (90%) and a majority of the dominant variants have arisen *de novo*. Of the sporadic cases with *ACTA1* variants, approximately 85% have been shown to be caused by *de novo* variants. Autosomal recessive variants are rarer (10%). Dominant variants inherited across two or more generations have been identified in less than 5% of *ACTA1* families, while mosaicism has been observed in a couple of families [12,13].

2. Clinical features in the three affected family members

2.1. Clinical findings and molecular diagnostic investigations

In the Finnish family described here, a 5-year-old boy underwent investigations because of generalised muscle weakness. His motor milestones were delayed but reached. He was a bright boy who did well at school. The clinical examination showed lumbar hyperlordosis, myopathic facies and high-arched palate (Fig. 1A–D). Muscle bulk was small and weakness was of grade 4 on the MRC scale in all muscle groups, while the facial muscles were weaker, and the neck flexors showed weakness of grade 2. A diagnosis of NM was made on the basis of muscle

* Corresponding author. The Folkhälsan Institute of Genetics and the Department of Medical and Clinical Genetics, Biomedicum Helsinki, University of Helsinki, Box 63 (Haartmaninkatu 8) 00014 Helsinki, Finland.

E-mail address: vilma.lehtokari@helsinki.fi (V.-L. Lehtokari).

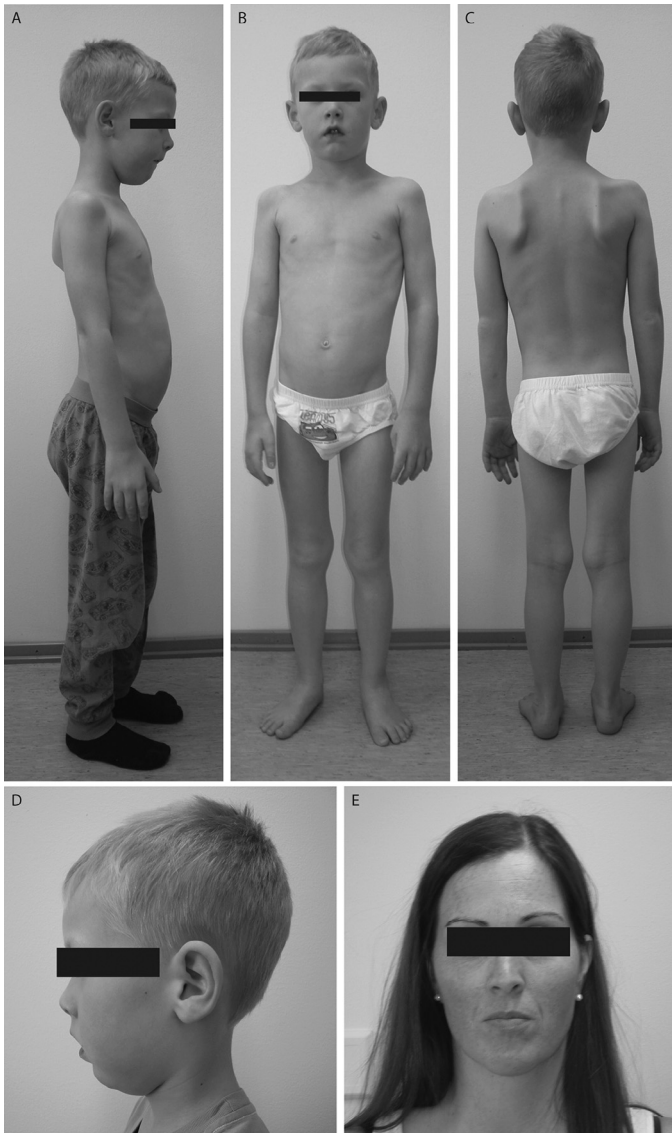

Fig. 1. The proband (A–D): a 5-year-old boy, with myopathic facies, slender build and hyperlordosis. His mother (E) has slight hypomimia and mild weakness of the neck flexors, grip strength and quadriceps muscles.

biopsy findings including the presence of nemaline bodies (Fig. 2A). His NM was classified as typical.

The genetic cause was subsequently sought for by sequencing of the nebulin gene for the known Finnish variants, and of the entire *ACTA1*, resulting in the identification of a missense variant, p.(Glu85Lys), in *ACTA1*. This variant had previously been identified in two unrelated NM patients as *de novo* mutations, and thus the variant was known to be pathogenic [14]. DNA samples of the family were subsequently sequenced to check the segregation of the variant.

The same variant was identified in the mother of the index patient, and she was then clinically examined. She was found to have mild weakness of the neck flexors, grip strength and quadriceps muscles, consistent with the mild form of NM (Fig. 1E). A detailed history revealed that she had always had slight motor difficulties although she had reached her motor

milestones without any observed delay. She had, however, never sought medical attention for her motor problems. Her biopsy, performed at the age of 36 years, showed numerous nemaline bodies (Fig. 2B).

After identification of the dominantly inherited mutation in the family, a DNA sample of the boy's deceased maternal grandmother was also sequenced for the variant. She had presented at the age of 44 years with muscle weakness. She had always worn high heels and had contractures of the Achilles tendons. EMG showed myopathic features while CK levels were normal. At the time, she was misdiagnosed as having myotonic dystrophy. The grandmother also had arthrosis, gall stones, hypothyreosis, high blood pressure and kidney stones. She died of cancer of the urinary tract at the age of 68 years. On re-examination of the muscle biopsy, it was found to show nemaline bodies (Fig. 2C). Her diagnosis was confirmed by the identification of the same *ACTA1* variant in her. She can in retrospect be thought to have had the mild form of NM. Her father was said to have had weak legs, and he had to use his arms for getting up from a chair.

2.2. Histology

Muscle biopsy of the vastus lateralis had been done in the three affected family members. In all three biopsies, Gömöri trichrome staining revealed abundant cytoplasmic nemaline bodies (Fig. 2A–C). Fibre size variability (Fig. 2D–F) was less apparent in the proband's biopsy (Fig. 2D) than in mother's (E) and grandmother's (F) biopsies. Only the grandmother's biopsy showed a clearly increased number of internal nuclei as well as split fibres (Fig. 2F). In addition, on NADH staining (Fig. 2G–I) a few core-like structures were seen in the biopsy of the grandmother (Fig. 2I), while core structures were not seen in the biopsies of the proband or mother (Fig. 2G,H). Myosin double staining of myosin heavy chain fast and slow (Fig. 2J,K) showed type 1 fibre uniformity and abnormal fibre size variability in the proband (Fig. 2J). The mother's biopsy showed mild fibre type 1 predominance, type 1 fibre atrophy and type 2 fibre hypertrophy. In addition, several immature hybrid fibres were present (Fig. 2K). The grandmother's biopsy is no longer available for double staining. However, the pathologist's report mentions fibre type 1 predominance and atrophy.

Electron microscopy was performed on muscle samples from the proband and mother. Both had typical intracytoplasmic nemaline rods. No intranuclear rods were found.

3. Variant prediction using the *in silico* tool

The *ACTA1* variant p.(Glu85Lys) was analysed using the HOPE tool (<http://www.cmbi.ru.nl/hope>), which predicts the 3D model of the protein of interest using WHAT IF web services. HOPE predicts how the variant affects the protein structure and function. Amino acid residue 85 is a glutamic acid in wild-type (wt) actin, located on the surface of the protein, this residue being 100 % conserved. The glutamic acid at position 85 forms a hydrogen bond with threonine at position

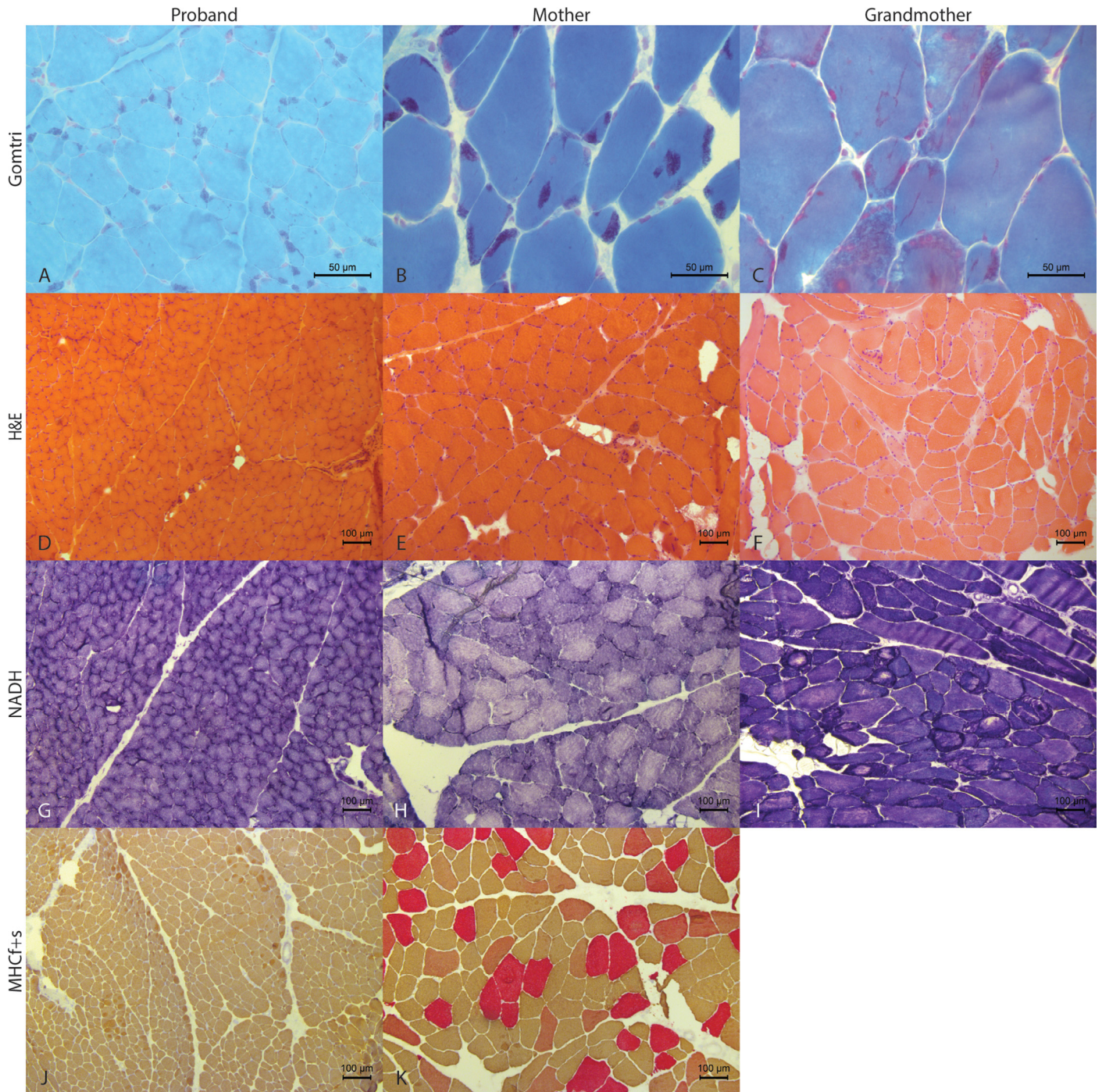


Fig. 2. Histological findings in muscle biopsies from the proband, the mother and the grandmother. Gömöri trichrome staining (A–C): in all three biopsies, aggregations of nemaline bodies are seen as dark-staining areas. H&E staining (D–F): fibre size variability is most apparent in the mother's (E) and grandmother's (F) biopsies. NADH staining (G–I) shows fibre type uniformity in the proband's (G) and the grandmother's (I) biopsies as only strongly reacting type I fibres are present. The grandmother's biopsy additionally reveals a few core-like centrally unstained fibres. In the mother's biopsy (H), NADH staining is unremarkable. MHC double staining (J,K): fast (red) and slow (brown) demonstrates fibre type 1 uniformity in the proband's biopsy (J). The mother's biopsy (K) shows slight predominance and atrophy of type 1 fibres. Some hypertrophic type 2 fibres are seen, as well as red-brown immature hybrid fibres.

128, and a salt bridge with lysine at position 120. The function of the residue at position 85 is not known, neither is it known whether Glu85 binds to other molecules. The variant discussed here changes a glutamine to a lysine, p.(Glu85Lys). Glutamic acid is smaller than lysine, and it is positively charged, while

lysine is negatively charged. Lysine instead of glutamine at position 85 is unable to form the hydrogen bond and the salt bridge present in wt actin. The variant therefore changes the structure of the protein and likely disrupts the correct function of the protein.

4. Discussion

To our knowledge, the family described here is the first NM family with a pathogenic dominant variant of *ACTA1* present in three generations. In this Finnish NM family, the variant p.(Glu85Lys) was found to be present in a 5-year-old boy, his mother and his maternal grandmother, who had probably inherited it from her father. All these family members were found to have NM, verified by muscle biopsy.

The same variant has been described in the literature as a *de novo* mutation in two unrelated patients of American origin [14]. Thus, the variant was known to be pathogenic, and therefore, further mutational analyses were not performed in the current family.

Both of the patients described in the previous publication [14] were boys with the typical form of NM. Hypotonia was noted at the age of three months in patient 349-1. At the age of three years he was ambulant, and had no respiratory or feeding issues at the time. Electron microscopy was not performed. The second patient, 349-2, showed hypotonia at birth. His motor milestones were delayed; he achieved sitting at the age of 9 months and walking at 16 months. He, too, was ambulant at the age of three years and did not have feeding or respiratory problems at the time. His muscle biopsy showed marked type 1 fibre predominance, moderate fibre size variability, scattered and group atrophy, and numerous nemaline bodies [14].

The largest single actinopathy pedigree published to date depicts an extended family of six generations with a dominant, progressive scapuloperoneal neuromuscular disorder, shown to be caused by the *ACTA1* variant p.(Glu197Asp). No nemaline rods or actin aggregates were observed in the muscle biopsies examined [10].

The family described here is one more example of how the clinical and histological features of NM may be variable, even between family members sharing the same mutation. This variability is likely due to both environmental and genetic modifying factors.

Acknowledgements

The authors thank PhD Student Lydia Sagath for helping with the illustrations, and the Sigrid Jusélius Foundation, the Association Française contre les Myopathies, the Finska

Läkarsällskapet and the Medicinska Understödsföreningen Liv och Hälsa for funding.

References

- [1] Nowak KJ, Ravenscroft G, Laing NG. Skeletal muscle alpha-actin diseases (actinopathies): pathology and mechanisms. *Acta Neuropathol* 2013;125:19–32.
- [2] Moreno CAM, Abath Neto O, Donkervoort S, Hu Y, Reed UC, Oliveira ASB, et al. Clinical and histologic findings in ACTA1-related nemaline myopathy: case series and review of the literature. *Pediatr Neurol* 2017;75:11–16.
- [3] Nowak KJ, Wattanasirichaigoon D, Goebel HH, Wilce M, Pelin K, Donner K, et al. Mutations in the skeletal muscle alpha-actin gene in patients with actin myopathy and nemaline myopathy. *Nat Genet* 1999;23:208–12.
- [4] Goebel HH, Brockmann K, Bonnemann CG, Warlo IA, Hanefeld F, Labeit S, et al. Actin-related myopathy without any missense mutation in the ACTA1 gene. *J Child Neurol* 2004;19:149–53.
- [5] Hung RM, Yoon G, Hawkins CE, Halliday W, Biggar D, Vajsar J. Cap myopathy caused by a mutation of the skeletal alpha-actin gene ACTA1. *Neuromuscul Disord* 2010;20:238–40.
- [6] Laing NG, Clarke NF, Dye DE, Liyanage K, Walker KR, Kobayashi Y, et al. Actin mutations are one cause of congenital fibre type disproportion. *Ann Neurol* 2004;56:689–94.
- [7] Kaindl AM, Ruschendorf F, Krause S, Goebel HH, Koehler K, Becker C, et al. Missense mutations of ACTA1 cause dominant congenital myopathy with cores. *J Med Genet* 2004;41:842–8.
- [8] Goebel HH, Warlo I. Nemaline myopathy with intranuclear rods—intranuclear rod myopathy. *Neuromuscul Disord* 1997;7:13–19.
- [9] Sewry CA, Holton JL, Dick DJ, Muntoni F, Hanna MG. Zebra body myopathy is caused by a mutation in the skeletal muscle actin gene (ACTA1). *Neuromuscul Disord* 2015;25:388–91.
- [10] Zukosky K, Meilleur K, Traynor BJ, Dastgir J, Medne L, Devoto M, et al. Association of a novel ACTA1 mutation with a dominant progressive scapuloperoneal myopathy in an extended family. *JAMA Neurol* 2015;72:689–98.
- [11] Liewluck T, Sorenson EJ, Walkiewicz MA, Rumilla KM, Milone M. Autosomal dominant distal myopathy due to a novel ACTA1 mutation. *Neuromuscul Disord* 2017;27:742–6.
- [12] Laing NG, Dye DE, Wallgren-Pettersson C, Richard G, Monnier N, Lillis S, et al. Mutations and polymorphisms of the skeletal muscle alpha-actin gene (ACTA1). *Hum Mutat* 2009;30:1267–77.
- [13] Witting N, Werlauff U, Duno M, Vissing J. Prevalence and phenotypes of congenital myopathy due to alpha-actin 1 gene mutations. *Muscle Nerve* 2016;53:388–93.
- [14] Agrawal PB, Strickland CD, Midgett C, Morales A, Newburger DE, Poulos MA, et al. Heterogeneity of nemaline myopathy cases with skeletal muscle alpha-actin gene mutations. *Ann Neurol* 2004;56:86–96.