

Doctoral Programme in Clinical Research
University of Helsinki
Department of Vascular Surgery
Helsinki University Hospital

ABDOMINAL AORTIC INFECTIONS

MIKA HEINOLA

ACADEMIC DISSERTATION

To be presented, with the permission of the Faculty of Medicine of the University of Helsinki, for public examination in lecture room I, Haartman Institute building, on May 31st, 2019, at 12 noon.

Helsinki 2019

Supervised by:

Professor Maarit Venermo
Department of Vascular Surgery
University of Helsinki and Helsinki University Hospital
Helsinki, Finland

Adjunct professor Ilkka Kantonen
Department of Vascular Surgery
University of Helsinki and Helsinki University Hospital
Helsinki, Finland

Reviewed by:

Adjunct professor Matti Pokela
Department of Vascular Surgery
Oulu University Hospital, Oulu, Finland

Adjunct professor Janne Laine
Department of Medicine, Division of Infectious Diseases
Tampere University Hospital, Tampere, Finland

Discussed with:

Professor Anders Wanhainen
Department of Vascular Surgery
Uppsala University Hospital, Uppsala, Sweden

Cover art by Juba

© 2019 Ivika Heinola

ISBN 978-951-51-5229-9 (pbk.)
ISBN 978-951-51-5230-5 (PDF)

Unigrafia
Helsinki 2019

“Don’t underestimate the power of vision and direction. These are irresistible forces, able to transform what might appear to be unconquerable obstacles into traversable pathways and expanding opportunities.”

Jordan B. Peterson

To my family

ABSTRACT

Background. Abdominal aortic infections are rare, but dreaded disorders in vascular surgery. They are linked to high morbidity and mortality. Mycotic aneurysm as a primary infection of the abdominal aorta (MAAA) and an aortic graft infection (AGI) are different entities; however, due to bacterial presence in aorta and perivascular tissue, the principles of management are the same. Owing to the low incidence, high quality evidence is lacking to guide us towards the best surgical treatment method. Uncertainty exists, whether prosthetic aortic reconstructions in infectious conditions are utterly safe or whether biological reconstruction material should be preferred despite some shortcomings in durability.

In complex abdominal surgery encompassing visceral aorta, prolonged aortic clamping above renal arteries is a risk factor for acute ischaemic kidney injury. In such situations, renal protection is recommended in order to avoid irreversible damage and renal replacement therapy.

Aims. The aim of current study was to evaluate the infection resistance and durability of biological grafts as an aortic reconstruction material in abdominal aortic infections (AGI and MAAA) and to estimate the mortality after such reconstructions. Furthermore, efficacy of temporary axillo-renal bypass in prevention of renal ischaemic damage from major aortic surgery was estimated.

Materials. The study comprises two parts. In the first part, 132 patients were retrospectively analysed after being treated for aorto-iliac infections with arterial resection and reconstruction with a biological graft. Study I included patients treated due to AGI with femoral vein grafts, Study II included patients in whom the arterial infection was treated using cryopreserved venous allografts, and Study III included patients who were treated with various biological grafts for a primary aortic infection. The primary endpoints were postoperative mortality and reinfection rates, secondary endpoints were treatment-related mortality, overall mortality and graft reinterventions. During the second part of the study, (Study IV) patients who underwent temporary axillo-renal bypass during a major aortic intervention were retrospectively analysed. Outcome measures were postoperative kidney injury, as defined by means of RIFLE classification, and 30-day mortality. Studies I, II and IV entailed retrospective analyses of patients treated at Helsinki University Hospital, while Study III was multicentre retrospective analysis of patients from six countries.

Results. Sixty-four percent (64%, n=85) of the patients underwent surgery for an abdominal aortic infection with autologous femoral veins (FV), 17% (n=23) with cryopreserved venous allografts (CVA), 9% (n=12) with xenopericardial tube grafts, 5% (n=7) with cryopreserved arterial allografts, and 4% (n=5) with fresh arterial allografts. Most common indications for operation were aortic graft infection (AGI) with an incidence of 51% (n=67) and mycotic abdominal aneurysm (MAAA) with 45% (n=60). The 30-day mortality was 9% for patients treated with FV for an AGI, 9% for patients treated for mixed infectious indications with cryopreserved venous allografts and 5% for patients treated with various biological reconstructions due to MAAA. The respective treatment-related mortality rates in these cohorts were 18%, 13% and 9%. The reinfection rate was 2% (n=3) and 11% (n=14) of the grafts needed reinterventions at the mid-term follow-up, with stenotic lesions in femoral veins as the most common indication (n=9/14). Kaplan-Meier estimation of survival at 5 years was 59% (95% confidence interval, [CI] 43% – 73%) for patients treated with FV due to AGI and 71% (95% CI 52% – 89%) for patients treated with mixed biological materials for MAAA. For patients treated with cryopreserved allografts for mixed indications, estimated survival at 2-years was 70% (95% CI 49% – 91%).

Sixteen patients were operated with temporary axillo-renal bypass during aortic surgery. Despite short median renal ischaemia time of 24.5 minutes, 6 (38%) patients suffered acute kidney injury (AKI), of whom 4 had renal insufficiency preoperatively. One patient needed temporary renal replacement therapy, at one-month follow-up, however, renal function had returned to its baseline level or improved in all patients. The 30-day and in-hospital mortality was nil.

Conclusions. Biological reconstruction material is infection resistant and reasonably durable in midterm analysis. Early postoperative and overall mortality rates are acceptable after treatment of such a complex entity as abdominal aortic infections. Furthermore, temporary axillo-renal bypass is safe and feasible in diminishing acute kidney injury during major aortic surgery.

TABLE OF CONTENTS

| | |
|--|-----------|
| ABSTRACT | 5 |
| TABLE OF CONTENTS | 7 |
| LIST OF ORIGINAL PUBLICATIONS..... | 9 |
| ABBREVIATIONS..... | 10 |
| INTRODUCTION..... | 11 |
| REVIEW OF THE LITERATURE..... | 13 |
| 1 AORTIC GRAFT INFECTION | 13 |
| 1.1 EPIDEMIOLOGY | 13 |
| 1.1.1 <i>Incidence</i> | 13 |
| 1.1.2 <i>Prognosis</i> | 14 |
| 1.2 CLASSIFICATION | 14 |
| 1.2.1 <i>Classification based on time of appearance after implantation</i> | 15 |
| 1.2.2 <i>Szilagy's classification</i> | 15 |
| 1.2.3 <i>Modified Bunt's classification</i> | 16 |
| 1.3 PATHOGENESIS | 16 |
| 1.3.1 <i>Etiology</i> | 16 |
| 1.3.2 <i>Bacteriology</i> | 21 |
| 1.4 PREVENTION | 23 |
| 1.5 DIAGNOSIS..... | 25 |
| 1.5.1 <i>Clinical presentation</i> | 27 |
| 1.5.2 <i>Laboratory findings</i> | 28 |
| 1.5.3 <i>Radiological findings</i> | 29 |
| 2 MYCOTIC ABDOMINAL AORTIC ANEURYSM..... | 32 |
| 2.1 DEFINITION | 32 |
| 2.2 CLASSIFICATION | 32 |
| 2.3 PATHOGENESIS | 34 |
| 2.3.1 <i>Etiology and associated risk factors</i> | 34 |
| 2.3.2 <i>Bacteriology</i> | 36 |
| 2.4 EPIDEMIOLOGY | 38 |
| 2.4.1 <i>Incidence</i> | 38 |
| 2.4.2 <i>Prognosis</i> | 38 |
| 2.5 DIAGNOSIS..... | 39 |
| 2.5.1 <i>Clinical presentation</i> | 39 |
| 2.5.2 <i>Laboratory findings</i> | 40 |
| 2.5.3 <i>Radiological findings</i> | 40 |
| 3 MANAGEMENT OF ABDOMINAL AORTIC INFECTIONS..... | 41 |
| 3.1 IN SITU RECONSTRUCTIONS..... | 41 |
| 3.1.1 <i>Prosthetic grafts</i> | 42 |

| | | |
|-------|---|------------|
| 3.1.2 | <i>Cryopreserved allografts</i> | 44 |
| 3.1.3 | <i>Autologous femoral veins</i> | 45 |
| 3.1.4 | <i>Xenopericardial tube grafts</i> | 47 |
| 3.2 | ENDOVASCULAR REPAIR | 48 |
| 3.3 | AXILLOFEMORAL RECONSTRUCTION | 49 |
| 3.4 | GRAFT PRESERVATION AND CONSERVATIVE TREATMENT | 50 |
| 3.5 | ANTIMICROBIAL THERAPY | 51 |
| 4 | ACUTE KIDNEY INJURY IN THE MANAGEMENT OF AORTIC DISEASE | 53 |
| 4.1 | DEFINITION | 53 |
| 4.1.1 | <i>Staging AKI</i> | 53 |
| 4.2 | PATHOPHYSIOLOGY OF AKI DUE TO ISCHAEMIC INSULT | 55 |
| 4.2.1 | <i>Incidence and prognosis of AKI after aortic surgery</i> | 56 |
| 4.2.2 | <i>Risk factors for AKI</i> | 57 |
| 4.3 | TREATMENT OF AKI | 58 |
| 4.4 | PREVENTION OF AKI DURING AORTIC SURGERY | 59 |
| 4.4.1 | <i>Aortic cross-clamping</i> | 59 |
| 4.4.2 | <i>Pharmacological protection</i> | 59 |
| 4.4.3 | <i>Cold renal perfusion</i> | 60 |
| 4.4.4 | <i>Arterial perfusion</i> | 60 |
| | AIMS OF THE STUDY | 63 |
| | MATERIALS AND METHODS | 65 |
| 1 | PATIENTS AND DATA ANALYSIS | 65 |
| 2 | STATISTICAL ANALYSIS | 69 |
| | RESULTS | 71 |
| 1 | EARLY MORBIDITY AND MORTALITY AFTER BIOLOGICAL AORTIC RECONSTRUCTIONS DUE TO ABDOMINAL AORTIC INFECTIONS (I, II, III) | 71 |
| 2 | INFECTION RESISTANCE OF BIOLOGICAL GRAFTS (I, II, III) | 72 |
| 3 | LATE GRAFT-RELATED MORBIDITY AND OVERALL MORTALITY (I, II, III) | 74 |
| 4 | PREVENTION OF AKI WITH TEMPORARY AXILLO-RENAL BYPASS (IV) | 77 |
| | DISCUSSION | 79 |
| 1 | LIMITATIONS OF THE STUDY | 79 |
| 2 | REINFECTIONS AND INFECTION RESISTANCE | 80 |
| 3 | GRAFT DURABILITY | 81 |
| 4 | MORTALITY | 83 |
| 5 | RENAL PROTECTION (IV) | 84 |
| 6 | FUTURE PROSPECTIVES | 85 |
| | CONCLUSIONS | 87 |
| | ACKNOWLEDGEMENTS | 89 |
| | REFERENCES | 93 |
| | ORIGINAL PUBLICATIONS | 115 |

LIST OF ORIGINAL PUBLICATIONS

This thesis is based on the following publications:

- I Heinola I, Kantonen I, Jaroma M, Albäck A, Vikatmaa P, Aho P, Venermo M. Editor's Choice – Treatment of Aortic Prosthesis Infections by Graft Removal and In Situ Replacement with Autologous Femoral Veins and Fascial Strengthening. *Eur J Vasc Endovasc Surg.* 2016; 51(2):232-9

- II Heinola I, Kantonen I, Mattila I, Albäck A, Venermo M. Cryopreserved venous allografts in suprainguinal reconstructions: A single-centre experience. Submitted.

- III Heinola I, Söreljus K, Wyss TR, Eldrup N, Settembre N, Setacci C, Mani K, Kantonen I, Venermo M. Open Repair of Mycotic Abdominal Aortic Aneurysms with Biological Grafts: An International Multicenter Study. *J Am Heart Assoc.* 2018 Jun 9;7(12). pii: e008104

- IV Heinola I, Halmesmäki K, Kantonen I, Vikatmaa P, Aho P, Lepäntalo M, Venermo M. Temporary Axillorenal Bypass in Complex Aorto-Renal Surgery. *Ann Vasc Surg.* 2016 Feb;31:239-45.

The publications are referred to in the text by their Roman numerals.

ABBREVIATIONS

| | |
|---------|--|
| ABO | A, B, AB and O blood types |
| AEE | aorto-enteric erosion |
| AEF | aorto-enteric fistula |
| AGI | aortic graft infection |
| AKI | acute kidney injury |
| AXBF | axillobifemoral bypass |
| CAA | cryopreserved arterial allograft |
| CI | confidence interval |
| CKD | chronic kidney disease |
| CNS | Coagulase-negative staphylococci |
| CRP | C-reactive protein |
| CT | computed tomography |
| CTA | computed tomography angiography |
| CVA | cryopreserved venous allograft |
| eg | exempli gratia / for example |
| ESRD | end-stage renal disease |
| etc | et cetera /and other similar things |
| EVAR | endovascular aortic repair |
| FDG PET | fluorodeoxyglucose positron emission tomography |
| FU | follow-up |
| FV | femoral vein |
| GFR | glomerular filtration rate |
| GI | gastrointestinal |
| HIV | human immunodeficiency virus |
| HUH | Helsinki University Hospital |
| KDIGO | Kidney Diseases: Improving Global Outcomes |
| MAA | mycotic aortic aneurysm |
| MAAA | mycotic abdominal aortic aneurysm |
| MRI | magnetic resonance imaging |
| MRA | magnetic resonance angiography |
| MRSA | methicillin-resistant <i>Staphylococcus aureus</i> |
| NPWT | negative-pressure wound treatment |
| PCR | polymerase chain reaction |
| PMN | polymorphonuclear cells |
| PTA | percutaneous transluminal angioplasty |
| PTFE | polytetrafluoroethylene |
| RCT | randomised controlled trial |
| RIFLE | Risk, Injury, Failure, Loss and End-stage renal disease – classification |
| RRT | renal replacement therapy |
| SCr | serum creatinine |
| SMC | smooth muscle cells |
| spp | species pluralis / multiple species |
| XPT | xenopericardial tube graft |

INTRODUCTION

Abdominal aortic infections are a challenge for vascular surgeons. Mycotic abdominal aortic aneurysm as a primary aortic infection is the consequence of arterial wall suppuration, and subsequent aneurysmal dilatation with a systemic infection. Rapid growth of the aneurysm sac induces pain and makes aneurysm prone to rupture. Aortic graft infection refers to prosthetic graft's bacterial colonisation after aortic reconstruction. Bacterial inoculation occurs via perioperative contamination, haematogenous seeding or by development of aorto-enteric fistula. Symptoms may range from general malaise to septic shock and gastrointestinal bleeding in case of aorto-enteric fistula. Aortic infections are lethal without treatment and require surgery for the eradication of infection.

The low incidence of 0.2%–3% of all abdominal aortic surgical disorders renders aortic infections rare vascular disorders (Berger *et al* 2015, Söreljus *et al* 2016, Argyrio *et al* 2017). Downside of the rarity of these disorders is the low volume of patients, manifesting as a lack of extensive experience and high-quality evidence concerning best treatment methods. Current recommendations for management are based on single centre experiences and few retrospective multicentre studies. Data are frequently heterogenic, and conclusions are difficult to draw.

In management of abdominal aortic infections, previous gold standard resection of infected aorta and extra-anatomical prosthetic bypass is replaced by in situ reconstructions. However, agreement on best reconstruction material is still lacking. Prosthetic reconstructions are feasible, but considerable risk of reinfection remains due to implantation of prosthetic material among infected tissue. Biological reconstructions are more infection-resistant, but some cause excessive surgical trauma to frail patients, and others are altered by long-term degenerations with lethal complications, or the graft material is difficult to retrieve. General agreement exists that endovascular aortic repair (EVAR) can be used as a bridge method for aortic infections, but in case of primary aortic infection EVAR is implemented as a definitive treatment method in numerous centres.

Therefore, current management practices are individually assigned based on availability of treatment methods as well as centre's experience and surgeons' skills and made compatible with patients' general condition without quality measurements to define the best care possible.

Disorders extending to visceral aorta complicate the treatment even further. Suprarenal aortic clamping and visceral ischaemia increase the morbidity and mortality of aortic disease (Monnot *et al* 2016). Kidneys are the most susceptible to oxygen deprivation

developing an ischaemic injury in less than half an hour, which is frequently exceeded in case of complex anatomy (O'Donnell *et al* 2018). Several protection methods have been developed to diminish postoperative renal impairment; however, some are technically demanding, such as the left heart bypass, and others, such as a cold perfusion, are applicable for a short period only. Therefore, providing physiological pulsatile perfusion with easy access and low additional morbidity would be optimal in any surgery encompassing suprarenal aorta.

In current study we evaluated the infection resistance and durability of biological grafts used as a reconstruction material for abdominal aortic infectious diseases. Furthermore, feasibility of temporary axillo-renal bypass as a renal protection method in major aortic surgery was assessed.

REVIEW OF THE LITERATURE

1 AORTIC GRAFT INFECTION

1.1 EPIDEMIOLOGY

1.1.1 INCIDENCE

The incidence of infection following aortic prosthetic reconstructions depends on the treatment method, indication and anastomotic sites. In case of aorto-iliac reconstruction – a totally intracavitary reconstruction – the reported infection rate is 0.3%–2% and rises up to 3% with distal anastomoses in the groin (Swain *et al* 2004, Vogel *et al* 2008, Berger *et al* 2015). In case of EVAR, the reported incidence remains even lower: 0.2%–1.4% (Antonios *et al* 2006, Hobbs *et al* 2010, Cernohorsky *et al* 2011, Fatima *et al* 2013, Argyrio *et al* 2017, Chafour *et al* 2017, Pettersson *et al* 2017). Aortoenteric fistulas (AEF) as the worst outcome infectious complications were expected to significantly decrease after introduction of endovascular aortic repair. However, albeit paradigm shift has happened, and overall incidence of infection has been reduced, the proportion of AEFs has remained as 1/3 of all AGIs (Reilly *et al* 1984, Fatima *et al* 2013, Kahlberg *et al* 2016, Lejay *et al* 2017). The peculiarity of the application of prosthetic grafts is that the device can get infected years after implantation and therefore overall incidence might be higher in the long term. Several biases affect the reported infection rate. Currently, most iliac occlusions and abdominal aortic aneurysms (AAA) are being treated endovascularly, leaving more time-consuming complex cases and reoperations for open surgery. Prolonged operation time and groin incisions are risk factors for AGI, and the infection rate may therefore seem elevated among patients treated with open repair (Antonios *et al* 2006, Berger *et al* 2015, Cheng *et al* 2017). Most of the AGI cases are concentrated in tertiary-level hospitals due to their complexity and the infection rate in these cohorts may thus appear higher. However, many surgical centres lack data on conservatively threatened patients, since they are treated by internal medicine specialist or do not get referred to surgical unit possibly, thereby lowering the reported incidence. Patients also move and due to peculiarity of late onset of infection, they might be relocated from district of index operation hospital. (Berger *et al* 2015.)

1.1.2 PROGNOSIS

Untreated symptomatic AGI is invariably fatal (Wilson *et al* 2016). The early survival rate of surgically treated AGI patients is currently 89%–92% and estimated 5-year survival 51%–63%. Reinfection is a prevalent treatment-related complication appearing in 4%–11.5% of patients. (Seeger *et al* 2000, Oderich *et al* 2006, Ali *et al* 2009, Harlander-Locke *et al* 2014, Smeds *et al* 2016, Chaoufour *et al* 2017.) In-situ reconstruction with prosthetic material offers the best short-term results, but the long-term outcome remains inferior to in situ reconstructions with biological material due to reinfections (O'Connor *et al* 2006, Batt *et al* 2018).

Patients with AEF carry the worst prognosis in treatment of aortic infectious diseases (Oderich *et al* 2006, Ali *et al* 2009, Chaoufour *et al* 2017). Early survival is 93% for endovascular treatment and 57% for open surgery. The advantage, however, dissolves fast due to the higher rate of infectious complications (69% vs 41%), being 32%–66% for EVAR and 45%–44% for open repair in 2-years. (Danneels *et al* 2006, Bergqvist and Björck 2008, Ali *et al* 2009, Batt *et al* 2011, Chaoufour *et al* 2017.) Estimated 5-year survival for conventionally treated patients with AEF remains reportedly less than 18% (Ali *et al* 2009, Batt *et al* 2011). Nevertheless, meticulous patient selection can result in an excellent 5-year survival of 59% with reinfection rate of 4% only, when AEF patients with no obvious purulence or abscesses are treated with in situ repair (Oderich *et al* 2011).

Infection diagnosis of aortic endograft is an absolute indication for conversion to achieve cure (Chaoufour *et al* 2017, Lyons *et al* 2013). As a consequence of frequent suprarenal fixation, EVAR explantation requires supraceliac or suprarenal aortic clamping and aggressive manipulation of suspension hooks around visceral arteries carrying the risk of vessel dissection and visceral ischaemia. Therefore, risk for postoperative complications and subsequent mortality appears elevated. (Capoggia *et al* 2016, Hobson *et al* 2018, Schaeffers *et al* 2019.) Following the explantation of an infected infrarenal EVAR device, 30-day mortality has been reported to be 26.6%–37.5% and overall mortality during follow-up up to 45.7% (Argyriou *et al* 2017, Schaeffers *et al* 2019).

1.2 CLASSIFICATION

There is no separate classification created especially for AGIs, but surgical site and vascular graft infection classifications take into consideration an intracavitary prosthetic grafts' involvement and are used in literature to classify AGI.

1.2.1 CLASSIFICATION BASED ON TIME OF APPEARANCE AFTER IMPLANTATION

- Early < 4 months after implantation
- Late > 4 months after implantation

This classification is based on the normal disappearance of fluid collections around prosthetic graft to distinguish infectious collections from normal postoperative situation. Early infections appear during the first 4 months after implantation and are generally more aggressive, featuring more virulent bacteria (*Staphylococcus aureus*, gram-negative bacteria) than late infections. Contamination is usually perioperative, due to a breakdown of asepsis or poor skin preparation or occurs during early postoperative period via wound infection or haematogenous route. Infection is often hospital-acquired and presents with fever, elevated biological markers, and it may evolve to sepsis. (Goldstone and Moore 1974, Szilagy *et al* 1972.) Late infections can also be acquired during the graft implantation, but causative agent is usually low-virulent bacteria, such as *Staphylococcus epidermidis*, which is capable of remaining indolent for years encased in biofilm. The infection may present with unexplainable fever episodes or manifest as systemic signs after stress caused by reoperation or superinfection. Cultures of low-symptomatic perigraft tissue or fluid may reveal no bacterial growth (Bandyk *et al* 1991). If late AGI presents with gram-negative bacteraemia, aorto-enteral erosion (AAE) or AEF must be suspected (Inui and Bandyk 2015).

1.2.2 SZILAGY'S CLASSIFICATION

Szilagy classified wound infections in vascular surgery according to the depth of involvement.

- Grade I – infection in dermal layer only
- Grade II – infection extends to subcutaneous tissue, but does not involve arterial prosthesis
- Grade III – infection involves arterial vascular prosthesis

Grade I and II are superficial, appear in early postoperative period and often heal with adequate treatment with no significant clinical sequelae. AGI is classified as Grade III infection and despite its' very low incidence, poses vast challenges in treatment and carries high morbidity and mortality. (Szilagi *et al* 1972.)

1.2.3 MODIFIED BUNT'S CLASSIFICATION

Bunt's classification is based on the extent of graft involvement and the presence of complications (Bunt 1983, Cornenwett and Johnston 2010). In addition to aortic graft infections, original classification also includes infections of extra-anatomical grafts (P1) and prosthetic patch angioplasties (P3). In modified version these have been excluded to concentrate on AGIs only (Tebeeken *et al* 2012).

- Graft infection
 - P0 graft infection – infection of a totally intracavitary graft (e.g. aorto-bi-iliac graft, aortic stent graft)
 - P2 graft infection – infection of extra-cavitary portion of a graft, whose origin is cavitory (e.g. groin and graft limb infection of an aorto-bi-femoral graft)
- Graft-enteric erosion
- Graft-enteric fistula
- Aortic stump sepsis after excision of an infected aortic graft

Since diagnosis, management and prognosis are somewhat different in case of a graft infection compared to a graft-organ erosion or a fistula and aortic stump sepsis; they are being considered rather as different entities and not as secondary graft infections (Bunt 1983). Szilagy's classification was commonly used during earlier years, while latest recommendations regarding AGIs favour classifying infections as early or late, based on time gap from index operation. Modified Bunt's classification is used to report the extent of AGI and presence of complications (Tebeeken *et al* 2012).

1.3 PATHOGENESIS

1.3.1 ETIOLOGY

1.3.1.1 *Biomolecular level*

As a foreign body, an aortic prosthetic graft is more susceptible to infection than autologous tissue. Alloplastic implant is a suitable microenvironment for bacterial adhesion and small inoculum is enough to seed the implant (Elek and Conen 1957). Blood and tissue fluid proteins facilitate the subsequent adhesion by providing adhesion matrix molecules on the surface of the vascular graft (Frei *et al* 2011). When microorganisms convert from free-floating to adherent form and start multiplying, the attachment to

prosthesis becomes stronger. Firmly anchored bacteria change genetic transcription to up-regulate virulence markers, start secreting extracellular polymers and recruit other pathogens. Biofilm forms via cell division and recruitment offering protection to viable microorganisms against the host defence system and antibacterial agents. (Hall *et al* 2014.) Biofilm may develop in a fast or slow flow environment and is dependent of the porosity of the graft. Knitted and woven Dacron grafts have higher porosity and are therefore more susceptible to bacterial adhesion and protein deposition than expanded polytetrafluoroethylene (PTFE) grafts. Mature biofilm includes dormant bacteria and dispatchable mobile cells in a planktonic condition to be spread through the vascular tree, create new microcolonies and thereby spread the infection. (Schmitt *et al* 1986, Woźniak *et al* 2017.) On the graft surface spreading of biofilm is slow and damage to graft material minimal but close to the area of graft-to-artery anastomosis, the tensile strength of artery can be reduced and a pseudoaneurysm may form. Invasion from graft surface to perigraft tissue to develop a fulminant sepsis is uncommon in case of low-virulent bacteria due to slow growth and sparse planktonic release and bacterial samples from perigraft liquid may therefore yield negative results (Frei *et al* 2011).

Bacterial invasion, biofilm formation and planktonic release are irritating to the host, causing an immune response. First reaction to bacterial invasion comes from neutrophils and is followed by reaction from macrophages. They circulate in blood and are attracted to the infection site by chemotactics to eliminate bacteria by phagocytosis and intracellular killing. Introduction of a foreign body attracts polymorfonuclear cells (PMN) and may activate phagocytosis. As has been shown with PTFE material, frustrating phagocytosis of nonphagocytosable material leads to partial exhaustion of PMN function, and loss of bactericidal activity already in an hour. Therefore, this locally acquired phagocytic defect has been shown to diminish PMN-mediated protection against staphylococcal strains and may be one factor contributing to biofilm generation and graft infection. (Zimmerli *et al* 1984.) Biofilm bacteria attach to graft material with minutes, connection becomes firm within 2-4 hours and secretion of protective matrix starts. This microenvironment makes biofilm bacteria recalcitrant to antibody reaction and phagocytosis considerably fast. However, albeit immune system cannot eliminate the invader, it remains stimulated. This chronic immune response attenuates incorporation of vascular prosthesis to surrounding tissue and causes autolysis of perigraft tissue. (Frei *et al* 2011, Hall *et al* 2014, White and Hollier 2008.)

Chronic inflammatory response is also induced by implanted vascular graft to isolate the foreign body from adjacent tissue by encapsulating it with fibrous collagen tissue.

Mononuclear cell infiltration, angiogenesis, capillary ingrowth, fibroblast proliferation and collagen deposition will incorporate vascular graft into surrounding tissue. Any factor undermining this process (seroma, haematoma, etc.) will attenuate graft incorporation as well as luminal endothelialisation. Platelets, fibrin and a thin thrombus will be first to line the luminal surface of implanted vascular graft. Near anastomosis, endothelial cells, smooth muscle cells (SMC) and fibroblasts will migrate from the adjacent artery to create endothelial surface – however, luminal migration can only cover limited distance. It is postulated that stable endothelialisation of the full length of the prosthesis requires capillary ingrowth of porous material, since endothelium has been found absent in areas with no tissue incorporation. The lack of luminal endothelia makes graft more thrombogenic and serves attachment sites for bacteria spreading haematogenous ways. (Moore *et al* 1980, Berger *et al* 1972, Zdanovski *et al* 1994, Lejay *et al* 2017^{*}.)

Insertion of vascular graft causes local tissue damage with ischaemic and acidic conditions around the perigraft area. Neutrophils continue to phagocytise in acidic environment, but local tissue hypoxia can hinder their function. Foreign body diminishes PMN activity and bactericidal function. With the addition of local autolysis due to immune response, the perigraft area becomes an excellent breeding ground for bacteria making it easy for infection to spread along graft surface. (Bergamini *et al* 1994.)

According to United States National Institute of Health's public announcement, biofilms account for over 80% of human microbial infections. In case of vascular prosthetic infection, presence of biofilm challenges the conservative treatment of AGI and, therefore, graft explantation is required for eradication (Frei *et al* 2011).

1.3.1.2 Evolution of infection and associated risk factors

Bacteria or fungi can seed vascular graft in four different ways: perioperative contamination, haematogenous seeding by bacteraemia, mechanical erosion of the skin, genitourinary or gastrointestinal tract, or involvement in adjacent infectious process.

It is generally accepted that usual time of graft contamination is during the operation. It can be caused by direct contact with bacteria through skin incision, since skin and lymph nodes are a reservoir of bacteria, or there may be a breakdown in aseptic. Bacterial spread can be haematogenous or lymphatic from remote sites of infection, or micro-organisms located in arterial wall or intramural thrombus can be a potential cause for AGI. (Cornenwett and Johnston 2010.)

Contamination

Most frequent sources of infection are endogenous pathogens from patients' skin. Staphylococci can contaminate the graft through the direct contact between graft and the skin or after excessive and reckless graft handling. Bacteria can also harbour in deeper dermal layers, scar tissue and sweat glands, where they remain relatively unaffected by topical bactericidal agents (Hicks and Greenhalgh 1997). Recent previous percutaneous arterial access or surgery may elevate the risk of graft contamination probably due to introduction of skin flora into subcutaneous tissue and local haematoma.

Positive bacterial samples from arterial wall have been considered to be a risk factor for graft infection. Routine samples from arterial reconstructions may yield positive results in up to 43% of the cases with Coagulase-negative staphylococci (CNS) as most prevalent culprit, but direct correlation with AGI is lacking (Durham *et al* 1987). However, in case of redo surgery, correlation between positive samples and subsequent graft infection has been suggested (Durham *et al* 1987, White and Hollier 2008). Any reoperation carries a risk of bacterial contamination, including secondary procedures for treating the endoleaks following EVAR (Hobbs *et al* 2010). In case of mycotic aneurysms, the association with wall bacteria and graft infection is clear (Sörelus *et al* 2014).

Laminar ventilation has reduced the problems with airborne bacteria in operating rooms, but the risk for infection is higher with endografts implanted in interventional radiology suites (Ducasse *et al* 2004). Accidental opening of genitourinary or gastrointestinal tract can predispose the graft to contamination with endogenous bacteria (Cornenwett and Johnston 2010, Capoggia *et al* 2016). Furthermore, aseptic breakdown in surgical technique can be an infection source, particularly in case of emergency, in addition to extended operation time (Cheng *et al* 2017).

Bacteraemia

Haematogenous seeding is a rare but important mechanism. Concomitant infection is a risk factor for AGI. Bacteria can be transmitted from vascular catheters or during bacteraemia from remote infection sites such as urinary tract infections, pneumonia or cellulitis. (Cornenwett and Johnston 2010.) Perioperative graft colonisation has decreased after introduction of parenteral antibiotic prophylaxis, but exposed surface of foreign material remains attractive attachment site to haematogenous bacteria in early postoperative period. Graft incorporation and growth of endothelial layer during the later period will diminish susceptibility to infection, although complete endothelialisation may

never happen resulting in graft's vulnerability. (Moore *et al* 1980.) An occult low-grade infection may deny graft incorporation and endothelialisation, allowing virulent bacteria during future episodes of bacteraemia to inoculate prosthetic graft surface and convert the low-grade infection to a symptomatic AGI. Therefore life-long antimicrobial prophylaxis should be considered to patients with aortic prosthetic reconstructions in case of invasive procedures with transient bacteraemia. (Cornenwett and Johnston 2010.)

Mechanical erosion

Erosion of aortic graft through the skin or to gastrointestinal tract often occurs due to a low-virulent infection. However, as a result of the fistulation, superinfection with more virulent bacteria may develop systemic infection.

An aorto-enteric fistula and erosion are a communication between aortic prosthetic graft and adjacent intestine. Most commonly third part of duodenum becomes involved due to its relatively fixed position and proximity to aortic graft body. Constant pulsatile movements of noncompliant graft can cause mechanical microtrauma and secondary ischaemia to duodenum when intervening soft tissue in retroperitoneal area is missing. A fistula usually develops after anastomotic pseudoaneurysm formation due to a low-grade infection or fatigue. Pseudoaneurysm can erode into the intestine and create a communication between aorta and intestine. In case of erosion, mechanical trauma to duodenum is the cause and graft contamination with enteric bacteria the result. However, the infection can spread in paraprosthetic tissue, involve anastomotic areas and result in pseudoaneurysm formation or rupture as well. (Omara *et al* 1981, Bunt 1983, Cornenwett and Johnston 2010.)

AEF development after EVAR is rare and often associated with a persistent endoleak and aneurysm growth or endotension (Spanos *et al* 2017).

A non-septic graft-cutaneous fistula is usually associated to low-grade streptococcal infection, causing chronic inflammation and tissue autolysis (Bergamini *et al* 1994).

Extension of contiguous infection focus

Wound healing complications are a risk factor for an AGI. Meticulous surgical technique with skin apposition and proper haemostasis will promote prompt fibrin seal, but excessive use of electrocautery and extended application of wound retractors can cause extensive skin and soft tissue trauma, resulting in large tissue necrosis. Presence of

wound haematoma or fatty necrosis diminishes the inoculum required for developing a wound infection and facilitates the extension of superficial infection to subcutaneous tissue and graft. Operating in scar tissue and obesity raise the risk of wound complications. (Inui and Bandyk 2015.) Colonisation in retroperitoneal space due to diverticulitis, periappendicular abscess, discitis or lumbar osteomyelitis has been described (Perera *et al* 2014, Laser *et al* 2011).

Patient-related risk factors

Any condition impairing host defences makes patient more susceptible to AGI. Deprivation of host immune reaction due to malnutrition, malignancy, chronic end-stage renal disease, long-term corticosteroid treatment, antirejection on cytostatic medicaments, lymphoproliferative disease or autoimmune disorders will diminish the amount of inoculation necessary to develop an AGI (Cornenwett and Johnston 2010).

Obesity is a risk factor for wound infection and subsequently possibly to graft contamination. Surgical intervention disturbs the fine balance between fat lobules and capillary system, leading to relative vascular insufficiency and diminished oxygen supply. This results in decreased collagen synthesis, decreased oxygen-dependent capacity to eliminate bacteria, and decreased ability to support the mechanisms of healing process. (Anderson and Hamm 2012.) Wound care proposes challenges in humid skin creases and diminishes the local oxygen supply even further.

Diabetes has been considered to be a risk factor for infections by attenuating host immune defence. The presence of hyperglycaemia constantly activates PMNs, making them less responsive to infectious stimuli. Diabetics as well patients with end-stage renal disease are more likely to be hospitalised and colonised with more virulent hospital-acquired bacteria, such as methicillin-resistant *Staphylococcus aureus* (MRSA). (Dryden *et al* 2015) Prolonged preoperative hospital stay is yet another risk factor for AGI.

1.3.2 BACTERIOLOGY

The most common isolated bacteria in AGI are Staphylococcal strains. *Staphylococcus aureus* is the most prevalent isolated microorganism accounting for more than quarter of all infections, but the proportions of *Staphylococcus epidermidis* and gram-negative bacteria are on the rise (Chambers 2005). The spectrum of bacteria varies depending on the time of infection onset after index operation and clinical presentation, but the

proportions follow along the lines of the reported microbial epidemiology of vascular prosthetic graft infections: *Staphylococcus aureus*, 20 %–53%; *Enterobacteriaceae*, 14%–41%; *Coagulase-negative staphylococcus*, 15%; *Pseudomonas aeruginosa*, *Streptococcus spp* and *Enterococcus spp*, 10%–15%; polymicrobial infections, 20%; obligatory anaerobes, 5% and *Candida spp*, 1%–2% (Revest *et al* 2015). However, prevalence of polymicrobial and candida infections is probably higher in case of AGI due to an AEF.

Early perigraft infections are commonly caused by more virulent bacteria acquired via perioperative contamination or haematologically during the postoperative period: *S. aureus*, MRSA, *Escherichia coli*, *Pseudomonas*, *Proteus* and *Kleibsiella*. Coagulase-negative staphylococci are common in late perigraft infections; however, they can play a part in the polymicrobial growth when indolent *Staphylococcus epidermidis* persistence becomes complicated by virulent superinfection. AEE and AEF present rather as late infections and commonly have polymicrobial etiology. (Cornenwett and Johnston 2010.) Staphylococci infections are typically result of perioperative contamination. *S. epidermidis* is a coagulase-negative skin commensal, which is strongly adherent to foreign bodies. Perioperative graft colonisation leads to biofilm formation where *S. epidermidis* can remain indolent for years. Due to low virulence, it is not capable of tissue invasion, but chronic host immune system stimulation can lead to tissue autolysis with perigraft fluid collection, graft-cutaneous fistula, anastomotic pseudoaneurysm or graft limb thrombosis. (Bandyk *et al* 1991, Hicks and Greenhalgh 1997.) Determining a *S. epidermidis* infection is challenging, as perigraft fluid and tissue commonly yield negative results. Sonication of prosthetic material is the most sensitive method to reveal bacterial growth, but it is unfortunately strongly underused in clinical practice (Chambers 2005). Another member of normal skin flora, *Staphylococcus aureus*, is a virulent bacterium often accountable for wound infections and early AGI. *S. aureus* produces mucinous biofilm to promote its adhesion to the prosthetic material and to protect itself against host defensive mechanisms and antibiotics. It is aggressively invasive pathogen, producing variety of toxic proteolytic enzymes and coagulase, which cause haemolysis, cell necrosis, autolysis and widespread inflammatory process. (Hicks and Greenhalgh 1997, Chiesa *et al* 2002.)

Among gram-negative rods, which are generally more virulent than gram-positive rods, *Pseudomonas aeruginosa* is a microorganism that causes complicated nosocomial infections. Taking advantage of immunocompromised situation, it spreads rapidly causing tissue invasion and sepsis. *Pseudomonas* produces elastase, alkaline protease

and endotoxins, which can break down elastin, collagen and fibrin, leading to tissue necrosis. Both, *Pseudomonas* and *Staph. aureus* typically cause acute systemic infection with rupture of anastomosis and haemorrhage. (Hicks and Greenhalgh 1994, Chiesa *et al* 2002, Perera *et al* 2006.) In addition to disseminative infection, *Pseudomonas* can create a protective biofilm keeping host immune response alert. As the immune system is unable to eliminate biofilm bacteria, the host tissues are damaged. Surrounding tissue becomes exposed to oxidative radicals and lytic enzymes released from inflammatory cells. Host cell release of proteases and elastases also degrades the immune cells and diminishes the anti-biofilm reaction even further. Therefore, pseudomonas infection remains highly resistant to conservative treatment and favours aggressive surgical interventions. (Moser *et al* 2017.)

At the beginning of the 21st century, the prevalence of vascular graft infections caused by methicillin-resistant *Staphylococcus aureus* (MRSA) was approximately 30%–40% (Hodgkiss-Harlow *et al* 2011). Since then, the prevalence has steadily declined in Europe but remains at >20%. Albeit skin colonisation among general population is 2%, it is significantly higher among people in long-term care facilities and with chronic ischaemic wounds (9%–22%) (Manzur and Gudiol 2009). There is an increased risk of amputation and prolonged length of hospital stay among patients with MRSA, and morbidity and early mortality are also higher with MRSA infection (Hodgkiss-Harlow *et al* 2011, Inui and Bandyk 2015, Revert *et al* 2015).

Candida spp, *Mycoplasma* and *Mycobacterium* as monoinfections are more prevalent among patients with immunocompromised condition. However, long-lasting antimicrobial treatment can provoke yeast overgrowth and graft superinfection. Furthermore, patients presenting with AEE/AEF may have *Candida* as a co-infection. (Cornenwett and Johnston 2010.)

In one third of the cases bacterial growth from an explanted graft or perigraft tissue remains negative, although there is a clinically and radiologically confirmed AGI. *S. epidermidis* and fungal infections are challenging to isolate, but antimicrobial treatment has often been administered prior to sample acquisition and, therefore, bacterial cultivation may no longer be successful (Kieffer *et al* 2004, Chambers 2005).

1.4 PREVENTION

Since surgical site infection (SSI) is a major risk factor for subsequent graft infection, measures to prevent SSI should be taken: bathing on the evening before operation, hair

clipping only immediately before the operation if necessary, skin preparation with alcohol-based antiseptics, prophylactic antibiotics, meticulous surgical technique, perioperative blood glucose control, tissue oxygenation and normothermic body temperature, as well as triclosan-coated sutures (Edmiston *et al* 2014, Inui and Bandyk 2015, Global Guidelines for SSI 2016).

Meticulous postoperative wound care and leaving sterile wounds undisturbed for 24–48 hours, as well as aggressive local, antibacterial or even surgical treatment when signs of skin edge necrosis, infection or excessive lymphatic drainage appear, are common preventive methods of SSI (Inui and Bandyk 2015, Hodgkiss-Harlow *et al* 2011). Prophylactic negative-pressure wound treatment (NPWT) has emerged as a wound dressing that decreases SSIs and subsequent AGIs. Tightly sealed and uninterrupted for several days, the dressing prevents local contamination. The negative pressure applied keeps wound dry and diminishes dead space possibly leading to a faster wound healing. In a retrospective study including 115 patients, prophylactic NPWT diminished SSI-rate in groin area to 3% compared to 30% in non-NPWT group (Matatov *et al* 2013). Retrospective data seems to favour routine use of NPWT but results from randomised controlled trials (RCT) are still missing.

Remote infection focuses should be treated prior to the operation and sufficient healing time provided. However, if aortic prosthetic grafting is urgent, pre- and postoperative parenteral antimicrobial treatment based on susceptibility should be administered. (Cornenwett and Johnston 2010.)

Antibiotic prophylaxis must be administered prior surgery. In vascular prosthetic surgery dual therapy with first- or second-generation cephalosporine in combination with a glycopeptide (*eg* vancomycin) is used. Glycopeptide should be administered 60–120 minutes before the incision, since drug distribution in tissue and appearance of bactericidal activity is slow. Cephalosporines should be administered 30 minutes before operation and redosed if procedure lasts over three hours or blood loss exceeds 1.5 litres. There are no recommendations about postoperative prolongation of antibiotic prophylaxis, but some prefer prolonged antimicrobial parenteral medication until intra-vascular catheters and tubes are removed or when two or more patient-dependent risk factors are present. (Cornenwett and Johnston 2010, Hodgkiss-Harlow *et al* 2011, Inui and Bandyk 2015, Global Guidelines for SSI 2016.)

The application of silver-impregnated or rifampicin-soaked grafts prophylactically has been studied widely. Silver ions bound to vascular grafts may affect Staphylococcal strains, *E. coli* and *Pseudomonas aeruginosa* by deactivating their enzymes, damaging

their cytoplasmic membrane, causing oxidative stress, and reducing their growth and division. Antibacterial effect is stronger against Gram-negative strains, possibly due to the thicker cell wall of gram-positive strains. (Quing *et al* 2018) Silver-acetate also promotes graft ingrowth to surrounding tissue, diminishing the possibility of perigraft seroma and subsequent bacterial contamination. In vivo testing on animals has shown the benefit of silver-acetate in tissue-incorporation over vaporized silver application to the Dacron grafts. The release of vaporized silver can last up to 12 months and eventually slow down the incorporation, as opposed to the quick release of silver-acetate that only lasts for 2–3 weeks. (Jeanmond *et al* 2013 and 2014) Nevertheless, in retrospective study with 913 patients, the prophylactic use of silver-acetate grafts has not shown significant benefit over common Dacron graft to justify routine use in infection prevention (Larena-Avellaneda *et al* 2009).

Rifampicin-bonded grafts have been used prophylactically and in case of infectious conditions. Two randomised controlled trials have been published with 600 patients from Italy and 2610 patients from a European multicentre study. All of the procedures included in the Italian study were aorto-femoral or iliac-femoral reconstructions with an inguinal incision, while the European study also included aorto-iliac reconstructions. Both found no significant differences between the two study groups in case of AGI, however, European study found significantly fewer wound infections (Szilagy I–II) in rifampicin-group compared to bare prosthesis. (D'Addato *et al* 1997, Goëau-Brissonnière *et al* 2011.) A late *in vitro* study by Berard showed that impregnated rifampicin loses its anti-staphylococcal efficacy relatively fast and bonded grafts may lead to emergence of rifampicin-resistant staphylococcal strains compromising the future efficacy of this antibiotic (Berard *et al* 2018). The high-concentrations used for soaking Dacron grafts to bond an effective amount of rifampicin have revealed to be toxic to endothelial and other vascular cells (Herten *et al* 2017). Therefore, prophylactic use of rifampicin-bonded grafts cannot currently be recommended either.

1.5 DIAGNOSIS

Until recently, AGI diagnosis was based on various combinations of patient symptoms, biochemical markers and radiological studies, making it impossible to distinguish between suspected and confirmed cases in the literature. To homogenize the AGI population and to make the data more comparable between different institutions, the

Management of Aortic Graft Collaboration suggested combination of diagnostic criteria to define the suspicion and confirm the diagnose of AGI (Lyons *et al* 2016).

After a systematic review of literature, the collaboration reached a consensus to define an AGI based on diagnostic criteria grouped as clinical, radiological or laboratory criteria (Figure 1). One major criterion or two minor criteria from different is regarded as a suspicion of AGI. An aortic graft infection can be diagnosed when, in addition to one major criterion, any other criterion from another category is present. If low-virulent skin commensals (eg coagulase-negative staphylococci, propionbacterium etc.) are cultured, the same bacteria must be confirmed in another intraoperative specimen and/or blood cultures to exclude contamination. (Lyons *et al* 2016.)

| | CLINICAL / SURGICAL | RADIOLOGY | LABORATORY |
|----------------|--|---|--|
| MAJOR CRITERIA | <ul style="list-style-type: none"> • Pus (confirmed by microscopy) around graft or in aneurysm sac at surgery • Open wound with exposed graft or communicating sinus • Fistula development e.g. aorto-enteric or aorto-bronchial • Graft insertion in an infected site e.g. fistula, mycotic aneurysm or infected pseudoaneurysm | <ul style="list-style-type: none"> • Peri-graft fluid on CT scan \geq 3 months after insertion • Peri-graft gas on CT scan \geq 7 weeks after insertion • Increase in peri-graft gas volume demonstrated on serial imaging | <ul style="list-style-type: none"> • Organisms recovered from an explanted graft • Organisms recovered from an intra-operative specimen • Organisms recovered from a percutaneous, radiologically-guided aspirate of peri-graft fluid |
| MINOR CRITERIA | <ul style="list-style-type: none"> • Localized clinical features of AGI e.g. erythema, warmth, swelling, purulent discharge, pain • Fever \geq38°C with AGI as most likely cause | <ul style="list-style-type: none"> • Other e.g. suspicious peri-graft gas/fluid/soft tissue inflammation; aneurysm expansion; pseudoaneurysm formation; focal bowel wall thickening; discitis/osteomyelitis; suspicious metabolic activity on FDG PET/CT; radiolabelled leukocyte uptake | <ul style="list-style-type: none"> • Blood culture(s) positive and no apparent source except AGI • Abnormally elevated inflammatory markers with AGI as most likely cause e.g. ESR, CRP, white cell count |

Figure 1 Major and minor criteria for suspecting and diagnosing an aortic graft infection. CT, computed tomography; FDG PET, fluorodeoxyglucose positron emission tomography; ESR, erythrocyte sedimentation rate; CRP, C-reactive protein. ¹

¹ Lyons OT et al. Diagnosis of Aortic Graft Infection: A Case Definition by the Management of Aortic Graft Infection Collaboration (MAGIC). Eur J Vasc Endovasc Surg. 2016 Dec; 52:758-763. DOI: 10.1016/j.ejvs.2016.09.007. Published by ELSEVIER Inc. Creative Commons Attribution-NonCommercial-NoDerivatives 4.0 International Public License (<https://creativecommons.org/licenses/by-nc-nd/4.0/>)

1.5.1 CLINICAL PRESENTATION

The non-specific nature of the AGI symptoms often delays the diagnosis and postpones adequate treatment. High index of suspicion is required to commence radiological studies and distinguish an AGI from other medical conditions. Berger conducted a questionnaire study among members of the Dutch Society of Vascular Surgery about diagnostics and treatment of AGI. The results showed that despite a highly variable clinical picture, 40% of surgeons consider fever early after graft implant to be an integral part of AGI as well as groin infection, while 95% rely on the results of radiological studies. (Berger *et al* 2015.) EVAR infections are predominantly highly symptomatic, however 10% of low-grade infections are detected during routine follow-up imaging. High suspicion is necessary for early detection due to completely intracavitary location. (Argyriou *et al* 2017.)

High-virulent bacteria are more common in early infections, presenting with aggressive symptoms such as high fever, sepsis and abdominal or back pain. Sepsis and fever are the most common symptoms (43%–70%) referring to an abscess in the groin or intracavitarily in 24%–37% of cases (Keiffer *et al* 2004, Daenans *et al* 2003, Davila *et al* 2015). Frequently present groin sinuses (26%–43%) or femoral pseudoaneurysms (18%–36%) are more typical for low-grade infections or aorto-enteric erosions (Kieffer *et al* 2004, Daenans *et al* 2003, Ali *et al* 2009).

Low-grade infections are typically caused by low-virulent bacteria, appear later and present with vague symptoms – general malaise, weakness, weight loss or anorexia. Graft thrombosis, gastro-intestinal bleeding, erythema over the graft, and cellulitis are symptoms associated with AGI and possible AEF or AEE.

AEF and AEE, as the most challenging clinical situations, represent roughly one third of AGI cases and often appear as haematemesis, melaena or anaemia. More than half of these patients experience herald bleeding characterised by intermittent haemorrhage and clot formation to the fistula. Gastrointestinal (GI) bleeding with a history of aortic reconstruction should urgently lead to further investigations; nevertheless, 21%–31% of then patients arrive in hospital in haemorrhagic shock. In case of erosion, sepsis is more common, frequently in combination with a groin abscess. Proximal anastomotic pseudoaneurysm as a contributing factor for fistulation is found in up to 46% of the cases. Abdominal and back pain are typical accompanying symptoms due to inflammation, while graft thrombosis and septic embolisation are rather infrequent. (Bergqvist and Björck 2008, Batt *et al* 2011, Oderich *et al* 2011)

Completely intracavitary aortic endograft infections present as sepsis or an AEF. Despite total intraluminal location, AEF is still common representing 31%–48% of cases. In contrast to the sequelae of open surgery, the fistula in cases of an endograft almost invariably forms between the fourth part of duodenum and the aneurysm sac (Hobbs *et al* 2010). Two thirds of all septic infections are high-grade, with a fever of > 38 degrees centigrade and abdominal pain, and the remaining third constitute low-grade infections with non-specific chronic symptoms. (Ducasse *et al* 2004, Hobbs *et al* 2010, Chaufour *et al* 2017.)

1.5.2 LABORATORY FINDINGS

Elevated leukocyte count, erythrocyte sedimentation rate (ESR) and C-reactive protein (CRP) as inflammatory markers are common, but not pathognomonic of AGI. Abnormal CRP values among patients with confirmed AGI have been reported, with a mean value of 96 ± 79 mg/L in all patients and leucocytosis of $>11 \times 10^9/L$ in 63% of patients (Lyons *et al* 2014, Garot *et al* 2014, Davila *et al* 2015). CRP is elevated during the postoperative period and therefore not indicative of an early AGI. In case of normal inflammatory biomarkers and peripheral leukocyte count, however, AGI is unlikely. Inflammatory markers may indicate the severity of infection and are useful tools in evaluation of treatment effectiveness and in follow-up (Wilson *et al* 2016).

Positive blood cultures can be obtained from 52%–53% of the patients, and overall positive bacterial cultures from 55%–83% of patients, 23%–43% of which are typically polymicrobial (See section 1.3.2 Bacteriology for details) (Ali *et al* 2009, Hobbs *et al* 2010, Bisdas *et al* 2010, Batt *et al* 2011, Kahlberg *et al* 2016, Garot *et al* 2014). Bacterial swabs from draining sinuses may reveal true pathogens, but in case of low-grade infection, cultured skin commensals may indicate contamination. Perigraft fluid aspirates, organisms recovered from an explanted graft, or perigraft tissue have strong diagnostic value when true pathogens are isolated. When aspirate shows leukocytes only and tissue samples remain negative, results could be improved with sonication, in addition to broad range polymerase chain reaction (PCR) and bacterial DNA sequencing. (Perera *et al* 2006, Lyons *et al* 2016.)

1.5.3 RADIOLOGICAL FINDINGS

Due to the nonspecific clinical symptoms, diagnosis of AGI relies on radiological studies, providing information on the extent and specifics of infection and enabling the planning of the possible surgical reconstruction.

1.5.3.1 *Computed tomography angiography*

CT is the gold standard in diagnosis of AGI. It is fast, easy to perform, easily accessible, and it provides sufficient data on vascular tree and adjacent structures when intravenous contrast media is used. Perigraft fluid, gas, soft-tissue oedema, pseudoaneurysms and focal bowel wall thickening can be distinguished with computed tomography angiography (CTA) with specificity of 85%–100%; however, the sensitivity varies between 78% and 94% and is lower in early infections. (Fiorani *et al* 1993, Orton *et al* 2000) Early postoperative period is a challenge to every radiologic study as regards distinguishing between a normal postoperative environment and an infection. However, perigraft fluid persisting over 3 months and perigraft air persisting over 7 weeks are suspicious to an infection (Qvarfordt *et al* 1985, Lyons *et al* 2016). Scintigraphy studies and MRI may offer more information, but correlation with clinical and laboratory signs define the course of action. CT-guided aspirations can be performed in diagnostics, but if they are revealed to be negative, a series of CT scans over few years are recommended. In rare cases, perigraft fluid has been observed for up to one year without graft infection. (Orton *et al* 2000.) AEF can often be diagnosed from CTA scans during the later postoperative period; the sensitivity is very high, but not the specificity. Patients with AEF frequently present with disappearance of periaortic fatplane and fatplane between aorta and bowel, as well as excessive perigraft soft tissue, focal bowel wall thickening adjacent to the graft, perigraft fluid and ectopic gas, pseudoaneurysms and dystrophic vascular graft calcifications (Figure 2). Active extravasation into the bowel and graft location inside the bowel lumen are pathognomonic signs of AEF. (Hagspiel *et al* 2007.) Endoscopic studies can be performed in case of uncertainty to identify graft material in the bowel, mucosal erosions or intruding pulsatile mass. However, the specificity of gastroduodenoscopy is lower compared to CTA – 57% vs 79%, respectively (Deijen *et al* 2016). An additional benefit of CT is the detection of other conditions occasionally present with AGI, such as more remote abscesses, discitis and osteomyelitis or hydronephrosis (Orton 2000).

1.5.3.2 Magnetic resonance imaging

MRI has not been used as widely as CT in the diagnosis of AGI. MRI is more sensitive to smaller amounts of liquid and allows differentiation between perigraft fluid with inflammatory changes in surrounding tissue eg psoas muscle and chronic haematoma. However, it cannot differentiate between infected and sterile liquid in early postoperative phase, nor identify AEF, unless surrounding inflammation is present. (Olofsson *et al* 1988.) The specificity and sensitivity of MRI in diagnosis of an AGI have been reported to be 97% and 68%, respectively. Compared to Indium-111-labelled white blood cell scans, the diagnostic value is similar (87% and 73%, respectively) and in case of incomplete CT results, MRI therefore could be preferred, as it is less invasive and does not cause radiation exposure. (Shahidi *et al* 2007, Bryggink *et al* 2011.)

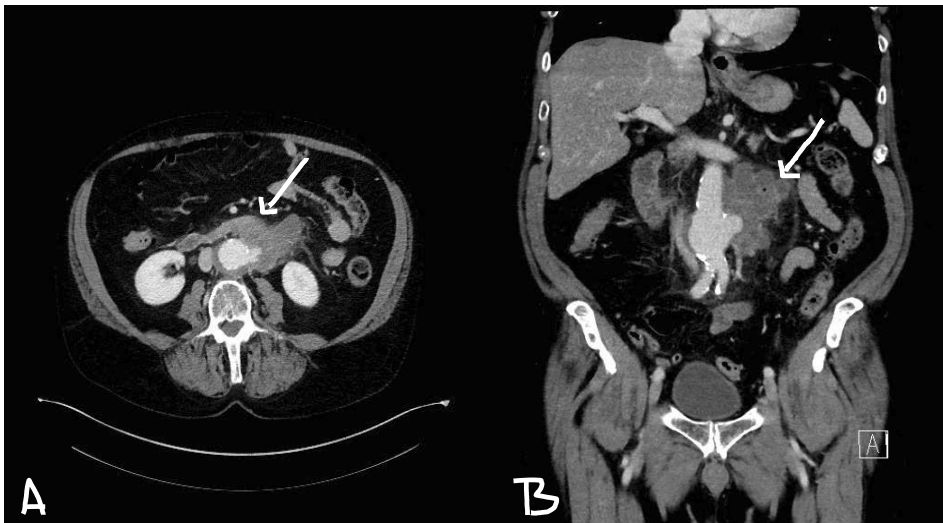


Figure 2 *Aorto-enteric fistula. A) Pseudoaneurysm and disappeared fatplane between the intestine and an infectious aneurysm sac. B) Gas inside the abscess around a pseudoaneurysm.*

1.5.3.3 Nuclear medicine techniques

¹⁸F – FDG-PET/CT

Fluorodeoxyglucose (FDG) is a radioactively labelled glucose uptaken by metabolically active leukocytes aggregating to the graft surface in case of an AGI. Metabolic activation is detected by positron emission tomography (PET) and anatomic lesions located with

CT. The integration of anatomic and metabolic locations improves the interpretation of results and helps to differentiate AGI from other infections and physiologically abnormal uptakes. Diffuse or linear FDG uptake on a PET scan is characteristic of inflammation, and focal uptake is rather suggestive of infection, but diagnostic problems are caused by false-positive results. (Saleem *et al* 2015) Fusion scans have improved results, and Spacek reported positive predictive value of 97% and negative predictive value of 95% with focal uptake; however, with diffuse uptake, positive predictive values dropped to 77% (Spacek *et al* 2009). Chang hypothesised that metabolic cells in inflammation might have different tracer release pattern to those in an infectious environment and performed a second scan 45 minutes later. Positive predictive value among 29 patients was 100%, but negative predictive value remained at 72% with the second scan added. (Chang *et al* 2015.)

Leukocyte scintigraphy

Radiolabelled leukocytes with Indium-111 or Technetium-99m can be used to identify infection focus, since radioactive label is tagged to neutrophils. In-111-scans have been reported to have sensitivity of 73% and specificity of 87%; Tc-99m-scans a sensitivity of 79%–100%, and specificity of 83%–100% (Keavey *et al* 1991, Prats *et al* 1993, Fiorani *et al* 1993, Shaidi *et al* 2007). In-111-scans take over 24 hours to yield results, their accuracy is low in low-grade infections and during the early postoperative period. Tc-99m-scans can be read in 4 hours after leukocyte reinfusion and seem to be more accurate in early and low-grade infections. Tc-99m-scans were performed on 20 patients during the first and second postoperative week after aortic reconstructions in a study by Keavey. During the first week, there were 14 negative, 2 positive and 4 ambiguous results, during the second week 18 negative and 2 ambiguous results. One unclear result turned negative during the third week. Overall specificity was 83%, but for the studies taken after the first week, it was 95%. (Keavey *et al* 1991.) In case of low-grade infection and negative CT scan, a tc-99m scan performed better with sensitivity of 100% and specificity of 94%, as well as positive and negative predictive value of 95% and 100%, respectively (Fiorani *et al* 1993).

Single-photon emission CT (SPECT/CT) is a more advanced, three-dimensional information-producing tagged leukocyte scan that seems to produce the highest accuracy in case of vascular graft infection (Reindels Formel *et al* 2018).

However, due to poor access, high dose of radiation, time consuming imaging, lack of extensive experience and conclusive data, as well as high cost, nuclear medicine techniques remain complementary studies when results of standard CT are inconclusive.

2 MYCOTIC ABDOMINAL AORTIC ANEURYSM

2.1 DEFINITION

Mycotic aortic aneurysm is a misleading term, but currently used for all aortic aneurysms with infectious origin. Sir William Osler was the first to describe a *mycotic* aortic aneurysm in Gulstorian lectures as septic embolic complication of endocarditis. Osler described a man diagnosed with syphilis who died after suffering diarrhoea, headaches, chills and fever. Autopsy revealed 4 irregular thoracic aortic aneurysms, one of which had “fresh fungous vegetations” and was ruptured to the pericardial sac (Osler 1885). In 1923 Stengel showed that an infected aneurysm may develop as a result of other septic conditions without valvular vegetations, and Sommerville described 6 cases of ruptured infected aneurysms with previous atherosclerotic changes, linking atherosclerotic arterial wall damage to a susceptibility to bacterial attachment (Stengel and Wolferth 1923, Sommerville *et al* 1959). After introduction of antibiotics and recognition of the use of aggressive surgical interventions on such aneurysms, the incidence of mycotic aneurysms declined (Barker 1953, Brown *et al* 1984, Trairatvorakul *et al* 1990, Cornenwett and Johnston 2010).

In current literature, mycotic arterial aneurysm and arterial infection are used synonymously, and both are therefore also used in the present thesis. Despite being a misnomer, mycotic arterial aneurysm is a comprehensive term encompassing aneurysms that emerge after bacterial seeding an arterial wall, as well as previously existing atherosclerotic aneurysms with secondary infection. Clinical course of such aneurysms is considerably fast, and patients typically present with abdominal pain, fever, elevated infection markers and an eccentric or saccular aneurysm in CT scan.

2.2 CLASSIFICATION

The classification of a mycotic arterial aneurysm is based on etiology and was reported by Wilson in 1978 after several definitions had emerged in the literature. He divided

arterial infections into four subgroups based on their clinical features: mycotic aneurysms caused by cardiac emboli; infected aneurysms and secondary infections of pre-existing aneurysms; microbial arteritis as haematogenous infection of non-aneurysmatic arteries and infected pseudoaneurysms caused by trauma, such as puncture (Wilson *et al* 1987). In addition, an infected aneurysm can develop secondarily to contiguous spreading of adjacent infection such as pancreatitis – however, due to the local spreading, the pathophysiology of wall damage is not bloodborne nor intima-mediated.

Primary aorto-enteric fistulas remain beyond the scope of current thesis and are therefore not discussed further herein.

Table 1. Classification based on the clinical features of infected aneurysms according to Wilson *et al* 1987.²

| | Mycotic Aneurysm | Infected Aneurysm | Microbial Arteritis | Post-traumatic Infected False Aneurysm |
|---------------------|-------------------------|--|-----------------------------|---|
| Etiology | Endocarditis | Bacteraemia | Bacteraemia | Trauma, drug addiction |
| Age | 30–50 yrs | >50 yrs | >50 yrs | <30 yrs |
| Incidence | Rare | Unusual | Common | Common |
| Number | Multiple | Single | Single | Multiple |
| Location | Aorta | Infrarenal Aorta | Aortoiliac | Femoral Carotid |
| | Visceral | | Femoral | |
| | Intracranial | | Previous | |
| | Peripheral | | Intimal defects | |
| Bacteriology | Gram-positive cocci | <i>Staphylococcus</i> <i>E.coli</i> | <i>Salmonella</i> Others | Polymicrobial |
| Mortality | 25% | 90% | 75% | 5% |

In the latest review of nomenclature, Sörelius suggested another subdivision to be added to classification, namely – HIV-related aneurysms (Sörelius *et Di Summa* 2018).

² Wilson SE *et al*. Arterial Infection. *Curr Probl Surg*. 1978 Sep;15:1-89. Published by ELSEVIER Inc. Creative Commons Attribution-NonCommercial-NoDerivatives 4.0 International Public License (<https://creativecommons.org/licenses/by-nc-nd/4.0/>)

2.3 PATHOGENESIS

2.3.1 ETIOLOGY AND ASSOCIATED RISK FACTORS

Healthy arterial luminal wall with an uninterrupted intimal layer is resistant to bacterial invasion. However, any clinical situation causing intimal damage, such as atherosclerosis, (syphilitic) arteritis or cystic media necrosis, may create an attachment site for bacteria and manifest as a mycotic aneurysm (Wilson *et al* 1952, Sommerville *et al* 1959, Jackman and Radolf 1989).

2.3.1.1 *Mycotic aneurysms*

A mycotic aneurysm arises, when septic an embolus from heart valve vegetations dislodges into the *vasa vasorum* of great vessels or lumen of smaller peripheral vessels. In the aorta and iliac vessels, large *vasa vasorum* arise from the site of the side branches and continue longitudinally and circumferentially in the adventitia. Occluded *vasa vasorum* cause localised vessel wall ischaemia, infection and subsequent destruction of the medial layer. When arterial wall loses its tensile strength, an aneurysm will develop. In the smaller peripheral vessels, septic embolus inoculates the wall through previously damaged intima. (Wilson *et al* 1978, Cornenwett and Johnston 2010.) Atherosclerotic inflammation or direct trauma exposes subendothelial cells and stimulates the secretion of extracellular-matrix protein as well as the deposition of platelets and fibrin. Several bacteria, especially Gram-positive cocci, present with fibrinogen- and fibronectin-binding proteins, allowing them to attach to the fibrin deposits. Furthermore, the same proteins can induce more platelet activation and aggregation and participate in endothelial cell invasion and inflammation. (Tong *et al* 2015.) The risk group includes current illicit drug users and, more rarely, immunocompromised elderly people suffering from Gram-positive sepsis (Wilson *et al* 1978).

Septic embolus can affect virtually any artery, but the aorta as well as the intracranial, superior mesenteric and femoral arteries are the predominant targets. Bifurcations and congenital coarctations are predisposed sites (Osler 1885, Stengel and Wolferth 1923).

2.3.1.2 *Infected aneurysms*

Pre-existing atherosclerotic aneurysms that become infected after haematogenous bacterial seeding form a remote infection focus. The inoculation process is somewhat

similar to what has been described above. Infected aneurysms are predominantly located infrarenally and occur in older population. In a series of over 20 000 autopsies, Sommerville found their prevalence to be 3.4% among ruptured aneurysms, (Sommerville *et al* 1959.) Nevertheless, the condition is not the same as asymptomatic bacterial presence in aneurysmal thrombus, which is found in approximately 14% of AAA cases. The clinical significance of such situation is still unclear, however. (McAuley *et al* 1984.)

2.3.1.3 Microbial arteritis

Microbial arteritis is currently the most common aortic infection, affecting more often men and older population. Some level of intimal damage is a prerequisite for a bacterial invasion of the arterial wall during bacteraemia, which is why the aorto-iliac and femoral arteries or congenital defects are the preferred locations. Microabscesses and suppuration cause wall perforation and aneurysm formation appearing saccular or multilocular in CT. (Wilson *et al* 1978, Cornenwett and Johnston 2010.) Typically, patients are immunocompromised due to malignancies, malnutrition, diabetes or autoimmune disorders. Furthermore, patients on haemodialysis are more prone to an arterial infection due to immunosuppression, atherosclerotic arteries and intravascular catheters, and they are also more often *Staph. aureus* carriers (Lee *et al* 2000, Oederich *et al* 2001, Hsu *et al* 2005). Concomitant or recent infections as a possible cause of a mycotic aneurysm can be identified in 46%–75% of cases and can comprise virtually any infection: gastroenteritis, a soft tissue or wound infection, osteomyelitis or septic arthritis, pneumonia, urinary tract infection, etc (Mundth *et al* 1968, Brown *et al* 1984, Oederich *et al* 2001, Sedivy *et al* 2012, Sörelus *et al* 2014).

2.3.1.4 Post-traumatic infected false aneurysms

Post-traumatic infected false aneurysms are sequelae of repetitive attempts at a venous injection, commonly found in the groin area. Usually, a pseudoaneurysm forms due to an arterial puncture, and infection develops later. Patients are young and predominantly intravenous illicit drug users. Common sites of such pseudoaneurysms are femoral, carotid and subclavian arteries. (Qiu *et al* 2016, Wilson *et al* 1978.)

2.3.1.5 HIV-related aneurysms

HIV-related aneurysms afflict young population, appear in advanced stages of disease and favour atypical locations: the aorta, carotid, femoral and popliteal vessels. Peri-arteritic fibroproliferative granulomatous inflammation occludes *vasa vasorum* with a cellular infiltrate, causing adventitial fibrosis. Medial fibrosis, muscle damage and elastic fragmentation follows. Internal elastic laminal fragmentation and calcifications occur in the intimal layer. HIV-related aneurysms develop without bacterial seeding; however, secondary infections are possible. (Pillay *et al* 2015.)

Etiology of mycotic aortic aneurysms, as a subject of current thesis, involves the subgroup of microbial arteritis, infected and mycotic aneurysms.

2.3.2 BACTERIOLOGY

During the pre-antibiotic era, 95% of arterial infections leading to aneurysms were caused by bacterial endocarditis. Streptococci, staphylococci and pneumococci were the most commonly cultivated bacteria (Osler 1885, Stengel and Wolferth 1923, Parkhurst and Dekcer 1955). After introduction of penicillin, embolic complications caused by valvular vegetations dropped from 80% to 45%, and the bacteriology of aortic infections became more variable (Wilson *et al* 1978). In their review of literature, Brown reported, that after the year 1965, *Staphylococcus aureus* (30%) has been the most common bacteria found in infected arterial aneurysms, followed by *Salmonella* (10%) and Streptococcal (10%) species. Gram-negative aerobes such as Clostridium, Pseudomonas and *E. coli* became more prevalent, and anaerobes Peptostreptococcus and Bacteroides emerged. Brown realised that over-use of broad-spectrum antibiotics would reveal a new spectrum of pathogens in the future. (Brown *et al* 1984.)

Currently, the spectrum of pathogens causing primary aortic infections has been divided in two. In the first, *Salmonella* is overwhelmingly dominant in Eastern Asia, and the other is dominated by Gram-positive bacteria presenting in Europe and Northern America.

In Western countries, *Staphylococcus spp* (15%–31%), *Streptococcus spp* (10%–22%) and *Salmonella spp* (9%–41%) are represented more equally; followed by *E. coli* (2%–14%), *Pseudomonas aeruginosa* (3%–9%), *Enterococcus spp* (4%) and others (Brown *et al* 1984, Oederich *et al* 2001, Dubois *et al* 2010, Vallejo *et al* 2011, Sedivy *et al* 2012, Söreljus *et al* 2014, Söreljus *et al* 2016).

In Asia, *Salmonella spp* (21%–80%) are the main causative agents, with *Staphylococcus spp* (5%–21%), *Streptococcus spp* (2%–11%), *E. coli* and *Klebsiella* (6% each), and *Mycobacteriae* (4%–7%) cultivated less often (Hsu *et al* 2002, Luo *et al* 2003, Hsu *et al* 2004, Woon *et al* 2008, Kan *et al* 2007, Kan *et al* 2009, Yu *et al* 2011, Lin and Hsu 2014, Luo *et al* 2017).

Staphylococcal strains are the most common cause of bacteraemia in Western countries (35%) (Fluit *et al* 1999). The situation is different in Asia, where a systematic review revealed a salmonella infection in 38% of 1 784 blood-culture-positive adults, 8% of which were caused by *Non-typhoidal Salmonellae* capable causing vascular infections. (Deen *et al* 2012) The speculation, why *Salmonellae spp* dominate in Asia, is linked to poor hygiene and consumption of goods bought from local markets without sanitation control. In combination with immunosuppression and atherosclerotic changes, salmonella bacteraemia becomes a strong risk factor for Asian people (Cohen *et al* 1987).

Salmonella is a Gram-negative biofilm-forming facultative anaerobic rod, which belongs to *Enterobacteriaceae* family. The species of *Salmonella typhi* and *paratyphi* cause enteric fever, but bacteria capable of invading the intima during septicaemia and causing arterial infections are known as *Non-typhoidal salmonellae*. The non-typhoid group includes several serotypes, which are normally hosted by animals and contamination occurs via food products. (Velge *et al* 2012.) The bacteraemia can appear secondarily after gastroenteritis or primarily, and cause focal infections such as osteomyelitis, urinary tract infections, soft tissue infections, microbial arteritis and endocarditis. The most common serotypes associated with arterial infections are *S. typhimurium*, *S. choleraesuis* and *S. enteritidis*. (Wilson *et al* 1978, Cohen *et al* 1987.) Non-typhoid salmonella has predilection for arterial infections. The exact mechanism of cell invasion is poorly understood, but in order to establish a disease, salmonella has several mechanisms of entering the phagocytic cells and hijacking them. (Velge *et al* 2012.) Salmonella prefers atherosclerotically damaged aorto-iliac vessels. Once vessel suppuration occurs, the aneurysm formation is considerably fast, but obscure. Ruptures of salmonella-induced aneurysms occur at smaller diameters, which is why prompt treatment is necessary (Mundth *et al* 1968, Cohen *et al* 1987, Jarret *et al* 1975, Trairatvorakul *et al* 1990, Valentine *et* Chung 2012).

A substantial amount of bacterial cultures remain negative (7%–42%) (Oderich *et al* 2001, Kan *et al* 2007, Woon *et al* 2008, Dubois *et al* 2010, Lin and Hsu 2014, Söreljus *et al* 2014, Söreljus *et al* 2016, Luo *et al* 2017). Blood cultures are positive even less often – 53% –78% of the cases (Mundth *et al* 1968, Oderich *et al* 2001, Woon *et al* 2008,

Sörelius *et al* 2014, Sedivy *et al* 2012). Many patients are treated with antimicrobial therapy prior culture acquisition, which might contribute to negative cultures, or some bacteria are just difficult to cultivate. Furthermore, when MAAs are treated endovascularly, tissue-samples for bacterial cultivation cannot be obtained and number of culture-positive patients decreases even further (Sörelius *et al* 2014). Such negative results, however, complicate the selection of antimicrobial therapy and demand more broad-spectrum medications.

2.4 EPIDEMIOLOGY

2.4.1 INCIDENCE

The incidence of mycotic aortic aneurysms is estimated to be 0.65%–1.3 % of treated aneurysms in Western countries and 3%–13.3% in East Asia (Reddy *et al* 1991, Müller *et al* 2001, Oderich *et al* 2001, Luo *et al* 2003, Yu *et al* 2011, Sörelius *et al* 2014). There are no population-based studies on the subject, and the estimates have been calculated on a per centre basis in the few studies, since data on patients treated conservatively and those who have died prehospitally are often missing. The reported incidence has decreased after introduction of antibiotics and surgical treatment, however, the true global incidence is probably higher, since data is lacking from African countries, where HIV, non-typhoid salmonella, malnutrition and hygiene problems are common (Deen *et al* 2012).

2.4.2 PROGNOSIS

Before surgical management, all cases were fatal (Sommerville *et al* 1952). After the first successful surgery in 1962, the survival rate improved with development of antimicrobial therapy and surgical skills. Currently, the early survival rates of surgically treated patients range from 81% to 95% in case of endovascular treatment and from 74% to 79% in case of conventional surgery. However, the early survival benefit of EVAR disappears, and the estimated survival at 5 years is 50%–60%. The late mortality is linked to recurrent infectious complications, since graft reinfections are lethal in 70% of cases. (Oderich *et al* 2001, Sedivy *et al* 2012, Sörelius *et al* 2014, Sörelius *et al* 2016.) Conservative

treatment with antimicrobials carries very high mortality rate, and mycotic aortic aneurysm with no treatment is eventually fatal (Lin and Hsu 2014).

2.5 DIAGNOSIS

The lack of consensus regarding the definition and diagnosis of mycotic abdominal aortic aneurysms makes a critical evaluation of existing data difficult. It is easy to distinguish between an AGI, AEF and mycotic abdominal aortic aneurysm (MAAA), but differentiating an inflammatory aneurysm from a mycotic one might be challenging, especially after EVAR application and unavailability of aortic wall bacterial culture.

An MAAA is defined as an aortic aneurysm caused by bacterial infection in aortic wall. Since bacterial presence is often hard to prove, a common agreement exists to accept the diagnosis based on combinations of four criteria. Any suspicion based on clinical signs and laboratory findings, must be supported by imaging studies and/or perioperative findings (Woon *et al* 2008, Luo *et al* 2011, Söreljus *et al* 2014, Lin and Hsu 2014, Söreljus *et al* 2016, Luo *et al* 2017, Söreljus *et al* Di Summa 2018). Despite some authors highlighting a compulsory positive bacterial culture, it is not considered a prerequisite, when antimicrobial therapy has been started prior sample acquisition (Mundth *et al* 1968, Müller *et al* 2001, Luo *et al* 2011, Vallejo *et al* 2011, Söreljus *et al* Di Summa 2018).

2.5.1 CLINICAL PRESENTATION

MAAAs are highly symptomatic, presenting with abdominal or back pain and fever in 46%–100% and 48%–99% of the cases, respectively (Soravia-Dunand *et al* 1999, Oderich *et al* 2001, Hsu *et al* 2004, Woon *et al* 2008, Yu *et al* 2011, Sedivy *et al* 2012, Lin and Hsu 2014, Söreljus *et al* 2014, Söreljus *et al* 2016, Luo *et al* 2017). Of patients, 12%–59% arrive at the hospital in shock due to rupture rather than due to sepsis (Mundth *et al* 1968, Soravia-Dunand *et al* 1999, Müller *et al* 2001, Oderich *et al* 2001, Hsu *et al* 2004, Söreljus *et al* 2016). Contained rupture into infectious tissue is common. Concomitant infections are often present, and may cause the patients to have confusing symptoms: back-pain due to discitis, osteomyelitis, and pyelonephritis; joint pain due to arthritis; flu-like symptoms due to pneumonia, etc. A historical symptomatic triad, such as abdominal pain, fever and pulsatile abdominal resistance are seen rarely (Mundth *et al* 1968, Wilson *et al* 1978).

2.5.2 LABORATORY FINDINGS

Elevated inflammatory markers are one cornerstone of an MAAA diagnosis. White blood cell count is elevated in 54%–89% of the cases and CRP rises above normal level in all cases (Oderich *et al* 2001, Hsu *et al* 2004, Woon *et al* 2008, Vallejo *et al* 2011, Söreljus *et al* 2014). Blood cultures are positive in 53%–85% of patients and the probability is higher if antimicrobial treatment has not been administered yet. (Soravia-Dunand *et al* 1999, Mundth *et al* 1968, Oderich *et al* 2001, Woon *et al* 2007, Söreljus *et al* 2014, Sedivy *et al* 2012). Continuous or recurrent bacteraemia is typical of arterial infections, especially with *Salmonella* (Soravia-Dunand *et al* 1999). Nevertheless, continuous bacteraemia despite antimicrobial treatment may refer to valvular vegetations or intestinal erosion (Cohen *et al* 1987). To improve the results of bacterial samples, board-spectrum PCR should be used to define causative agent by means of DNA sequencing.

2.5.3 RADIOLOGICAL FINDINGS

Imaging studies have a crucial role in MAA diagnosis; therefore, fast and easily accessible CTA is current gold standard in imaging of aortic infections. It enables the evaluation of vascular anatomy and periaortic tissue, identification of infectious processes in aorta with associated complications and other intra-abdominal infection focuses. The first signs of aortic infections are arterial wall irregularity, peri-aortic soft tissue oedema, a soft tissue mass and periaortic gas. As the infection progresses, an aneurysm develops. A mycotic aneurysm is eccentric and saccular or multilobular. In contrast to atherosclerotic fusiform aneurysms, mycotic ones rarely present with calcification and thrombus. A rupture can be detected as an extravasation into the surrounding tissues or haematoma adjacent to aorta (Lee *et al* 2008). Contained ruptures, however, are sometimes hard to distinguish from soft tissue mass and are therefore not revealed until perioperatively. Rapid aneurysm expansion over a short period of time is characteristic of MAA (Valentine *et al* Chung 2012). Most common findings are periaortic soft-tissue mass and saccular aneurysms, present in 30%–50% and 52%–95% of the scans, respectively. Periaortic gas is rare, presenting in 10%–16% of cases (Hsu *et al* 2002, Lai *et al* 2011, Vallejo *et al* 2011, Sedivy *et al* 2012, Söreljus *et al* 2014, Söreljus *et al* 2016).

If CTA is contraindicated, current technology in magnetic resonance angiography (MRA) can diminish motion artefacts and improve resolution for a very precise evaluation of perivascular tissues and aorta (Lee *et al* 2008).

Radionuclide scintigraphy techniques are used in equivocal cases, and ¹⁸F-FDG-PET/CT can be employed during follow-up in selected cases, before the discontinuation of antimicrobial treatment, for instance (Sedivy *et al* 2012).

3 MANAGEMENT OF ABDOMINAL AORTIC INFECTIONS

The treatment methods have evolved, and the results improved significantly over the years. Furthermore, axillobifemoral reconstruction as a gold standard from last century, has now become a marginal part of selection of treatment methods, and is only used for limited indications (Berger and Moll 2011).

Abdominal aortic infections encompass mycotic abdominal aortic aneurysms and aortic graft infections. Aorto-enteral erosions and fistulas are a subgroup of the latter, with different pathophysiology and microbiology, specifications of surgical treatment and an inferior outcome. Open surgery, including the resection of infected material, debridement and lower limb revascularisation, in combination with antimicrobial therapy is the cornerstones of infection eradication. However, during the past 20 years, MAAAs have, to an increasing extent, been treated with endovascular devices without the resection of the infected aneurysm. Due to the paucity of evidence, the debate continues in order to establish the preferred reconstruction material and revascularisation method.

3.1 IN SITU RECONSTRUCTIONS

Resection of the infected graft or mycotic aneurysm with meticulous debridement and in situ aortic reconstruction is the most prevalent method in treatment of abdominal aortic infections today. Being anatomical, it offers better patency rates and fewer amputations than axillobifemoral bypass (AXBF). However, controversy concerning the preferred conduit material still exists.

3.1.1 PROSTHETIC GRAFTS

Prosthetic interposition is most commonly accomplished using silver-coated or rifampicin-soaked grafts to provide additional protection from reinfection (see more details in section 1.4 Prevention). Encouraged by the results of comparing AXBF and prosthetic reconstruction for AGI, Oderich reported on rifampicin-soaked prosthetic reconstructions for 54 AEF patients and found a postoperative mortality of 9%, no amputations and a reinfection rate of 4% (Oderich *et al* 2006 and 2011). Similar results were reported after 15 infected EVAR reconstructions, with one fatal reinfection during the median follow-up (FU) of 14 months and no other graft complications (Fatima *et al* 2013). However, in all these studies, the authors emphasized patient selection and excluded patients with gross purulence or a large abscess in operating area. Circular omental wrapping to eliminate dead space, keep graft separated from the bowel and to enhance perigraft blood circulation was an important part of the method. (Oderich *et al* 2011, Fatima *et al* 2013.)

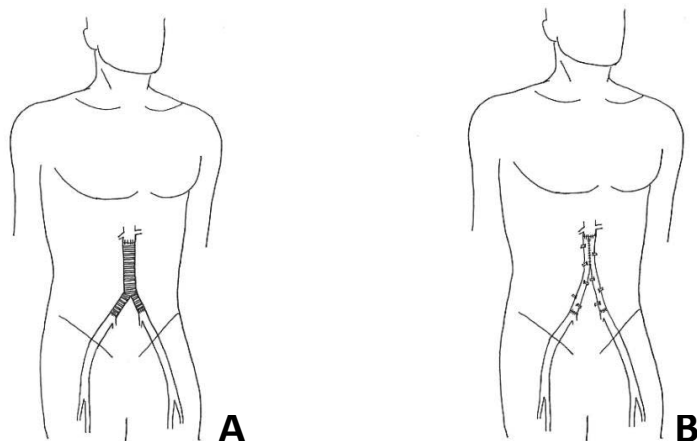


Figure 3 Illustration of in situ reconstructions with the interposition of a prosthetic graft (A) and femoral veins (B).

In a multicentre study with 197 EVAR explants due to infections, 111 reconstructions were performed with in situ prosthetic grafts, 59% of which were rifampicin-soaked.

Operation times were significantly shorter compared to reconstructions with cryopreserved allografts (CAA) or autologous femoral veins (FV), and albeit graft failures occurred in all groups, late mortality was higher among patients with prosthetic as opposed to biological reconstructions: 47% vs 29%, respectively. The lowest 5-year survival rate was 12% for patients with bare prosthetic grafts. However, 11 extra-anatomical bypasses were added to prosthetic in-line reconstruction for survival analysis, with a possible negative influence on the outcome. (Smeds *et al* 2016.)

In series by Batt, 27 consecutive aortic infections were treated with silver-acetate prosthetic grafts despite gross purulence in ten cases and MRSA in two. Copious irrigation with povidone-iodine solution prior to graft insertion was considered crucial, as well as omental wrapping of implanted graft. Perioperative mortality was 14.8%, of which 3 patients had AEF and one an AGI with upper anastomotic rupture. There was no additional mortality during the median FU of 17 months and estimated 2-year survival was 85%. One patient presented with a local recurrence of infection (3.7%). (Batt *et al* 2003.) Two more small studies showed that silver-grafts are not inferior to cryopreserved or fresh allografts regarding mortality or graft-related complications (Bisdas *et al* 2011, Pupka *et al* 2011).

Several patient series have been reported in treatment of mycotic aortic aneurysms, where in situ prosthetic repair has been preferred reconstruction method until recently in supra- and infrarenal mycotic aortic aneurysms (MAA), yielding an early mortality rate of 5%–18% and reinfection rate of 5–21% (Hsu *et al* 2002, Lai *et al* 2011, Lin and Hsu 2014, Söreljus *et al* 2016). The mortality risk was higher with emergency procedures and concomitant GI-reconstruction due to advanced disease. After “elective” MAA surgery, when patients have been treated with antibiotics for up to 4 weeks preoperatively to suppress the inflammation and eliminate bacteraemia, the reinfection rate falls to 4% and 5-year mortality rate in 2 small series to 5% (Uchida *et al* 2013, Yu *et al* 2011). It has been speculated that the insertion of a prosthetic (endo)graft would be safe in the case of an MAA after 4 weeks of preoperative iv-antibiotic treatment (Lin and Hsu 2014, Söreljus *et al* 2016).

The advantages of prosthetic reconstructions are availability, shorter operating time, excellent patency and almost no amputations, reasonable cost and good early postoperative outcome in non-emergency settings. However, considerable rates of reinfections and subsequent late mortality are reasons why biological in situ grafts have been introduced.

3.1.2 CRYOPRESERVED ALLOGRAFTS

The fresh allografts implanted in the 1970s were discouraging and complicated with graft ruptures, aneurysmatic degenerations and occlusions. In 1988 Kieffer decided to use fresh allografts as a bridge to definitive prosthetic grafting until the infection had subsided, but outcome was surprisingly good and only few patients underwent late prosthetic grafting despite numerous occlusive events and reoperations. In 1996, due to changes in legislation, Kieffer *et al* shifted to using CAAs. In a series of 179 patients, aorto-iliac aortic infections were treated with fresh allografts in 111 patients, and with CAAs in 68 patients. During the postoperative period, all nine patients, suffering graft complications, were among fresh graft recipients and four of those patients died due to graft rupture (2.2%). During a mean FU of 46-months, one fatal CAA rupture occurred due to reinfection and two more fresh grafts ruptured after silent dilatation. Second reinfection was reoperated. Forty-seven patients suffered non-infective graft complications, such as thrombosis or dilatation with fresh allograft recipients dominating in this group. Despite a significant number of reinterventions, the estimated 5-year survival was 55%. Fresh allografts appeared as a risk factor for complications and fresh thoracic allografts a significant risk factor for aortic graft complications. Nevertheless, late reinfection rate was 1.4%, and only one patient needed amputation. Late deterioration of fresh allografts was speculated to be immunomediated. (Kieffer *et al* 2004.)

A variety of results have been reported regarding durability of CAAs. CAA is very infection resistant, with reported reinfection-rate of 0% to 4%; however anastomotic ruptures as well as late graft occlusions and aneurysmatic dilatations require reinterventions in 5%–55% of the cases (Lesèche *et al* 2001, Vogt *et al* 2002, Bisdas *et al* 2010, Harlander-Locke *et al* 2014, Ben Ahmed *et al* 2017, Heo *et al* 2017, Lejay *et al* 2017). The early mortality of 6%–28%, nor the 5-year mortality of 36%–60%, have no significant advantage compared to other in situ reconstructions (Bisdas *et al* 2010, Harlander-Locke *et al* 2014, Touma *et al* 2014, Ben Ahmed *et al* 2017, Lejay *et al* 2017). Despite graft occlusion, the reported limb salvage is 100% (Lesèche *et al* 2001, Vogt *et al* 2002, Harlander-Locke *et al* 2014, Lejay *et al* 2017).

A multicentre study from the United States including 220 patients reported 14% of graft-related complications and 5% rate of graft explantations. Predicting factors for graft complications were age >70 years, peripheral vascular disease and virulent, gram-negative organisms. Graft explant was associated with age and partial prosthetic graft reconstruction. Freedom from graft complications was estimated to be 80% at 5 years. (Harlander-Locke *et al* 2014.) Despite other postoperative complications, the recurrence

of graft infections is low. During the early postoperative period, it is hard to distinguish whether graft ruptures are due to friability or reinfection, and the reinfection rates of 0%–4% may therefore be underestimated. Despite continuous controversy, no evidence exists of a relationship between the blood type (ABO) mismatch of CAAs and graft-related complications (Della Schiava *et al* 2016, Minga Lowampa *et al* 2016, Heo *et al* 2017).

In a multicentre review with 33 infected EVAR explants, 23 patients were treated with in-line CAA reconstruction and 10 patients with AXBF, in situ rifampicin-soaked silver prosthesis or autologous femoral veins. No differences in graft performances were seen. Nevertheless, two CAAs ruptured during the early period due to a reinfection in AEF patients. (Chaufour *et al* 2017.)

Technical details could diminish the graft-related complications after CAA reconstruction: following proper thawing protocol, using the appropriate size and length of graft, tension-free anastomosis with spatulation in case on size mismatch, securing side branches with polypropylene sutures through the CAA wall, circumferential reinforcement to the anastomoses, application of gentamycin-impregnated fibrin glue around the anastomoses and aggressive drainage of intra-abdominal collections and wounds. Omental wrap and sartorius myoplasty in the groin are recommended. By implementing these measures, Vogt *et al* were able to decrease graft-related complications from 7/10 to 2/39 patients (80% vs 2.6%) (Vogt *et al* 2002).

Downsides of CAA are availability, cost and uncertain durability. Few centres with their own tissue banks and organ-harvesting programmes have continuous access, although most centres are able to obtain a CAA within a few days, excluding emergency use (Bisdas *et al* 2011, Lejay *et al* 2017).

3.1.3 AUTOLOGOUS FEMORAL VEINS

After Nevelsteen and Clagett reported the first series of autologous venous aortic reconstructions with early mortality of 10% and no reinfections, the use of femoral vein as an aortic conduit has widely spread. In Clagett's series, a neo-aorta was reconstructed in half of the patients using saphenous veins, and 64% of these occluded within the first year, whereas no graft complications occurred among large-calibre FV conduits. (Clagett *et al* 1993, Nevelsteen *et al* 1995.)

Femoral veins with no post-thrombotic changes and a minimum diameter of 6–7 mm, can be harvested from the popliteal fossa to confluence with profunda vein and used as an

autologous conduit in aortic infectious reconstructions (Clagett *et al* 1993). The distal popliteal vein must be spared, and care must be taken to not leave a proximal “stump” to allow thrombus formation (Neufang and Savvidis 2016). Valves should be excised after vein eversion under direct visual control, since valve remnants cause stenotic complications (Beck *et al* 2008). A new aorta can be reconstructed in several configurations, however, a “pantaloon” shape is most commonly used after proximal ends are cut open for few centimetres and sewn together with continuous suture (Figure3). FVs are kink-resistant when compared to saphenous vein grafts (Clagett *et al* 1993, Smith and Clagett 2008, Beck *et al* 2008, Neufang and Savvidis 2016).

A review of 187 FV reconstructions showed postoperative mortality of 10%, procedure-related mortality of 14% and reinfection rate of 5%. Six out of ten reinfection-patients were treated for an AEF, five of whom had new duodenal leakage. A few patients had no obvious signs of infection, but since they were immunocompromised and initially suffered from a polymicrobial infection, the infection was considered to be the most likely agent. Factors for poor early outcome were a *Candida* infection, *Klebsiella*, *Bacteroides fragilis*, sepsis and blood loss of >3 litres; poor late outcome was associated with age of >64 years, initial graft rupture, chronic kidney disease (CKD) or a fungal infection. Overall survival at 5 years was 52%, but in cohorts with and without AEF 18.4 % and 56.7%, respectively. FVs seem infection-resistant, but in the circumstances of impaired host defences and continuous bacterial presence, risk of reinfection remains. (Ali *et al* 2009.) Factors possibly predisposing to graft reinfections include malnutrition, immunocompromised state, active cancer, duodenal leak/continuous bacterial presence and a polymicrobial, especially fungal infection. Severely debilitated patients, therefore, may benefit from extra-anatomical reconstructions. (Ali *et al* 2005.)

The 5-year survival rates are similar to those of other in situ reconstructions at 45–70%, but late stenotic graft complications appear. The early amputation rate is 2–7% and limb salvage at 5 years 89%–96%. The primary patency rates at 5-years are 75%–91%. (Daenens *et al* 2003, Ehsan and Gibbons 2009, Beck *et al* 2008, Dorweiler *et al* 2013.) Beck reported 11 (4.6%) stenotic lesions and 9 (3.8%) occlusions among 240 aortic reconstructions and found small vein size (<7.2mm), extensive smoking and cardiovascular disease as risk factors (Beck *et al* 2008).

Vein harvesting is generally well-tolerated when distal popliteal vein is left intact and drainage to common femoral vein unobstructed. Mild swelling occurs in 15% of the patients; severe swelling with skin changes and ulcers are extremely rare. Postoperative fasciotomy is necessary in 12% of the cases and usually associated with previous severe

limb ischaemia, preoperative volume overload, a too distal deep vein or concomitant ipsilateral saphenous vein harvest. (Smith and Clagett 2008, Neufang and Savvidis 2016.)

Main downsides of FV applications are extensive surgical trauma for a frail patient and long duration of operation of up to 10–12 hours (Nevelsteen *et al* 1995, Ali *et al* 2009). However, in case of a non-emergency situation, FVs may be mobilised a day prior to aortic reconstruction without compromising the outcome (Ali *et al* 2008).

3.1.4 XENOPERICARDIAL TUBE GRAFTS

Xenopericardial grafts are currently self-made from a bovine, porcine or equine pericardium and sewn together into a tube configuration. Additional smaller-diameter tubes can be added as aortic graft limbs. Advantages are constant availability, ease of handling, inexpensiveness and biocompatibility. Few small series with up to 35 patients have been published with early mortality of 7.7%–31% and mid-term total mortality of 32%–49% (Czerny *et al* 2011, Kubota *et al* 2015, Lutz *et al* 2016, Weiss *et al* 2017). Among a total of 71 patients, one early anastomotic rupture was encountered and three anastomotic pseudoaneurysm were operated on, two of which were considered occurring due to technical problems rather than graft complications. Three studies reported no reinfections, whereas Lutz reported two reinfection-ruptures, one of which was tube graft rupture and the other was rupture of a native artery adjacent to anastomosis. (Czerny *et al* 2011, Kubota *et al* 2015, Lutz *et al* 2016, Weiss *et al* 2017.) Xenopericardial tube grafts (XPT) seem infection-resistant, and no late degenerations have been reported, however, the evidence is scarce and data on durability is lacking.

Two meta-analyses have compared in situ and extra-anatomical reconstructions including all of the above-mentioned reconstruction materials except XPTs. Both studies concluded that in situ reconstructions are superior regarding mortality, reinfections, conduit failures and amputations. Rifampicin-soaked and silver-prostheses are associated with lowest amputation rates but carry the highest risk of reinfection (11%). Bare polyester grafts remain inferior to silver or rifampicin grafts. FVs are the most resistant to reinfections, followed by cryopreserved grafts, but amputation-rate is high (2%–24%) despite a low rate of graft occlusions (2%). Early mortality was significantly lower for FVs (10%) and rifampicin-soaked prostheses (12%) compared to CAAs (22%) and silver-prostheses. Late survival was better for patients treated with biological grafts.

Batt *et al* concluded that, for older individuals, silver prostheses would be preferable, while FVs should be preferred for younger patients without an AEF and silver- or rifampicin-soaked prostheses for patients with an AEF. (O'Connor *et al* 2006, Batt *et al* 2018.)

3.2 ENDOVASCULAR REPAIR

During the last few decades, EVAR has been adopted as the preferred treatment in case of mycotic aortic aneurysms in several centres. A systematic review by Kan reported postoperative survival of 89.6 % and 2-year survival of 82.2%. They divided patients into healed patients and those with persistent infection after operation and reported 1-year survival rates of 94% vs 39%, respectively. Predictive factors for persistent infection were older age, ruptured aneurysm or fistula and perioperative fever. Preoperative antibiotic treatment lasting >1 week and adjunctive procedures, such as collection drainage or surgical debridement were protective. (Kan *et al* 2007.) A study from Czech Republic presented postoperative survival rate of

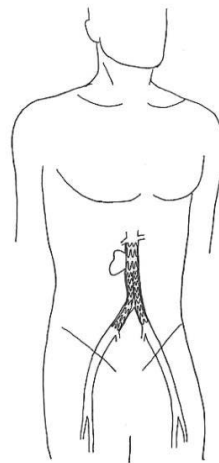


Figure 1 *Illustration of endovascular treatment for mycotic abdominal aortic aneurysm*

of 81%, but only 50% survived one year. Half of the deaths in the cohort were infection-related. (Sedivy *et al* 2012.) A multicentre study of 124 patients confirmed the perioperative advantage of endovascular treatment, with an early survival of 91%. Nonetheless, 27% of survivors developed infection-related complications that were fatal in 70% of cases. The total infection-related mortality was 19%, and the survival advantage disappeared: the one- and 5-year survival rates were 76% and 55%, respectively. (Söreljus *et al* 2014.) A Swedish nationwide study once again showed the advantage of EVAR over open repair during the first 30-days, with respective survival

rates of 99% and 89%, but difference vanished at 5-years (58% and 60%, respectively). However, since the open repair overwhelmingly constituted prosthetic reconstruction, the respective reinfection rates of 18% and 24% were similar in both groups. Patients treated with open surgery were 7 times more likely to expire during the first 3 months. (Sörelius *et al* 2016.) Nonetheless, the authors who approve of EVAR emphasize the duration of preoperative antimicrobial treatment of up to 4–6 weeks when possible to decrease the bacterial load. Postoperatively, lifelong suppression is often necessary. (Kan *et al* 2007, Kan *et al* 2010, Sörelius *et al* 2014.) EVAR is feasible and provides excellent early survival, but since reinfection risk is substantial, patients with aforementioned risk factors and non-salmonella infections should be closely followed, and the threshold for a conversion should be low (Sörelius *et al* 2014).

In contrast to native infections, in case of AGI, EVAR is indicated only for rupture or AEF with haemodynamic instability. In a meta-analysis of mixed case-reports of primary and secondary AEFs, postoperative mortality was 8.5% and recurrent bleeding appeared in 36% and sepsis in 41% of cases. Estimated 2-year survival was 52%. Patients at risk presented with large fistulas, had tube graft placement, were septic, did not have intestinal repair and developed new AEFs. Patients with no additional intestinal repairs were at high risk of infectious complications (48% vs 0%). (Kakkos *et al* 2011.) For patients with life expectancy of less than 6 months, EVAR and lifelong antibiotic treatment could be considered a definitive repair, for patients with longer life expectancy, EVAR can serve as a bridge only (Haidar *et al* 2017).

Treating EVAR infection with re-lining or device extension is unsuccessful with or without additional drainage (Lyons *et al* 2013).

3.3 AXILLOBIFEMORAL RECONSTRUCTION

Resection of infected material and debridement, followed by extra-anatomical axillobifemoral bypass, is an old technique with the main advantage of inserting a new reconstruction through uninfected planes (Figure 2). When extra-anatomic reconstruction is performed first, aortic cross-clamping and the subsequent resection of the infected graft and tissue will have a lesser effect on the cardiac afterload. Therefore, procedure is better tolerated for patients in poor condition and of an advanced age. (Dubois *et al* 2010.) The shortcomings of axillobifemoral bypass (AXBF) are a high rate of reinfections, occlusions and aortic stump blowout. Furthermore, the rate of stump blowout increases to 31% and rate of reinfections to 75%, when AXBF is reconstructed due to an AEF

(Jauseeran *et al* 1997, O'Connor *et al* 2006, Woon *et al* 2008, Batt *et al* 2011). Albeit new prosthesis is inserted into non-infected area, continuous bacteraemia, possible perioperative contamination, immunocompromised condition and poorer perfusion in subcutaneous fat plane make the new graft more susceptible to reinfection. In conclusion, AXBF reconstruction carries a higher long-term mortality of 26%–60% compared to in situ operations with a corresponding rate of 24%–48% (Berger and Moll 2011, Charlton-Ouw *et al* 2014).

In the light of current evidence, AXBF remains rather a bail-out option in case of gross purulence in the abdominal cavity, active osteomyelitis, discitis, psoas abscess, and multiresistant virulent bacteria for patients in extremely poor condition or of an advanced age (Soravia-Dunand *et al* 1999, O'Connor *et al* 2006, Wilson *et al* 2016, Batt *et al* 2018).

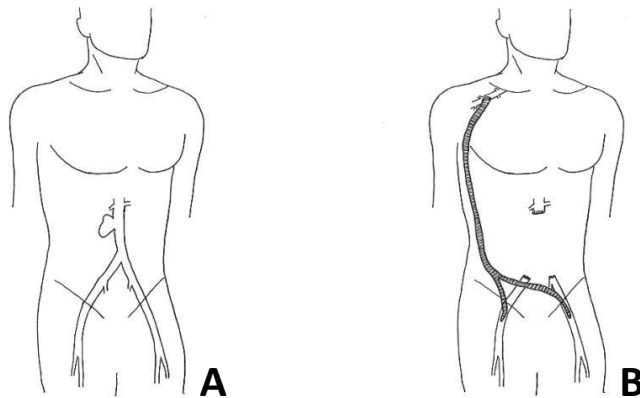


Figure 4 Illustration of a mycotic abdominal aortic aneurysm (A) and axillobifemoral bypass (B) after aneurysm resection.

3.4 GRAFT PRESERVATION AND CONSERVATIVE TREATMENT

Indications for partial aortic graft resection are prohibitive risk for total explant and, occasionally, localised or asymptomatic infection. Total retention due to localised infection of an extracavitary part is accepted in low-risk patients, when graft is patent and

intact, and patient is not septic. Partial resection can be considered in case of localised purulence of the groin, distal anastomosis pseudoaneurysm or limb thrombosis with rest of the graft firmly incorporated. Infected and thrombosed graft limbs must be resected, since an intraprosthetically organised thrombus is impossible to sterilise. In a prohibitive-risk patient with septic infection, fluid collections must be drained percutaneously or via laparotomy and frequently irrigated with an antibiotic-solution or providone-iodine until discharge is clear. Intestinal fistulas have to be repaired. Debridement of perigraft tissue is recommended, and exposed parts of graft must be covered with vascularised myoplasty or omentoplasty intra-abdominally. Antimicrobial treatment and close surveillance are a mandatory part of the treatment. (Szilagy *et al* 1972, Calligaro and Veith 1997 and 2003, Lawrence 2011.)

Graft preservation carries a lower risk with low-virulent bacteria; however, Calligaro reported the long-term results of nine patients with one early death and only one reinfection among patients with highly virulent bacteria (*Pseudomonas*, *E.coli*, MRSA), while using aggressive drainage and debridement (Calligaro *et al* 2003). In another cohort of 17 patients unfit for graft explant, septic relapses occurred in 59% of patients during median FU of 57 months, and 59% eventually died due to infection-related reasons (Maze *et al* 2013). Postoperative antibiotics were administered in both series, but permanent suppression used only in the latter series. Despite the suppression therapy, relapses were frequent and more resistant bacteria occurred. (Calligaro *et al* 2003, Maze *et al* 2013.)

Endograft retention in case of a symptomatic AGI and solely conservative treatment of an MAAA are rather palliative methods only. Based on a recent review, the midterm survival after conservative therapy with or without drainage was 67% (Soravia-Dunand *et al* 1999, Lyons *et al* 2013, Chaufour *et al* 2017, Li *et al* 2018). However, small unruptured aneurysms can rarely resolved, and Lin reported a mid-term survival of 33% among 24 patients (Lin and Hsu 2014).

3.5 ANTIMICROBIAL THERAPY

Antimicrobial therapy is crucial part of management of abdominal aortic infections. Antibiotics without a surgical intervention carry high mortality, therefore combination-therapy is recommended. The treatment should be organised by infectious disease specialist and guided by bacterial susceptibility or started with broad-spectrum antibiotics and de-escalated based on antibiogram. In case of septic patients, treatment starts

immediately after acquisition of two different sets of blood cultures. In non-septic patients, additional needle aspiration samples from fluid collections or abscesses are taken under ultrasound or CT guidance prior the administration of antibiotics. (Revert *et al* 2015.)

Antimicrobial therapy is initiated intravenously with bactericidal medication and recommended to be continue for at least 6 weeks postoperatively. When using compounds with good bioavailability (rifampicin, fluoroquinolones), conversion to oral antibiotics can occur sooner, whereas elevated biomarkers of inflammation are normalised. After parenteral treatment, oral medication lasting for 3–6 months may be considered, depending on micro-organism isolated, treatment method used and clinical course of disease. (Revert *et al* 2015, Wilson *et al* 2016.) When biological grafts are used, patients are generally treated with antimicrobial medicine for 6 weeks and thereafter medication is tailored individually. Life-long suppression, however, is rare with biological reconstructions, and used in case of partial graft excision only. (Daenans *et al* 2003, Bisdas *et al* 2010, Dorweiler *et al* 2013, Weiss *et al* 2017.) With prosthetic reconstructions, life-long suppression is commonly used (Oderich *et al* 2011, Fatima *et al* 2013, Smeds *et al* 2016). Relapses may appear after compliance problems; furthermore, adverse drug effects and acquisition of resistant organisms are downsides of long-term medication (Hsu *et al* 2009, Oderich *et al* 2011, Söreljus *et al* 2016).

In case of endovascular treatment of MAAA, some authors recommend preoperative antibiotic treatment for 4–6 weeks until blood cultures become negative. Thereafter the risk for stent graft reinfection is low. (Hsu *et al* 2002, Kan *et al* 2007.) Nevertheless, the evidence is lacking and since MAAA carries a high risk of rupture, the delay might be fatal.

Anti-fungal treatment cannot be disregarded in patients with aortic infections. Due to long antibiotic treatment, the yeast overgrowth is common, or *Candida* can be part of the intestinal microflora of AEF patients. When a fungus is cultured, 10-days parenteral treatment is recommended, and if the cultures remain negative thereafter, oral suppression lasting from 6 weeks to 3 months is recommended, if oral medication is available. (Revert *et al* 2015.)

4 ACUTE KIDNEY INJURY IN THE MANAGEMENT OF AORTIC DISEASE

4.1 DEFINITION

Acute renal failure is a definition commonly used describing a rapid decline in glomerular filtration rate (GFR) which might require renal replacement therapy (RRT) with or without pre-existing renal disease. However, since even minor changes in renal function are linked to increased risk of mortality, the definition should be broader and amenable to the prevention, early detection and prompt treatment of renal dysfunction. Therefore, the term of acute kidney injury (AKI) was introduced to describe rapid decline of GFR and accumulation of uraemic waste products within one week of triggering event, such as surgery. (Van Biese *et al* 2006, Kellum *et al* 2013.)

AKI is defined as any of the following:

- increase in serum creatinine (SCr) by $\geq 26.5\mu\text{mol/l}$ ($\geq 0.3\text{mg/dl}$) within 48 hours;
- OR**
- increase in SCr to 1.5 times baseline value, which is known or presumed to have occurred within previous 7 days
- OR**
- urine volume of $< 0.5\text{ml/kg/h}$ for 6 hours

(Kellum *et al* 2013, KDIGO Clinical Practice Guideline for Acute Kidney Injury 2012.)

4.1.1 STAGING AKI

There are a few different classifications, or staging systems, used in current literature for AKI. In the earlier literature, an elevation of the preoperative SCr to $> 176\mu\text{mol/l}$ ($> 2\text{mg/dl}$) and the need for RRT were the only two criteria for postoperative renal dysfunction, but results are currently reported based on the RIFLE classification (Table 3) or KDIGO stages (Table 4), making reporting the results more homogenous and comparable. (Chong *et al* 2009.)

RIFLE – an acronym for **R**isk of renal dysfunction; **I**njury and **F**ailure of the kidney, **L**oss of kidney function and **E**nd-stage renal disease – constitutes a classification of AKI based

on international consensus criteria (Bellomo *et al* 2004). Since urine output and estimated GFR are more sensitive, albeit, not very specific, and since SCr is specific, but sometimes lags behind in renal injury and recovery, all three parameters were included in the RIFLE criteria. Based on aforementioned parameters, RIFLE defines three stages of severity of renal dysfunction during the early postoperative period (Risk, Injury and Failure) and two outcome measures after 30-day period (Loss, ESRD). (Bellomo *et al* 2004, Van Biese *et al* 2006.)

After implementing the RIFLE criteria, a group of nephrologists and intensivists, the Acute Kidney Injury Network (AKIN), suggested modifications to make the classification more

Table 2. *The RIFLE criteria and classification of AKI for adults by Bellomo et al 2004.*

| Stages | GFR criteria | Urine Output Criteria |
|----------------|---|--|
| Risk | Increase of SCr x1.5 OR GFR decrease >25% | <0.5ml/kg/h for 6 h |
| Injury | Increase of SCr x 2 OR GFR decrease >50% | <0.5ml/kg/h for 12 h |
| Failure | Increase SCr x 3 OR GFR decrease 75% OR SCr $\geq 350 \mu\text{mol/l}$ ($\geq 4\text{mg/dl}$) with acute increase at least 44 $\mu\text{mol/l}$ (0.5mg/dl) | <0.3ml/kg/h for 24 h (Oligouria) OR Anuria for 12 h |
| Loss | Complete loss of kidney function >4 weeks = Persistent acute renal failure | |
| ESRD | End-stage Renal Disease (>3 months) | |

GFR, glomerular filtration rate; SCr, serum creatinine

sensitive. After two measurements over 48h, an elevation in SCr levels ($\geq 26.5\mu\text{mol/l}$ or 0.3mg/dl) was added to the first (Risk) stage, since it is linked to increased mortality independently of comorbidities. AKIN also classified patients needing RRT into stage 3 (Failure) and excluded both outcome criteria. (Metha *et al* 2007, Kellum *et al* 2013.) Therefore, modified RIFLE classification became quite similar to the latest KDIGO staging system.

Kidney Diseases: Improving Global Outcomes (KDIGO) consensus published guidelines for diagnosing and treating AKI in 2012 and defined severity of AKI in three stages. The parameters are SCr and urine output, and the lowest criterion defines the stage. New-onset RRT qualifies for stage three. (KDIGO Clinical Practice Guideline for Acute Kidney Injury 2012.)

Table 3. Staging of AKI by KDIGO.

| Stages | Serum Creatinine | Urine Output |
|--------|---|--|
| 1 | 1.5–1.9 times the baseline value OR $\geq 26.5\mu\text{mol/l}$ ($\geq 0.3\text{mg/dl}$) increase | $<0.5\text{ml/kg/h}$ for 6–12 h |
| 2 | 2–2.9 times the baseline value | $<0.5\text{ml/kg/h}$ for ≥ 12 h |
| 3 | 3 times the baseline value OR Increase in serum creatinine to $\geq 353.6\mu\text{mol/l}$ ($\geq 4.0\text{mg/dl}$) OR Initiation of renal replacement therapy | $<0.3\text{ml/kg/h}$ for ≥ 24 h OR Anuria for ≥ 12 h |

4.2 PATHOPHYSIOLOGY OF AKI DUE TO ISCHAEMIC INSULT

AKI can be classified as pre-renal, acute post-renal obstruction or intrinsic renal disease. Pre- and post-renal AKI are the results of extra-renal conditions, which can develop into

intrinsic disease without treatment. Ischaemic complications due to renal or suprarenal artery clamping in complex aortic surgery are the cause of intrinsic AKI. (Markis and Spanou 2016.)

Aortic cross-clamping at the thoracic level decreases the renal blood flow by 85%–94%, leading to a diminished GFR and urine output (Zammert and Gelman 2016). Suprarenal clamping and de-clamping induce an ischaemia–reperfusion insult leading to acute tubular necrosis that may manifest as AKI. Prolonged warm ischaemia causes tubular cell injury and apoptosis. An inability to convert from oxidative to glycolytic metabolism makes the epithelial cells of *pars recta*, and thick ascending tubules of nephron in outer medulla, most susceptible to oxygen deprivation. Ischaemia-injured microvessels vasoconstrict and, in combination with endothelial-leukocyte interactions and activated coagulation cascade, lead to small vessel occlusion. Local oedema due to ischaemia and inflammation lead to tubular necrosis. Desquamated injured and apoptotic cells form casts, causing tubular obstruction and increased intratubular pressure. Furthermore, now uncovered basement membrane is a weak barrier, allowing glomerular filtrates to backleak to the interstitium. However, after reperfusion the kidney can recover from the ischaemic insult. Replacement of lost tubular cells depends on the migration and differentiation of surviving cells; therefore, the repair is often incomplete, and fibrosis occurs. Post-ischaemic development of chronic kidney disease is associated with many factors, but especially with the chronic activation of macrophages and long-term hypoxia. Albeit perfusion is re-established, the amount of microvessels remains decreased, causing chronic hypoxia, which leads to chronic kidney injury. (Bonventre *et al* 2011, Makris and Spanou 2016.)

Healthy kidneys should tolerate warm ischaemia for up to 25 minutes, thereafter additional protection could be achieved with renal cooling, to diminish the oxygen consumption, or with isothermic perfusion (Köksoy *et al* 2002, Yeung *et al* 2008, O'Donnell *et al* 2018).

4.2.1 INCIDENCE AND PROGNOSIS OF AKI AFTER AORTIC SURGERY

Incidence of AKI is lower after infrarenal aortic surgery, ranging from 2.9% to 15% among patients treated with EVAR and from 9.5% to 23% among patients treated with open surgery (Chong *et al* 2009, Castagno *et al* 2016, Zarkowsky *et al* 2016, Dariane *et al* 2017, Stadius van Eps *et al* 2017). Incidence increases with suprarenal clamping and additional renal reconstructions, ranging from 17% to 36% and an incidence of 28% has

been reported after complex endovascular procedures encompassing the renal arteries (Chong *et al* 2009, Marrocco-Trischitta *et al* 2009, Sailer *et al* 2016, Sugimoto *et al* 2017, O'Donnell *et al* 2018).

Postoperative mortality, late mortality and future CKD are associated with increasing severity of AKI. Among patients with suprarenal clamp, O'Donnell *et al* reported higher postoperative mortality after kidney injury independently of the preoperative renal function – 3.1% without renal dysfunction, 6.2% with AKI and 18.3% for patients on RRT. Furthermore, the long-term mortality was also associated with AKI and RRT (O'Donnell 2018). Similarly, compared to non-AKI patients, occurrence of AKI predicted higher early mortality after infrarenal aortic repair with rates of 0.6% vs 4.8%; and in a cohort of mixed-level aortic clamping – 4.3% vs 35% (Grant *et al* 2012, Castagno *et al* 2016).

Chronic renal disease developed in 15.9% of patients in Sugimoto cohort after supra- or inter-renal aortic clamping, 52.9% of those patients suffered AKI previously (Sugimoto *et al* 2017). Sailer reported that postoperative AKI-group was at a 3.01-fold risk of developing CKD compared to the non-AKI group (Sailer *et al* 2016).

The 5-year survival of patients without postoperative AKI has been estimated to be 77% as opposed to the 54% for patients with AKI, while only 23% of the patients on RRT survive for three years (Zarkovsky *et al* 2016).

4.2.2 RISK FACTORS FOR AKI

The strongest risk factor for postoperative AKI is preoperative renal dysfunction, and it is linearly associated with the severity of disease. Other included risk factors are age > 75 years, preoperative respiratory disease, smoking, hypertension, a symptomatic aneurysm and a suprarenal aortic clamp. (Chong *et al* 2009, Marrocco-Trischitta *et al* 2009, Grant *et al* 2012, Castagno *et al* 2016, Dariane *et al* 2017.) In complex aortic surgery encompassing renal arteries, the risk of postoperative AKI increases with suprarenal aortic clamping time over 25 minutes, suprarenal or supravisceral clamp position, additional renal artery reconstruction, male sex, diabetes, and with morbid obesity. (Wahlberg *et al* 2002, Marrocco-Trischitta *et al* 2009, Chong *et al* 2009, Sugimoto *et al* 2017, O'Donnell *et al* 2018.)

Perioperative hypovolemia, renal artery embolization, low systemic vascular resistance due to anaesthetics and renal vein division may additionally contribute to the development of AKI (Marrocco-Trischitta *et al* 2009, Maxwell and Bell 2017).

4.3 TREATMENT OF AKI

The early recognition and prevention of further renal damage is the most effective treatment of AKI. Further deterioration can be addressed with haemodynamic stability and adequate renal blood flow. The first step is to treat the underlying cause if possible. Once AKI has developed, the treatment becomes supportive to allow renal recovery. Fluid management in combination with vasopressors should be aimed based on haemodynamic goals to correct hypovolemia while synchronically avoiding fluid overload. Isotonic crystalloids should be preferred if blood products are not indicated and colloids avoided. In case of volume overload, loop-diuretics can be used, which may stimulate urine output and shift the fluid balance. Nephrotoxic agents should be avoided, and alternatives used. (Kellum *et al* 2012, Ad-hoc working group of ERBP 2012, Bell *et al* 2016, Vaara and Bellomo 2017.)

Electrolyte abnormalities and acidosis are common complications of AKI. The goal of treatment in hyperkalaemia is hiding extracellular potassium in the intracellular space and stabilising the cellular membrane. Insulin and glycosse infusion forces potassium intracellularly, and calcium gluconate stabilizes the membrane. Sodium bicarbonate shifts potassium back into intracellular space, but only a limited amount of sodium carbonate should be used and only in case of acidosis due to possible cause of hypernatremia and subsequent development of fluid overload. Diminished GFR causes hypocalcaemia and replacement is recommended, often in combination with the treatment of underlying hyperphosphatemia. (Maxwell and Bell 2017.)

The most effective treatment of electrolyte abnormalities, acidosis, fluid overload and azotaemia is RRT. Timing of the initiation of RRT is, however, controversial due to lack of evidence. RRT is associated with the risk of complications and, therefore, waiting for renal recovery is common. It is widely accepted that combination of severe hyperkalemia, severe acidosis, pulmonary oedema and severe uraemia is indication for dialysis, but in a less dramatic situation, SCr and urea are often followed. In case of postoperative AKI, fluid overload should be considered an indication for RRT and dialysis seen as renal support rather than renal replacement. (Kellum *et al* 2012, Maxwell and Bell 2017.)

4.4 PREVENTION OF AKI DURING AORTIC SURGERY

4.4.1 AORTIC CROSS-CLAMPING

Based on a substantial body of evidence, suprarenal clamping with cessation of renal arterial perfusion is a risk factor for postoperative AKI in complex aortic surgery (Marrocco-Trischitta *et al* 2009, Jeyabalan *et al* 2011, Hobson *et al* 2018, O'Donnell *et al* 2017). A renal ischaemia time of <25 min has been regarded as considerably safe without additional renal protection, thereafter, the risk of AKI increases in conjunction with clamping time (Wahlberg *et al* 2002, Dubois *et al* 2013, O'Donnell *et al* 2018, Hobson *et al* 2018). When concomitant renal artery reconstruction is performed, the risk of renal injury is elevated even further (Chong *et al* 2009, Dubois *et al* 2013). Inter-renal clamping does not seem to affect renal function more than infrarenal clamping (Marrocco-Trischitta *et al* 2009). Suprarenal and supramesenteric clamps have been associated with a possible visceral embolisation of atherosclerotic debris and are therefore recommended to be avoided when possible. Nevertheless, if preoperative imaging excludes atherosclerosis or perivisceral thrombus, lowermost clamp is recommended. (Marrocco-Trischitta *et al* 2009, Jongkind *et al* 2010, Kasahara *et al* 2013, Hobson *et al* 2018.) Supravisceal aorta is most often healthy, but downsides of clamping it are increased cardiac afterload and a global visceral ischaemia-reperfusion insult that may additionally contribute to postoperative organ dysfunction and AKI (Sarac *et al* 2002, Hanssen *et al* 2008, Marrocco-Trischitta *et al* 2009, Jongkind *et al* 2010, Kasahara *et al* 2013, Yeung *et al* 2016).

4.4.2 PHARMACOLOGICAL PROTECTION

Pharmacological protection, cold-fluid renal perfusion and temporary shunts are used to diminish the effect of an ischaemia-reperfusion injury to the kidneys. Mannitol is an osmotic diuretic causing renal vasodilatation and increasing tubular urine flow. As a free-radical scavenger, it reduces the ischaemia-reperfusion injury. It is widely used before suprarenal clamp placement, but albeit several studies have reported mannitol use to enhance postoperative urine output, convincing evidence of its benefits in avoid AKI is lacking. (Hersey and Poullis 2008, Kellum *et al* 2012.) Fenoldopam mesylate is a short-acting dopamine receptor agonist that causes renal vasodilatation and inhibits tubular sodium reabsorption. Continuous infusion perioperatively and during early postoperative

period has been shown to be renoprotective by one randomized controlled trial in the context of cardiac surgery, however data in the specific context of aortic surgery is non-existent. (Cogliati *et al* 2007, Kellum *et al* 2012.)

4.4.3 COLD RENAL PERFUSION

Hypothermia reduces cell metabolism and oxygen consumption, there by cooling the renal parenchyma to 10 degrees, oxygen consumption decreases to < 5%. After suprarenal clamping and opening of the aneurysm sac, small Pruitt catheters are placed into renal arteries and, after the initial bolus, continuous perfusion is started. Either, Ringer's solution or saline can be used as a perfusate. Selective use of four-degree perfusion is common, when longer renal ischaemia is expected, or if the patient has preoperative renal dysfunction. (Yeung *et al* 2016.) A review by Jongkind comparing studies with selective cooling, to studies, where it was not reported, and showed fewer cases of new-onset dialysis among patients with cooling: 2.7% vs 5.7%, respectively (Jongkind *et al* 2010). Yeung found no postoperative AKIs after elective repair of a juxtarenal aneurysm with renal cooling. Study among patients with ruptured a juxtarenal aneurysm reported postoperative mortality of 48%, where 2 out of 10 patients who died received cold perfusion and 8 had not. Out of 11 patients suffering a postoperative AKI, 10 were operated on without cold perfusion. (Yeung *et al* 2008 and 2010.) The benefit of cold perfusion was also indicated in a recent register-based study including 2 635 patients with suprarenal aortic clamping, where renal cooling was associated with a lower risk of AKI, after renal ischaemia time exceeded 25 min (O'Donnell *et al* 2018).

4.4.4 ARTERIAL PERFUSION

To overcome the risk from longer suprarenal clamping time, several temporary perfusion methods are available. Commonly used methods in thoracoabdominal aortic surgery encompassing visceral segment of aorta, are left heart bypass or cardiopulmonary bypass with selective organ perfusion (Aftab and Coselli 2014, Waked and Schepens 2018). However, selective renal perfusion via cannulation does not appear superior to cold perfusion in thoracoabdominal aortic surgery (Köksoy *et al* 2002). Temporary arterial shunts, such as axillo-femoral bypass, are more commonly used in case of kidney transplants to maintain physiologic pulsatile perfusion. Several small series and case reports are published introducing different temporary shunts to minimise renal ischaemia

time and to maintain physiologic perfusion as the safest option. Sidhu reported on 15 aorto-iliac reconstructions where temporary bypass was used in 10 patients, cold renal perfusion in two and no protection in three cases. The only transplant loss occurred in the no-protection group with subsequent mortality, and only one patient suffered temporary renal transplant dysfunction in bypass group. (Sidhu *et al* 2003.) Monnot found no allograft dysfunction in a series of three patients and preferred this method due to low cost, minimal amount of heparin needed and physiologic renal perfusion (Monnot *et al* 2015).

AIMS OF THE STUDY

The overall purpose of the study was to investigate the aspects of treatment of aortic infections involving biological grafts on the abdominal level and to evaluate a novel method of renal protection during complicated abdominal aortic surgery.

The specific aims were:

1. To evaluate the postoperative mortality and morbidity as well as long-term overall mortality after treatment of abdominal aortic infections with biological grafts (I–III).
2. To study the long-term infection resistance of biological grafts after treatment of abdominal aortic infections (I–III).
3. To study the midterm graft-related morbidity and mortality after biological conduit reconstructions due to abdominal aortic infections (I–III).
4. To evaluate the efficacy of temporary axillo-renal bypass to prevent AKI in major aortic surgery. (IV)

MATERIALS AND METHODS

1 PATIENTS AND DATA ANALYSIS

All studies were retrospective by nature, and data on patients was collected from hospital database and HUSVASC register in Helsinki, Finland. Studies I, II and IV were single-centre studies conducted at Helsinki University Hospital and Study III was a multicentre collaboration. For the multicentre Study (III), retrospective data was acquired from hospital records in France, Italy, Switzerland, Denmark and Finland. In addition, Sweden provided data from prospective national SWEDVASC register. Causes of death were retrieved from Statistics Finland. The demographics and comorbidities of study patients are listed in Table 4. Additionally, perioperative details were collected, and known postoperative complications recorded.

Table 4. *Preoperative characteristics of patients*

| | Study I | Study II | Study III | Study IV |
|------------------------------------|----------------|-----------------|------------------|-----------------|
| Number of patients | 55 | 23 | 56 | 16 |
| Male (%) | 42 (76) | 15 (65) | 46 (82) | 13 (81) |
| Age, median (range) | 66 (51-82) | 69 (24-87) | 69 (35-85) | 68 (31-80) |
| Hypertension (%) | 40 (73) | 20 (87) | 44 (79) | 11 (69) |
| Coronary heart disease (%) | 20 (36) | 10 (43) | 17 (30) | 5 (31) |
| Diabetes (%) | 23 (42) | 9 (39) | 16 (29) | 2 (13) |
| COPD (%) | 6 (11) | 9 (39) | 12 (21) | N/A |
| Cerebrovascular disease (%) | N/A | 6 (26) | 5 (9) | 3 (19) |
| Renal insufficiency (%) | 2 (4) | 5 (22) | 9 (16) | 9 (56) |
| Cardiac insufficiency (%) | N/A | 3 (13) | N/A | N/A |
| Immunocompromised (%) | N/A | N/A | 16 (29) | N/A |
| Smoking (%) | 23 (42) | 11 (48) | 31 (60) | 3 (19) |

COPD, chronic obstructive pulmonary disease; N/A, not available

Diagnoses of AGI and MAAA were based on clinical symptoms (fever, abdominal/back pain, graft-cutaneous fistulas, GI-bleeding, concomitant infection), characteristic findings in at least one imaging modality, elevated inflammatory markers in laboratory analysis,

and positive bacterial cultures from blood and/or intraoperative samples. Characteristic findings in CT or MRI included a perigraft abscess, air, pseudoaneurysm or AEF/AEE in case of an AGI; a saccular, multi-lobular, eccentric and rapidly growing aneurysm, periaortic soft tissue mass and gas for a MAAA. All suspicions were confirmed intraoperatively: AGI as the presence of infective fluid around the graft, as the graft being totally unincorporated to the surrounding tissues or as the presence of AEE/AEF; and MAAA as pus and infection in aneurysm sac and surrounding tissues. Reinfection was defined as graft infection, graft rupture with sepsis, graft-enteric/aorto-enteric fistula, or a recurrent MAAA.

The primary endpoints were 30-day mortality, overall treatment-related mortality, and reinfection rate. The secondary endpoints were long-term survival and graft-related morbidity (I–III). The impact of major aortic surgery on renal function was evaluated by means of the postoperative incidence of AKI and the outcome measures were 30-day renal function and mortality (IV).

I

All consecutive patients treated at HUH with aortic, aortobi-iliac or aortobifemoral graft resection and in situ FV reconstruction due to an AGI between October 2000 and March 2013 were included in the study. Patients were identified from the hospital database by scrutinising all hospital admissions and outpatient clinic visits due to a postoperative infection or wound infection and from prospective HUSVASC register by identifying all patients operated on due to graft complications. Patients treated conservatively or by other operative means were excluded.

Data from included 55 patients were collected from an electronic database and manually from patients' charts. A two-team surgical approach was used: while one exposed infected graft, the other bilaterally harvested femoral veins from popliteal fossa to common femoral vein confluence. Side branches were doubly ligated, and, after graft eversion, valves were excised. After re-eversion, two grafts were sewn together into "pantaloon" configuration. After debridement, new aortic anastomosis was reinforced with autologous *tensior fascia latae* and graft covered with omentoplasty if possible. Femoral anastomoses were covered with sartorius myoplasty and intestinal defect, when present, reconstructed by a gastric surgeon. Postoperatively low-molecular-weight-heparin (LMWH) and aspirin were administered, and intermittent pneumatic pumps used. Antibiotic treatment was prescribed by infectious disease specialist.

Patients were evaluated clinically one month after hospital discharge and radiologically 6–12 months after discharge in order to assess graft patency and perigraft conditions. Synchronously laboratory tests were followed at the outpatient clinic of infectious diseases with possible adjustments to the antimicrobial medication and its duration. After one year, the follow-up was organised individually at the patient's local hospital, with the intention of organising one radiological examination per year.

II

The study included patients who received cryopreserved large calibre venous allografts (CVA) (great saphenous veins excluded) for an arterial infection in suprainguinal area between February 2012 and March 2018. Patients were identified from the register of HUH Children's Hospital Homograft Bank. Twenty-three patients treated with venous allografts were included in the study, whereas patients treated with arterial allografts for the same indications were reported separately in the Supplement (n=8). Reconstruction with femoral veins was performed in 21 (91%) patients, while 2 (9%) received vena cava grafts. Data on patients were retrieved from an electronic database.

The HUH Homograft Bank cryopreserves vessels harvested from multiorgan donors by certified vascular surgeons. The freezing is temperature-controlled, and vessels are stored in nitrogen vapour at -180°C for up to 5 years. Thawing occurs in 37°C water bath for 30 minutes followed by cryoprotectant washout.

At the implantation, the grafts side branches were doubly ligated and valves excised prior to the creation of the "pantaloon" or another graft configuration. Infected vessel or prosthetic graft was excised, area debrided, and new aortic anastomosis reinforced with *fascia latae*. Distal anastomoses were tension-free, but without reinforcement. Intracavitary grafts were covered with omentoplasty when possible and sartorius myoplasty was used in the groins. Postoperatively aspirin and LMWH were administered and antibiotics prescribed by an infectious diseases' specialist.

A clinical follow-up was organised one month after discharge, with radiological studies at 6 months and one year. Thereafter annual radiological follow-up with CT or MRA for intracavitary grafts and triplex-ultrasound for extracavitary grafts, was recommended either at HUH or in a local hospital. The duration of antibiotic treatment was determined by an infectious diseases' specialist based on haematological tests as well as the clinical status and radiological studies.

III

All consecutive patients treated for abdominal or iliac mycotic aortic aneurysms in collaborating centres from January 2006 to December 2016 were identified. Electronic hospital databases were scrutinised in addition to the prospective registers of HUSVASC in Finland and SWEDVASC in Sweden. Fifty-six patients treated by means of biological in situ reconstruction were included in the study. The grafts used were: autologous FVs (n=30; 54%), cryopreserved arterial (n=7; 12%) or venous allografts (n=2; 4%), fresh allografts (n=5; 9%) or self-made XPTs (n=12; 21%). Patients treated with EVAR, prosthetic in-line reconstruction or AXBF were excluded as were patients who underwent biological reconstruction after an emergency bridge procedure with EVAR. Due to retrospective nature, the follow-up was not homogenised, but was rather individually designed by each collaborating centre.

IV

All major aortic surgery form catchment area of 2 million people, as well as oncovascular cases including aorta, vena cava or visceral vessels from all of Finland, are performed at HUUH. In less than 2% of these cases have we needed efficient renal protection due to potentially long suprarenal cross-clamping time or impaired renal function. Therefore, we have used extracorporeal axillo-renal bypass for temporary renal arterial perfusion in selected cases with following indications: preoperative renal insufficiency, one functioning kidney, renal transplant or expected long suprarenal clamping time due to scar tissue, a congenital tissue defect, concomitant renal artery stenosis or other anatomical challenge.

Between October 2007 and May 2012, sixteen patients underwent temporary axillo-renal bypass during suprarenal aortic clamping. Two-team approach was used with one team preparing the axillar prosthetic inflow-graft with necessary amount of outflow branches, while other team dissected visceral aorta and renal vessels. Prior to aortic clamping, an end-to-end anastomosis between the renal artery and prosthesis was made for one renal artery requiring perfusion. If both were perfused, Y-shaped prosthetic graft limbs were first anastomosed one renal artery at the time prior to aortic clamping (Figure 5). Renal perfusion was confirmed with flowmetry. After aortic reconstruction, temporary graft was truncated and implanted into the aortic prosthesis. Axillar stump was oversewn.

Postoperatively, SCr and urine output were measured, and acute renal failure evaluated based on RIFLE (Risk, Injury, Failure, Loss of renal function, End stage renal disease) criteria. At 30-day clinical follow-up SCr and estimated GFR were determined.

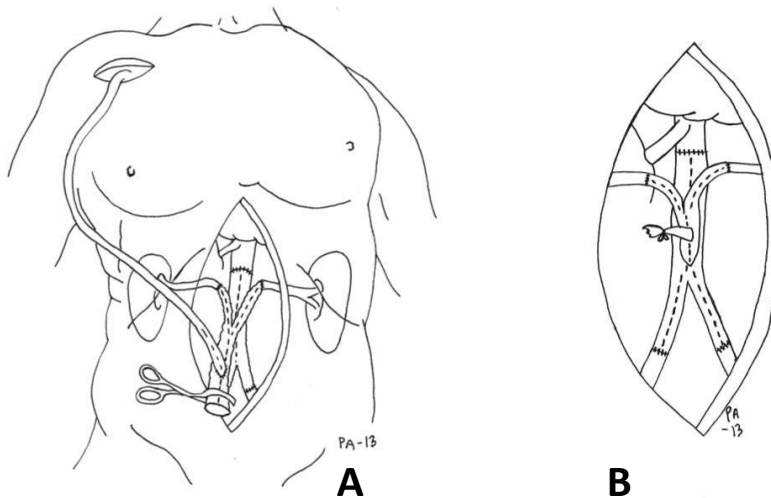


Figure 5 Temporary axillo-birenal bypass during aortic surgery (A) and after truncation (B).³

2 STATISTICAL ANALYSIS

For statistical analysis SPSS packages 19.0 (SPSS Inc, College Station, TX, USA) (I, IV) and 22 (IBM, Armonk, NY, USA) (II, III) were used. Continuous variables are expressed as median (range) and categorical variables as proportions (%). Univariable analysis was performed to analyse the associations of risk factors (age, comorbidities and operative details) with early, treatment-related and overall mortality using the chi-squared test and unadjusted proportional hazards model (I), Fisher's exact test (II, III), and the Kruskal-Wallis test (II). Binary logistic regression was applied to determine risk factors associated with treatment-related mortality (III, IV) or postoperative renal failure (IV). The multivariable Cox regression analysis for overall survival (I, III) and graft thrombosis (II) were performed. The survival was calculated with Kaplan-Meier method (I–III). All statistical tests were two-tailed, and $p < 0.05$ was considered statistically significant.

³ Heinola I, Halmesmäki K, Kantonen I, Vikatmaa P, Aho P, Lepäntalo M, Venermo M. Temporary Axillorenal Bypass in Complex Aorto-Renal Surgery. *Ann Vasc Surg.* 2016 Feb;31:239-45. With permission by ELSEVIER Inc.

RESULTS

1 EARLY MORBIDITY AND MORTALITY AFTER BIOLOGICAL AORTIC RECONSTRUCTIONS DUE TO ABDOMINAL AORTIC INFECTIONS (I, II, III)

During the early postoperative period 35% (46/132) of the patients needed a reoperation: this involved 36% of the AGI patients treated with FVs (I), 43% of patients whose aortic infection was treated with cryopreserved allografts (II) and 29% of patients with a MAAA treated with biological grafts (III). The most common indications for the operation were lower limb ischaemia and GI complications including bowel necrosis and intestinal leakage after AEF repair. Non-surgical complications occurred in 26% (34/132) of the cases, constituting; 20%, 39% and 25% in Studies I, II, III, respectively, with renal dysfunction being the most prevalent (13%–19%). A total of 17 (13%) patients required renal replacement therapy and 3 (2%) of them permanently. Two FV grafts and one cryopreserved vein graft ruptured –one FV due to size mismatch and tension in the proximal anastomosis, other FV and CVA due to reinfection. Operative details and postoperative complications are listed in Table 5.

The 30-day mortality was 9% for patients treated with FV for an AGI (I); 9% for patients treated with cryopreserved allografts for mixed indications (II); and 5% for patients who received mixed reconstruction materials due to a MAAA (III). None of the deaths were directly graft-related but were rather disease-related and due to postoperative complications. The 30-day and in-hospital mortality rates in patients treated due to AEF were 10% and 20%, respectively, compared to the respective 9% and 10% in patients treated due to non-AEF-related AGI; the respective 5% and 8% in patients operated on for a MAAA.

Table 5. Perioperative details, postoperative complications (grey background) and 30-day mortality after in situ biological reconstruction due to aorto-iliac infections.

| Variable, n (%) | Study I | Study II | Study III |
|--------------------------------------|--------------|--------------|--------------|
| Number of patients | 55 | 23 | 56 |
| Intracavitary rec | 15 (27) | 7 (30) | 56 (100) |
| Intra- and extracavitary rec | 40 (73) | 11 (48) | - |
| Extracavitary rec | - | 4 (17) | - |
| Concomitant vasc rec / other | 4/9 (7/16) | 8/4 (35/17) | 13/3 (23/5) |
| AEF and AEE | 8 (33) | 2 (9) | - |
| Rupture | 1 (2) | 5 (22) | 12 (21) |
| Reoperations due to graft rupture | 2 (4) | 1 (4) | - |
| Other bleeding | - | 2 (9) | 6 (11) |
| Ischaemia / graft thrombosis | 8/4 (15/7) | 1/- (4/-) | 2/- (4/-) |
| GI complication | 6 (11) | 3 (13) | 4 (7) |
| Amputation, primary op / reoperation | 1/3 (2/5) | - | -/1 (-/2) |
| Renal dysfunction | 9 (16) | 3 (13) | 9 (16) |
| RRT, temporary / permanent | 5/- (9/-) | 2/1 (9/4) | 7/2 (13/4) |
| Cardiac complications | 6 (11) | 2 (9) | 2 (4) |
| Stroke | 1 (2) | 1 (4) | 1 (2) |
| Early graft reinfection | 1(2) | 1 (4) | - |
| 30-day mortality | 5 (9) | 2 (9) | 3 (5) |

Rec, reconstruction; vasc, vascular; AEF, aorto-enteral fistula; AEE, aorto-enteral erosion; GI, gastrointestinal; op, operation; RRT, renal replacement therapy

2 INFECTION RESISTANCE OF BIOLOGICAL GRAFTS (I, II, III)

Bacterial cultures from tissue or blood were positive in 74% (n=98/132) of all cases – 71%, 70% and 77% in Studies I, II and III, respectively. The most commonly isolated bacteria were Staphylococcal strains in all series; however, virulent *Staphylococcus aureus* was predominant in cohorts operated on due to a MAAA (III) or mixed infectious

indications (II). Coagulase-negative staphylococci were the most prevalent among patients treated with FV for an AGI, closely followed by *Staph. aureus* (I). Polymicrobial growth was detected in 19% (n=25/132) of all cases; with 33%, 17% and 7% in Studies I, II and III, respectively, being most common among patients treated for AGI and AEF. The most frequently isolated bacteria are listed in Table 6.

Table 6. *Isolated microorganisms*

| | Study I | Study II | Study III |
|--|---------|----------|-----------|
| Positive microbial growth, n (%) | 39 (71) | 16 (70) | 43 (77) |
| Polymicrobial growth, n (%) | 18 (33) | 4 (17) | 4 (7) |
| Monomicrobial growth, n (%) | 21 (38) | 12 (52) | 39 (70) |
| <i>Coagulase-neg Staphylococcus spp</i> | 10 | 2 | - |
| <i>Staphylococcus aureus / MRSA</i> | 6/1 | 5/- | 15/3 |
| <i>Streptococcus spp</i> | 5 | 3 | 7 |
| <i>Escherichia coli</i> | 3 | 3 | 5 |
| <i>Candida spp</i> | 5 | 1 | 2 |
| <i>Salmonella spp</i> | - | - | 10 |
| <i>Pseudomonas aeruginosa</i> | 4 | 2 | - |
| <i>Enterobacteriaceae spp</i> | 4 | 1 | - |
| <i>Bacteroides fragilis</i> | 4 | - | 1 |
| <i>Enterococcus spp</i> | 2 | 1 | - |
| <i>Staphylococcus lugdunensis</i> | - | 2 | - |
| <i>Prevotella</i> | 1 | 2 | - |
| <i>Lactobacillus</i> | 3 | - | - |
| <i>Klebsiella</i> | 2 | - | - |
| <i>Campylobacterium spp</i> | - | - | 2 |

As mentioned before, two graft reinfections appeared during the early postoperative period, and one during the later phase, constituting a reinfection rate of 2% (3/132) among all biological reconstructions. One FV reconstruction became reinfected in a constantly septic patient, who was primarily treated with EVAR for a MAAA. He

developed an early AEF with concomitant discitis and was therefore treated with endovascular graft explant and in-line reconstruction. He had dispersed intestinal necrosis and peritonitis while his FV graft ruptured due to reinfection. Despite a successful reoperation, he died on the 37-th postoperative day due to mesenteric ischaemia. Second early graft reinfection occurred after aortobifemoral CVA rupture reconstructed due to a late AGI. The patient underwent a graft limb re-reconstruction with a new CVA due to graft contamination with *Candida*. However, re-ruptures appeared in different parts of the graft and patient required re-reconstructions until antifungal medication eliminated bloodborne spread after which the grafts remained intact. Third reinfection appeared two years after an aortobifemoral FV reconstruction due to an AEF. Recurrent AEF developed and was treated with palliative EVAR due to patient's poor general condition. The patient died of a GI haemorrhage three months later. No reinfections emerged among patients treated for MAAA.

Isolated strains and susceptibility determined the antibiotic therapy when available. In case of negative cultures, antimicrobial therapy was broad-spectrum. The duration depended on the virulence of isolated strains, severity of the infection and postoperative course. The median duration was 12 weeks (range 3–85 weeks) in a cohort treated for mixed suprainguinal arterial infections (II) and 8.5 weeks (range 1–35 weeks) among patients treated for MAAA (III). None of these patients needed life-long medication. The median duration of antimicrobial therapy was not evaluated among patients treated with FV for AGI; however, the suppression was necessary for two patients as a consequence of partial graft preservation (I).

3 LATE GRAFT-RELATED MORBIDITY AND OVERALL MORTALITY (I, II, III)

In addition to reinfections, stenotic complications and occlusions, anastomotic dilatation and pseudoaneurysms occurred causing graft morbidity. During the follow-up period, 14/132 patients required graft reinterventions, with stenosis as the most frequent indications. (see all details in Table 7) Stenotic complications appeared only in autologous FV grafts (n=9), two of which occluded. Third occlusion occurred without underlying stenosis (n=10/85 FVs; 12%). Reinterventions were performed for symptomatic or hemodynamically significant stenosis found in follow-up studies. Percutaneous transluminal angioplasty (PTA) was sufficient in all cases, with the

exception of one that required thrombectomy. One graft occluded after several angioplasties and was diverted with femoro-femoral crossover bypass. One graft limb occluded silently after initial angioplasty as a result of a common femoral artery occlusion. Few months later, ipsilateral native iliac arteries were recanalized during a hybrid procedure for critical limb ischaemia, possible due to previous end-to-side upper anastomosis. One anastomotic pseudoaneurysm among FV graft recipients was stented and another operated on, but latter patient died due to postoperative pulmonary embolism (I, III).

None of the seven cryopreserved arterial allografts showed any complications in treatment of MAAAs (III). Among the cryopreserved venous allografts, one aneurysmatic anastomotic dilatation was operated on with prosthetic interposition and one pseudoaneurysm stented percutaneously (n=2/23 CVAs; 9%). No association between graft complications and ABO-incompatibility existed (p=0.743) (II).

Table 7. Long-term graft-related morbidity (grey background) and mortality.

| | Study I | Study II | Study III |
|--|-------------|-----------|---------------|
| Number of patients | 55 | 23 | 56 |
| Follow-up months, median (range) | 32 (1–157) | 15 (3–62) | 26 (3w–172mo) |
| Graft occlusions, n (%) | 2 (4) | - | 1 (2) |
| Graft stenosis, n (%) | 7 (13) | - | 2 (4) |
| Anastomotic | | | |
| aneurysm/pseudoaneurysm, n (%) | 2 (4) | 2 (9) | - |
| Graft patency, primary/secondary | 84% / 96% | 100%/100% | 95%/100% |
| Freedom from graft reinterventions | 78% 5 y | 87% 2 y | 95% 5 y |
| Treatment-related mortality, n (%) | 10 (18) | 3 (13) | 5 (9) |
| Overall mortality during follow-up, n (%) | 22 (40) | 6 (26) | 11 (20) |
| Kaplan-Meier survival for 1 year | 82% | 76% | 83% |
| (95% confidence interval) | (71%–92%) | (57%–95%) | (73%–94%) |
| Kaplan-Meier survival for 2 years | 76% | 70% | 81% |
| (95% confidence interval) | (65%–88%) | (49%–91%) | (70%–92%) |
| Kaplan-Meier survival for 5 years | 59% | - | 71% |
| (95% confidence interval) | (43% - 73%) | | (52% - 89%) |

There were no graft-related complications among patients treated with self-made bovine pericardium tube grafts (n=12) and fresh arterial allografts (n=5) (III). At the end of follow-up, all but two femoral vein grafts remained patent, and only one patient underwent amputation as a result of critical limb ischaemia with a patent aortic graft.

The overall treatment-related mortality during the study period was 18% after treatment of AGIs with FVs (I), 9% after treatment of MAAAs with biological graft (II) and 9% after treatment of mixed infections with CVAs (III). The Kaplan-Meier estimate for 5-year survival in the studies I and III was 59% and 71%, respectively; due to a small number of patients, only 2-year Kaplan-Meier survival estimate was calculated in Study II (Table 7, Figure 6).

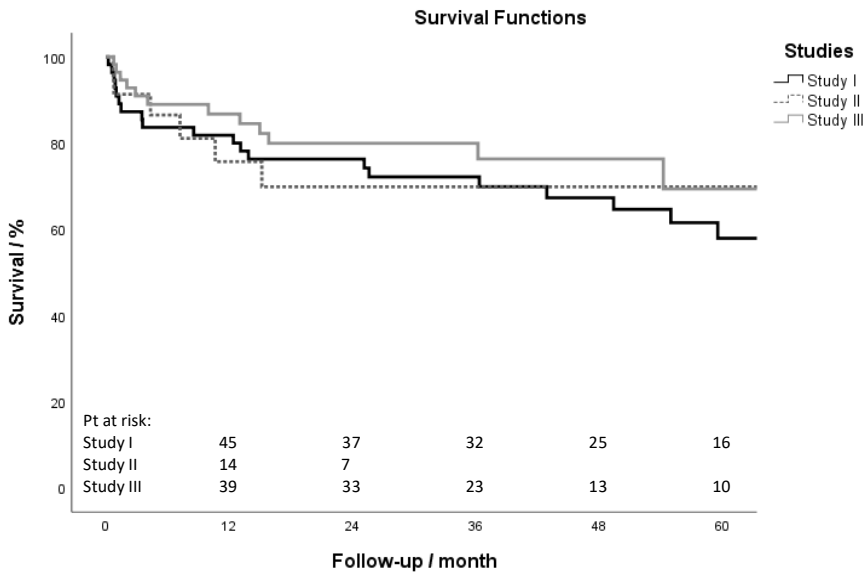


Figure 6 Kaplan-Meier curve demonstrating the overall survival for patients treated with autologous veins due to an aortic graft infection (Study I); with cryopreserved venous allografts due to various suprainguinal arterial infections (Study II); and with different biological materials for a mycotic abdominal aortic aneurysm (Study III).

For patients treated due to MAAA, univariate analysis revealed need for renal protection during suprarenal clamping (p=0.15), duration of the operation (p=0.046) and CRP at the time of diagnosis (p=0.049) as predictive factors for treatment-related mortality. Smoking (p=0.034) was associated with higher total mortality, and a negative bacterial culture (p=0.026) was associated with lower mortality. In multivariable analysis, smoking (hazard ratio [HR] 10.1; 95% CI, 1.09–92.96; p=0.042) and CRP level at diagnosis (HR 1.1 for

every 10 units; 95% CI, 1.02–1.15; $p=0.013$) were associated with all-cause mortality (III).

For patients treated with CVA for suprainguinal arterial infection, heart failure was associated with all-cause mortality based on the univariable analysis ($p=0.019$) (II).

In AGI cohort treated with autologous veins no statistical association appeared with mortality (I).

4 PREVENTION OF AKI WITH TEMPORARY AXILLO-RENAL BYPASS (IV)

The most common indication for surgery was juxta- or suprarenal aneurysm ($n=11/16$, 69%; see details and results in Table 8). Preoperative renal function was normal in 44% ($n=7/16$) of the patients and moderately impaired in 56% ($n=9/16$). Temporary bypass was reconstructed for a single kidney in 7 (44%) cases and bilaterally in 9 (56%) cases. The median operation time was 393 minutes and the median cumulative renal ischaemia time was 24.5 minutes. Despite considerably safe renal ischaemia time, kidney function deteriorated in six (38%) patients, and two (12.5%) suffered temporary renal failure, one of which required RRT for five days. However, all patients survived the postoperative period, and renal function had stabilised to preoperative level or improved in all cases at the 30-day follow-up. Statistical analysis revealed no significant factors associated with postoperative kidney injury.

The axillar dissection area caused no extra morbidity and healed *per primum* in all cases.

Table 8. Patients who underwent temporary axillorenal bypass and postoperative measures

| Age/ Sex | Indication | Renal clamp time (min) | Preop SCr/ eGFR | Postop SCr/Uop | RIFLE | Follow-up SCr/ eGFR |
|-------------|--|---------------------------------|-----------------------|------------------------|---------|------------------------|
| 58/F | Intra-abdominal myofibroblastic tumour, recidive | 8 | 67/82 | 80/2,110 | | 58/95 |
| 71/M | RA stenosis (kidney transplant), AAA, CIAA, IIAA (transplant side) | 26 | 146/47 | 142/1,930 | | 94/71 |
| 60/M | Suprarenal AAA. Renal tumour on the right side. | 16 | 202/40 | 227/2,080 | | 141/60 |
| 58/F | Aortic occlusion with claudication. Takayasu arteritis. | 24 | 80/104 | 88/1,280 | | 52/161 |
| 62/M | Bilateral CLI. Infrarenal AAA, RA stenosis (kidney transplant) | 29 | 75/79 | 112/2,245 | | 77/77 |
| 71/M | Bilateral renal artery stenosis. Infrarenal AAA. Suprarenal AAA. Thoracic and infrarenal aorta | 16 | 111/59 | 103/1,250 | | 74/88 |
| 76/M | previously reconstructed. | 25 | 81/76 | 86/2,120 | | 85/76 |
| 66/M | Suprarenal AAA | 15 | 132/61 | 177/1,080 | | 112/71 |
| 73/M | Suprarenal AAA. Infrarenal aorta previously reconstructed. | 20 | 126/63 | 127/ 820 | Injury | 110/73 |
| 74/M | Juxtarenal AAA. RA stenosis (single functioning kidney) | 50 | 171/36 | 249 /1,475 | Risk | 186/33 |
| 47/M | Suprarenal AAA, bilateral CIAAs. Marfan's syndrome. Status post B type dissection. | 29 | 78/132 | 83/1,443 | | 82/125 |
| 74/M | Suprarenal AAA | 24 | 160/39 | 148/ 565 RRT | Failure | 100/62 |
| 58/M | Suprarenal AAA | 39 | 93/101 | 184 /1,695 | Risk | 136/69 |
| 80/M | Suprarenal AAA contained rupture. Pelvic kidney. | 32 | 52/106 | 116/ 269 | Failure | 70/79 |
| 70/F | Suprarenal AAA | 36 | 110/60 | 101/915 | | 73/91 |
| 31/M | Symptomatic suprarenal AAA. Marfan's syndrome. | 17 | 101/125 | 188 /1,515 | Injury | N/A |

AAA, abdominal aortic aneurysm; CIAA, common iliac artery aneurysm; CLI, critical limb ischaemia; F, female; eGFR, estimated glomerular filtration rate; IIAA, internal iliac artery aneurysm; M, male; N/A, not available; RA, renal artery; SCr, serum creatinine ($\mu\text{mol/l}$); Uop, urine output (ml). Bold figures highlight the results that defined RIFLE category.

DISCUSSION

1 LIMITATIONS OF THE STUDY

The main limitation of the study is the lack of comparison between biological reconstructions and other treatment methods used for aorto-iliac infections. Herein, the entity of aortic infections comprises of AGIs and MAAAs, which are different in etiology, pathophysiology and bacteriology and a prospective comparative study should therefore be implemented separately for both to provide high-quality results. However, due to low incidence of these conditions per institution, a vast multicentre collaboration is needed, which, in turn, hampers the organisation of uniform management and the homogenisation of the follow-up. Patients with advanced age, severe systemic diseases and a variety of complications due to aortic infections are extremely difficult to randomise, making recruitment slow and ineffective. Gaining high-quality results from such demanding setting would take an extremely long time and, entails the risk of the treatment methods under comparison becoming obsolete. In case of Study III, only a handful of patients with MAAA were treated with other methods besides in situ biological grafts at the other collaborating centres except in Sweden. During the study period 70 EVAR implants out of 80 (88%) were performed in Sweden due to MAAA, as well as 41 in situ prosthetic reconstructions out of 51 (80%). The results of these SWEDVASC patients treated with EVAR or in situ prosthetic grafts during a time span of 8 years overlapping with Study III were published by Sörelius and are therefore considered somewhat comparable (Sörelius *et al* 2016).

The retrospective nature of the study also contains the risk of case selection and selection bias. Reliable data on patients treated conservatively (II, III) did not exist, or patients treated with suprarenal clamping and without a renal protection method were not extracted (IV). However, in Study I, all 73 patients treated for AGI during the selected time period were revised, and 18 were excluded from the study. Nine out of 18 patients were treated conservatively due to poor general condition or a localised, nearly asymptomatic infection. In seven cases, local debridement was performed due to the patient's advanced age and comorbidities, while one patient was treated with prosthetic in-line reconstruction due to haemorrhagic shock and one reconstruction was performed with fresh allografts due to the patient's refusal of FV harvesting.

In addition, the retrospective nature of the study makes it impossible to acquire missing data, such as hospital stay in a local facility (I–III) or results of missing laboratory analysis (IV) and to standardise follow-up protocols (III).

In Study IV the follow-up comprised only early postoperative period, and, therefore, the associations of postoperative AKI and development of CKD with risk of higher long-term mortality cannot be determined.

The relatively small number of patients in all studies set limitations to the statistical analysis and compromises the results.

2 REINFECTIONS AND INFECTION RESISTANCE

Biological-material is not as susceptible to bacteria as prosthetic material. Total endothelial coverage of FV grafts and scattered coverage of cryopreserved allografts protects them from bacterial attachment. Furthermore, nutrients, oxygen and antibiotics are capable of diffusing into the vessel wall and through it to the perigraft tissue. (Moore *et al* 1980, Kieffer *et al* 2004.) Three reinfections occurred during the current study; two grafts became reinfected after treatment for an AEF, and one *Candida*-colonized cryopreserved allograft ruptured due to a reinfection (I, II).

An invasion of *Candida* into the bloodstream after endothelial adhesion is difficult to treat. Adhesion depends on the virulence factors present, but predilection to abnormal intima may place allografts at risk (Mai *et al* 2006, Sanchez *et al* 2004). *Candida* is part of intestinal microflora and can be transferred via AEF, or the colonisation can be a result of a recipient-borne complication due to antimicrobial suppression and diminished host resistance. *Candida* has been associated with higher early mortality and has been speculated to be associated with graft rupture (Vogt *et al* 2002, Matsuura *et al* 2002, Ali *et al* 2009, Lejay *et al* 2017). Therefore, a high suspicion of concomitant fungal infection in patients on prolonged antibiotic medication, and involvement of multi-disciplinary team in the management of these complex patients are mandatory to improve the outcome (Ali *et al* 2009, Lyons *et al* 2016, Lejay *et al* 2017).

Two other patients who suffered FV reinfection after the treatment of AEF, had polymicrobial intestinal flora in bacterial cultures and required extensive aortobifemoral reconstructions. One on them was already in severe sepsis after primary endovascular stenting of a MAAA and did not recover even after conversion to in situ reconstruction with FVs. *Candida*, and virulent gram-negative bacteria as predictive factor for graft

complications, were cultured from the graft (Harlander-Locke *et al* 2014, Lejay *et al* 2017). The other patient had rather mild symptoms, but suffered Candida-induced sepsis prior to AGI diagnosis, possibly indicating an immunocompromised state (I).

However, the reinfection rate of 2% remains extremely low, and shows better infection resistance in comparison prosthetic reconstructions without strict preselection. Söreljus reported reinfection rate of 18% after prosthetic in situ reconstructions for mycotic aortic aneurysms and of up to 27% after EVAR (Söreljus *et al* 2014 and 2016). A reinfection rate of 11% has been reported after in situ prosthetic repair for AGI. Among selected patients with low-grade infection and no gross purulence, it can be diminished to 4% .(Batt *et al* 2003, Oderich *et al* 2006 and 2011.)

Other series have reported reinfections in 0%–5% of patients after aortic reconstructions with CAAs and FVs (Daenans *et al* 2003, Ali *et al* 2009, Harlander-Locke *et al* 2014, Touma *et al* 2014, Ahmed *et al* 2017). Until recently, no infectious complications had occurred among XPT recipients, but the latest paper by Lutz reported 2 ruptures due to reinfections in a cohort of 13 patients (Czerny *et al* 2011, Weiss *et al* 2017, Lutz *et al* 2017). No reinfections emerged among XPT recipients in the current cohort, but despite the infection resistance, data on graft durability is lacking and considered approach is therefore recommended until further research (III).

3 GRAFT DURABILITY

The synthetic materials of prosthetic grafts are resistant to breaking and degradation despite robust handling or bacterial presence. Furthermore, large diameter warrants patency, resulting in extremely low amputation rates (Batt *et al* 2003, Oderich *et al* 2011, Frei *et al* 2011). Biological grafts, however, react to handling and implantation with several mechanisms. Autologous FVs are immunologically excellent, but patency is altered by stenotic lesions. Intimal hyperplasia and remodelling, as well as chronic inflammatory endothelial cell activation caused by elevated shear stress in arterial position, may result in stenotic lesions similar to graft stenosis in lower-limb saphenous vein bypasses (Ward *et al* 2017). Heavy smoking, graft diameter of < 7.2 mm and clinically significant coronary artery disease seem to be associated with stenotic complications. The relative risk of stenosis is doubled with every one-millimetre decrease in graft diameter. Moreover, smaller grafts present with stenotic complications in earlier phase. (Beck *et al* 2008.) In current study, FVs of > 6mm were accepted as reconstruction

material, and the smaller diameter may therefore have contributed to the 10.6% incidence of stenotic complications among FV recipients in current cohort compared to 8.3% in cohort reported by Beck (I, III) (Beck *et al* 2008).

The durability of cryopreserved grafts has improved with advanced cryopreservation techniques, but the amount of graft-related non-infectious complications ranges from 5%–55% (Vogt *et al* 2002, Bisdas *et al* 2010, Harlander-Locke *et al* 2014, Heo *et al* 2017, Lejay *et al* 2017). Cryopreservation modifies the antigenicity of vascular grafts, but some degree of recipients' cellular and humoral response still exists (Mirelli *et al* 2005). Immunogenicity is affected by HLA complexes presented by endothelial cells and SMCs, which cryopreservation methods aim to preserve for better patency (Rendal *et al* 2004). Freezing and thawing still cause some degree of endothelial denudation, furthermore, they carry a risk of elastic fibre fragmentation and loss of wall tensile strength. Therefore, freezing process must be temperature-controlled and thawing slow. (Pegg *et al* 1996, Müller-Schweinitzer 2009.) The SMC layer is thicker in arteries and the immunologic response is thus thought to be more potent compared to veins. After a few thrombotic complications of arterial allografts (II, supplement) and some atherosclerotic degenerations of peripheral grafts (unpublished data), cryopreserved venous allografts became the preferred reconstruction material at HUH. Vein calibre is larger due to thin vessel wall, and, therefore, "pantaloon"-grafts reconstructed from two femoral vein allografts offer a more suitable diameter for aortic anastomosis, than grafts created out of two femoral arteries. Another contributing factor could be lack of endothelium, and therefore, fewer antigen-presenting cells and lesser immunological reaction (Aavik *et al* 2008). We have studied cryopreserved venous allografts prior to implantation and found no luminal endothelium present. Despite a denuded luminal surface, large calibre and large flow volume maintained graft patency of all venous allografts in current study (II). However, one anastomotic aneurysmal dilatation and one pseudoaneurysm call for further research in cryopreservation techniques and graft handling to avoid elastic fibre fragmentation. Furthermore, to secure a proximal anastomosis, thin valve pockets should be excised and circumferential outer support with *fascia latae* used. With this technique, no proximal anastomotic complications appeared. Moreover, reinforcement of distal anastomosis in the future should be considered, since two distal dilatations developed in current study. (II)

The durability of fresh allografts is inferior to that of cryopreserved allografts, and caution is warranted despite the excellent performance in the current cohort (III) (Kieffer *et al* 2004).

4 MORTALITY

Aortic infection is physiologically exhausting and requires extensive surgery to achieve bacterial eradication and to cure the infection. Patients present with sepsis, acute limb ischaemia, AEFs, rupture and concomitant infections, and they are frequently immunocompromised and nutritionally depleted, making the risk of early mortality considerable. To minimise the risk of early and late mortality, patients have to be evaluated individually and managed with tailored treatment.

In situ reconstructions have outperformed the extra-anatomical bypass in every aspect (Batt *et al* 2018). AXBF has been recommended in case of an AGI with *Pseudomonas*, MRSA or multidrug-resistant pathogens, since metastatic microabscesses have been found in the proximal aorta of *Pseudomonas*-patients. However, the same reason raises the risk of stump blowout and subsequent mortality. (Geary *et al* 1990, Wilson *et al* 2016.) In current study, seven patients presented with *Pseudomonas* infection and one with MRSA. One of them died due to sepsis during the early postoperative period, but none developed infectious graft complications (I, II). In rare cases, MAAA patients presenting with concomitant discitis or psoas abscesses and constant sepsis, may benefit from extra-anatomical reconstruction (Wilson *et al* 2016).

In situ reconstructions with rifampicin-soaked prostheses, silver-prostheses and FVs carry similar early mortality rates of 10%–12%. Reconstructions with CAAs express a slightly higher mortality of 22%. However, biological grafts have the advantage in late survival. (Batt *et al* 2108, Smeds *et al* 2014.) In current study, the postoperative mortality was as low as 5% for patients treated for MAAA (III), 9% for patients treated for AGI (I) and 9% for patients treated for mixed infectious indications (II). Patients who undergo surgery due to an AGI have more severe atherosclerotic risk factors, have already been operated on due to atherosclerotic complications and may present with an AEF. AGI operations are performed in scar tissue, reconstructions are more extensive and technically more demanding than operations for MAAAs, which might explain the higher mortality among patients with AGI. Furthermore, there is possibility for case selection in Study II. Our preferred reconstruction material has been FV, but to diminish surgical trauma on very severely ill individuals, we have implanted cryopreserved allografts rather than FVs in case of fragile patients with severe comorbidities, making cryopreserved the allograft cohort the highest-risk group for complications and mortality.

The estimated 5-year survival of 71% in patients treated for MAAAs (III) is comparable to survival of patients treated for elective degenerative AAAs with open repair and EVAR

(75% and 67%, respectively) (Laine *et al* 2017). EVAR does not yield a significant advantage in early survival, compared to Study III, and the survival of 58% at 5 years remains inferior (Sörelis *et al* 2014). Therefore, for MAAA patients fit for open surgery, mycotic aneurysm resection and in situ reconstruction with biological material should be considered. If they are treated with EVAR, close surveillance and extremely low threshold for conversion is recommended.

Patients treated for AGI had a 5-year survival of 59% (I) and patients treated for mixed indications a survival of 70% at two years (II). Both cohorts included patients with AEFs, who are generally sicker, have polymicrobial infections and are often in need of an urgent operation due to sepsis, GI bleeding or graft limb thrombosis. In several series of AGIs, patients who died postoperatively are the ones with AEF. The early mortality varies from 8%–9% in some series to up to 43%–57% in others % (Ali *et al* 2009, Oderich *et al* 2011, Batt *et al* 2011). Oderich reported a 5-year survival of 59% after in situ rifampicin-soaked prosthetic reconstruction in a somewhat selected AEF cohort (Oderich *et al* 2011). However, without preselection, long-term survival remains significantly lower – 11%–18% (Ali *et al* 2009, Batt *et al* 2011). For 18 patients with an AEF in Study I, in-hospital mortality was 22% and 5-year mortality 44%. Both patients who developed reinfections in Study I initially presented with an AEF.

5 RENAL PROTECTION (IV)

Major aortic surgery encompassing visceral arteries poses a risk of postoperative renal dysfunction. Acute ischaemic kidney injury, a common complication in vascular surgery, is associated with higher postoperative and total mortality, as well as development of the CKD (Sailer *et al* 2016, Zarkovsky *et al* 2016). Therefore, any preventive method to diminish renal ischaemia time is justified.

A clamp-and-sew technique is accepted when anatomical challenges are not expected. However, when ischaemia is prolonged to over 25 minutes and patient has underlying renal dysfunction, protection should be considered (Yeung *et al* 2016, O'Donnell *et al* 2018). Cold renal perfusion is preferred due to availability and ease of use. Yeung reported a mean renal ischaemia time of 37 minutes to be safe with no postoperative AKI in elective setting (Yeung *et al* 2008). Nevertheless, the median ischaemia time of 24.5 minutes in current cohort led to AKI in six cases, indicating the possibility that in complex patients, development of AKI is hard to predict and depends on more factors than solely

ischaemia. When anatomical challenges propose the prolongation of clamping time, patient already has underlying renal disease or a kidney transplant, temporary bypass lowers the risk of renal damage providing physiological perfusion that can be confirmed perioperatively with flowmetry or triplex ultrasound. In case of renal transplant, we find axillary bypass directly to renal arteries, with subsequent shunt implantation to aortic prosthesis, a more elegant solution than temporary axillo-femoral bypass. End-to-end renal bypass provides pulsatile flow with adequate pressure, and subsequently created aorto-renal bypass protects the renal arteries from further extension of atherosclerotic disease. Furthermore, femoral cut-down predisposes to a higher risk of wound infection compared to proximal axillar incision (Szilagyi *et al* 1972). One might argue that additional bypasses prolonging the operation are unnecessary, if cold perfusion only takes minutes to start. However, if an additional surgeon is recruited, bypass can be reconstructed synchronically, and extra time is spent on visceral anastomosis only. Temporary bypass affords time to adopt a meticulous technique in creating the aortic anastomosis and allows additional manoeuvres when unexpected difficulties appear in case of complicated anatomy, tumour resection or congenital tissue defects. We aim to use cold perfusion in suprarenal reconstructions in patients without renal impairment. Nevertheless, due to renal artery ostial stenosis or, vice versa, large arteries with constant dislocation of catheters, we frequently end up using a clamp-and-sew technique, when temporary bypass is not indicated.

In addition to renal arteries, five superior mesenteric arteries were concomitantly shunted to minimize the global ischaemia-reperfusion insult. Mesenteric ischaemia lasting over 40 minutes is associated with vast inflammatory reaction and multiorgan failure (Hanssen *et al* 2008, Monnot *et al* 2016).

Since temporary bypass is used extremely rarely, patients at higher risk of complications and mortality were selected to current study. Despite the more gravely ill cohort, all 16 patients survived postoperative period. Moreover, in case of three patients, preoperative renal impairment was normalised.

6 FUTURE PROSPECTIVES

To diagnose abdominal aortic infections, one has to understand the criteria defining them. Protean manifestations and ambiguous results in laboratory tests and radiological studies require a consensus to differentiate between “not likely”, a suspicion and a confirmed diagnosis. The MAGIC collaboration defined diagnostic criteria for AGIs in

2016, but a similar document for MAAAs is lacking (Lyons *et al* 2016, Sörelius *et Di Summa* 2018). Due to complexity of the disease, prospective comparative studies will most likely never be possible which is why we need to improve the quality of the results by homogenising the patients included in the series to develop the recommendations for diagnostics and management. Due to rarity of the condition, prospective international registries could provide standardised data on management of such patients and further contribute to evidence-based recommendations. The MAGIC-database has been created to collect prospective data on AGI patients, however similar database for MAAA patients is lacking (Lyons *et al* 2016).

Biological aortic reconstruction material is infection-resistant, however long-term durability could be improved. Further research on cryopreservation techniques and suppression of immunology of the arteries could improve the results. Decellularized grafts provide an immunologically compatible alternative, with immunogenic cells removed and acellular matrix ready to be repopulated by recipient cells. Promising results from cardiac surgery have raised interest, however, current decellurisation methods accelerate elastin fragmentation and, therefore, aneurysmal degeneration appears after the implantation of such grafts into high-pressure arterial system. Tissue engineering, such as combining decellularized allografts with synthetic polymers, may result in more durable grafts, as might seeding the decellularized allograft's scaffold with luminal vascular cells prior to implantation. (Martin *et al* 2005.)

Cryopreserved large-calibre venous allografts showed promising results in current study; however, fragmentation and slow aneurysmal dilatation at the anastomotic sites may still appear. Further research on developing cryopreservation methods designed for veins are warranted. Denuded endothelium diminishes the immunogenicity but does not promote thrombogenicity. Creating freezing-thawing protocols and handling techniques that spare elastic fibres from deterioration would make cryopreserved large-calibre venous allografts a very promising biological reconstruction material for the aorta.

XPTs as aortic reconstruction material are very appealing due to availability, scaffolding and cost. They are infection-resistant and results regarding their durability are anticipated with excitement to ascertain their position in infectious conditions.

The prevention of AKI remains one of the most important factors to be addressed in aortic surgery encompassing renal arteries. Comparative studies of renal protection methods in major aortic surgery could identify patients who benefit from physiological perfusion the most and provide prognostic data for determining whether different renal protections have any effect on early mortality, or development of CKD and overall survival.

CONCLUSIONS

1. Postoperative morbidity remains high after surgical treatment of abdominal aortic infections. The mortality, however, is at acceptable level in multidisciplinary team approach. An aorto-enteric fistula as an indication for surgery carries the highest risk of morbidity and mortality irrespective of the reconstruction material used. In terms of midterm mortality, treatment of mycotic abdominal aortic aneurysm with biological conduit is not inferior to standard treatment of infrarenal degenerative aneurysm. The overall mortality after aortic graft infections remains higher compared to mortality after mycotic aneurysm. However, long-term survival after biological reconstructions is superior to survival after prosthetic reconstructions in the context of aortic infections.
2. Biological grafts are infection-resistant in treatment of abdominal aortic infections. Furthermore, they spare patients from life-long antibiotic suppression and subsequent complications without undermining the outcome.
3. Biological grafts show good durability in midterm analysis after treatment of abdominal aortic infections. However, their performance was similar, and no single conduit was superior to others. Therefore, based on current evidence, the choice of conduit should be made by the surgeon in consensus with patient and on the basis of patient's general condition, availability of graft, urgency of the aortic repair and surgeon's own experience.
4. Ischaemic kidney injury during major aortic surgery can be diminished with temporary axillo-renal bypass. It is safe and feasible, with minimal additional morbidity.

ACKNOWLEDGEMENTS

Current study was carried out at the Department of Vascular Surgery of Helsinki University Hospital in 2012 to 2019. Financial support was received from the grant of the Special Governmental Subsidy for the Health Sciences Research in Finland, Finnish Society of Angiology and Aarne and Aili Turusen foundation.

This work would have not been possible without contribution and support of many people and therefore I would like to devote my deepest gratitude to:

Maarit, my supervisor, for turning my reluctance to do research into eagerness to report our results and pursue academic career. Every mental obstacle I created, you took down with ease and always found time to listen, guide and support. Your patience, positivity and hilarity are endless at work and after. Thank you for being my mentor, my idol and most of all, my friend.

Ilkka, my co-supervisor, for making me part of the complex aortic surgery team, teaching me all the tricks in the operating room and trusting me to analyze the data on cases that are closest to your heart. Your unconditional support, kindness and enthusiastic passion for surgery (as well as for lists) are inspiring for all us, young surgeons.

Matti and **Janne**, for critical revision and excellent remarks to improve the manuscript.

Anders, for the hardest job of steering the ship. It is genuinely amazing how far meticulous technique and preciseness can carry in operating room and in revising the manuscripts. Thank you for sharing it with me.

Pekka, undoubtedly the funniest member of my theses committee. Thank you for teaching me the straight forward techniques in surgery, for bailing me out every time I run into trouble in hybrid suite, for guidance in the magical world of endovascular techniques, and for the best pizzas I have ever eaten. Your excellence in choosing the simplest solution to complex problems is admirable, as well is your excellence in shoe selection.

Pirkka, the fearless member of my thesis committee, for teaching me the perfection in carotid surgery and boldness in oncovascular surgery. Your endless ability to create invigorating debates on any subject, while backing up your statements with numbers and facts, keeps me motivated to learn more and become better in the field of surgery and research.

Karoliina, my first teacher in writing the manuscript, for truly caring, kindness, unlimited amount of positivity, amazing ability for problem solving and for girl power during my early days in vascular surgery.

Co-authors for joining the collaboration: **Karl Sörelius, Thomas R. Wyss, Nicla Settembre, Carlo Setacci, Nikolaj Eldrup, Kevin Mani, Marianne Jaroma** and **Ilkka Mattila**. Special thanks to Thomas for challenging me in sledding competition and sharing the countless hours of laughing in Lapland; Nicla for lightening up the mood with the Italian spirit in the dark underground rooms of Meilahti, while digging through the raw data; and Karl for immediate feedback whenever I had a question and for introducing Mr. Ocean to me.

My room-mates **Eeva-Maija** and **Sailaritta** for “adopting” me. Thank you for introducing surgeons’ life from a different perspective. Eeva-Maijas artistic personality, eagerness to learn something new and gorgeous voice amaze me every time. Sailis, you are probably the strongest person I know, and I am honored to be looked after by you. Your support and understanding when life felt too overwhelming, meant more than words can ever express. Thank you.

Sani, for teaching me patience and EVAR-skills; **Maria**, for always filling in when help was needed and sharing the first steps on the endovascular road; **Petteri**, for kindness and brilliant remarks to ease the tension in morning meetings; **Milla**, for ability to handle surgeries and family life with spectacular effortlessness; and **Eva** for straight forwardness, enthusiasm and friendship.

My “co-fighters” on the way to consultant status and dissertation: **Kata, Matti** and **Patrick**, my partners-in-crime, confidants and friends. You all reached the goal way before me and I admire you for the dedication, hard work and smarter choices you made. Thank you for the support on my journey and still keeping faith in me.

Riikka, for making me believe that some people have more than 24-hours in the day; **Sanna**, for keeping things “real” and introducing me SPSS; **Sari**, for the bike and for allowing me to teach you vascular surgery; **Heli**, for keeping up the Estonian spirit and always smiling; **Tiia** and **Hanni**, for peer support during the first years in vascular surgery; and **Kristýna**, for untamed spirit, positivity, dedication, long nights with Mr. Morgan and extremely dear and valuable friendship.

Ellinoora, Jenni, Mirjami, Juan, Jaakko and **Herman**, for your enthusiasm, energy, and eagerness. The future for Finnish vascular surgery is bright thanks to you all.

Leena and Anita, for fixing all the bureaucratic problems whether with Harppi or Terkko. Your constant, extremely valuable, but invisible work that magically makes our lives way smoother as surgeons and as researchers.

Mauri, for the great legacy you created that we are honored to be part of and contribute to. And for hiring me at the first place.

Teemu, for teaching me the baby steps in vascular surgery and having the patience to watch me learn.

Eeva Parviainen for the English language revision.

My dearest friend **Kristi**, for sharing the life from kinder garden, through high-school and medical school all the way to Helsinki. You are the voice of reason, when I lose the direction and shoulder to cry on, when I am hurt. Your honesty is refreshing, personality is striking, and craziness goes over the top. Thank you for being my best friend.

Mare, Madli and Kristjan, for being my extended family. Mare for supporting and listening me when I felt misunderstood. Madli, for introducing me the real world, where human interactions and interpretations are the actual backbone of society. Kristjan, for showing that intelligence, success and responsibility are not correlated with obedience.

My family, for always supporting me and believing in me. My dad **Uno**, for your unselfish way of helping people and caring for your family. Your ability to concentrate on details has taught me meticulousness and made me a better surgeon. My mom, **Epp**, for teaching me the meaning of dedication and caring, for taking me along to the hospital and showing what surgery requires, for all the love and care you provided and endless amount of delicious food! My brother, **Ivar**, for never stopping acting as a big brother. Despite the distance, your daily support and encouragement has paved my way to become stronger and better, because I have always a place to go back to when I fall. My granny, "**Memme**" for bringing us the sincere joy with witty comments and proving that (almost) 106 is just a number.

Sami, for giving me the time and space to concentrate on this project, and for putting up with all the stress and lonely weekends you spent without me. Thank you for being my personal Oxford dictionary, my sport manager, my support pillar and my joy. I could not have done it without your love and belief in me. You are wonderful, my love.

Thank You!

REFERENCES

- Aavik A, Lieberg J, Kals J, Pulges A, Kals M, Lepner U. Ten years experience of treating aorto-femoral bypass graft infection with venous allografts. *Eur J Vasc Endovasc Surg*. 2008 Oct;36:432-7.
- Ad-hoc working group of ERBP, Fliser D, Laville M, Covic A, Fouque D, Vanholder R, Juillard L, Van Biesen W. A European Renal Best Practice (ERBP) position statement on the Kidney Disease Improving Global Outcomes (KDIGO) clinical practice guidelines on acute kidney injury: part 1: definitions, conservative management and contrast-induced nephropathy. *Nephrol Dial Transplant*. 2012 Dec;27:4263-72. doi: 10.1093/ndt/gfs375.
- Aftab M, Coselli JS. Renal and visceral protection in thoracoabdominal aortic surgery. *J Thorac Cardiovasc Surg*. 2014 Dec;148:2963-6. doi: 10.1016/j.jtcvs.2014.06.072.
- Ali AT, Bell C, Modrall JG, Valentine RJ, Clagett GP. Graft-associated hemorrhage from femoropopliteal vein grafts. *J Vasc Surg*. 2005 Oct;42:667-72.
- Ali AT, McLeod N, Kalapatapu VR, Moursi MM, Eidt JF. Staging the neoaortoiliac system: feasibility and short-term outcomes. *J Vasc Surg*. 2008 Nov;48:1125-30; discussion 1130-1. doi: 10.1016/j.jvs.2008.06.067.
- Ali AT, Modrall JG, Hocking J, Valentine RJ, Spencer H, Eidt JF, Clagett GP. Long-term results of the treatment of aortic graft infection by in situ replacement with femoral popliteal vein grafts. *J Vasc Surg*. 2009 Jul;50:30-9. doi: 10.1016/j.jvs.2009.01.008.
- Anderson K, Hamm RL. Factors That Impair Wound Healing. *J Am Coll Clin Wound Spec*. 2014 Mar 24;4:84-91. doi: 10.1016/j.jccw.2014.03.001.
- Antonios VS, Noel AA, Steckelberg JM, Wilson WR, Mandrekar JN, Harmsen WS, Baddour LM. Prosthetic vascular graft infection: a risk factor analysis using a case-control study. *J Infect*. 2006 Jul;53:49-55.
- Argyriou C, Georgiadis GS, Lazarides MK, Georgakarakos E, Antoniou GA. Endograft Infection After Endovascular Abdominal Aortic Aneurysm Repair: A Systematic Review and Meta-analysis. *J Endovasc Ther*. 2017 Oct;24:688-697. doi: 10.1177/1526602817722018.
- Bandyk DF, Bergamini TM, Kinney EV, Seabrook GR, Towne JB. In situ replacement of vascular prostheses infected by bacterial biofilms. *J Vasc Surg*. 1991 May;13:575-83.
- Barker WF. Mycotic aneurysms. *Ann Surg*. 1954 Jan;139:84-9.

- Batt M, Feugier P, Camou F, Coffy A, Senneville E, Caillon J, Calvet B, Chidiac C, Laurent F, Revest M, Daures JP. Research Group for Vascular Graft Infection; A Meta-Analysis of Outcomes After In Situ Reconstructions for Aortic Graft Infection. *Angiology*. 2018 May;69:370-379. doi: 10.1177/0003319717710114.
- Batt M, Feugier P, Camou F, Coffy A2, Senneville E2,5, Caillon J2,6, Calvet B2,7, Chidiac C, Laurent F, Revest M, Daures JP; Research Group for Vascular Graft Infection. A Meta-Analysis of Outcomes After In Situ Reconstructions for Aortic Graft Infection. *Angiology*. 2018 May; 69:370-379.
- Batt M, Jean-Baptiste E, O'Connor S, Saint-Lebes B, Feugier P, Patra P, Midy D, Haulon S. Early and late results of contemporary management of 37 secondary aortoenteric fistulae. *Eur J Vasc Endovasc Surg*. 2011 Jun;41:748-57. doi: 10.1016/j.ejvs.2011.02.020.
- Batt M, Magne JL, Alric P, Muzj A, Ruotolo C, Ljungstrom KG, Garcia-Casas R, Simms M. In situ revascularization with silver-coated polyester grafts to treat aortic infection: early and midterm results. *J Vasc Surg*. 2003 Nov;38:983-9.
- Beck AW, Murphy EH, Hocking JA, Timaran CH, Arko FR, Clagett GP. Aortic reconstruction with femoral-popliteal vein: graft stenosis incidence, risk and reintervention. *J Vasc Surg*. 2008 Jan;47:36-43; discussion 44.
- Bell S, Ross VC, Zealley KA, Millar F, Isles C. Management of post-operative acute kidney injury. *QJM*. 2017 Nov 1;110:695-700. doi: 10.1093/qjmed/hcw175.
- Bellomo R, Ronco C, Kellum JA, Mehta RL, Palevsky P; Acute Dialysis Quality Initiative workgroup. Acute renal failure - definition, outcome measures, animal models, fluid therapy and information technology needs: the Second International Consensus Conference of the Acute Dialysis Quality Initiative (ADQI) Group. *Crit Care*. 2004 Aug;8:R204-12.
- Ben Ahmed S, Louvancourt A, Daniel G, Combe P, Duprey A, Albertini JN, Favre JP, Rosset E. Cryopreserved arterial allografts for in situ reconstruction of abdominal aortic native or secondary graft infection. *J Vasc Surg*. 2018 Feb;67:468-477. doi: 10.1016/j.jvs.2017.06.088.
- Berard X, Puges M, Pinaquy JB, Cazanave C, Stecken L, Bordenave L, Pereyre S, M'Zali F. In vitro Evidence of Improved Antimicrobial Efficacy of Silver and Triclosan Containing Vascular Grafts Compared with Rifampicin Soaked Grafts. *Eur J Vasc Endovasc Surg*. 2018 Oct 6. pii: S1078-5884(18)30653-1. doi: 10.1016/j.ejvs.2018.08.053.

- Bergamini TM, Corpus RA Jr, Brittain KR, Peyton JC, Cheadle WG. The natural history of bacterial biofilm graft infection. *J Surg Res.* 1994 May;56:393-6.
- Berger K, Sauvage LR, Rao AM, Wood SJ. Healing of arterial prostheses in man: its incompleteness. *Ann Surg.* 1972 Jan;175:118-27.
- Berger P, De Borst GJ, Moll FL. Current opinions about diagnosis and treatment strategy for aortic graft infections in The Netherlands. *J Cardiovasc Surg (Torino).* 2015 Dec;56:867-76.
- Berger P, Moll FL. Aortic graft infections: is there still a role for axillobifemoral reconstruction? *Semin Vasc Surg.* 2011 Dec;24:205-10. doi: 10.1053/j.semvascsurg.2011.10.011.
- Berger P, Vaartjes I, Moll FL, De Borst GJ, Blankensteijn JD, Bots ML. Cumulative incidence of graft infection after primary prosthetic aortic reconstruction in the endovascular era. *Eur J Vasc Endovasc Surg.* 2015 May;49:581-5. doi: 10.1016/j.ejvs.2015.01.001.
- Bergqvist D, Björck M. Secondary arterioenteric fistulation--a systematic literature analysis. *Eur J Vasc Endovasc Surg.* 2009 Jan;37:31-42. doi: 10.1016/j.ejvs.2008.09.023.
- Bisdas T, Bredt M, Pichlmaier M, Aper T, Wilhelmi M, Bisdas S, Haverich A, Teebken OE. Eight-year experience with cryopreserved arterial homografts for the in situ reconstruction of abdominal aortic infections. *J Vasc Surg.* 2010 Aug;52:323-30. doi: 10.1016/j.jvs.2010.02.277.
- Bisdas T, Wilhelmi M, Haverich A, Teebken OE. Cryopreserved arterial homografts vs silver-coated Dacron grafts for abdominal aortic infections with intraoperative evidence of microorganisms. *J Vasc Surg.* 2011 May;53:1274-1281.e4. doi: 10.1016/j.jvs.2010.11.052.
- Bonventre JV, Yang L. Cellular pathophysiology of ischemic acute kidney injury. *J Clin Invest.* 2011 Nov;121(11):4210-21. doi: 10.1172/JCI45161.
- Brown SL, Busuttill RW, Baker JD, Machleder HI, Moore WS, Barker WF. Bacteriologic and surgical determinants of survival in patients with mycotic aneurysms. *J Vasc Surg.* 1984 Jul;1:541-7.
- Bruggink JL, Slart RH, Pol JA, Reijnen MM, Zeebregts CJ. Current role of imaging in diagnosing aortic graft infections. *Semin Vasc Surg.* 2011 Dec;24:182-90. doi: 10.1053/j.semvascsurg.2011.10.007.

- Bunt TJ. Synthetic vascular graft infections. I. Graft infections. *Surgery*. 1983 Jun;93:733-46.
- Calligaro KD, Veith FJ, Yuan JG, Gargiulo NJ, Dougherty MJ. Intra-abdominal aortic graft infection: complete or partial graft preservation in patients at very high risk. *J Vasc Surg*. 2003 Dec;38:1199-205.
- Calligaro KD, Veith FJ. Graft preserving methods for managing aortofemoral prosthetic graft infection. *Eur J Vasc Endovasc Surg*. 1997 Dec;14 Suppl A:38-42.
- Capoccia L, Speziale F, Menna D, Esposito A, Sirignano P, Rizzo AR, Mansour W, Montelione N, Sbarigia E, Setacci C. Collaborators; Preliminary Results from a National Enquiry of Infection in Abdominal Aortic Endovascular Repair (Registry of Infection in EVAR--R.I.EVAR). *Ann Vasc Surg*. 2016 Jan;30:198-204. doi: 10.1016/j.avsg.2015.07.017.
- Castagno C, Varetto G, Quaglino S, Frola E, Scozzari G, Bert F, Rispoli P. Acute kidney injury after open and endovascular elective repair for infrarenal abdominal aortic aneurysms. *J Vasc Surg*. 2016 Oct;64:928-933.e1. doi: 10.1016/j.jvs.2016.02.048.
- Cernohorsky P, Reijnen MM, Tielliu IF, van Sterkenburg SM, van den Dungen JJ, Zeebregts CJ. The relevance of aortic endograft prosthetic infection. *J Vasc Surg*. 2011 Aug;54:327-33. doi: 10.1016/j.jvs.2010.12.067.
- Chambers ST. Diagnosis and management of staphylococcal infections of vascular grafts and stents. *Intern Med J*. 2005 Dec;35 Suppl 2:S72-8.
- Chang CY, Chang CP, Shih CC, Yang BH, Cheng CY, Chang CW, Chu LS, Wang SJ, Liu RS. Added Value of Dual-Time-Point 18F-FDG PET/CT With Delayed Imaging for Detecting Aortic Graft Infection: An Observational Study. *Medicine (Baltimore)*. 2015 Jul;94:e1124. doi: 10.1097/MD.0000000000001124.
- Charlton-Ouw KM, Sandhu HK, Huang G, Leake SS, Miller CC 3rd, Estrera AL, Azzizadeh A, Safi HJ. Reinfection after resection and revascularization of infected infrarenal abdominal aortic grafts. *J Vasc Surg*. 2014 Mar;59:684-92. doi: 10.1016/j.jvs.2013.09.030.
- Chaufour X, Gaudric J, Goueffic Y, Khodja RH, Feugier P, Malikov S, Beraud G, Ricco JB; AURC (French University Surgeons Association) collaborators. A multicenter experience with infected abdominal aortic endograft explantation. *J Vasc Surg*. 2017 Feb;65:372-380. doi: 10.1016/j.jvs.2016.07.126.

- Cheng H, Chen BP, Soleas IM, Ferko NC, Cameron CG, Hinoul P. Prolonged Operative Duration Increases Risk of Surgical Site Infections: A Systematic Review. *Surg Infect (Larchmt)*. 2017 Aug/Sep;18:722-735. doi: 10.1089/sur.2017.089.
- Chiesa R, Astore D, Frigerio S, Garriboli L, Piccolo G, Castellano R, Scalamogna M, Odero A, Pirrelli S, Biasi G, Mingazzini P, Biglioli P, Polvani G, Guarino A, Agrifoglio G, Tori A, Spina G. Vascular prosthetic graft infection: epidemiology, bacteriology, pathogenesis and treatment. *Acta Chir Belg*. 2002 Aug;102:238-47.
- Chong T, Nguyen L, Owens CD, Conte MS, Belkin M. Suprarenal aortic cross-clamp position: a reappraisal of its effects on outcomes for open abdominal aortic aneurysm repair. *J Vasc Surg*. 2009 Apr;49:873-80. doi: 10.1016/j.jvs.2008.10.057.
- Clagett GP, Bowers BL, Lopez-Viego MA, Rossi MB, Valentine RJ, Myers SI, Chervu A. Creation of a neo-aortoiliac system from lower extremity deep and superficial veins. *Ann Surg*. 1993 Sep;218:239-48; discussion 248-9.
- Cogliati AA, Vellutini R, Nardini A, Urovi S, Hamdan M, Landoni G, Guelfi P. Fenoldopam infusion for renal protection in high-risk cardiac surgery patients: a randomized clinical study. *J Cardiothorac Vasc Anesth*. 2007 Dec;21:847-50.
- Cohen JI, Bartlett JA, Corey GR. Extra-intestinal manifestations of salmonella infections. *Medicine (Baltimore)*. 1987 Sep;66(5):349-88.
- Cronenwett JL & Johnston KW (eds). *Rutherford's Vascular Surgery, 7-th Edition*: Saunders, 2010.
- Czerny M, von Allmen R, Opfermann P, Sodeck G, Dick F, Stellmes A, Makaloski V, Bühlmann R, Derungs U, Widmer MK, Carrel T, Schmidli J. Self-made pericardial tube graft: a new surgical concept for treatment of graft infections after thoracic and abdominal aortic procedures. *Ann Thorac Surg*. 2011 Nov;92:1657-62. doi: 10.1016/j.athoracsur.2011.06.073.
- D'Addato M, Curti T, Freyrie A. The rifampicin-bonded gelseal graft. *Eur J Vasc Endovasc Surg*. 1997 Dec;14 Suppl A:15-7.
- Daenens K, Fourneau I, Nevelsteen A. Ten-year experience in autogenous reconstruction with the femoral vein in the treatment of aortofemoral prosthetic infection. *Eur J Vasc Endovasc Surg*. 2003 Mar;25:240-5.
- Danneels MI, Verhagen HJ, Teijink JA, Cuypers P, Nevelsteen A, Vermassen FE. Endovascular repair for aorto-enteric fistula: a bridge too far or a bridge to surgery? *Eur J Vasc Endovasc Surg*. 2006 Jul;32:27-33.

- Darlane C, Coscas R, Boullitrop C, Javerliat I, Vilaine E, Goeau-Brissonniere O, Coggia M, Massy ZA. Acute Kidney Injury after Open Repair of Intact Abdominal Aortic Aneurysms. *Ann Vasc Surg.* 2017 Feb;39:294-300. doi: 10.1016/j.avsg.2016.09.010.
- Davila VJ, Stone W, Duncan AA, Wood E, Jordan WD Jr, Zea N, Sternbergh WC 3rd, Money SR. A multicenter experience with the surgical treatment of infected abdominal aortic endografts. *J Vasc Surg.* 2015 Oct;62:877-83. doi: 10.1016/j.jvs.2015.04.440.
- Deen J, von Seidlein L, Andersen F, Elle N, White NJ, Lubell Y. Community-acquired bacterial bloodstream infections in developing countries in south and southeast Asia: a systematic review. *Lancet Infect Dis.* 2012 Jun;12:480-7. doi: 10.1016/S1473-3099(12)70028-2.
- Deijen CL, Smulders YM, Coveliers HME, Wisselink W, Rauwerda JA, Hoksbergen AWJ. The Importance of Early Diagnosis and Treatment of Patients with Aortoenteric Fistulas Presenting with Herald Bleeds. *Ann Vasc Surg.* 2016 Oct;36:28-34. doi: 10.1016/j.avsg.2016.03.028.
- Della Schiava N, Mathevet JL, Boudjelit T, Arsicot M, Feugier P, Lermusiaux P, Millon A. Cryopreserved Arterial Allografts and ABO and Rhesus Compatibility. *Ann Vasc Surg.* 2016 May;33:173-80. doi: 10.1016/j.avsg.2015.11.014.
- Dorweiler B, Neufang A, Chaban R, Reinstadler J, Duenschede F, Vahl CF. Use and durability of femoral vein for autologous reconstruction with infection of the aortoiliiofemoral axis. *J Vasc Surg.* 2014 Mar;59:675-83. doi:10.1016/j.jvs.2013.09.029.
- Dryden M, Baguneid M, Eckmann C, Corman S, Stephens J, Solem C, Li J, Charbonneau C, Baillon-Plot N, Haider S. Pathophysiology and burden of infection in patients with diabetes mellitus and peripheral vascular disease: focus on skin and soft-tissue infections. *Clin Microbiol Infect.* 2015 Sep;21 Suppl 2:S27-32. doi: 10.1016/j.cmi.2015.03.024.
- Dubois L, Durant C, Harrington DM, Forbes TL, Derosé G, Harris JR. Technical factors are strongest predictors of postoperative renal dysfunction after open transperitoneal juxtarenal abdominal aortic aneurysm repair. *J Vasc Surg.* 2013 Mar;57:648-54. doi: 10.1016/j.jvs.2012.09.043.
- Dubois M, Daenens K, Houthoofd S, Peetermans WE, Fourneau I. Treatment of mycotic aneurysms with involvement of the abdominal aorta: single-centre experience in 44 consecutive cases. *Eur J Vasc Endovasc Surg.* 2010 Oct;40:450-6. doi: 10.1016/j.ejvs.2010.07.017

- Ducassee E, Calisti A, Speziale F, Rizzo L, Misuraca M, Fiorani P. Aortoiliac stent graft infection: current problems and management. *Ann Vasc Surg.* 2004 Sep;18:521-6.
- Durham JR, Malone JM, Bernhard VM. *J Vasc Surg.* 1987 Jan;5:160-9.
- Edmiston CE Jr, Daoud FC, Leaper D. Is there an evidence-based argument for embracing an antimicrobial (triclosan)-coated suture technology to reduce the risk for surgical-site infections? A meta-analysis. *Surgery.* 2014 Feb;155:362-3. doi: 10.1016/j.surg.2013.11.002.
- Ehsan O, Gibbons CP. A 10-year experience of using femoro-popliteal vein for re-vascularisation in graft and arterial infections. *Eur J Vasc Endovasc Surg.* 2009 Aug;38:172-9. doi: 10.1016/j.ejvs.2009.03.009.
- Elek SD, Conen PE. The virulence of *Staphylococcus pyogenes* for man; a study of the problems of wound infection. *Br J Exp Pathol.* 1957 Dec;38:573-86.
- Fatima J, Duncan AA, de Grandis E, Oderich GS, Kalra M, Gloviczki P, Bower TC; Treatment strategies and outcomes in patients with infected aortic endografts. *J Vasc Surg.* 2013 Aug;58:371-9. doi: 10.1016/j.jvs.2013.01.047.
- Fiorani P, Speziale F, Rizzo L, De Santis F, Massimi GJ, Taurino M, Faraglia V, Fiorani L, Baiocchi P, Santini C, et al. Detection of aortic graft infection with leukocytes labeled with technetium 99m-hexametazime. *J Vasc Surg.* 1993 Jan;17:87-95; discussion 95-6.
- Fluit AC, Jones ME, Schmitz FJ, Acar J, Gupta R, Verhoef J. Antimicrobial susceptibility and frequency of occurrence of clinical blood isolates in Europe from the SENTRY antimicrobial surveillance program, 1997 and 1998. *Clin Infect Dis.* 2000 Mar;30:454-60.
- Frei E, Hodgkiss-Harlow K, Rossi PJ, Edmiston CE Jr, Bandyk DF. Microbial pathogenesis of bacterial biofilms: a causative factor of vascular surgical site infection. *Vasc Endovascular Surg.* 2011 Nov;45:688-96. doi: 10.1177/1538574411419528.
- Garot M, Delannoy PY, Meybeck A, Sarraz-Bournet B, d'Elia P, d'Escrivan T, Devos P, Leroy O. Intra-abdominal aortic graft infection: prognostic factors associated with in-hospital mortality. *BMC Infect Dis.* 2014 Apr 22;14:215. doi: 10.1186/1471-2334-14-215.
- Global Guidelines for the Prevention of Surgical Site Infection. Geneva: World Health Organization; 2016. 6, ANNEXES. Available from: <https://www.ncbi.nlm.nih.gov/books/NBK401124/>.

- Goëau-Brissonnière O, Javerliat I, Koskas F, Coggia M, Pechère JC. Rifampin-bonded vascular grafts and postoperative infections. *Ann Vasc Surg.* 2011 Jan;25:134-42. doi: 10.1016/j.avsg.2010.09.002.
- Goldstone J, Moore WS. Infection in vascular prostheses. Clinical manifestations and surgical management. *Am J Surg.* 1974 Aug;128:225-33.
- Grant SW, Grayson AD, Grant MJ, Purkayastha D, McCollum CN. What are the risk factors for renal failure following open elective abdominal aortic aneurysm repair? *Eur J Vasc Endovasc Surg.* 2012 Feb;43:182-7. doi: 10.1016/j.ejvs.2011.11.018.
- Hagspiel KD, Turba UC, Bozlar U, Harthun NL, Cherry KJ, Ahmed H, Bickston SJ, Angle JF. Diagnosis of aortoenteric fistulas with CT angiography. *J Vasc Interv Radiol.* 2007 Apr;18:497-504.
- Haidar GM, Hicks TD, Strosberg DS, El-Sayed HF, Davies MG. "In situ" endografting in the treatment of arterial and graft infections. *J Vasc Surg.* 2017 Jun;65:1824-1829. doi: 10.1016/j.jvs.2016.12.134.
- Hall MR, McGillicuddy E, Kaplan LJ. Biofilm: basic principles, pathophysiology, and implications for clinicians. *Surg Infect (Larchmt).* 2014 Feb;15:1-7. doi: 10.1089/sur.2012.129.
- Hanssen SJ, Derikx JP, Vermeulen Windsant IC, Heijmans JH, Koeppel TA, Schurink GW, Buurman WA, Jacobs MJ. Visceral injury and systemic inflammation in patients undergoing extracorporeal circulation during aortic surgery. *Ann Surg.* 2008 Jul;248:117-25. doi: 10.1097/SLA.0b013e3181784cc5.
- Harlander-Locke MP, Harmon LK, Lawrence PF, Oderich GS, McCready RA, Morasch MD, Feezor RJ; Vascular Low-Frequency Disease Consortium, Zhou W, Bismuth J, Pevac WC, Correa MP, Jim J, Ladowski JS, Kougias P, Bove PG, Wittgen CM, White JV. The use of cryopreserved aortoiliac allograft for aortic reconstruction in the United States. *J Vasc Surg.* 2014 Mar;59:669-74. doi: 10.1016/j.jvs.2013.09.009.
- Heo SH, Kim YW, Woo SY, Park YJ, Kim DK, Chung DR. Recent Results of In Situ Abdominal Aortic Reconstruction with Cryopreserved Arterial Allograft. *Eur J Vasc Endovasc Surg.* 2017 Feb;53:158-167. doi: 10.1016/j.ejvs.2016.07.090
- Hersey P, Poullis M. Does the administration of mannitol prevent renal failure in open abdominal aortic aneurysm surgery? *Interact Cardiovasc Thorac Surg.* 2008 Oct;7:906-9. doi: 10.1510/icvts.2008.184010.
- Herten M, Idelevich EA, Sielker S, Becker K, Scherzinger AS, Osada N, Torsello GB, Bisdas T. Vascular Graft Impregnation with Antibiotics: The Influence of High

- Concentrations of Rifampin, Vancomycin, Daptomycin, and Bacteriophage Endolysin HY-133 on Viability of Vascular Cells. *Med Sci Monit Basic Res.* 2017 Jun 27;23:250-257.
- Hicks RC, Greenhalgh RM. The pathogenesis of vascular graft infection. *Eur J Vasc Endovasc Surg.* 1997 Dec;14 Suppl A:5-9.
- Hobbs SD, Kumar S, Gilling-Smith GL. Epidemiology and diagnosis of endograft infection. *J Cardiovasc Surg (Torino).* 2010 Feb;51:5-14.
- Hobson C, Lysak N, Huber M, Scali S, Bihorac A. Epidemiology, outcomes, and management of acute kidney injury in the vascular surgery patient. *J Vasc Surg.* 2018 Sep;68:916-928. doi: 10.1016/j.jvs.2018.05.017.
- Hodgkiss-Harlow KD, Bandyk DF. Antibiotic therapy of aortic graft infection: treatment and prevention recommendations. *Semin Vasc Surg.* 2011 Dec;24:191-8. doi: 10.1053/j.semvascsurg.2011.10.013.
- Hoffert PW, Gensler S, Haimovici H. Infection complicating arterial grafts: Personal experience with 12 cases and review of the literature. *Arch Surg.* 1965 Mar;90:427-35.
- Hsu RB, Chang CI, Wu IH, Lin FY. Selective medical treatment of infected aneurysms of the aorta in high risk patients. *J Vasc Surg.* 2009 Jan;49:66-70. doi: 10.1016/j.jvs.2008.08.004.
- Hsu RB, Chen RJ, Wang SS, Chu SH. Infected aortic aneurysms: clinical outcome and risk factor analysis. *J Vasc Surg.* 2004 Jul;40:30-5.
- Hsu RB, Lin FY, Chen RJ, Hsueh PR, Wang SS. Antimicrobial drug resistance in salmonella-infected aortic aneurysms. *Ann Thorac Surg.* 2005 Aug;80:530-6.
- Hsu RB, Tsay YG, Wang SS, Chu SH. Surgical treatment for primary infected aneurysm of the descending thoracic aorta, abdominal aorta, and iliac arteries. *J Vasc Surg.* 2002 Oct;36:746-50
- Insall RL, Keavey PM, Hawkins T, Hayes N, Jones NA, Chamberlain J. The specificity of technetium-labelled-leucocyte imaging of aortic grafts in the early postoperative period. *Eur J Vasc Surg.* 1991 Oct;5:571-6.
- Inui T, Bandyk DF. Vascular surgical site infection: risk factors and preventive measures. *Semin Vasc Surg.* 2015 Sep-Dec;28:201-7. doi: 10.1053/j.semvascsurg.2016.02.002.
- Jackman JD Jr, Radolf JD. Cardiovascular syphilis. *Am J Med.* 1989 Oct;87:425-33.

- Jarrett F, Darling RC, Mundth ED, Austen WG. Experience with infected aneurysms of the abdominal aorta. *Arch Surg.* 1975 Nov;110:1281-6.
- Jausseran JM, Stella N, Courbier R, Bergeron P, Ferdani M, Houel H, Rudondy P. Total prosthetic graft excision and extra-anatomic bypass. *Eur J Vasc Endovasc Surg.* 1997 Dec;14 Suppl A:59-65.
- Jeanmonod P, Laschke MW, Gola N, von Heesen M, Glanemann M, Dold S, Menger MD, Moussavian MR. Silver acetate coating promotes early vascularization of Dacron vascular grafts without inducing host tissue inflammation. *J Vasc Surg.* 2013 Dec;58:1637-43. doi: 10.1016/j.jvs.2013.02.012.
- Jeanmonod P, Laschke MW, Gola N, von Heesen M, Glanemann M, Menger MD, Moussavian MR. Early host tissue response to different types of vascular prostheses coated with silver acetate or vaporized metallic silver. *Eur J Vasc Endovasc Surg.* 2014 Jun;47:680-8. doi: 10.1016/j.ejvs.2014.03.006.
- Jeyabalan G, Park T, Rhee RY, Makaroun MS, Cho JS. Comparison of modern open infrarenal and pararenal abdominal aortic aneurysm repair on early outcomes and renal dysfunction at one year. *J Vasc Surg.* 2011 Sep;54:654-9. doi: 10.1016/j.jvs.2011.03.007.
- Jongkind V, Yeung KK, Akkersdijk GJ, Heidsieck D, Reitsma JB, Tangelder GJ, Wisselink W. Juxtarenal aortic aneurysm repair. *J Vasc Surg.* 2010 Sep;52:760-7. doi: 10.1016/j.jvs.2010.01.049.
- Kahlberg A, Rinaldi E, Piffaretti G, Speziale F, Trimarchi S, Bonardelli S, Melissano G, Chiesa R; MAEFISTO collaborators. Results from the Multicenter Study on Aortoenteric Fistulization After Stent Grafting of the Abdominal Aorta (MAEFISTO). *J Vasc Surg.* 2016 Aug;64:313-320.e1. doi: 10.1016/j.jvs.2016.04.008.
- Kakkos SK, Papadoulas S, Tsolakis IA. Endovascular management of arterioenteric fistulas: a systemic review and meta-analysis of the literature. *J Endovasc Ther.* 2011 Feb;18:66-77. doi: 10.1583/10-3229.1.
- Kan CD, Lee HL, Luo CY, Yang YJ. The efficacy of aortic stent grafts in the management of mycotic abdominal aortic aneurysm-institute case management with systemic literature comparison. *Ann Vasc Surg.* 2010 May;24:433-40. doi: 10.1016/j.avsg.2009.08.004.
- Kan CD, Lee HL, Yang YJ. Outcome after endovascular stent graft treatment for mycotic aortic aneurysm: a systematic review. *J Vasc Surg.* 2007 Nov;46:906-12.

- Kasahara H, Shimizu H, Yozu R. Postoperative renal function after juxtarenal aortic aneurysm repair with simple cross-clamping. *Ann Vasc Surg.* 2013 Apr;27:291-8. doi: 10.1016/j.avsg.2012.04.024.
- Kellum JA, Lameire N; KDIGO AKI Guideline Work Group. Diagnosis, evaluation, and management of acute kidney injury: a KDIGO summary (Part 1). *Crit Care.* 2013 Feb 4;17:204. doi: 10.1186/cc11454.
- Kellum, J.A., Lameire, N., Aspelin, P., Barsoum, R.S., Burdmann, E.A., Goldstein, S.L., Herzog, C.A., Joannidis, M., Kribben, A., Levey, A.S., MacLeod, A.M., Mehta, R.L., Murray, P.T., Naicker, S., Opal, S.M., Schaefer, F., Schetz, M., Uchino, S. Kidney disease: Improving global outcomes (KDIGO) acute kidney injury work group. KDIGO clinical practice guideline for acute kidney injury (2012) *Kidney International Supplements*, 2, pp. 1-138.
- Kieffer E, Gomes D, Chiche L, Fléron MH, Koskas F, Bahnini A. Allograft replacement for infrarenal aortic graft infection: early and late results in 179 patients. *J Vasc Surg.* 2004 May;39:1009-17.
- Köksoy C, LeMaire SA, Curling PE, Raskin SA, Schmittling ZC, Conklin LD, Coselli JS. Renal perfusion during thoracoabdominal aortic operations: cold crystalloid is superior to normothermic blood. *Ann Thorac Surg.* 2002 Mar;73:730-8.
- Kubota H, Endo H, Noma M, Ishii H, Tsuchiya H, Yoshimoto A, Takahashi Y, Inaba Y, Nishino Y, Nunokawa M, Hosoi Y, Ikezoe T, Nemoto M, Makino Y, Nemoto Y, Matsukura M, Sugiyama M, Abe N, Takeuchi H, Nagao G, Kondo E, Yanagida O, Yoshino H, Sudo K. Xenopericardial roll graft replacement for infectious pseudoaneurysms and graft infections of the aorta. *J Cardiothorac Surg.* 2015 Oct 27;10:133. doi: 10.1186/s13019-015-0343-5.
- Lai CH, Luo CY, Lin PY, Kan CD, Chang RS, Wu HL, Yang YJ. Surgical consideration of in situ prosthetic replacement for primary infected abdominal aortic aneurysms. *Eur J Vasc Endovasc Surg.* 2011 Nov;42:617-24. doi: 10.1016/j.ejvs.2011.07.005.
- Laine MT, Laukontaus SJ, Sund R, Aho PS, Kantonen I, Albäck A, Venermo M. A population-based study of abdominal aortic aneurysm treatment in Finland 2000 to 2014. *Circulation.* 2017;136:1726–1734.
- Larena-Avellaneda A, Russmann S, Fein M, Debus ES. Prophylactic use of the silver-acetate-coated graft in arterial occlusive disease: a retrospective, comparative study. *J Vasc Surg.* 2009 Oct;50:790-8. doi: 10.1016/j.jvs.2009.05.003.

- Lawrence PF. Conservative treatment of aortic graft infection. *Semin Vasc Surg.* 2011 Dec;24:199-204. doi: 10.1053/j.semvascsurg.2011.10.014.
- Lee CC, Ng YY, Chou YH, Tiu CM, Wang Z, Yang HM, Chen TW, Yang WC. Mycotic aneurysm of the abdominal aorta in a patient undergoing hemodialysis: an unusual complication of *Staphylococcus aureus* bacteraemia. *Clin Infect Dis.* 2000 May;30:823-4.
- Lee WK, Mossop PJ, Little AF, Fitt GJ, Vrazas JI, Hoang JK, Hennessy OF. Infected (mycotic) aneurysms: spectrum of imaging appearances and management. *Radiographics.* 2008 Nov-Dec;28(7):1853-68. doi: 10.1148/rg.287085054.
- Lejay A, Delay C, Girsowicz E, Chenesseau B, Bonnin E, Ghariani MZ, Thaveau F, Georg Y, Geny B, Chakfe N. Cryopreserved Cadaveric Arterial Allograft for Arterial Reconstruction in Patients with Prosthetic Infection. *Eur J Vasc Endovasc Surg.* 2017 Nov;54:636-644.
- Lejay A*, Monnot A, Georg Y, Colvard B, Thaveau F, Geny B, Chakfé N. Pathology of graft and stent-graft infections: Lessons learned from examination of explant materials. *Semin Vasc Surg.* 2017 Jun - Sep;30:70-74.
- Lesèche G, Castier Y, Petit MD, Bertrand P, Kitzis M, Mussot S, Besnard M, Cerceau O. Long-term results of cryopreserved arterial allograft reconstruction in infected prosthetic grafts and mycotic aneurysms of the abdominal aorta. *J Vasc Surg.* 2001 Oct;34:616-22.
- Li HL, Chan YC, Cheng SW. Current Evidence on Management of Aortic Stent-graft Infection: A Systematic Review and Meta-Analysis. *Ann Vasc Surg.* 2018 Aug;51:306-313. doi: 10.1016/j.avsg.2018.02.038.
- Lin CH, Hsu RB. Primary Infected Aortic Aneurysm: Clinical Presentation, Pathogen, and Outcome. *Acta Cardiol Sin.* 2014 Nov;30:514-21.
- Luo CM, Chan CY, Chen YS, Wang SS, Chi NH, Wu IH. Long-term Outcome of Endovascular Treatment for Mycotic Aortic Aneurysm. *Eur J Vasc Endovasc Surg.* 2017 Oct;54:464-471. doi: 10.1016/j.ejvs.2017.07.004.
- Luo CY, Ko WC, Kan CD, Lin PY, Yang YJ. In situ reconstruction of septic aortic pseudoaneurysm due to *Salmonella* or *Streptococcus* microbial aortitis: long-term follow-up. *J Vasc Surg.* 2003 Nov;38:975-82.
- Lutz B, Reeps C, Biro G, Knappich C, Zimmermann A, Eckstein HH. Bovine Pericardium as New Technical Option for In Situ Reconstruction of Aortic Graft Infection. *Ann Vasc Surg.* 2017 May;41:118-126. doi: 10.1016/j.avsg.2016.07.098.

- Lyons OT, Baguneid M, Barwick TD, Bell RE, Foster N, Homer-Vanniasinkam S, Hopkins S, Hussain A, Katsanos K, Modarai B, Sandoe JA, Thomas S, Price NM. Diagnosis of Aortic Graft Infection: A Case Definition by the Management of Aortic Graft Infection Collaboration (MAGIC). *Eur J Vasc Endovasc Surg.* 2016 Dec;52:758-763. doi: 10.1016/j.ejvs.2016.09.007.
- Lyons OT, Patel AS, Saha P, Clough RE, Price N, Taylor PR. A 14-year experience with aortic endograft infection: management and results. *Eur J Vasc Endovasc Surg.* 2013 Sep;46:306-13. doi: 10.1016/j.ejvs.2013.04.021.
- Macbeth GA, Rubin JR, McIntyre KE Jr, Goldstone J, Malone JM. The relevance of arterial wall microbiology to the treatment of prosthetic graft infections: graft infection vs. arterial infection. *J Vasc Surg.* 1984 Nov;1:750-6.
- Mai H, Champion L, Ouali N, Hertig A, Peraldi MN, Glotz D, Rondeau E, Costa MA, Snanoudj R, Benoit G, Charpentier B, Durrbach A. *Candida albicans* arteritis transmitted by conservative liquid after renal transplantation: a report of four cases and review of the literature. *Transplantation.* 2006 Nov 15;82:1163-7.
- Makris K, Spanou L. Acute Kidney Injury: Definition, Pathophysiology and Clinical Phenotypes. *Clin Biochem Rev.* 2016 May;37:85-98.
- Manzur A, Gudiol F. Methicillin-resistant *Staphylococcus aureus* in long-term-care facilities. *Clin Microbiol Infect.* 2009 Dec;15 Suppl 7:26-30. doi: 10.1111/j.1469-0691.2009.03093.x.
- Marrocco-Trischitta MM, Melissano G, Kahlberg A, Vezzoli G, Calori G, Chiesa R. The impact of aortic clamping site on glomerular filtration rate after juxtarenal aneurysm repair. *Ann Vasc Surg.* 2009 Nov-Dec;23:770-7. doi: 10.1016/j.avsg.2009.04.002.
- Martin ND, Schaner PJ, Tulenko TN, Shapiro IM, Dimatteo CA, Williams TK, Hager ES, DiMuzio PJ. In vivo behavior of decellularized vein allograft. *J Surg Res.* 2005 Nov;129:17-23
- Matsuura JH, Rosenthal D, Wellons ED, Castronovo CS, Fronk D. Hemodialysis graft infections treated with cryopreserved femoral vein. *Cardiovasc Surg.* 2002 Dec;10:561-5
- Maxwell RA, Bell CM. Acute Kidney Injury in the Critically Ill. *Surg Clin North Am.* 2017 Dec;97:1399-1418. doi: 10.1016/j.suc.2017.07.004.
- Maze MJ, Laws P, Buckenham T, Pithie A, Gallagher K, Metcalf S, Roake J, Chambers ST. Outcomes of infected abdominal aortic grafts managed with antimicrobial therapy

- and graft retention in an unselected cohort. *Eur J Vasc Endovasc Surg.* 2013 Apr;45:373-80
- McAuley CE, Steed DL, Webster MW. Bacterial presence in aortic thrombus at elective aneurysm resection: is it clinically significant? *Am J Surg.* 1984 Mar;147:322-4.
- Mehta RL, Kellum JA, Shah SV, Molitoris BA, Ronco C, Warnock DG, Levin A; Acute Kidney Injury Network. Acute Kidney Injury Network: report of an initiative to improve outcomes in acute kidney injury. *Crit Care.* 2007;11:R31.
- Mirelli M, Buzzi M, Pasquinelli G, Tazzari PL, Testi G, Ricchi E, Conte R, Stella A. Fresh and cryopreserved arterial homografts: immunological and clinical results. *Transplant Proc.* 2005 Jul-Aug;37:2688-91.
- Monnot A, Dusseaux MM, Godier S, Plissonnier D. Passive Temporary Visceral Shunt from the Axillar Artery as an Adjunct Method during the Open Treatment of Thoracoabdominal Aortic Aneurysm. *Ann Vasc Surg.* 2016 Oct;36:127-131. doi: 10.1016/j.avsg.2016.03.031.
- Monnot A, Rouer M, Horion J, Plissonnier D. Axillofemoral bypass for kidney transplant protection during open repair of abdominal aortic aneurysm. *Ann Vasc Surg.* 2015 Aug;29:1315.e1-2. doi: 10.1016/j.avsg.2015.04.058.
- Moore WS, Malone JM, Keown K. Prosthetic arterial graft material. Influence on neointimal healing and bacteremic infectibility. *Arch Surg.* 1980 Nov;115:1379-83.
- Moser C, Pedersen HT, Lerche CJ, Kolpen M, Line L, Thomsen K, Høiby N, Jensen PØ. Biofilms and host response - helpful or harmful. *APMIS.* 2017 Apr;125:320-338. doi: 10.1111/apm.12674.
- Müller BT, Wegener OR, Grabitz K, Pillny M, Thomas L, Sandmann W. Mycotic aneurysms of the thoracic and abdominal aorta and iliac arteries: experience with anatomic and extra-anatomic repair in 33 cases. *J Vasc Surg.* 2001 Jan;33:106-13
- Müller-Schweinitzer E. Cryopreservation of vascular tissues. *Organogenesis.* 2009 Jul;5:97-104.
- Mundth ED, Darling RC, Alvarado RH, Buckley MJ, Linton RR, Austen WG. *Am J Surg.* Surgical management of mycotic aneurysms and the complications of infection in vascular reconstructive surgery. 1969 Apr;117:460-70.
- Neufang A, Savvidis S. Operative technique and morbidity of superficial femoral vein harvest. *Gefasschirurgie.* 2016;21(Suppl 2):45-54.

- Nevelsteen A, Lacroix H, Suy R. Autogenous reconstruction with the lower extremity deep veins: an alternative treatment of prosthetic infection after reconstructive surgery for aortoiliac disease. *J Vasc Surg.* 1995 Aug;22:129-34.
- O'Connor S, Andrew P, Batt M, Becquemin JP. A systematic review and meta-analysis of treatments for aortic graft infection. *J Vasc Surg.* 2006 Jul;44:38-45.
- O'Donnell TFX, Boitano LT, Deery SE, Clouse WD, Siracuse JJ, Schermerhorn ML, Green R, Takayama H, Patel VI. Factors associated with postoperative renal dysfunction and the subsequent impact on survival after open juxtarenal abdominal aortic aneurysm repair. *J Vasc Surg.* 2018 Nov 23. pii: S0741-5214.32104-9. doi: 10.1016/j.jvs.2018.07.066.
- O'Mara CS, Williams GM, Ernst CB. Secondary aortoenteric fistula. A 20 year experience. *Am J Surg.* 1981 Aug;142:203-9.
- Oderich GS, Bower TC, Hofer J, Kalra M, Duncan AA, Wilson JW, Cha S, Gloviczki P. In situ rifampin-soaked grafts with omental coverage and antibiotic suppression are durable with low reinfection rates in patients with aortic graft enteric erosion or fistula. *J Vasc Surg.* 2011 Jan;53:99-106, 107.e1-7; discussion 106-7. doi: 10.1016/j.jvs.2010.08.018.
- Oderich GS, Bower TC, Cherry KJ Jr, Panneton JM, Sullivan TM, Noel AA, Carmo M, Cha S, Kalra M, Gloviczki P. Evolution from axillofemoral to in situ prosthetic reconstruction for the treatment of aortic graft infections at a single center. *J Vasc Surg.* 2006 Jun;43:1166-74.
- Oderich GS, Panneton JM, Bower TC, Cherry KJ Jr, Rowland CM, Noel AA, Hallett JW Jr, Gloviczki P. Infected aortic aneurysms: aggressive presentation, complicated early outcome, but durable results. *J Vasc Surg.* 2001 Nov;34:900-8
- Olofsson PA, Auffermann W, Higgins CB, Rabahie GN, Tavares N, Stoney RJ. Diagnosis of prosthetic aortic graft infection by magnetic resonance imaging. *J Vasc Surg.* 1988 Aug;8:99-105.
- Orton DF, LeVeen RF, Saigh JA, Culp WC, Fidler JL, Lynch TJ, Goertzen TC, McCowan TC. Aortic prosthetic graft infections: radiologic manifestations and implications for management. *Radiographics.* 2000 Jul-Aug;20:977-93.
- Osler W. The Gulstonian Lectures, on Malignant Endocarditis. *Br Med J.* 1885 Mar 7;1(1262):467-70.
- Parkhurst GF, Dekcer JP. Bacterial aortitis and mycotic aneurysm of the aorta; a report of twelve cases. *Am J Pathol.* 1955 Sep-Oct;31:821-35

- Pegg DE, Wusteman MC, Boylan S. Fractures in cryopreserved elastic arteries. *Cryobiology*. 1997 Mar;34:183-92.
- Perera GB, Fujitani RM, Kubaska SM. Aortic graft infection: update on management and treatment options. *Vasc Endovascular Surg*. 2006 Jan-Feb;40:1-10.
- Pettersson J, Daryapeyma A, Gillgren P, Hultgren R. Aortic Graft Infections after Emergency and Non-Emergency Reconstruction: Incidence, Treatment, and Long-Term Outcome. *Surg Infect (Larchmt)*. 2017 Apr;18:303-310. doi: 10.1089/sur.2016.225.
- Pillay B, Ramdial PK, Naidoo DP. HIV-associated large-vessel vasculopathy: a review of the current and emerging clinicopathological spectrum in vascular surgical practice. *Cardiovasc J Afr*. 2015 Mar-Apr;26:70-81. doi: 10.5830/CVJA-2015-017.
- Prats E, Banzo J, Abós MD, Garcia-Lopez F, Escalera T, Garcia-Miralles M, Gaston R, Asenjo MJ. Diagnosis of prosthetic vascular graft infection by technetium-99m-HMPAO-labeled leukocytes. *J Nucl Med*. 1994 Aug;35:1303-7.
- Pupka A, Skora J, Janczak D, Plonek T, Marczak J, Szydelko T. In situ revascularisation with silver-coated polyester prostheses and arterial homografts in patients with aortic graft infection--a prospective, comparative, single-centre study. *Eur J Vasc Endovasc Surg*. 2011 Jan;41:61-7. doi: 10.1016/j.ejvs.2010.10.005.
- Qing Y, Cheng L, Li R, Liu G, Zhang Y, Tang X, Wang J, Liu H, Qin Y. Potential antibacterial mechanism of silver nanoparticles and the optimization of orthopedic implants by advanced modification technologies. *Int J Nanomedicine*. 2018 Jun 5;13:3311-3327. doi: 10.2147/IJN.S165125.
- Qiu J, Zhou W, Zhou W, Tang X, Yuan Q, Zhu X, Yang Y, Xiong J. The Treatment of Infected Femoral Artery Pseudoaneurysms Secondary to Drug Abuse: 11 Years of Experience at a Single Institution. *Ann Vasc Surg*. 2016 Oct;36:35-43. doi: 10.1016/j.avsg.2016.03.030.
- Qvarfordt PG, Reilly LM, Mark AS, Goldstone J, Wall SD, Ehrenfeld WK, Stoney RJ. Computerized tomographic assessment of graft incorporation after aortic reconstruction. *Am J Surg*. 1985 Aug;150:227-31.
- Reddy DJ, Shepard AD, Evans JR, Wright DJ, Smith RF, Ernst CB. Management of infected aortoiliac aneurysms. *Arch Surg*. 1991 Jul;126:873-8; discussion 878-9.
- Reilly LM, Altman H, Lusby RJ, Kersh RA, Ehrenfeld WK, Stoney RJ. Late results following surgical management of vascular graft infection. *J Vasc Surg*. 1984 Jan;1:36-44.

- Reinders Folmer EI, Von Meijenfeldt GCI, Van der Laan MJ, Glaudemans AWJM, Slart RHJA, Saleem BR, Zeebregts CJ. Diagnostic Imaging in Vascular Graft Infection: A Systematic Review and Meta-Analysis. *Eur J Vasc Endovasc Surg.* 2018 Nov;56:719-729. doi: 10.1016/j.ejvs.2018.07.010.
- Rendal E, Santos MV, Rodriguez M, Sánchez J, Segura R, Matheu G, Filgueira P, Pértega S, Andi6n C. Effects of cryopreservation and thawing on the structure of vascular segment. *Transplant Proc.* 2004 Dec;36:3283-7.
- Revest M, Camou F, Senneville E, Caillon J, Laurent F, Calvet B, Feugier P, Batt M, Chidiac C; Groupe de Réflexion sur les Infections de Prothèses vasculaires (GRIP). Medical treatment of prosthetic vascular graft infections: Review of the literature and proposals of a Working Group. *Int J Antimicrob Agents.* 2015 Sep;46:254-65. doi: 10.1016/j.ijantimicag.2015.04.014.
- Sailer AM, Nelemans PJ, van Berlo C, Yazar O, de Haan MW, Fleischmann D, Schurink GW. Endovascular treatment of complex aortic aneurysms: prevalence of acute kidney injury and effect on long-term renal function. *Eur Radiol.* 2016 Jun;26:1613-9. doi: 10.1007/s00330-015-3993-8.
- Saleem BR, Berger P, Vaartjes I, de Keizer B, Vonken EJ, Slart RH, de Borst GJ, Zeebregts CJ. Modest utility of quantitative measures in (18)F-fluorodeoxyglucose positron emission tomography scanning for the diagnosis of aortic prosthetic graft infection. *J Vasc Surg.* 2015 Apr;61:965-71. doi: 10.1016/j.jvs.2014.11.005.
- Sanchez AA, Johnston DA, Myers C, Edwards JE Jr, Mitchell AP, Filler SG. Relationship between *Candida albicans* virulence during experimental haematogenously disseminated infection and endothelial cell damage in vitro. *Infect Immun.* 2004 Jan;72:598-601.
- Schaefers JF, Donas KP, Panuccio G, Kasprzak B, Heine B, Torsello GB, Osada N, Usai MV. Outcomes of Surgical Explantation of Infected Aortic Grafts After Endovascular and Open Abdominal Aneurysm Repair. *Eur J Vasc Endovasc Surg.* 2019 Jan;57:130-136. doi: 10.1016/j.ejvs.2018.07.021.
- Schmitt DD, Bandyk DF, Pequet AJ, Towne JB. Bacterial adherence to vascular prostheses. A determinant of graft infectivity. *J Vasc Surg.* 1986 May;3:732-40.
- Sedivy P, Spacek M, El Samman K, Belohlavek O, Mach T, Jindrak V, Rohn V, Stadler P. Endovascular treatment of infected aortic aneurysms. *Eur J Vasc Endovasc Surg.* 2012 Oct;44:385-94. doi: 10.1016/j.ejvs.2012.07.011.

- Shahidi S, Eskil A, Lundof E, Klaerke A, Jensen BS. Detection of abdominal aortic graft infection: comparison of magnetic resonance imaging and indium-labeled white blood cell scanning. *Ann Vasc Surg.* 2007 Sep;21:586-92.
- Sidhu RS, Lindsay TF, Rubin B, Walker PM, Kalman P, Johnston KW. Aortic and iliac reconstruction after kidney transplantation: experience with an algorithm for renal protection. *Ann Vasc Surg.* 2003 Mar;17:165-70.
- Siracuse JJ, Krafcik BM, Farber A, Kalish JA, McChesney A, Rybin D, Doros G, Eslami MH. Contemporary open repair of ruptured abdominal aortic aneurysms. *J Vasc Surg.* 2017 Apr;65:1023-1028. doi: 10.1016/j.jvs.2016.08
- Smeds MR, Duncan AA, Harlander-Locke MP, Lawrence PF, Lyden S, Fatima J, Eskandari MK. Vascular Low-Frequency Disease Consortium; Treatment and outcomes of aortic endograft infection. *J Vasc Surg.* 2016 Feb;63:332-40. doi: 10.1016/j.jvs.2015.08.113.
- Smith ST, Clagett GP. Femoral vein harvest for vascular reconstructions: pitfalls and tips for success. *Semin Vasc Surg.* 2008 Mar;21:35-40. doi: 10.1053/j.semvascsurg.2007.11.007.
- Sommerville RL, Allen EV, Edwards JE. Bland and infected arteriosclerotic abdominal aortic aneurysms: a clinicopathologic study. *Medicine (Baltimore).* 1959 Sep;38:207-21.
- Soravia-Dunand VA, Loo VG, Salit IE. Aortitis due to Salmonella: report of 10 cases and comprehensive review of the literature. *Clin Infect Dis.* 1999 Oct;29:862-8.
- Sörelius K, di Summa PG. On the Diagnosis of Mycotic Aortic Aneurysms. *Clin Med Insights Cardiol.* 2018 Feb 20;12:1179546818759678. doi: 10.1177/1179546818759678.
- Sörelius K, Mani K, Björck M, Sedivy P, Wahlgren CM, Taylor P, Clough RE, Lyons O, Thompson M, Brownrigg J, Ivancev K, Davis M, Jenkins MP, Jaffer U, Bown M, Rancic Z, Mayer D, Brunkwall J, Gawenda M, Kölbel T, Jean-Baptiste E, Moll F, Berger P, Liapis CD, Moulakakis KG, Langenskiöld M, Roos H, Larzon T, Pirouzram A, Wanhainen A; European MAA collaborators. Endovascular treatment of mycotic aortic aneurysms: a European multicenter study. *Circulation.* 2014 Dec 9;130:2136-42. doi: 10.1161/CIRCULATIONAHA.114.009481.
- Sörelius K, Wanhainen A, Furebring M, Björck M, Gillgren P, Mani K, Swedish Collaborator Group for Mycotic Abdominal Aortic Aneurysms. Nationwide Study of

- the Treatment of Mycotic Abdominal Aortic Aneurysms Comparing Open and Endovascular Repair. *Circulation*. 2016 Dec 6;134:1822-1832.
- Spacek M, Belohlavek O, Votrubova J, Sebesta P, Stadler P. Diagnostics of "non-acute" vascular prosthesis infection using 18F-FDG PET/CT: our experience with 96 prostheses. *Eur J Nucl Med Mol Imaging*. 2009 May;36:850-8. doi: 10.1007/s00259-008-1002-z.
- Spanos K, Kouvelos G, Karathanos C, Matsagkas M, Giannoukas AD. Current status of endovascular treatment of aortoenteric fistula. *Semin Vasc Surg*. 2017 Jun - Sep;30:80-84. doi: 10.1053/j.semvascsurg.2017.10.004.
- Status van Eps RG, Nemeth B, Mairuhu RTA, Wever JJ, Veger HTC, van Overhagen H, van Dijk LC, Knippenberg B. Determinants of Acute Kidney Injury and Renal Function Decline After Endovascular Abdominal Aortic Aneurysm Repair. *Eur J Vasc Endovasc Surg*. 2017 Dec;54:712-720. doi: 10.1016/j.ejvs.2017.09.011.
- Stengel, A and CC. Wolferth. Mycotic (bacterial) aneurysms of intravascular origin. *Arch Intern Med (Chic)*. 1923;31:537-554. doi:10.1001/archinte.1923.00110160074005
- Sugimoto M, Takahashi N, Niimi K, Kodama A, Banno H, Komori K. Long-term fate of renal function after open surgery for juxtarenal and pararenal aortic aneurysm. *J Vasc Surg*. 2018 Apr;67:1042-1050. doi: 10.1016/j.jvs.2017.07.121.
- Swain, TW ; Calligaro, KD ; Dougherty, MD. Management of Infected Aortic Prosthetic Grafts. *Vasc Endovascular Surg*. 2004 Jan-Feb;38:75-82.
- Szilagyi DE, Smith RF, Elliott JP, Vrandecic MP. Infection in arterial reconstruction with synthetic grafts. *Ann Surg*. 1972 Sep;176:321-33.
- Teebken OE, Bisdas T, Assadian O, Ricco JB. Recommendations for reporting treatment of aortic graft infections. *Eur J Vasc Endovasc Surg*. 2012 Feb;43:174-81. doi: 10.1016/j.ejvs.2011.11.003.
- Tong SY, Davis JS, Eichenberger E, Holland TL, Fowler VG Jr. Staphylococcus aureus infections: epidemiology, pathophysiology, clinical manifestations, and management. *Clin Microbiol Rev*. 2015 Jul;28:603-61. doi: 10.1128/CMR.00134-14.
- Touma J, Cochenec F, Parisot J, Fialaire Legendre A, Becquemin JP, Desgranges P. In situ reconstruction in native and prosthetic aortic infections using cryopreserved arterial allografts. *Eur J Vasc Endovasc Surg*. 2014 Sep;48:292-9. doi: 10.1016/j.ejvs.2014.04.023.
- Trairatvorakul P, Sriphojanart S, Sathapatayavongs B. Abdominal aortic aneurysms infected with salmonella: problems of treatment. *J Vasc Surg*. 1990 Jul;12:16-9.

- Uchida N, Katayama A, Tamura K, Miwa S, Masatsugu K, Sueda T. In situ replacement for mycotic aneurysms on the thoracic and abdominal aorta using rifampicin-bonded grafting and omental pedicle grafting. *Ann Thorac Surg.* 2012 Feb;93:438-42. doi: 10.1016/j.athoracsur.2011.07.050.
- Vaara ST, Bellomo R. Postoperative renal dysfunction after noncardiac surgery. *Curr Opin Crit Care.* 2017 Oct;23:440-446. doi: 10.1097/MCC.0000000000000439.
- Valentine RJ, Chung J. Primary vascular infection. *Curr Probl Surg.* 2012 Mar;49:128-82. doi: 10.1067/j.cpsurg.2011.11.004.
- Vallejo N, Picardo NE, Bourke P, Bicknell C, Cheshire NJ, Jenkins MP, Wolfe J, Gibbs RG. The changing management of primary mycotic aortic aneurysms. *J Vasc Surg.* 2011 Aug;54:334-40. doi: 10.1016/j.jvs.2010.12.066
- Van Biesen W, Vanholder R, Lameire N. Defining acute renal failure: RIFLE and beyond. *Clin J Am Soc Nephrol.* 2006 Nov;1:1314-9
- Velge P, Wiedemann A, Rosselin M, Abed N, Boumart Z, Chaussé AM, Grépinet O, Namdari F, Roche SM, Rossignol A, Virlogeux-Payant I. Multiplicity of Salmonella entry mechanisms, a new paradigm for Salmonella pathogenesis. *Microbiologyopen.* 2012 Sep;1:243-58. doi: 10.1002/mbo3.28.
- Vogel TR, Symons R, Flum DR. The incidence and factors associated with graft infection after aortic aneurysm repair. *J Vasc Surg.* 2008 Feb;47:264-9. doi: 10.1016/j.jvs.2007.10.030.
- Vogt PR, Brunner-LaRocca HP, Lachat M, Ruef C, Turina MI. Technical details with the use of cryopreserved arterial allografts for aortic infection: influence on early and midterm mortality. *J Vasc Surg.* 2002 Jan;35:80-6.
- Wahlberg E, Dimuzio PJ, Stoney RJ. Aortic clamping during elective operations for infrarenal disease: The influence of clamping time on renal function. *J Vasc Surg.* 2002 Jul;36:13-8
- Waked K, Schepens M. State-of-the-art review on the renal and visceral protection during open thoracoabdominal aortic aneurysm repair. *J Vis Surg.* 2018 Feb 8;4:31. doi: 10.21037/jovs.2018.01.12
- Ward AO, Caputo M, Angelini GD, George SJ, Zakkar M. Activation and inflammation of the venous endothelium in vein graft disease. *Atherosclerosis.* 2017 Oct;265:266-274. doi: 10.1016/j.atherosclerosis.2017.08.023
- Weiss S, Tobler EL, von Tengg-Kobligk H, Makaloski V, Becker D, Carrel TP, Schmidli J, Wyss TR. Self Made Xeno-pericardial Aortic Tubes to Treat Native and Aortic Graft

- Infections. *Eur J Vasc Endovasc Surg.* 2017 Nov;54:646-652. doi: 10.1016/j.ejvs.2017.07.017.
- White RA & Hollier LH (eds.). *Vascular Surgery: Basic Science and Clinical Correlations*, 2-nd Edition. John Wiley & Sons, 2008.
- Wilson SE, Van Wagenen P, Passaro E Jr. Arterial infection. *Curr Probl Surg.* 1978 Sep;15:1-89.
- Wilson WR, Bower TC, Creager MA, Amin-Hanjani S, O'Gara PT, Lockhart PB, Darouiche RO, Ramlawi B, Derdeyn CP, Bolger AF, Levison ME, Taubert KA, Baltimore RS, Baddour LM. American Heart Association Committee on Rheumatic Fever, Endocarditis, and Kawasaki Disease of the Council on Cardiovascular Disease in the Young; Council on Cardiovascular and Stroke Nursing; Council on Cardiovascular Radiology and Intervention; Council on Cardiovascular Surgery and Anesthesia; Council on Peripheral Vascular Disease; and Stroke Council. Vascular Graft Infections, Mycotic Aneurysms, and Endovascular Infections: A Scientific Statement From the American Heart Association. *Circulation.* 2016 Nov 15;134:e412-e460.
- Woon CY, Sebastian MG, Tay KH, Tan SG. Extra-anatomic revascularization and aortic exclusion for mycotic aneurysms of the infrarenal aorta and iliac arteries in an Asian population. *Am J Surg.* 2008 Jan;195:66-72.
- Woźniak W, Kozińska A, Ciostek P, Sitkiewicz I. Susceptibility of Vascular Implants to Colonization in vitro by *Staphylococcus aureus*, *Staphylococcus epidermidis*, *Enterococcus faecalis* and *Pseudomonas aeruginosa*. *Pol J Microbiol.* 2017 Mar 30;66:125-129. doi: 10.5604/17331331.1235001.
- Yeung KK, Groeneveld M, Lu JJ, van Diemen P, Jongkind V, Wisselink W. Organ protection during aortic cross-clamping. *Best Pract Res Clin Anaesthesiol.* 2016 Sep;30:305-15. doi: 10.1016/j.bpa.2016.07.005.
- Yeung KK, Jongkind V, Coveliers HM, Tangelder GJ, Wisselink W. Routine continuous cold perfusion of the kidneys during elective juxtarenal aortic aneurysm repair. *Eur J Vasc Endovasc Surg.* 2008 Apr;35:446-51. doi: 10.1016/j.ejvs.2007.11.022.
- Yeung KK, Tangelder GJ, Fung WY, Coveliers HM, Hoksbergen AW, Van Leeuwen PA, de Lange-de Klerk ES, Wisselink W. Open surgical repair of ruptured juxtarenal aortic aneurysms with and without renal cooling: observations regarding morbidity and mortality. *J Vasc Surg.* 2010 Mar;51:551-8. doi: 10.1016/j.jvs.2009.09.051.

- Yu SY, Hsieh HC, Ko PJ, Huang YK, Chu JJ, Lee CH. Surgical outcome for mycotic aortic and iliac aneurysm. *World J Surg.* 2011 Jul;35:1671-8. doi: 10.1007/s00268-011-1104-9.
- Zammert M, Gelman S. The pathophysiology of aortic cross-clamping. *Best Pract Res Clin Anaesthesiol.* 2016 Sep;30:257-69. doi: 10.1016/j.bpa.2016.07.006.
- Zarkowsky DS, Hicks CW, Bostock IC, Stone DH, Eslami M, Goodney PP. Renal dysfunction and the associated decrease in survival after elective endovascular aneurysm repair. *J Vasc Surg.* 2016 Nov;64:1278-1285.e1. doi: 10.1016/j.jvs.2016.04.009.
- Zdanowski Z, Hallberg E, Schalén C, Ribbe E. Reduced susceptibility of polytetrafluoroethylene vascular prostheses to colonization by *Staphylococcus aureus* following in situ endothelialization. *Artif Organs.* 1994 Jun;18:448-53.
- Zimmerli W, Lew PD, Waldvogel FA. Pathogenesis of foreign body infection. Evidence for a local granulocyte defect. *J Clin Invest.* 1984 Apr;73:1191-200.

ORIGINAL PUBLICATIONS