

Keywords: tumour budding; oral squamous cell carcinoma; prognosis; marker; invasive front; treatment; survival

Tumour budding in oral squamous cell carcinoma: a meta-analysis

Alhadi Almangush^{*,1,2,3}, Matti Pirinen^{4,5,6}, Ilkka Heikkinen^{1,2}, Antti A Mäkitie⁷, Tuula Salo^{2,8,9,10} and Ilmo Leivo¹¹

¹Department of Pathology, University of Helsinki, Haartmaninkatu 3, PO Box 21, Helsinki FIN-00014, Finland; ²Department of Oral and Maxillofacial Diseases, University of Helsinki, Haartmaninkatu 8, PO Box 63, Helsinki FI-00014, Finland; ³Institute of Dentistry, University of Misurata, PO Box 2478, Misurata, Libya; ⁴Institute for Molecular Medicine Finland (FIMM), University of Helsinki, Helsinki FIN-00014, Finland; ⁵Helsinki Institute for Information Technology HIIT and Department of Mathematics and Statistics, University of Helsinki, Helsinki FIN-00014, Finland; ⁶Department of Public Health, University of Helsinki, Helsinki FIN-00014, Finland; ⁷Department of Otorhinolaryngology – Head and Neck Surgery, Helsinki University Hospital and University of Helsinki, Kasarminkatu 11-13, Helsinki FI-00130, Finland; ⁸Helsinki University Hospital, Helsinki FIN-00014, Finland; ⁹Research Group of Cancer Research and Translational Medicine, Medical Faculty, University of Oulu, PO Box 5281, Oulu 90014, Finland; ¹⁰Medical Research Center, Oulu University Hospital, Oulu 90220, Finland and ¹¹Department of Pathology, University of Turku, Kiinamylynkatu 10, Turku 20520, Finland

Background: Tumour budding has been reported as a promising prognostic marker in many cancers. This meta-analysis assessed the prognostic value of tumour budding in oral squamous cell carcinoma (OSCC).

Methods: We searched OvidMedline, PubMed, Scopus and Web of Science for articles that studied tumour budding in OSCC. We used reporting recommendations for tumour marker (REMARK) criteria to evaluate the quality of studies eligible for meta-analysis.

Results: A total of 16 studies evaluated the prognostic value of tumour budding in OSCC. The meta-analysis showed that tumour budding was significantly associated with lymph node metastasis (odds ratio = 7.08, 95% CI = 1.75–28.73), disease-free survival (hazard ratio = 1.83, 95% CI = 1.34–2.50) and overall survival (hazard ratio = 1.88, 95% CI = 1.25–2.82).

Conclusions: Tumour budding is a simple and reliable prognostic marker for OSCC. Evaluation of tumour budding could facilitate personalised management of OSCC.

Oral squamous cell carcinoma (OSCC) is the most common malignancy of the oral cavity and constitutes the majority of head and neck squamous cell carcinomas. According to a recent report, ~300 000 new cases of oral cancer were diagnosed worldwide in 2012, and with a consequent 145 000 cancer-related deaths (Ferlay *et al*, 2015). The incidence of OSCC has increased in many countries and especially in young people (Muller *et al*, 2008; Korvala *et al*, 2017). In the Western world, the main aetiological factors for OSCC are tobacco and alcohol consumption. Chewing

of Areca nuts and the use of snuff are the classic risk factors in the Indian population. The 5-year survival rate of OSCC patients is relatively low, and especially the patients with recurrence have poor outcomes. Identifying cases at risk for recurrence remains challenging.

Many histopathologic prognostic parameters (e.g., tumour grade, depth of invasion, perineural invasion, lymphovascular invasion, lymphocytic host response and mitotic activity) are usually evaluated in haematoxylin- and eosin- (H-E) stained

*Correspondence: Dr A Almangush; E-mail: alhadi.almangush@helsinki.fi or alhadi.almangush@gmail.com

Received 29 September 2017; revised 27 October 2017; accepted 30 October 2017; published online 30 November 2017

© 2018 Cancer Research UK. All rights reserved 0007–0920/18

sections. Such information is included in pathology reports to aid in predicting the behaviour of OSCC. This is paramount for planning of an appropriate and successful management. However, some of these parameters (e.g., tumour grade and lymphocytic response) have not been promising prognosticators, especially in early stage OSCC (Chen *et al*, 2013; Almangush *et al*, 2015a). Moreover, recent research has introduced several biomarkers for OSCC, but they are not yet eligible to be included in the pathology report (Soland and Brusevold, 2013; Almangush *et al*, 2017a). In addition, such biomarkers require additional staining procedures which are not routinely used. Therefore, it is important to identify new powerful prognostic markers that are adaptable to conventional H-E staining.

Tumour budding, defined as the presence of single cancer cell(s) or cluster(s) of less than five cancer cells at the invasive front (IF), has been reported in many cancers as a promising prognostic feature (Kadota *et al*, 2015; Almangush *et al*, 2016; Rogers *et al*, 2016). Tumour budding at the IF (Figure 1) indicates the dissociation of invasive cancer cells from the main tumour mass. Several recent studies have evaluated the significance of tumour budding in OSCC. The aim of the current study was to systematically review the studies on tumour budding in OSCC and to present a meta-analysis of the prognostic value of tumour budding in OSCC. We also discuss the shortcomings in the published studies and provide recommendations for further research to standardise the evaluation method of tumour budding in OSCC.

MATERIALS AND METHODS

Search protocol. OvidMedline, PubMed, Scopus and Web of Science were searched using the following keywords: ('oral' or 'mouth' or 'tongue' or 'floor of mouth' or 'lip' or 'gingiva' or 'buccal' or 'palate') and ('tumour budding'). Our search was limited to articles in the English language. The end point of the search was May 2017. To ensure inclusion of all relevant articles, we manually searched the reference lists of all eligible studies. When searching and screening the studies, we followed the Preferred Reporting Items for Systematic Review and Meta-Analysis (PRISMA) (Moher *et al*, 2009).

Exclusion criteria. We excluded studies in a language other than English, studies on animal samples and conference abstracts.

Quality assessment. We used reporting recommendations for tumour marker prognostic studies (REMARK) guidelines (Altman *et al*, 2012) to assess the quality of studies that evaluated the prognostic value of tumour budding in OSCC. We summarised the main guidelines in Table 1. Any study that received a score of less than 6 was not included in our meta-analysis.

Statistical methods. The meta-analysis was performed by the 'meta' package (version 4.8-1) in statistical software R (version 3.4.0). For each analysis, we carried out an inverse variance-weighted fixed-effects analysis. For completeness, a DerSimonian-Laird random effects analysis (DerSimonian and Laird, 1986) was also performed. We considered the random effects analysis as our main result to account for heterogeneity between the studies. In addition to the meta-analysed effect sizes, our results also included the estimated proportion of variation in effect sizes due to heterogeneity (I^2) (Higgins and Thompson, 2002) and the DerSimonian-Laird estimate of the variance of the effect sizes (τ^2) (DerSimonian and Laird, 1986). We first conducted meta-analyses for each survival end point even if tumour stage, oral subsite or budding cutoff point varied between the studies. To reduce heterogeneity among the included studies, we then conducted additional meta-analyses specifically for studies with early stage cases and for studies from single oral subsite (oral tongue). We also conducted separate meta-analyses for studies with a similar cutoff point of tumour budding.

RESULTS

Search results. A total of 63 hits were retrieved from searches of databases, and 39 hits were excluded as duplicates. There were 22 studies that had evaluated tumour budding in OSCC (Figure 2). Of these, 16 studies had reported the prognostic value of tumour budding in OSCC (Table 2). The other six studies had evaluated tumour budding in OSCC without providing its prognostic value (Table 3).

Statistical results. A meta-analysis of the prognostic value of tumour budding for lymph node metastasis, disease-free survival and overall survival is summarised in Figures 3–5. For each end

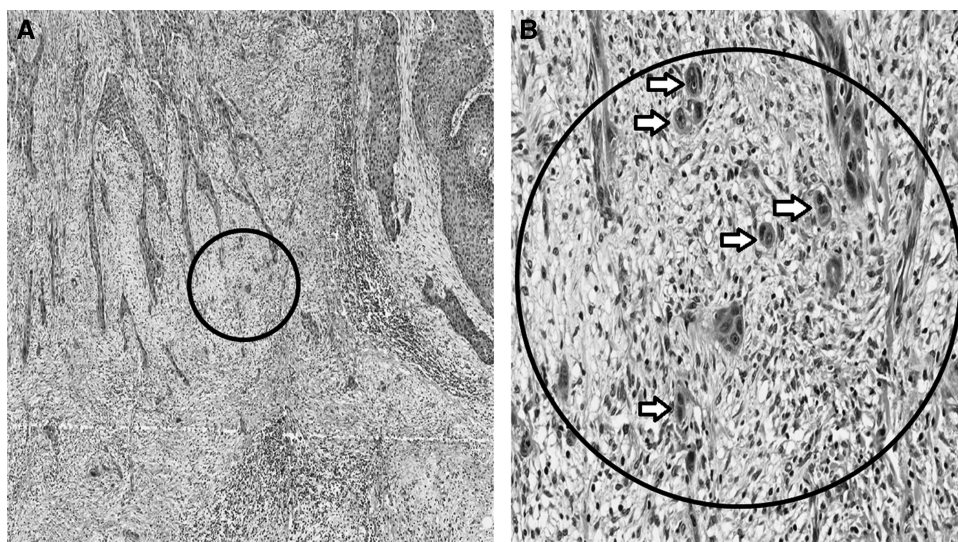


Figure 1. Tumour budding, defined as single cancer cell or clusters of less than five cells at the invasive front of oral squamous cell carcinoma (OSCC). (A) Low magnification ($\times 4$); and (B) high magnification ($\times 20$) of the area inside the circle.

Table 1. Evaluation criteria that have been used to assess the quality of studies evaluated tumour budding in OSCC (adapted from REMARK)

Checklist	Criteria
Introduction	The hypotheses and objectives of the study were clearly explained
Cohort description	Retrospective or prospective cohort with a well-defined study population Medical treatment of the cases was explained
Patient data	The basic data such as age, gender, clinical stage and histopathologic grade was provided
Evaluation method	Well-described method including the microscopic field/s and the cutoff point. Inter-observer variability was evaluated
Prognostic analysis	The survival end point was defined and/or the relationship between the tumour budding and lymph node metastasis was studied
Statistical analysis	Estimated effect (e.g., hazard ratio, relative risk with their confidence interval), which reveal the relationship between tumour budding and the survival end point/s The independence of prognostic value was reported by multivariate analysis
Classical prognostic factors	The prognostic value of the classical prognostic factors (e.g., stage and grade) were reported The relationship between tumour budding and classical prognostic factors was reported
Interpretation of the prognostic value and discussion	Comparison of the current findings with other studies Strengths and limitations of the current data Recommendation for further research

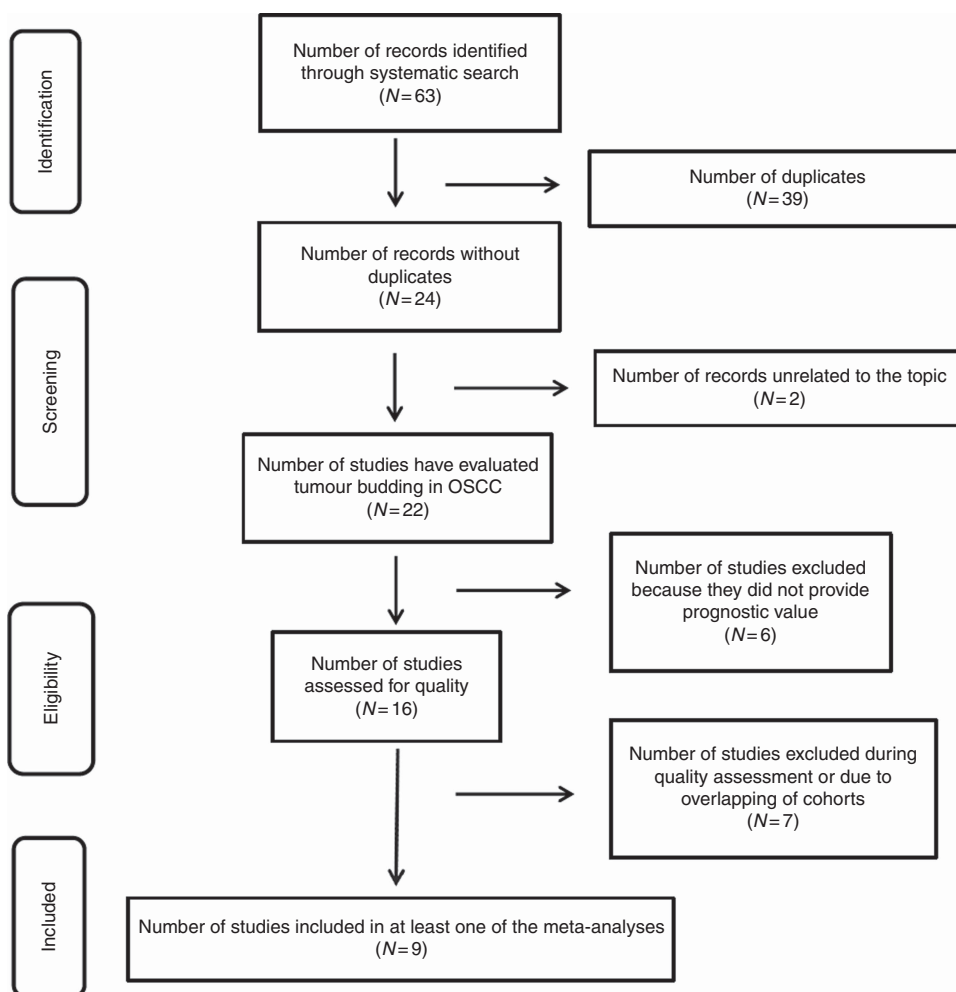


Figure 2. Flow diagram outlining the search strategy and the search results along various steps.

point, there was at least one meta-analysis of three high-quality studies (according to REMARK guidelines; Table 1) that had reported the necessary statistical values (hazard ratio (HR) or odds ratio (OR) and confidence interval (CI)). According to our

analyses, there was strong evidence for tumour budding to be considered as a promising prognostic marker for OSCC.

Our meta-analyses of eligible studies with different budding cutoff points for risk stratification indicated that high-grade

Table 2. Summary of the studies that examined the prognostic value of tumour budding in OSCC

(Authors, year) Country	Cases	Stage	Location	Follow up	Primary treatment	Staining	Cutoff	%	Field	Survival analysis	HR (95% CI)	P value	Quality
(Wang et al, 2011) China	133	I-IV	Tongue	65 months	Surgery	H-E	5 buds	44.4%	× 20	OS	3.350 (1.774 – 6.323) 3.029 (1.535 – 5.977)	0.0014	8
(Alman-gush et al, 2014) Finland	233	cT1-2N0	Tongue	67 months	Surgery	H-E	5 buds	34.8%	× 20	DSS	2.00 (1.17 – 3.40) 2.04 (1.17 – 3.55)	0.01	7
(Manjula et al, 2015) India	33	T1-T4	Gingivo buccal complex	15 months	Surgery	H-E	10 buds	63.6%	NA	DFS	1.32 (0.59 – 2.95)	0.49	6
										LNM	OR 7.5 (1.49 – 37.66)	0.014	
(Alman-gush et al, 2015b) Finland and Brazil	311	cT1-2N0	Tongue	57 months	Surgery	H-E	5 buds	30.9%	× 20	DSS	2.59 (1.58 – 4.26) 1.76 (1.01 – 3.06)	<0.001 0.044	7
										DFS	1.85 (1.21–2.82) 1.80 (1.10 – 2.93)	0.005 0.020	
										OS ^a	1.40 (1.01 – 1.93) 1.62 (1.17 – 2.25)	0.042 0.004	
(Angadi et al, 2015) India	75	T1-T4	Oral cavity	NA	Surgery	H-E	10 buds	45.3%	× 25	LNM	OR 6.79 (2.28 – 20.18)	<0.001 0.001	7
(Attrama-dal et al, 2015) Norway	58	cT1-2N0	Oral cavity	55 months	Surgery	IHC	5 buds	51.7%	× 20	DFS	NA	0.043	5
(Jensen et al, 2015a) Denmark	199	T1-T4	Tongue and floor of mouth	4.6 years	Surgery	IHC	Median bud count	50.3%	× 20 (DIA)	LNM	AUC of 0.69 (95% CI 0.61 – 0.76)	NA	8
										OS	1.8 (1.3 – 2.6) 1.6 (1.1 – 2.3)	0.01	
										DFS	2.1 (1.2 – 3.6)	<0.01	
(Xie et al, 2015) China	195 (106 with follow up)	cT1-2N0	Tongue	56 months	Surgery	IHC	5 buds	52.8%	× 20	Occult LNM	NA	0.015	7
										Local relapse	NA	0.001	
										OS	10.44 (2.43 – 44.88) 5.58 (1.23 – 25.38)	0.002 0.026	
(Nandita et al, 2016) India	30	NA	Oral cavity	NA	NA	H-E	5 buds	NA	NA	OS	NA	NA	3
(Seki et al, 2016) Japan	91	T1-T4	Tongue and floor of mouth (biopsy)	From 4 months to 5 years	Surgery; 47 cases received preoperative CT	IHC	3 buds	50.5%	× 20	LNM	Univariate: NA OR 31 (2.6 – 331.8)	<0.01	6
										OS	NA	<0.05	
										RFS	NA	<0.01	
(Xie et al, 2016) China	100	T1-T4	Tongue	3 years	Surgery	H-E, IHC	5 buds	49%	× 20	OS	2.23 (0.99 – 5.01)	0.046	

Table 2. (Continued)

(Authors, year) Country	Cases	Stage	Location	Follow up	Primary treatment	Staining	Cutoff	%	Field	Survival analysis	HR (95% CI)	P value	Quality
										LNM	NA	<0.01	
(Seki et al, 2017) Japan	209	cT1–T4	Oral cavity (biopsy)	16–72 months	Surgery; 111 cases received preoperative CT	IHC	5 buds	28.7%	× 20	LNM	Univariate: NA OR 30.05 (10.98 – 82.23)	<0.01	6
										RFS	NA	<0.01	
										OS	NA	0.01	
(Boxberg et al, 2017) Germany	157	T1–T4	Oral cavity	33.2 months	Surgery	H–E	5 buds	26.1%	× 40	OS	NA	0.003	5
										DSS	NA	0.001	
										DFS	NA	0.003	
(Pedersen et al, 2017) Denmark	222	cT1–2N0	Oral cavity	36 months	Surgery	IHC	DIA	NA	DIA	PFS	7.1 (2.4 – 20.5) 2.3 (1.5 – 3.8)	<0.001	8
										OS	4.0 (1.9 – 8.4) 1.6 (1.1 – 2.2)	0.01	
										Occult LNM	AUC of 0.83 (95% CI: 0.78 – 0.89)	<0.001	
(Hori et al, 2017) Japan	48	cT1–2N0	Tongue	71 months	Surgery	H–E	5 buds	27%	× 20	Neck recurrence	Univariate: NA RR 24.07 (2.27 – 254.89)	<0.001 <0.01	6
(Arora et al, 2017) India	336	cT1–2N0	OSCC	60 months	Surgery	H–E	5 buds	39.6%	× 20	LNM	OR 1.92 (1.18 – 3.12) ^b OR 1.28 (1.09 – 2.61)	0.008 0.039	8

Abbreviations: AUC = area under curve; CI = confidence interval; CT = chemotherapy; DFS = disease-free survival; DIA = digital image analysis; H–E = haematoxylin and eosin staining; HR = hazard ratio; IHC = immunohistochemical staining with cytokeratin or pan-cytokeratin. × 20 = refer to × 20 objective lens; LNM = lymph node metastasis; NA = not available; OR = odds ratio; OS = overall survival; % = percentage of cases with high intensity of tumour budding; PFS = progression free survival; RFS = relapse free survival; RR = risk ratio; SCC = squamous cell carcinoma.

^aWe conducted the OS from data of our original study Almangush et al, (2015b) for this meta-analysis.

^bWe computed a univariate OR (with its 95% CI) estimate for tumour budding from study of Arora et al, 2017.

Notes: Wang et al, (2011) and Xie et al, (2015, 2016) are overlapped. Almangush et al, (2014) and Almangush et al, (2015b) are overlapped. Jensen et al, (2015a) and (Pedersen et al, 2017) are overlapped. Seki et al, (2016) and Seki et al, (2017) are overlapped. HR, RR, OR and CI in bold are from multivariate analysis.

tumour budding was significantly associated with the presence of lymph node metastasis (Figure 3A) when compared with low-grade tumour budding (OR = 7.08, 95% CI = 1.75–28.73). Subsequently, our meta-analysis of studies (Arora et al, 2017; Seki et al, 2017) that used a cutoff point of five buds (Figure 3B) and our pooled analysis of the other studies (Angadi et al, 2015; Manjula et al, 2015) that used a cutoff point of 10 buds (Figure 3C) showed similar odds ratios (OR = 7.32, 95% CI = 0.49–108.35; and OR = 7.0, 95% CI = 2.84–17.29, respectively), while the former analysis was more heterogeneous.

The pooled analysis for disease-free survival (Figure 4) also showed that high-grade tumour budding was correlated with poorer survival (HR = 1.83, 95% CI = 1.34–2.50). For overall survival, tumour budding was associated with poor survival when all stages (Figure 5A) were included (HR = 1.88, 95% CI = 1.25–2.82) and also when a meta-analysis of early stage (Figure 5B) cases only was performed (HR = 3.27, 95% CI = 1.12–9.55). The pooled analyses for overall survival of the studies that evaluated tumour budding in oral tongue cancers using five buds as a cutoff point also showed similar results (Figure 5C) when advanced stage was included (HR = 2.07, 95% CI = 0.88–4.85), as well as when studies of early stage cases (Figure 5D) were analysed separately (HR = 3.35, 95% CI = 0.48–23.62).

We observed potential heterogeneity ($I^2 \geq 66\%$) between the studies for two analyses of lymph node metastasis (Figure 3A and B) and for overall survival meta-analyses (Figure 5), but we could not assess statistical significance of heterogeneity due to the small number of studies. Of note, for one meta-analysis of lymph node metastasis (Figure 3C), as well as for disease-free survival meta-analysis (Figure 4), we did not observe heterogeneity between the studies ($I^2 = 0$).

DISCUSSION

The invasive tumour front of OSCC has been an area of research interest in recent decades. Cancer cells at the IF behave aggressively compared with cancer cells in the superficial or central regions of the main tumour mass (Bryne et al, 1992; Jensen et al, 2015a). In addition, cancer cells at the IF may undergo epithelial–mesenchymal transition, which is an important step in progression of tumour metastasis (Christofori, 2006). Tumour budding that may be involved in development of metastasis has been reported at the IF and evaluated in several studies on OSCC (Table 2). Here, we performed a meta-analysis on the results of such studies. Our

Table 3. Summary of the studies evaluated tumour budding in OSCC without analysis of its prognostic value

(Authors, year) Country	Cases	Stage	Location	Follow up	Primary treatment	Staining	Cutoff	%	Field	Findings related to tumour budding
(Marangon Junior <i>et al</i> , 2014) Brazil	57	NA	Oral cavity	NA	NA	IHC	5 buds	75.4%	× 20	High intensity tumour budding is associated with higher density of stromal myofibroblasts and higher expression of laminin-5 gamma 2 chain
(Sawazaki-Calone <i>et al</i> , 2015) Brazil	113	T1–T4	Oral cavity	5 years	Surgery	H–E	5 buds	NA	× 20	Tumour budding is a parameter of the budding-depth (BD) prognostic model. BD showed a superior prognostic value compared to other histopathologic grading systems
(Jensen <i>et al</i> , 2015b) Denmark	28	NA	Oral cavity	NA	NA	IHC	NA	NA	NA	A relationship between tumour budding and myofibroblasts was seen but was not a general feature. Budding cells have shown low expression of E-cadherin
(Zhang <i>et al</i> , 2016) China	73	T1–T4	Tongue	114 months	CT for 7 cases, RT for 17, and surgery for others	H–E	5 buds	75.4%	× 20	High intensity of tumour budding was more common in tongue cancer (75.4%) compared to high intensity of tumour budding in nasopharyngeal carcinoma (45.5%)
(Strieder <i>et al</i> , 2017) Brazil	53	T1–T4	Lip	159.4 months or 57.4 months	Surgery	H–E	5 buds	67.9%	× 20	Tumour budding is a parameter of the budding-depth (BD) prognostic model. BD showed a high prognostic value for lip cancer
(Leao <i>et al</i> , 2017) Brazil	103	NA	Oral cavity	NA	NA	H–E; IHC	5 buds	NA	× 20	Evaluation of tumour budding by IHC showed higher reproducibility and replicability compared to H–E

Abbreviations: CT=chemotherapy; H-E=haematoxylin and eosin staining; IHC=immunohistochemical staining with cytokeratin or pan-cytokeratin.

meta-analysis shows that tumour budding is a promising prognostic marker for OSCC.

The importance of tumour budding in cancer prognosis has been studied widely particularly in colorectal cancer (Rogers *et al*, 2016; Lugli *et al*, 2017), where it is recognised as an additional prognostic marker (Koelzer *et al*, 2014). In oesophageal cancer (Almangush *et al*, 2016), pancreatic cancer (Karamitopoulou, 2012), breast cancer (Gujam *et al*, 2015) and lung cancer (Kadota *et al*, 2014), tumour budding has been reported as a promising prognostic marker. A significant correlation between high tumour budding count and the presence of lymph node metastases is one of the most important findings observed in OSCC (Figure 3) and in many other cancers (Yamaguchi *et al*, 2010; Landau *et al*, 2014; Salhia *et al*, 2015; Cappellesso *et al*, 2017). Such a finding might indicate that tumour budding is an early step en route to metastasis. A correlation between tumour budding and occult lymph node metastasis was reported in early stage OSCC (Xie *et al*, 2015). As occult metastasis is the most common reason for relapse and poor prognosis in early stage cases, it is of great importance to validate this correlation in other large multicentre cohorts.

Simplicity, reproducibility and low cost are important characteristics when considering a new marker for clinical application. The published studies in OSCC and in other cancers repeatedly reported these advantages for tumour budding (Wang *et al*, 2011; Graham *et al*, 2015; Almangush *et al*, 2015b). Another advantage of the studies of tumour budding in OSCC is that their results are consistent with those from the first study that evaluated budding in OSCC (Wang *et al*, 2011). Conversely, controversial findings were reported for the prognostic biomarkers identified for OSCC (Soland and Brusevold, 2013; Almangush *et al*, 2017a).

When considering a new prognostic marker for clinical application, the marker should also have a significant prognostic value independent from classical markers. Interestingly, for tumour budding, most of the studies that provided multivariate analysis (Wang *et al*, 2011; Angadi *et al*, 2015; Almangush *et al*, 2015b; Seki *et al*, 2016; Hori *et al*, 2017; Pedersen *et al*, 2017) reported that

tumour budding has a superior prognostic value compared to other classical markers such as TNM stage, depth of invasion or WHO tumour grade. However, in one study, (Manjula *et al*, 2015), tumour thickness (5-mm cutoff point) showed superior prognostic value compared with tumour budding, and the same was observed for depth of invasion in the study by Arora *et al*. (2017). In another study (Jensen *et al*, 2015a), advanced stage was associated with a poorer prognosis than in cases with high-grade budding. Of note, in the latter two studies (Jensen *et al*, 2015a; Arora *et al*, 2017) tumour budding was also reported as an independent prognostic marker in multivariate analysis. Therefore, multivariate analysis of published studies indicates that high-intensity tumour budding, either independently or in addition to the advanced stage, deeply invaded tumour or both, is associated with poor prognosis of OSCC. Only in the study by Manjula *et al*. (2015), tumour budding was not a prognostic marker in multivariate analysis. However, Manjula *et al*. used a 10-bud cutoff point to stratify cases into risk scores, and it is possible that some cases with \geq five buds were included in the low-grade budding group, which subsequently reduced the prognostic value of tumour budding in this cohort.

Different methods have been introduced for the evaluation of tumour budding (Koelzer *et al*, 2014). However, a traditional method was widely used in the studies on OSCC. In this method, the IF is scanned under low magnification ($\times 4$), and the field with the highest budding number is counted under high magnification ($\times 20$) and used for the score (Wang *et al*, 2011). The evaluation of intra-tumoural budding was not reported in OSCC. Of note, intra-tumoural budding was shown as a valid method in colorectal cancer (Lugli *et al*, 2011). In only a few studies, evaluation of the prognostic value of tumour budding at the IF was carried out in biopsy specimens of OSCC (Seki *et al*, 2016, 2017; Almangush *et al*, 2017b). However, the IF area might not be included in a biopsy specimen. In such cases, another form of tumour budding, the intra-tumoural budding (i.e., tumour budding between tumour islands) might be more applicable. The latter approach may be of great importance from a clinical point of view for treatment

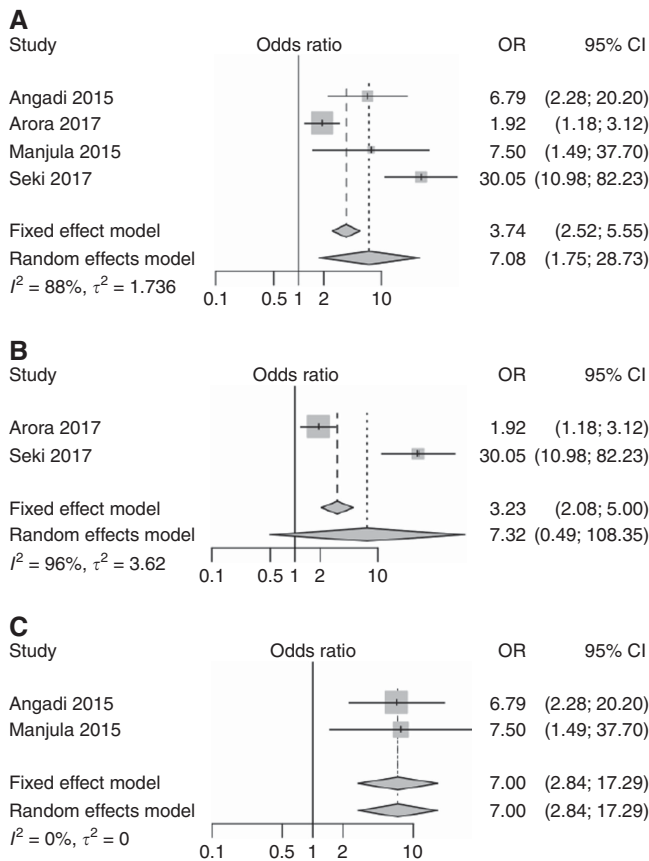


Figure 3. Forest plots for the pooled analyses of the studies evaluated the prognostic value of tumour budding in assessing lymph node metastasis of OSCC. (A) All eligible studies. (B) Studies used five-bud cutoff point. (C) Studies used 10-bud cutoff point.

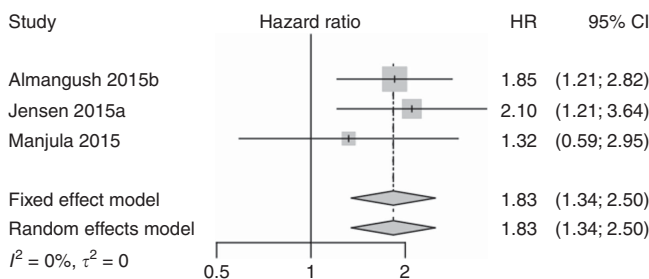


Figure 4. Pooled analysis for disease-free survival.

planning of OSCC, and should be further evaluated. In addition, intraoperative evaluation of tumour budding (i.e., using fresh-frozen sections) should also be considered in future studies.

Diverse cutoff points were suggested for stratification of cases into low-grade and high-grade tumour budding (Table 2). In the present studies on OSCC, five-bud cutoff point was the most commonly used (low grade <5 vs high grade ≥5). We conducted meta-analysis for studies that used different cutoff points (Figure 3A), and then, we conducted separate meta-analyses for studies that used a five-bud cutoff point (Figure 3B) and for studies that used a 10-bud cutoff point (Figure 3C). Interestingly, these meta-analyses show that tumour budding is a useful prognostic marker for OSCC cases. As the risk of poor prognosis begins at the presence of five buds, we suggest considering both five-bud and 10-bud cutoff points in further studies to determine which one of

these cutoff points is more predictive of poor prognosis and should therefore be used in clinical practice.

Most studies evaluated tumour budding using H-E staining. Interestingly, a recent study on OSCC concluded that evaluation of tumour budding by immunohistochemistry with pan-cytokeratin antibodies (clones AE1/AE3) showed a better reproducibility of results than those with H-E staining (Leao *et al*, 2017). However, standardisation of the evaluation method and cutoff point is still necessary. A recent international consensus conference on tumour budding (Lugli *et al*, 2017) made several statements (including definition, evaluation method and others) for reporting tumour budding in colorectal cancer. Such statements are still necessary to allow inclusion of tumour budding in a pathology report for OSCC cases.

The combination of squamous cell carcinoma (SCC) from different subsites of the oral cavity was a common disadvantage among the studies that evaluated tumour budding in OSCC. Therefore, we recommend a separate analysis for each subsite when reporting tumour budding in future studies. Despite a small number of studies available, we conducted a meta-analysis for overall survival of studies that evaluated tumour budding in oral tongue SCC (Figure 5C and D), which is the most common SCC of the oral cavity. The results of this meta-analysis suggest, although without strong statistical evidence, that cases of oral tongue cancer with a high budding index have a poorer overall survival. This is consistent with the other meta-analyses where the subsites were mixed. Another combination that was also common among the included studies was mixing of early stage and late-stage cancers in the same analysis. We conducted a meta-analysis for the two studies that included only early stage cancers (Figure 5D), and the result suggests that tumour budding in such early stage cases has a prognostic value, but given the wide confidence intervals, this result lacks strong statistical evidence and requires further studies for validation.

Tumour budding in OSCC has also been evaluated using digital pathology (Jensen *et al*, 2015a; Pedersen *et al*, 2017). Digital image analysis has been used increasingly in recent research and it has shown better accuracy and reproducibility compared with the conventional method as it allows truly quantitative scores (Riber-Hansen *et al*, 2012). Moreover, it will be easier to standardise the scoring method using digital image analysis (Pedersen *et al*, 2017). Therefore, digital image analysis of tumour budding in OSCC should be used to validate results in large cohorts.

Few studies have examined the biological background of tumour budding in OSCC. Immunohistochemical analysis showed that tumour budding is associated with reduced expression of E-cadherin and overexpression of vimentin (Wang *et al*, 2011). Regarding interactions with the surrounding stroma, high-grade budding was associated with a higher density of stromal myofibroblasts and higher expression of laminin-5 gamma 2 chain (Marangon Junior *et al*, 2014). In genetic profiling, decreased expression of *miR-200a*, *miR-200b* and *miR-200c* was reported in cancer cells of tumour budding (Jensen *et al*, 2015a). However, molecular analyses in other cancers have provided more details about the genetic background of tumour budding (Zlobec and Lugli, 2010; Galvan *et al*, 2015; Bradley *et al*, 2016; Miyake *et al*, 2017), and similar analyses in OSCC are still necessary to better understand this phenomenon.

The main limitation of the current meta-analyses is the small number of the original studies. Accordingly, it was difficult to statistically evaluate the heterogeneity between the studies. To avoid bias due to any potential heterogeneity, we focused on a random effects model that is known as an effective method to combine heterogeneous studies (Guolo and Varin, 2017). In addition, for each meta-analysis (Figures 3–5), we also reported results of a fixed effect model and they were consistent with a random effects model. Moreover, our meta-analyses addressed

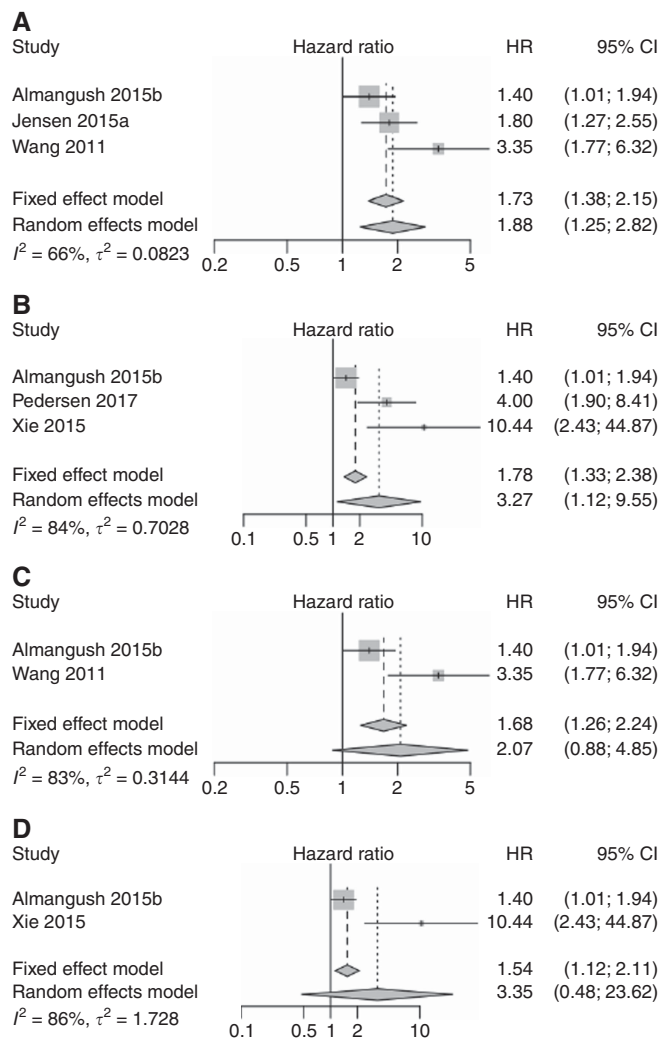


Figure 5. Pooled analyses for overall survival. (A) All stages of OSCC. (B) Pooled analysis for overall survival of OSCC including studies of early stage only. (C) Pooled analysis for overall survival including only oral tongue cancer studies which used five-bud cutoff point. (D) Pooled analysis for overall survival including early stage oral tongue cancer studies that used five-bud cutoff point.

three different end points (metastasis, overall survival and disease-free survival), and our results regarding the common effect of tumour budding as a negative prognostic marker are valid based on meta-analyses of these different end points. Of note, this effect is also consistent across published studies. Inclusion of different subsites of the oral cavity or mixing of different stages in analysis of the same cohort was another limitation, as mentioned above. The absence of prospective studies was also noted.

Despite these shortcomings, there is sufficient evidence to suggest that OSCCs with high-grade tumour budding are at high risk of poor prognosis. This evidence was prominent and validated in many studies. Similar evidence has also accumulated on the prognostic value of tumour budding in other cancers (Almangush *et al*, 2016; Rogers *et al*, 2016; Lugli *et al*, 2017). To the best of our knowledge, this is the first meta-analysis on the prognostic value of tumour budding in OSCC. We conclude that tumour budding has a prominent prognostic power for OSCC even at early stages of the disease. Future research on OSCC should compare the different evaluation methods with the goal of standardising the assessment method for pathology reports. In addition, understanding the genetic background of tumour budding may facilitate identification of treatment targets in OSCC.

ACKNOWLEDGEMENTS

This work was financially supported by the Finnish Dental Society (Alhadi Almangush), the Rauha Ahokas Foundation (Alhadi Almangush), the Academy of Finland (288509 and 294050 to Matti Pirinen), the Research Funds of the University of Helsinki (Matti Pirinen), the Helsinki University Hospital Research Fund (Antti A Mäkitie and Tuula Salo), the Sigrid Juselius Foundation (Tuula Salo), the Finnish Cancer Society (Tuula Salo) and the Maritza and Reino Salonen Foundation (Ilmo Leivo).

CONFLICT OF INTEREST

The authors declare no conflict of interest.

REFERENCES

- Almangush A, Bello IO, Coletta RD, Makitie AA, Makinen LK, Kauppila JH, Pukkila M, Hagstrom J, Laranne J, Soini Y, Kosma VM, Koivunen P, Kelner N, Kowalski LP, Grenman R, Leivo I, Laara E, Salo T (2015a) For early-stage oral tongue cancer, depth of invasion and worst pattern of invasion are the strongest pathological predictors for locoregional recurrence and mortality. *Virchows Arch* **467**(1): 39–46.
- Almangush A, Bello IO, Keski-Santti H, Makinen LK, Kauppila JH, Pukkila M, Hagstrom J, Laranne J, Tommola S, Nieminen O, Soini Y, Kosma VM, Koivunen P, Grenman R, Leivo I, Salo T (2014) Depth of invasion, tumor budding, and worst pattern of invasion: prognostic indicators in early-stage oral tongue cancer. *Head Neck* **36**(6): 811–818.
- Almangush A, Coletta RD, Bello IO, Bitu C, Keski-Santti H, Makinen LK, Kauppila JH, Pukkila M, Hagstrom J, Laranne J, Tommola S, Soini Y, Kosma VM, Koivunen P, Kowalski LP, Nieminen P, Grenman R, Leivo I, Salo T (2015b) A simple novel prognostic model for early stage oral tongue cancer. *Int J Oral Maxillofac Surg* **44**(2): 143–150.
- Almangush A, Heikkinen I, Makitie AA, Coletta RD, Laara E, Leivo I, Salo T (2017a) Prognostic biomarkers for oral tongue squamous cell carcinoma: a systematic review and meta-analysis. *Br J Cancer* **117**(6): 856–866.
- Almangush A, Karhunen M, Hautaniemi S, Salo T, Leivo I (2016) Prognostic value of tumour budding in oesophageal cancer: a meta-analysis. *Histopathology* **68**(2): 173–182.
- Almangush A, Leivo I, Siponen M, Sundquist E, Mroueh R, Makitie AA, Soini Y, Haglund C, Nieminen P, Salo T (2017b) Evaluation of the budding and depth of invasion (BD) model in oral tongue cancer biopsies. *Virchows Arch*; epub ahead of print 2 August 2017; doi:10.1007/s00428-017-2212-1.
- Altman DG, McShane LM, Sauerbrei W, Taube SE (2012) Reporting recommendations for tumor marker prognostic studies (REMARK): explanation and elaboration. *BMC Med* **10**: 51.
- Angadi PV, Patil PV, Hallikeri K, Mallapur MD, Hallikerimath S, Kale AD (2015) Tumor budding is an independent prognostic factor for prediction of lymph node metastasis in oral squamous cell carcinoma. *Int J Surg Pathol* **23**(2): 102–110.
- Arora A, Husain N, Bansal A, Neyaz A, Jaiswal R, Jain K, Chaturvedi A, Anand N, Malhotra K, Shukla S (2017) Development of a new outcome prediction model in early-stage squamous cell carcinoma of the oral cavity based on histopathologic parameters with multivariate analysis: the adit-nuzhat lymph-node prediction score (ANLPS) system. *Am J Surg Pathol* **41**(7): 950–960.
- Attramadal CG, Kumar S, Boysen ME, Dhakal HP, Nesland JM, Bryne M (2015) Tumor budding, EMT and cancer stem cells in T1-2/N0 oral squamous cell carcinomas. *Anticancer Res* **35**(11): 6111–6120.
- Boxberg M, Jesinghaus M, Dorfner C, Mogler C, Drecoll E, Warth A, Steiger K, Bollwein C, Meyer P, Wolff KD, Kolk A, Weichert W (2017) Tumor budding activity and cell nest size determine patient outcome in oral squamous cell carcinoma: Proposal for an adjusted grading system. *Histopathology* **70**(7): 1125–1137.
- Bradley CA, Dunne PD, Bingham V, McQuaid S, Khawaja H, Craig S, James J, Moore WL, McArt DG, Lawler M, Dasgupta S, Johnston PG, Van Schaeybroeck S (2016) Transcriptional upregulation of c-MET is

- associated with invasion and tumor budding in colorectal cancer. *Oncotarget* 7(48): 78932–78945.
- Bryne M, Koppang HS, Lilleng R, Kjaerheim A (1992) Malignancy grading of the deep invasive margins of oral squamous cell carcinomas has high prognostic value. *J Pathol* 166(4): 375–381.
- Cappellesso R, Luchini C, Veronese N, Mele ML, Rosa-Rizzotto E, Guido E, De Lazzari F, Pilati P, Farinati F, Realdon S, Solmi M, Fassan M, Rugge M (2017) Tumor budding as a risk factor for nodal metastasis in Pt1 colorectal cancers: a meta-analysis. *Hum Pathol* 65: 62–70.
- Chen TC, Wang CP, Ko JY, Yang TL, Hsu CW, Yeh KA, Chang YL, Lou PJ (2013) The impact of perineural invasion and/or lymphovascular invasion on the survival of early-stage oral squamous cell carcinoma patients. *Ann Surg Oncol* 20(7): 2388–2395.
- Christofori G (2006) New signals from the invasive front. *Nature* 441(7092): 444–450.
- DerSimonian R, Laird N (1986) Meta-analysis in clinical trials. *Control Clin Trials* 7(3): 177–188.
- Ferlay J, Soerjomataram I, Dikshit R, Eser S, Mathers C, Rebelo M, Parkin DM, Forman D, Bray F (2015) Cancer incidence and mortality worldwide: sources, methods and major patterns in GLOBOCAN 2012. *Int J Cancer* 136(5): E359–E386.
- Galvan JA, Zlobec I, Wartenberg M, Lugli A, Gloor B, Perren A, Karamitopoulou E (2015) Expression of E-cadherin repressors SNAIL, ZEB1 and ZEB2 by tumour and stromal cells influences tumour-budding phenotype and suggests heterogeneity of stromal cells in pancreatic cancer. *Br J Cancer* 112(12): 1944–1950.
- Graham RP, Vierkant RA, Tillmans LS, Wang AH, Laird PW, Weisenberger DJ, Lynch CF, French AJ, Slager SL, Raissian Y, Garcia JJ, Kerr SE, Lee HE, Thibodeau SN, Cerhan JR, Limburg PJ, Smyrk TC (2015) Tumor budding in colorectal carcinoma: confirmation of prognostic significance and histologic cutoff in a population-based cohort. *Am J Surg Pathol* 39(10): 1340–1346.
- Gujam FJ, McMillan DC, Mohammed ZM, Edwards J, Going JJ (2015) The relationship between tumour budding, the tumour microenvironment and survival in patients with invasive ductal breast cancer. *Br J Cancer* 113(7): 1066–1074.
- Guolo A, Varin C (2017) Random-effects meta-analysis: the number of studies matters. *Stat Methods Med Res* 26(3): 1500–1518.
- Higgins JP, Thompson SG (2002) Quantifying heterogeneity in a meta-analysis. *Stat Med* 21(11): 1539–1558.
- Hori Y, Kubota A, Yokose T, Furukawa M, Matsushita T, Takita M, Mitsunaga S, Mizoguchi N, Nonaka T, Nakayama Y, Oridate N (2017) Predictive significance of tumor depth and budding for late lymph node metastases in patients with clinical n0 early oral tongue carcinoma. *Head Neck Pathol* 11(4): 477–486.
- Jensen DH, Dabelsteen E, Specht L, Fiehn AM, Therkildsen MH, Jonson L, Vikesaa J, Nielsen FC, von Buchwald C (2015a) Molecular profiling of tumour budding implicates TGFbeta-mediated epithelial-mesenchymal transition as a therapeutic target in oral squamous cell carcinoma. *J Pathol* 236(4): 505–516.
- Jensen DH, Reibel J, Mackenzie IC, Dabelsteen E (2015b) Single cell migration in oral squamous cell carcinoma - possible evidence of epithelial-mesenchymal transition in vivo. *J Oral Pathol Med* 44(9): 674–679.
- Kadota K, Nitadori J, Woo KM, Sima CS, Finley DJ, Rusch VW, Adusumilli PS, Travis WD (2014) Comprehensive pathological analyses in lung squamous cell carcinoma: single cell invasion, nuclear diameter, and tumor budding are independent prognostic factors for worse outcomes. *J Thorac Oncol* 9(8): 1126–1139.
- Kadota K, Yeh YC, Villena-Vargas J, Cherkassky L, Drill EN, Sima CS, Jones DR, Travis WD, Adusumilli PS (2015) Tumor budding correlates with the protumor immune microenvironment and is an independent prognostic factor for recurrence of stage I lung adenocarcinoma. *Chest* 148(3): 711–721.
- Karamitopoulou E (2012) Tumor budding cells, cancer stem cells and epithelial-mesenchymal transition-type cells in pancreatic cancer. *Front Oncol* 2: 209.
- Koelzer VH, Langer R, Zlobec I, Lugli A (2014) Tumor budding in upper gastrointestinal carcinomas. *Front Oncol* 4: 216.
- Korvala J, Jee K, Porkola E, Almangush A, Mosakhani N, Bitu C, Cervigne NK, Zandonadi FS, Meirelles GV, Leme AF, Coletta RD, Leivo I, Salo T (2017) MicroRNA and protein profiles in invasive versus non-invasive oral tongue squamous cell carcinoma cells in vitro. *Exp Cell Res* 350(1): 9–18.
- Landau MS, Hastings SM, Foxwell TJ, Luketich JD, Nason KS, Davison JM (2014) Tumor budding is associated with an increased risk of lymph node metastasis and poor prognosis in superficial esophageal adenocarcinoma. *Mod Pathol* 27(12): 1578–1589.
- Leao PL, Marangon Junior H, Melo VV, Caixeta AB, Souza PE, de Aguiar MC, Horta MC (2017) Reproducibility, repeatability and level of difficulty of two methods for tumor budding evaluation in oral squamous cell carcinoma. *J Oral Pathol Med* 46(10): 949–955.
- Lugli A, Kirsch R, Ajioka Y, Bosman F, Cathomas G, Dawson H, El Zimaity H, Flejou JF, Hansch TP, Hartmann A, Kakar S, Langner C, Nagtegaal I, Puppa G, Riddell R, Ristimaki A, Sheahan K, Smyrk T, Sugihara K, Terris B, Ueno H, Vieth M, Zlobec I, Quirke P (2017) Recommendations for reporting tumor budding in colorectal cancer based on the International Tumor Budding Consensus Conference (ITBCC) 2016. *Mod Pathol* 30(9): 1299–1311.
- Lugli A, Vljajic T, Giger O, Karamitopoulou E, Patsouris ES, Peros G, Terracciano LM, Zlobec I (2011) Intratumoral budding as a potential parameter of tumor progression in mismatch repair-proficient and mismatch repair-deficient colorectal cancer patients. *Hum Pathol* 42(12): 1833–1840.
- Manjula BV, Augustine S, Selvam S, Mohan AM (2015) Prognostic and predictive factors in gingivo buccal complex squamous cell carcinoma: role of tumor budding and pattern of invasion. *Indian J Otolaryngol Head Neck Surg* 67(Suppl 1): 98–104.
- Marangon Junior H, Rocha VN, Leite CF, de Aguiar MC, Souza PE, Horta MC (2014) Laminin-5gamma 2 chain expression is associated with intensity of tumor budding and density of stromal myofibroblasts in oral squamous cell carcinoma. *J Oral Pathol Med* 43(3): 199–204.
- Miyake M, Hori S, Morizawa Y, Tatsumi Y, Toritsuka M, Ohnishi S, Shimada K, Furuya H, Khadka VS, Deng Y, Ohnishi K, Iida K, Gotoh D, Nakai Y, Inoue T, Anai S, Torimoto K, Aoki K, Tanaka N, Konishi N, Fujimoto K (2017) Collagen type IV alpha 1 (COL4A1) and collagen type XIII alpha 1 (COL13A1) produced in cancer cells promote tumor budding at the invasion front in human urothelial carcinoma of the bladder. *Oncotarget* 8(22): 36099–36114.
- Moher D, Liberati A, Tetzlaff J, Altman DG, Group P (2009) Preferred reporting items for systematic reviews and meta-analyses: the PRISMA statement. *BMJ* 339: b2535.
- Muller S, Pan Y, Li R, Chi AC (2008) Changing trends in oral squamous cell carcinoma with particular reference to young patients: 1971–2006. The Emory University experience. *Head Neck Pathol* 2(2): 60–66.
- Nandita KP, Boaz K, Srikant N, Lewis AJ, Manaktala N (2016) Tumour budding: a promising parameter in oral squamous cell carcinoma. *Res J Pharm Biol Chem Sci* 7(5): 2059–2063.
- Pedersen NJ, Jensen DH, Lelkaitis G, Kiss K, Charabi B, Specht L, von Buchwald C (2017) Construction of a pathological risk model of occult lymph node metastases for prognostication by semi-automated image analysis of tumor budding in early-stage oral squamous cell carcinoma. *Oncotarget* 8(11): 18227–18237.
- Riber-Hansen R, Vainer B, Steiniche T (2012) Digital image analysis: a review of reproducibility, stability and basic requirements for optimal results. *APMIS* 120(4): 276–289.
- Rogers AC, Winter DC, Heeney A, Gibbons D, Lugli A, Puppa G, Sheahan K (2016) Systematic review and meta-analysis of the impact of tumour budding in colorectal cancer. *Br J Cancer* 115(7): 831–840.
- Salhia B, Trippel M, Pfaltz K, Cihoric N, Grogg A, Ladrach C, Zlobec I, Tapia C (2015) High tumor budding stratifies breast cancer with metastatic properties. *Breast Cancer Res Treat* 150(2): 363–371.
- Sawazaki-Calone I, Rangel A, Bueno AG, Morais CF, Nagai HM, Kunz RP, Souza RL, Rutkuskis L, Salo T, Almangush A, Coletta RD (2015) The prognostic value of histopathological grading systems in oral squamous cell carcinomas. *Oral Dis* 21(6): 755–761.
- Seki M, Sano T, Yokoo S, Oyama T (2016) Histologic assessment of tumor budding in preoperative biopsies to predict nodal metastasis in squamous cell carcinoma of the tongue and floor of the mouth. *Head Neck* 38(Suppl 1): E1582–E1590.
- Seki M, Sano T, Yokoo S, Oyama T (2017) Tumour budding evaluated in biopsy specimens is a useful predictor of prognosis in patients with cN0 early stage oral squamous cell carcinoma. *Histopathology* 70(6): 869–879.
- Soland TM, Brusevold IJ (2013) Prognostic molecular markers in cancer - quo vadis? *Histopathology* 63(3): 297–308.
- Strieder L, Coutinho-Camillo CM, Costa V, da Cruz Perez DE, Kowalski LP, Kaminagapura E (2017) Comparative analysis of three histologic grading methods for squamous cell carcinoma of the lip. *Oral Dis* 23(1): 120–125.

- Wang C, Huang H, Huang Z, Wang A, Chen X, Huang L, Zhou X, Liu X (2011) Tumor budding correlates with poor prognosis and epithelial-mesenchymal transition in tongue squamous cell carcinoma. *J Oral Pathol Med* **40**(7): 545–551.
- Xie N, Wang C, Liu X, Li R, Hou J, Chen X, Huang H (2015) Tumor budding correlates with occult cervical lymph node metastasis and poor prognosis in clinical early-stage tongue squamous cell carcinoma. *J Oral Pathol Med* **44**(4): 266–272.
- Xie N, Wang C, Zhuang Z, Hou J, Liu X, Wu Y, Liu H, Huang H (2016) Decreased miR-320a promotes invasion and metastasis of tumor budding cells in tongue squamous cell carcinoma. *Oncotarget* **7**(40): 65744–65757.
- Yamaguchi Y, Ishii G, Kojima M, Yoh K, Otsuka H, Otaki Y, Aokage K, Yanagi S, Nagai K, Nishiwaki Y, Ochiai A (2010) Histopathologic features of the tumor budding in adenocarcinoma of the lung: tumor budding as an index to predict the potential aggressiveness. *J Thorac Oncol* **5**(9): 1361–1368.
- Zhang P, Zhang L, Liu H, Zhao L, Li Y, Shen JX, Liu Q, Liu MZ, Xi M (2016) Clinicopathologic characteristics and prognosis of tongue squamous cell carcinoma in patients with and without a history of radiation for nasopharyngeal carcinoma: a matched case-control study. *Cancer Res Treat* **49**(3): 695–705.
- Zlobec I, Lugli A (2010) Epithelial mesenchymal transition and tumor budding in aggressive colorectal cancer: tumor budding as oncotarget. *Oncotarget* **1**(7): 651–661.

This work is published under the standard license to publish agreement. After 12 months the work will become freely available and the license terms will switch to a Creative Commons Attribution-NonCommercial-Share Alike 4.0 Unported License.